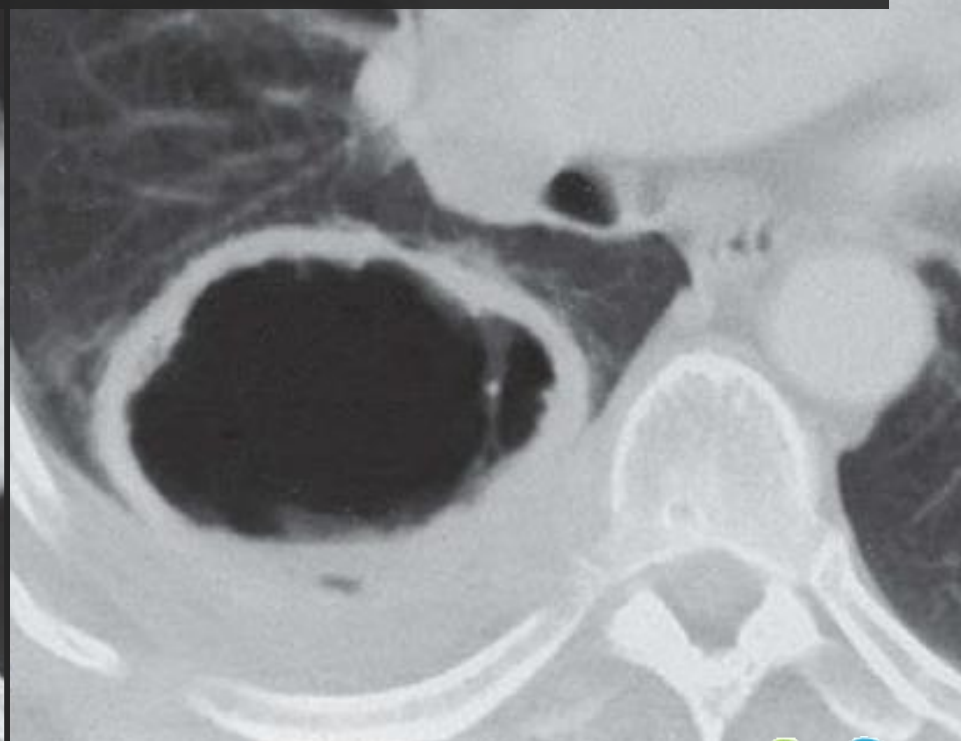
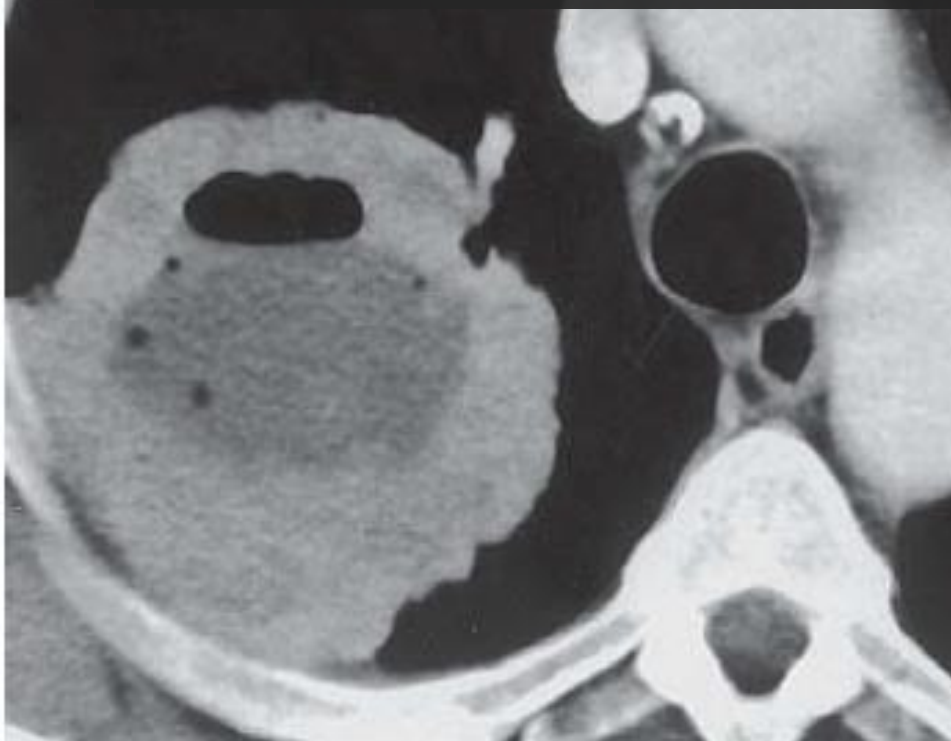


Pulmonary Cavitation & Cyst



潘奕宏 2020/8/16

Division of Pulmonary Department, Antai TSMH

安泰醫療社團法人安泰醫院 胸腔內科 主治醫師



Disclaimer

- No disclosure.

Fleischner Society: Glossary of Terms for Thoracic Imaging¹

- **Cavity:** A cavity is a **gas-filled** space, seen as a lucency or low-attenuation area, **within** pulmonary consolidation, a mass, or a nodule
- **Cyst:** A cyst appears as a round parenchymal lucency or low-attenuating area with a **well-defined interface** with normal lung. Cysts have variable wall thickness but are **usually thin-walled (<2 mm)** and occur without associated pulmonary emphysema

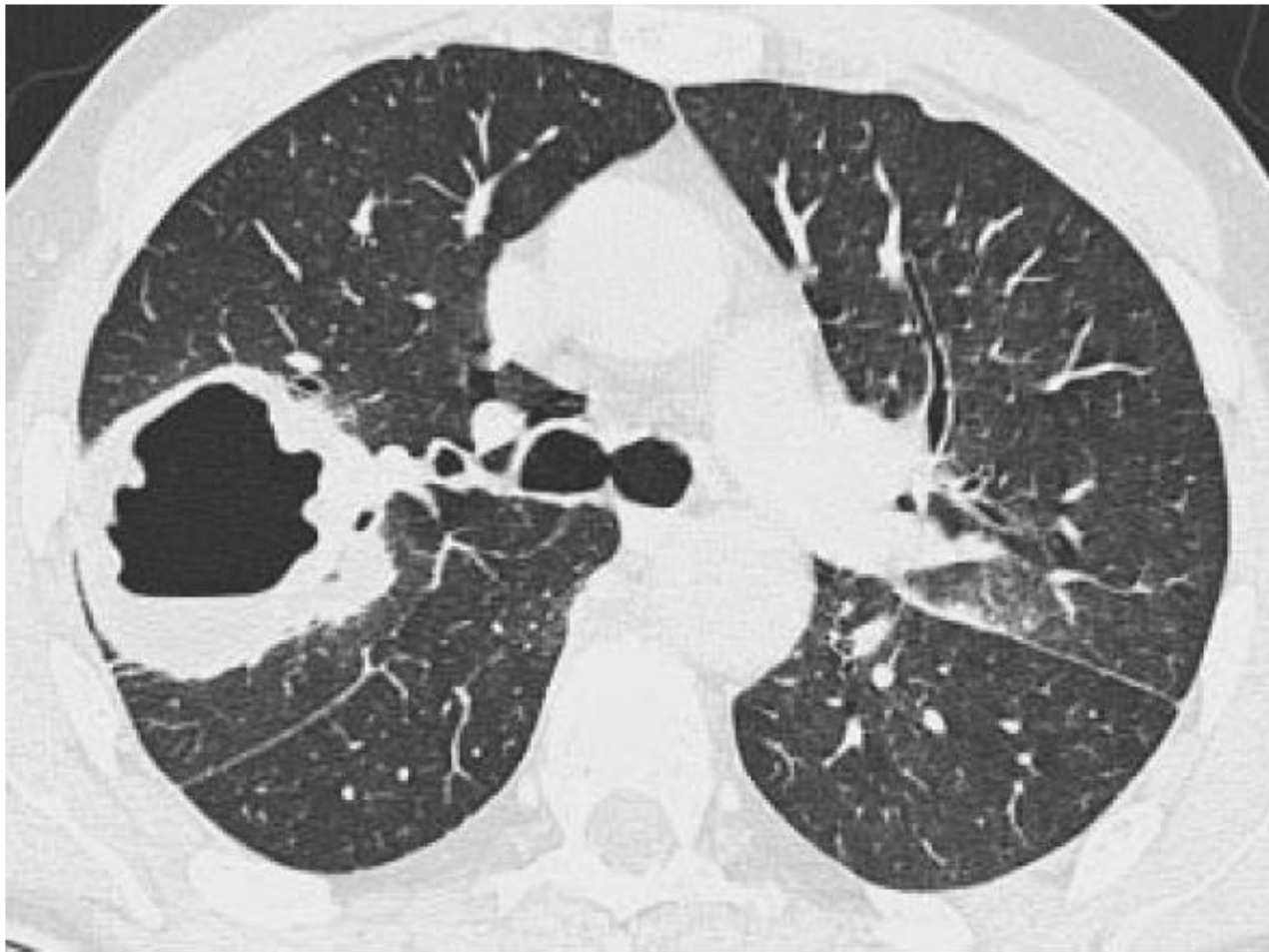
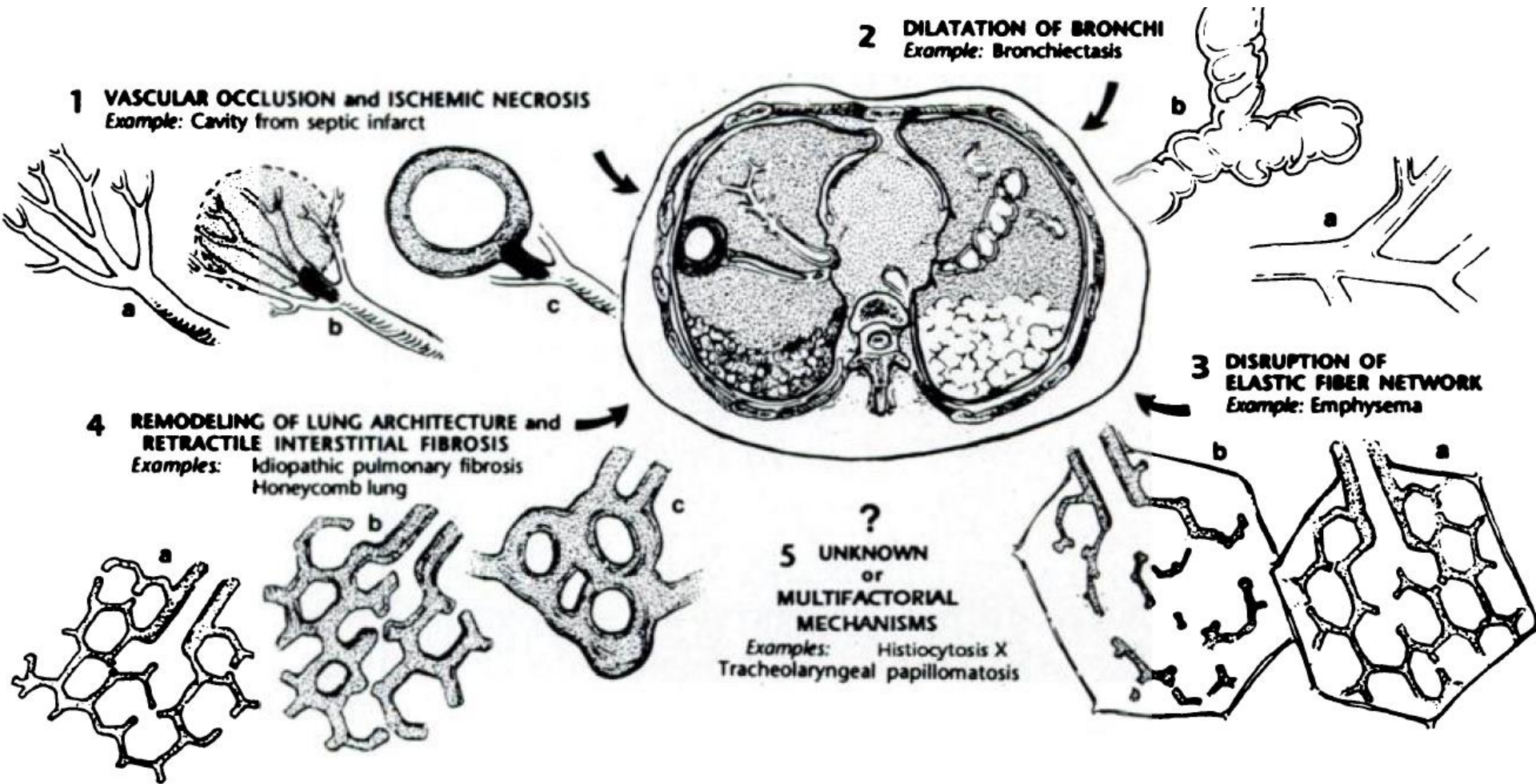


Figure 17: Transverse CT scan shows cavitating mass in right upper lobe.

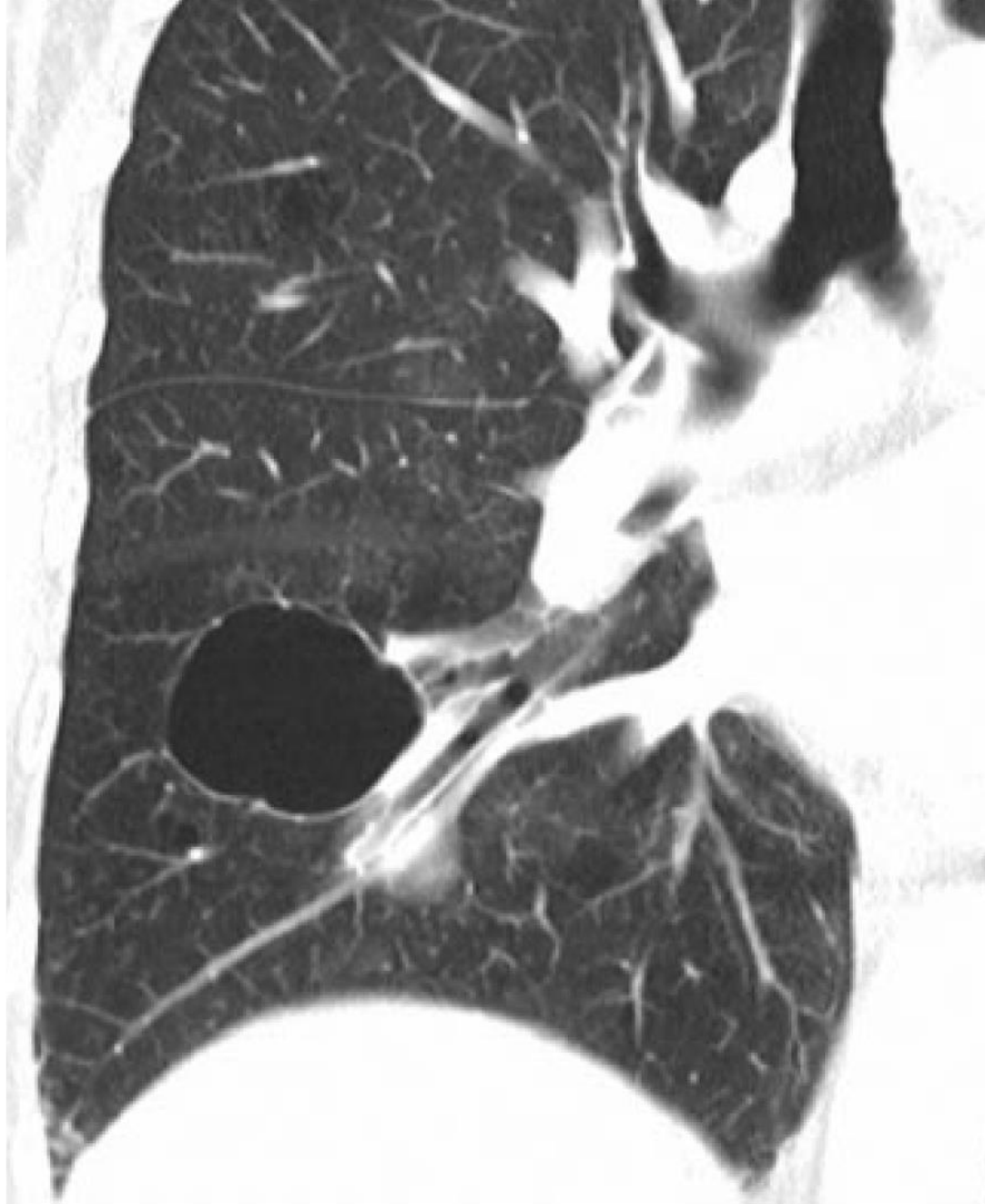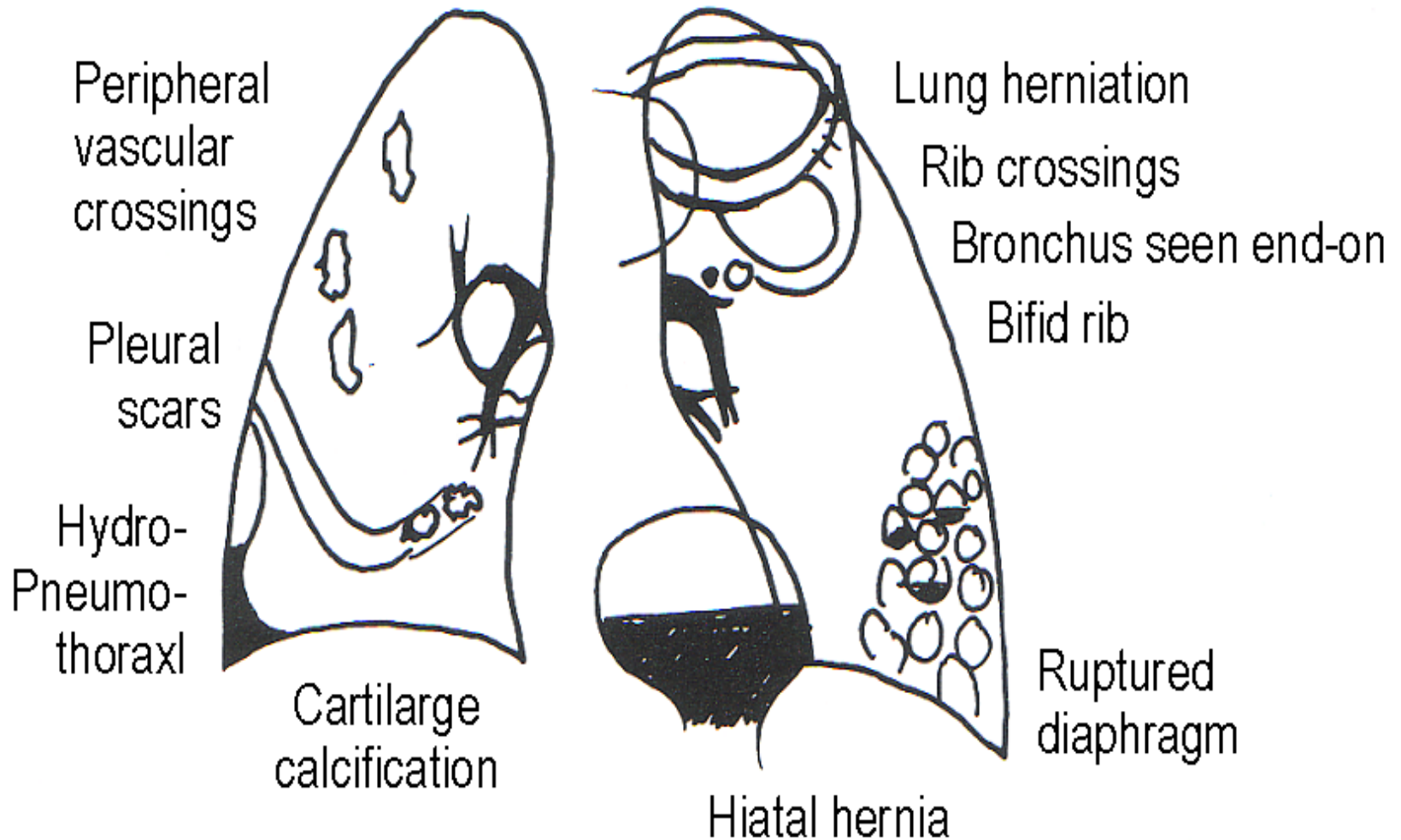


Figure 21: Coronal CT scan shows a cyst. Radiology. 2008 Mar;246(3):697-722.

Abnormal **air-filled** spaces in the lung and their mechanisms of formation



Pseudo-cavities and Pseudocysts



■ **C: cancer**

- Primary bronchogenic carcinoma: most frequently SCC
- Pulmonary metastasis: most frequently SCC, also adenocarcinoma, sarcoma

■ **A: autoimmune;**

- Wegener Granulomatosis, rheumatoid arthritis (rheumatoid nodules) etc.

■ **V: vascular** (both bland and septic pulmonary emboli)

■ **I: infection** (bacterial/fungal) / **inhalation**

- pulmonary abscess
- fungal / parasite infection
- pulmonary tuberculosis
- pneumoconiosis

■ **T: trauma** - pneumatoceles

■ **Y: youth**

- CPAM (congenital pulmonary airway malformation)
- pulmonary sequestration
- bronchogenic cyst

Lucent Defects in chest image

- Solitary localized vs. Multiple
- Cavity vs. Cyst

I. Cavity

A. Inflammation

- ★ 1. Abscess, acute or chronic
 - a. Pyogenic infection^{40,279} (staphylococcal and gram-negative pneumonia)
 - b. Aspiration pneumonia⁴⁰ (common source of anaerobes)
 - c. Mycoplasma pneumonia^{444,686} (rare)
- ★ 2. Fungal infection^{481,584}
 - a. Histoplasmosis^{127,144}
 - b. Coccidioidomycosis⁴⁸³
 - c. Blastomycosis^{291,580}
 - d. Cryptococcosis^{264,306}
 - e. Mucormycosis^{41,821}
 - f. Aspergillosis²²²
- 3. Mycobacterial infection
 - ★ Tuberculosis (typical and atypical)^{76,109,476,504,767}
 - b. Nocardiosis^{35,280}

B. Neoplasms

- ★ 1. Primary lung tumor⁷⁴⁰
- 2. Metastases (usually multiple)^{31,133,156}
 - a. Squamous cell (nasopharynx, esophagus, cervix)
 - b. Adenocarcinoma (lung, breast, gastrointestinal tract)
 - c. Osteosarcoma (rare)
 - d. Melanoma

C. Vascular (commonly multiple)

- 1. Rheumatoid^{191,600}
- 2. Wegener's granulomatosis^{427,467}
- 3. Infarct (thromboemboli or septic emboli)¹⁴⁸

D. Environmental

- 1. Silicosis and coal-worker's pneumoconiosis (most commonly owing to complicating tuberculosis)

I. Cavities

A. Infection

1. Bacterial pneumonias²⁷⁹ (*Staphylococcus*, *Klebsiella*, mixed gram-negative organisms, anaerobes, and *Nocardia*)
2. Fungal infections
 - a. Histoplasmosis^{127,144}
 - b. Blastomycosis⁵⁸⁰
 - c. Coccidioidomycosis⁴⁸³
 - d. Cryptococcosis^{264,306,387}
 - e. Mucormycosis⁴¹
 - f. Sporotrichosis¹¹⁹
 - g. Aspergillosis⁵⁸⁴
3. Tuberculosis^{76,798}
4. Parasites (echinococcal disease)^{458,563}

B. Neoplasms

- ★1. Metastases^{31,133,156}
2. Lymphoma (rare)⁴⁶⁵
3. Bronchioloalveolar cell carcinoma^{778,780}
4. Pulmonary papillomatosis²⁵⁰

C. Vascular

1. Rheumatoid disease⁶⁰⁰
- ★2. Wegener's granulomatosis⁴⁶⁷
3. Infarcts¹⁴⁸
- ★4. Septic emboli^{290,824}

- II. Pneumatocele
 - A. Postinfectious^{22,155,286,303}
 - B. Posttraumatic^{184,272}
- III. Congenital cyst^{595,596}
 - A. Bronchogenic cyst¹⁷
 - B. Intrapulmonary sequestration^{195,311}
- IV. Parasitic cysts (Hydatid cyst)⁵⁶³
- V. Bronchiectatic cyst⁵⁹⁶
- VI. Bullous emphysema²¹⁸

Chart 24-1

MULTIPLE LUCENT LESIONS

- II. Cystic bronchiectasis (recurrent pneumonias, tuberculosis, cystic fibrosis, agammaglobulinemia, allergic aspergillosis)
- III. Pneumatoceles^{22,155,184,303}
- IV. Bullous emphysema (see Chapter 22)
- V. Honeycomb lung (see Chapter 19)
- VI. Cystic adenomatoid malformation (newborn)^{466,783}
- VII. Herniation of small bowel (congenital or traumatic)
- VIII. Idiopathic lung diseases with cysts
 - ★ A. Langerhans' cell histiocytosis¹⁶
 - ★ B. Lymphangioleiomyomatosis⁵⁴⁹
 - ★ C. Lymphocytic interstitial pneumonia⁵¹⁸
 - D. Amyloidosis²²⁵

Differential Diagnosis

- Thickness of cavitary wall (壁厚)
- Multiplicity of Lesions (數目)
- Inner contour of cavity (壁內緣)
- Nature of the cavitary content (內容物)
- Associated Lesions (周圍肺實質的變化)
- Location (位置)

Thickness of Cavitory Wall

■ Wall thickness: (measure thickest part)

- ☐ < 4 mm: favor benign.
- ☐ 4-15 mm: inconclusive
- ☐ > 15 mm: favor malignancy

■ Thick:

- ☐ Inflammatory: lung abscess
- ☐ Granulomatous Dx: WG
- ☐ Neoplasm: primary lung cancer

■ Thin:

- ☐ Congenital: bronchogenic cyst
- ☐ Bullae

Multiplicity of Lesions (數目)

■ Solitary: such as

- ☐ Primary lung cancer
- ☐ Acute lung abscess
- ☐ Post-traumatic lung cyst

■ Multiple: such as

- ☐ Wegener granulomatosis
- ☐ Septic emboli
- ☐ Lung metastases

Inner Contour of Cavity (壁内縁)

- **Nodular / Irregular / Lobulated:**
malignancy
- **Shaggy:** acute lung abscess
- **Smooth:** more favor benign lesions

Cavitary Content (內容物)

■ Fluid (air-fluid level):

- In most cases, the contents are liquid
- Malignancy is less likely, except bleeding or 2nd infection

■ Fungus ball:

- Aspergillosis

■ Pulmonary gangrene:

- Necrotic lung parenchyma的片段會浮在cavity fluid上，如同浮在水面的冰山一般

■ Water-lily sign:

- Ruptured **echinococcus cyst** which float on the top of the fluid

Associated Lesions

(周圍肺實質的變化)

- **Air-space consolidation:**

- Acute process, such infection, hemorrhage

- **Irregular reticular strands:**

- Chronic fibrotic scar

Location (位置)

■ Central:

- ☐ More common in fibrotic and neoplastic lesions

■ Peripheral:

- ☐ More common in embolic, metastatic and infectious lesions (hematogeneous spreading)

■ Apical:

- ☐ TB
- ☐ Fungus ball

Cavitary Lesions

■ Vascular

- ☐ Collagen-vascular:
 - Wegener granulomatosis
 - Rheumatoid nodule
- ☐ Thromboembolic:
 - Pulmonary infarct
 - Septic emboli

■ Infection / Inflammation

- ☐ Pyogenic
- ☐ TB
- ☐ Fungus
- ☐ Nocardia

■ Inhalation

- ☐ Silicosis
- ☐ Coal-worker pneumoconiosis (CWP)

■ Neoplasm

- ☐ Primary lung cancer
- ☐ Metastasis of lung

■ **C: cancer**

- Primary bronchogenic carcinoma: most frequently SCC
- Pulmonary metastasis: most frequently SCC, also adenocarcinoma, sarcoma

■ **A: autoimmune;**

- Wegener Granulomatosis, rheumatoid arthritis (rheumatoid nodules) etc.

■ **V: vascular** (both bland and septic pulmonary emboli)

■ **I: infection** (bacterial/fungal) / **inhalation**

- pulmonary abscess
- fungal / parasite infection
- pulmonary tuberculosis
- pneumoconiosis

■ **T: trauma** - pneumatoceles

■ **Y: youth**

- CPAM (congenital pulmonary airway malformation)
- pulmonary sequestration
- bronchogenic cyst

Cancer

Primary lung cancer:

- Squamous cell carcinoma
- Cavitating neoplasm also develop **after chemotherapy**

Metastatic cancer:

- Mostly:
 - ☐ lung cancer
 - ☐ **head and neck**
 - ☐ **cervical cancer**
 - ☐ **colon**
- Also:
 - ☐ esophageal cancer
 - ☐ transitional cell carcinoma of bladder
 - ☐ sarcomas
 - ☐ lymphoma
 - ☐ pancreatic adenocarcinoma (very rare)

Cancer

Features suggesting malignancy

- **Not** significant amount of **fluid**
- **Eccentric** cavitation
- **Thick wall** (?)
- Lobulated and nodular inner margin

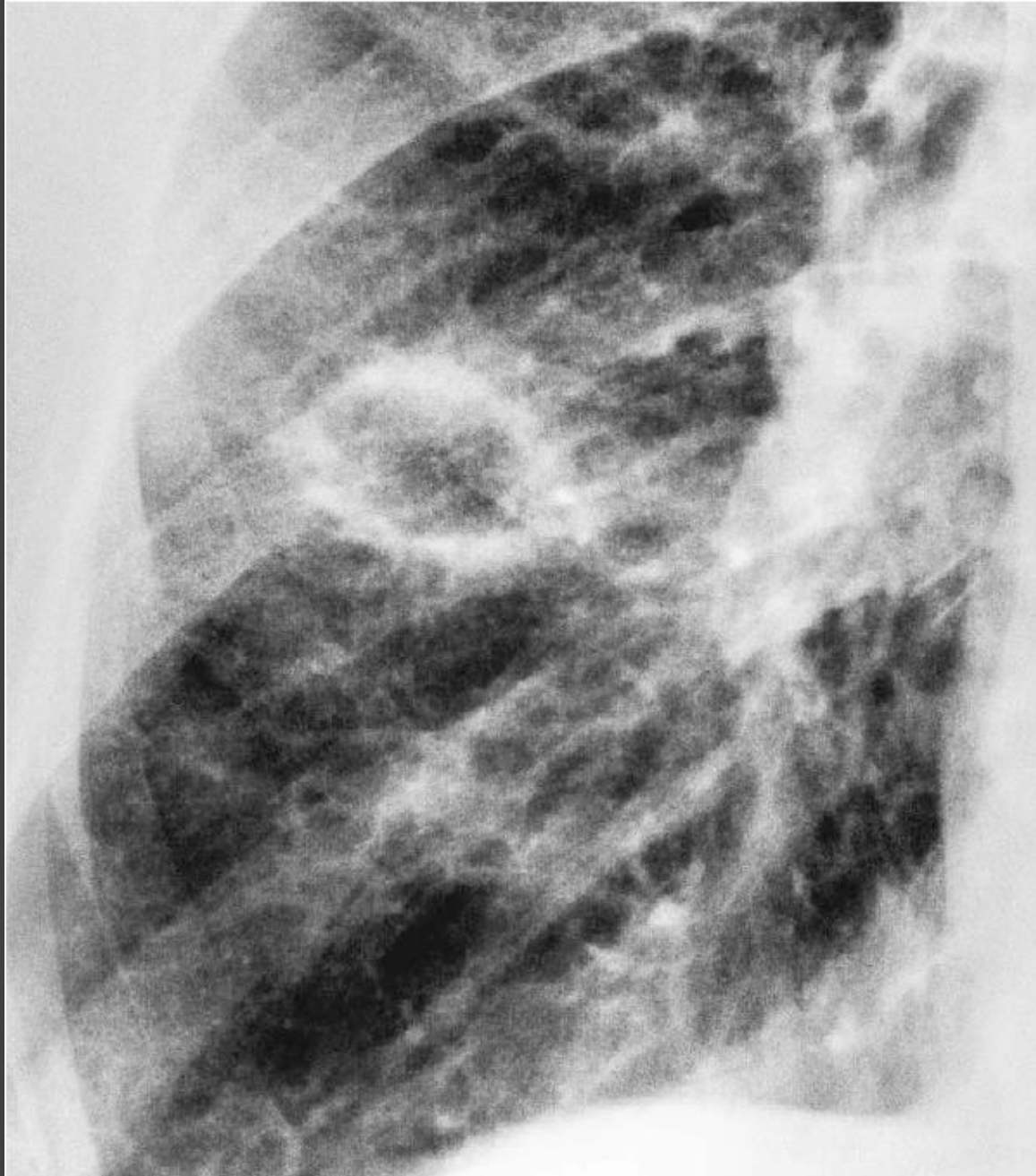

Fig. 13.10 Squamous cell carcinoma of bronchus showing a thin, uniform-thickness cavity wall.

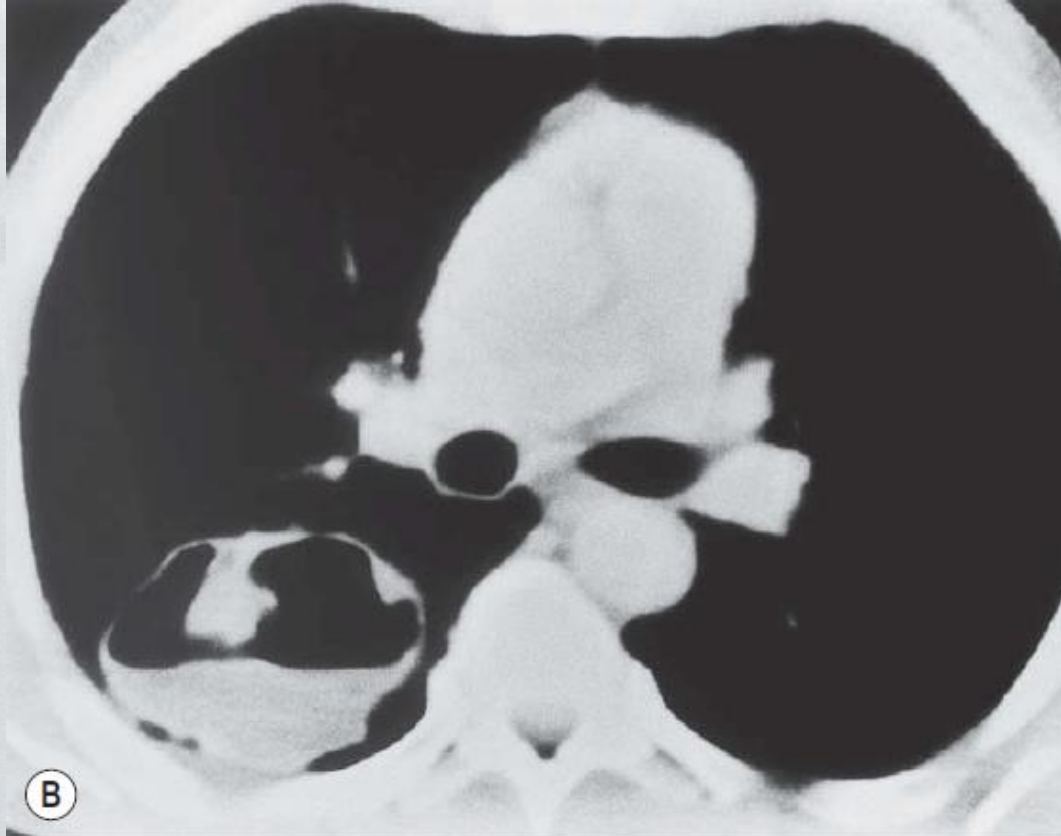
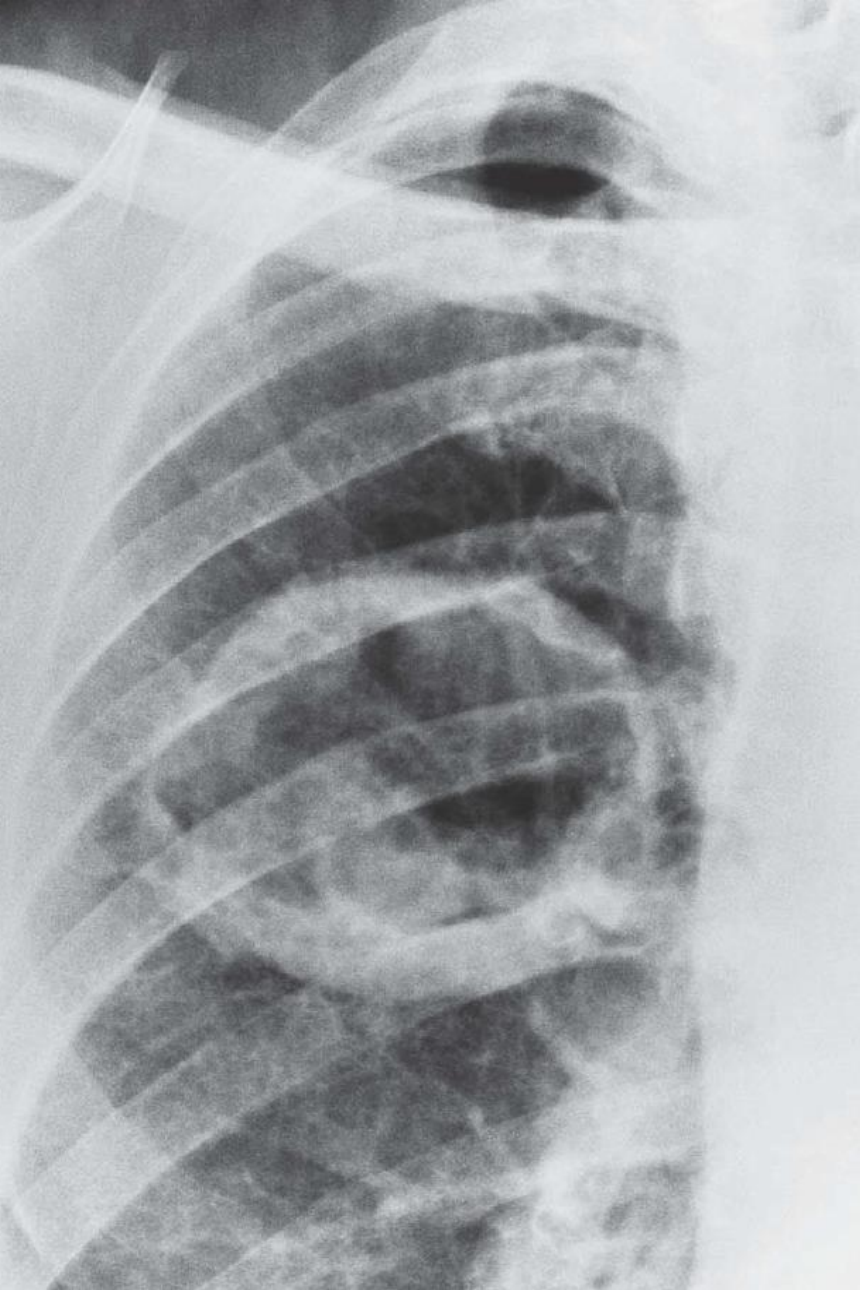
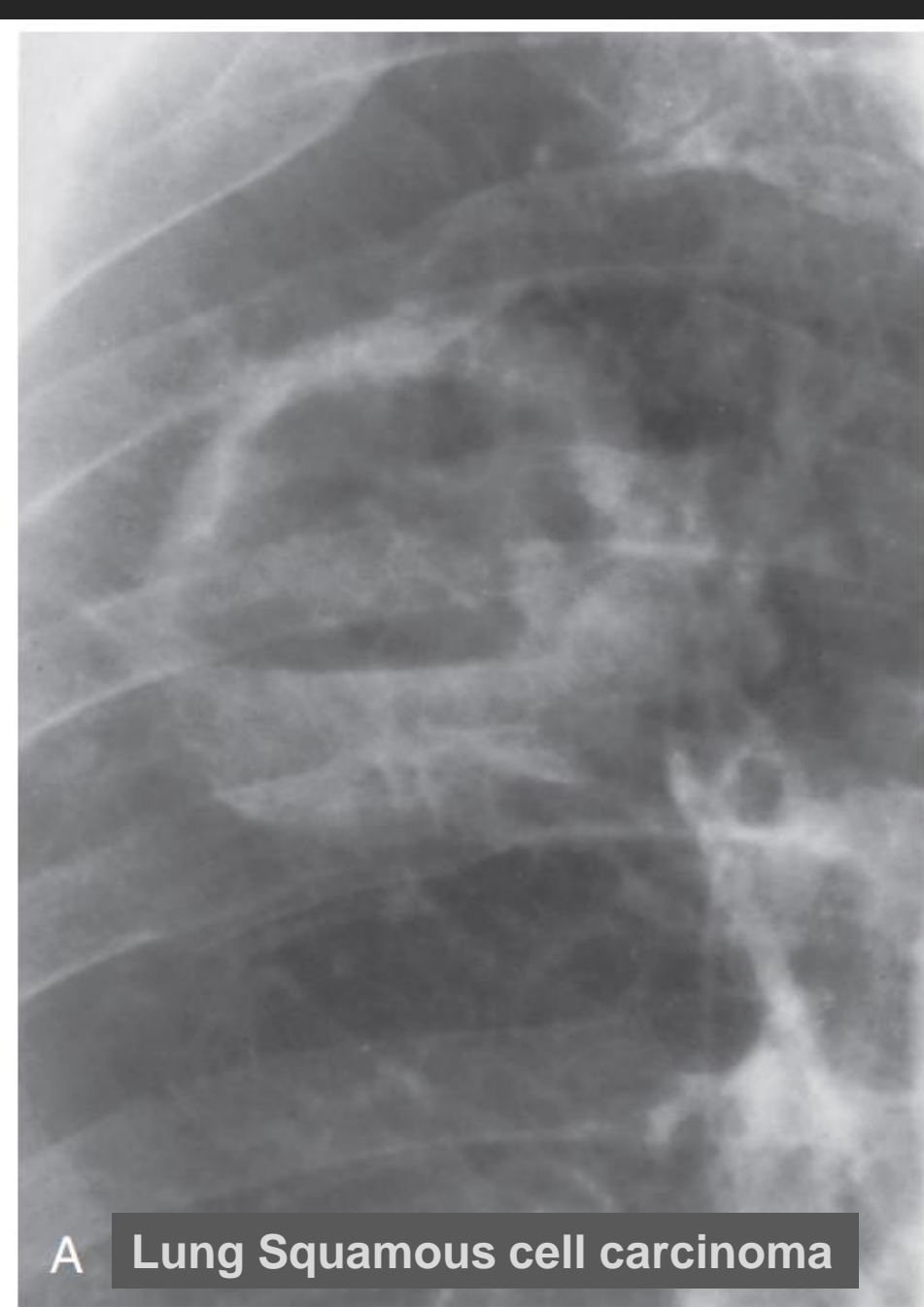
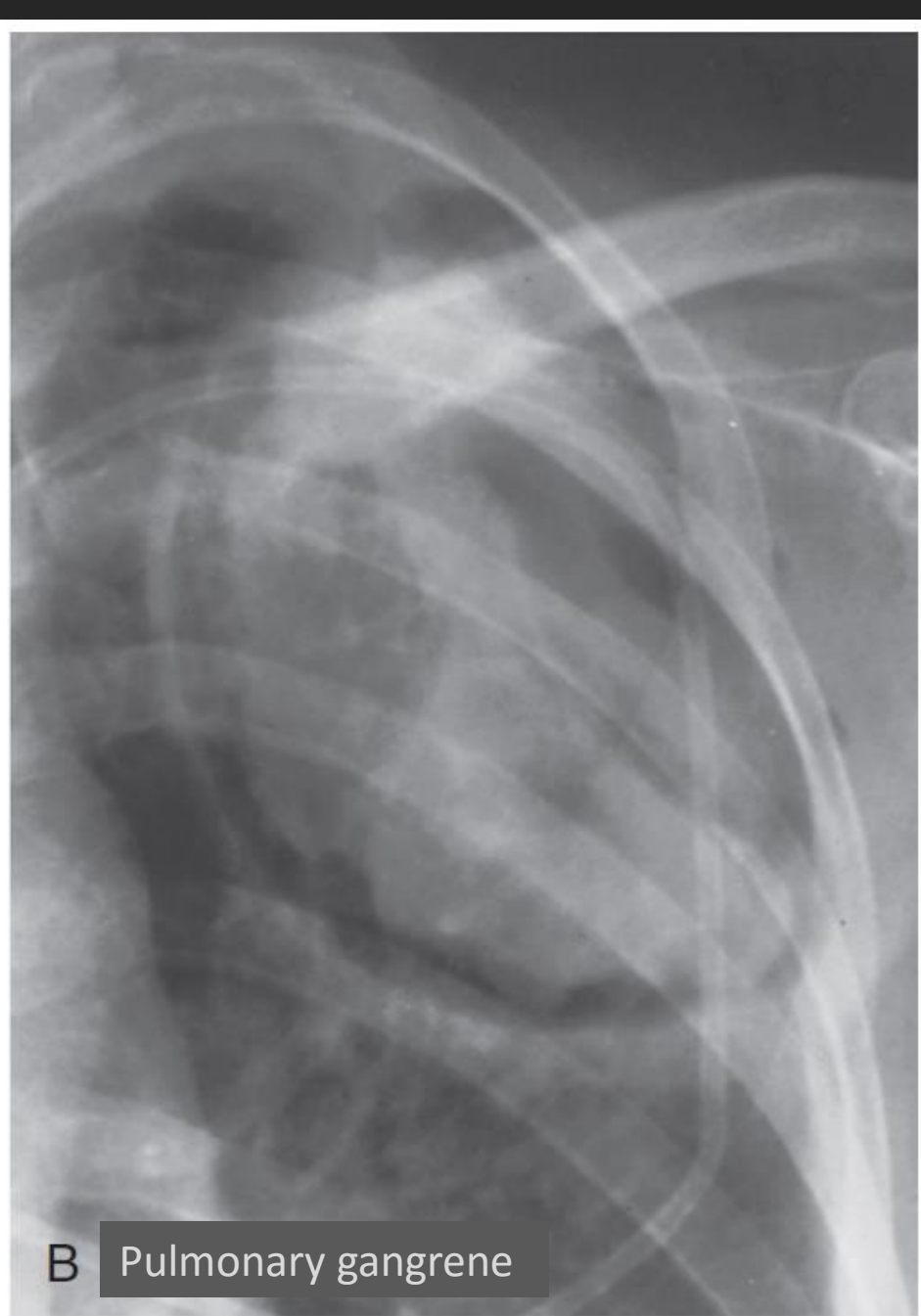
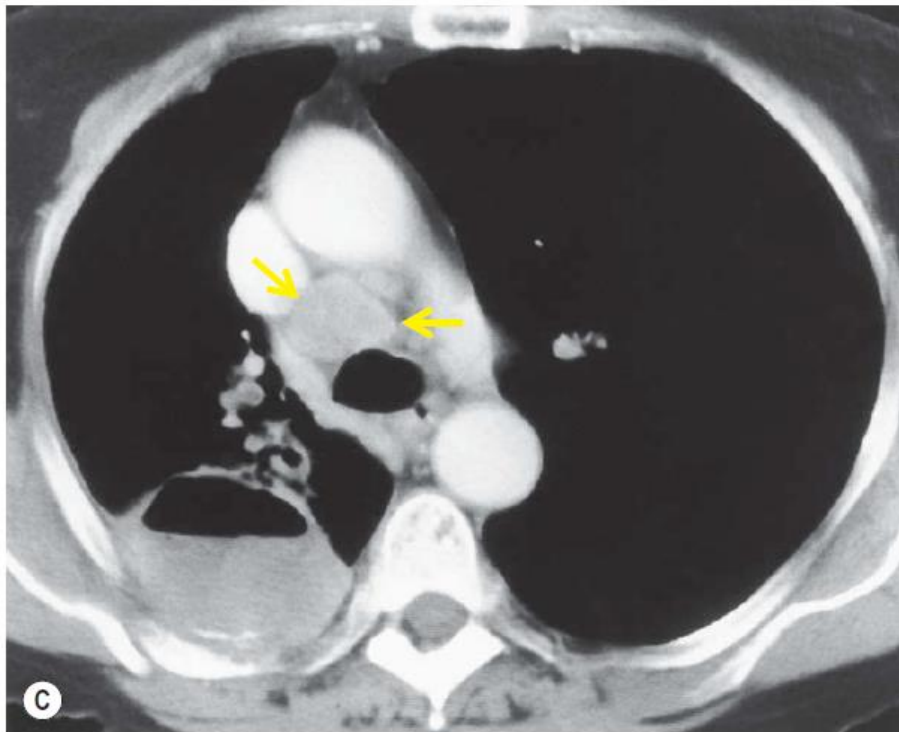
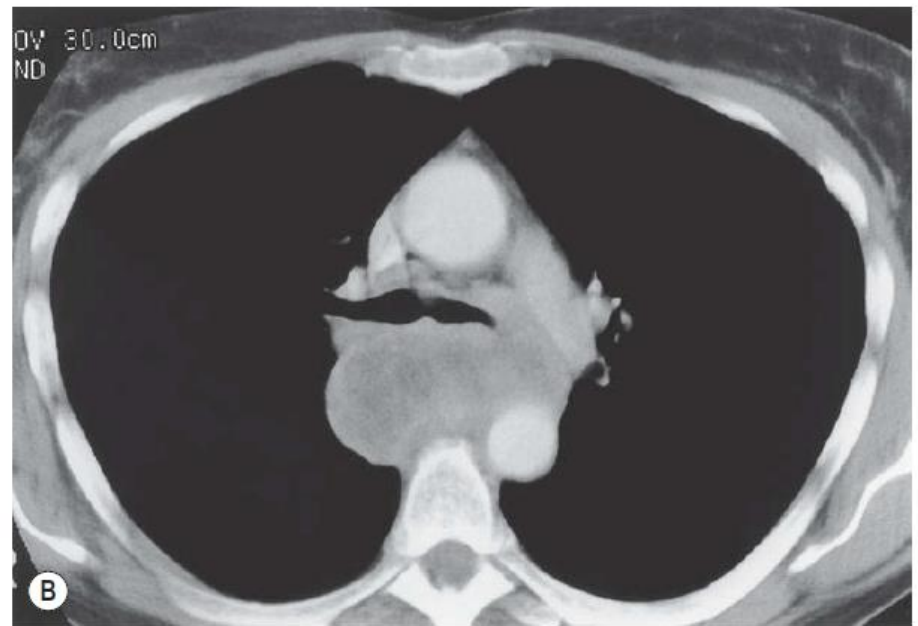
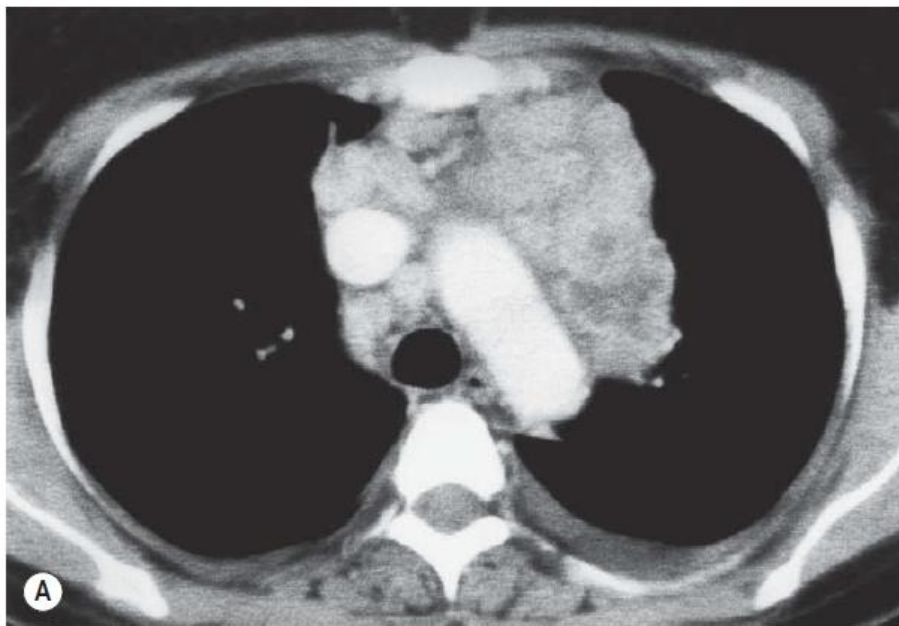
Fig. 13.9 Squamous cell carcinoma of bronchus showing cavitation. The cavity wall is of variable thickness and shows a mural nodule as well as an air-fluid level. **A**, Posteroanterior radiograph. **B**, CT.



A Lung Squamous cell carcinoma

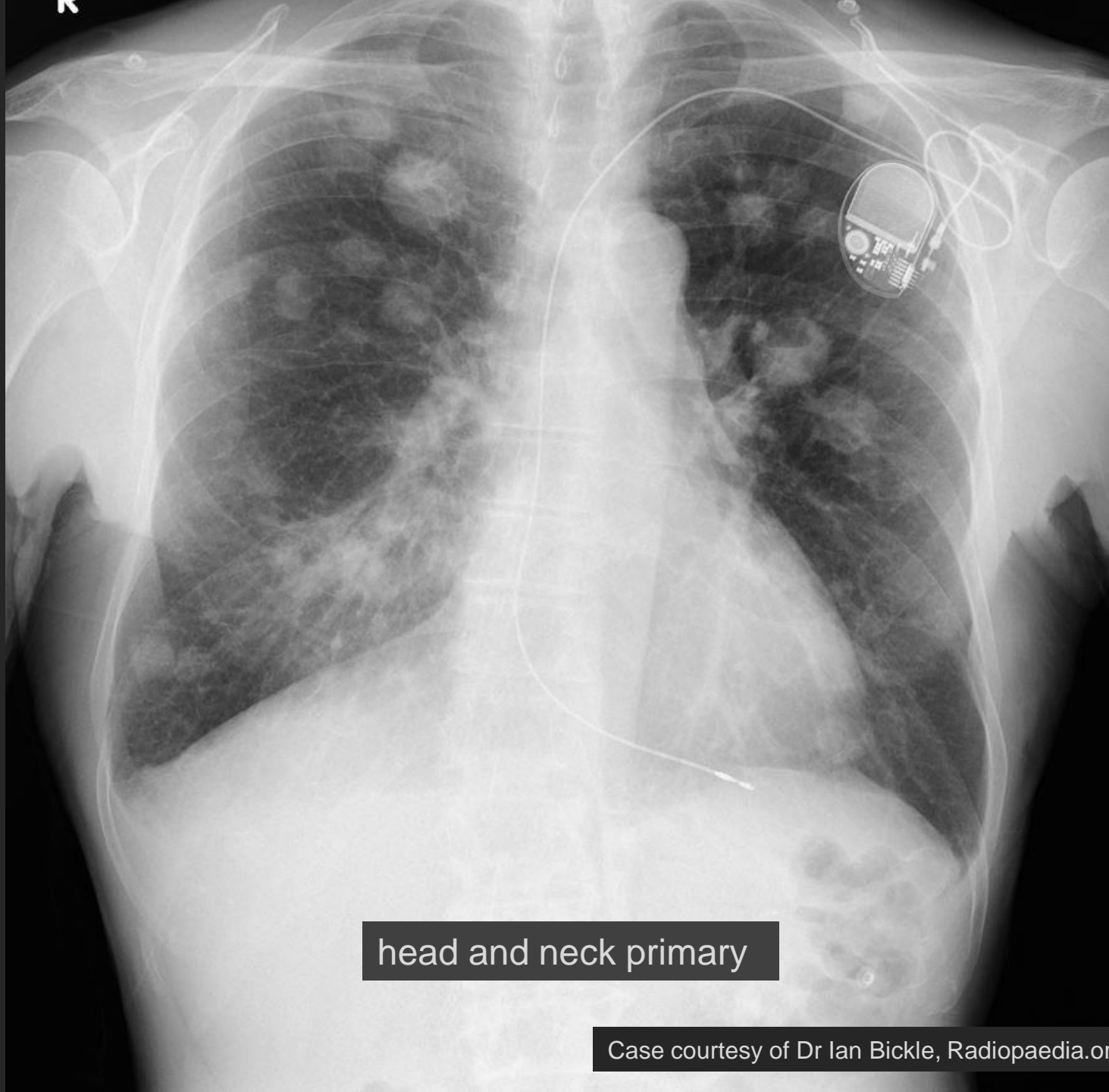


B Pulmonary gangrene



Hansell Imaging of Diseases of the Chest. 5th Ed

Fig. 13.33 CT of mediastinal lymph node enlargement caused by metastases from lung cancer. The enlarged nodes enhance to approximately the same degree as muscle following intravenous contrast enhancement. **A**, Massive multifocal lymphadenopathy. **B**, Matted massively enlarged subcarinal and lower paratracheal nodes. **C**, Greatly enlarged precarinal lymph node (arrows). Note also the chest wall involvement by the primary tumor – a thin-walled cavitating carcinoma.



head and neck primary

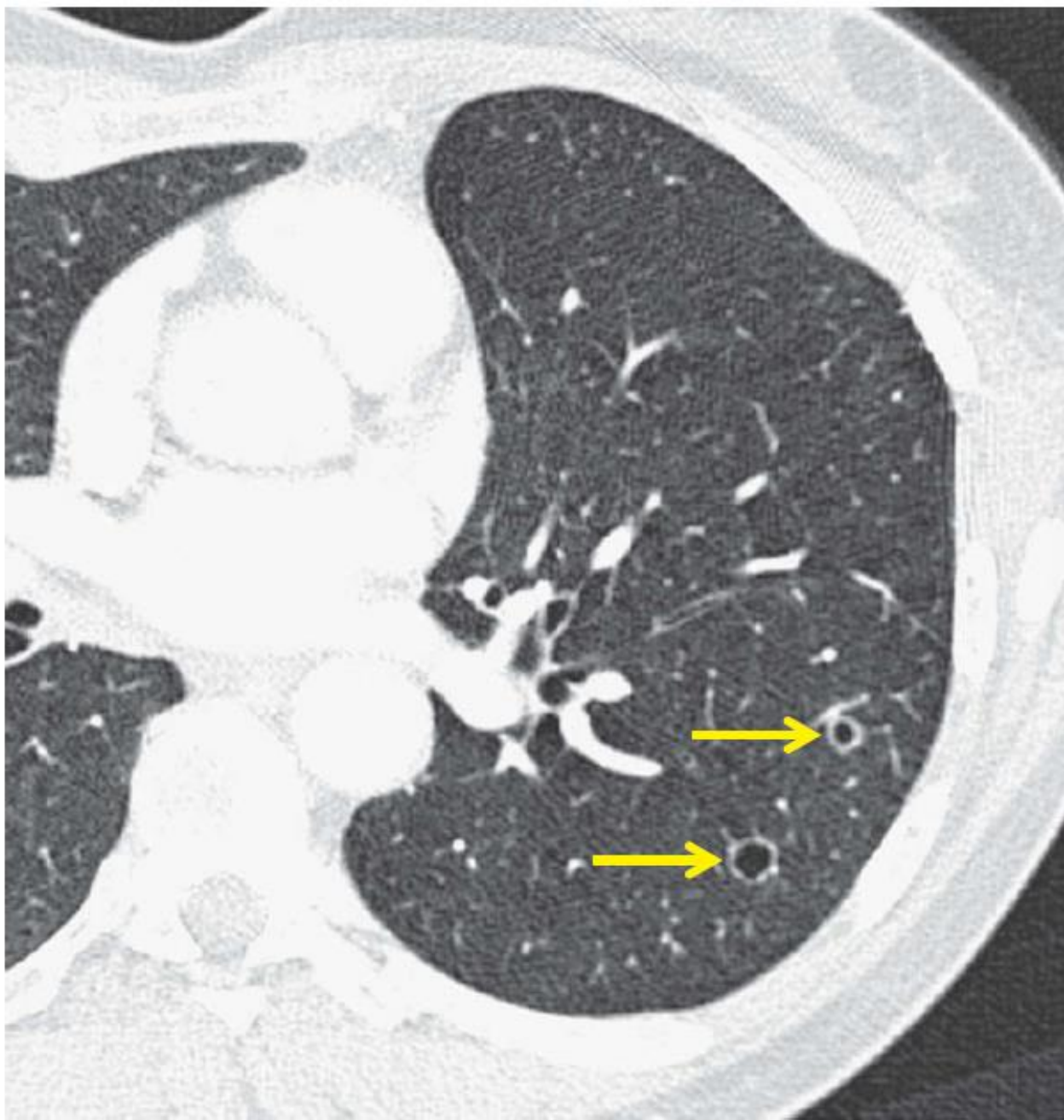
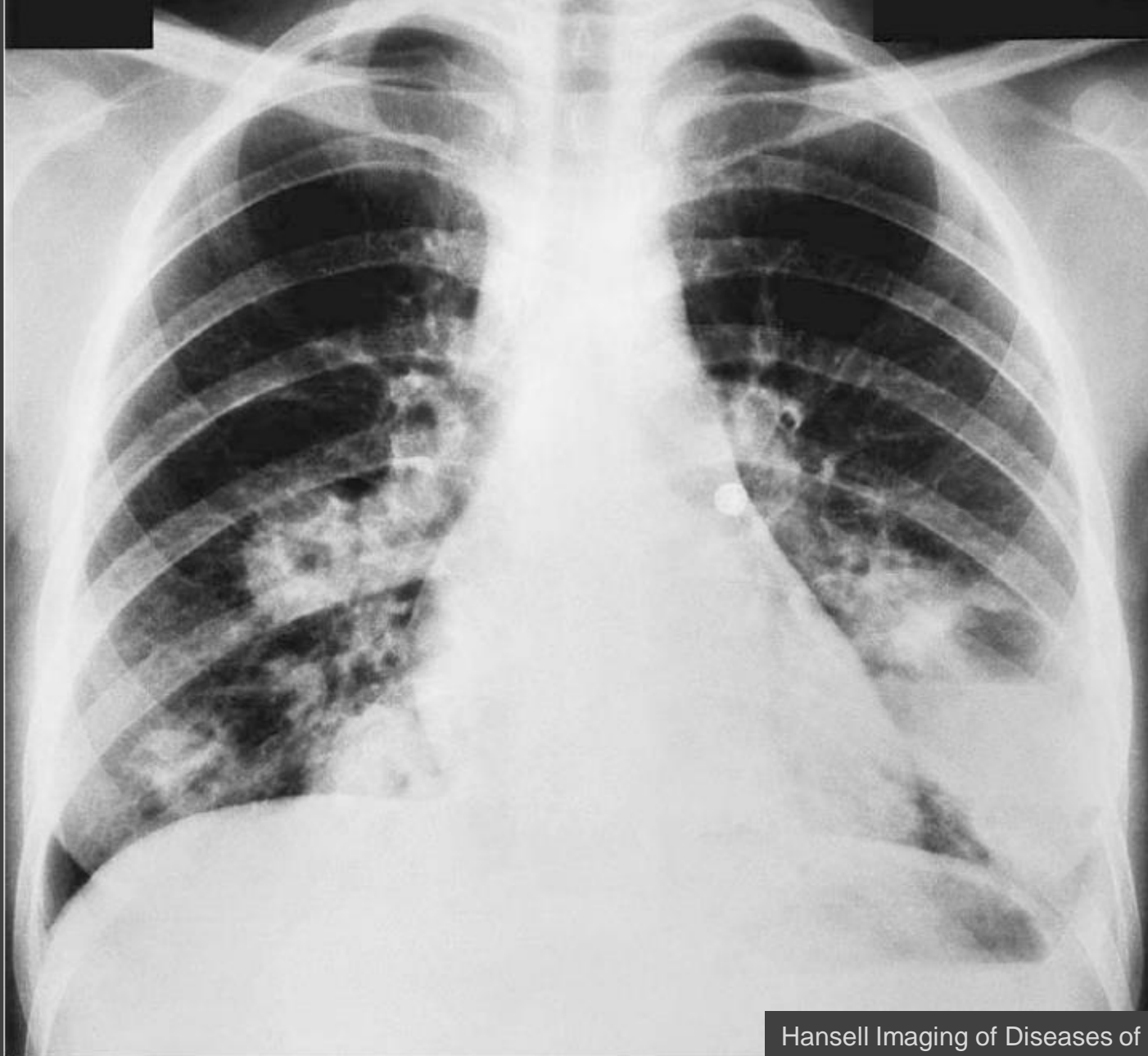


Fig. 13.107 CT of cavitating metastasis from squamous cell carcinoma (arrows).

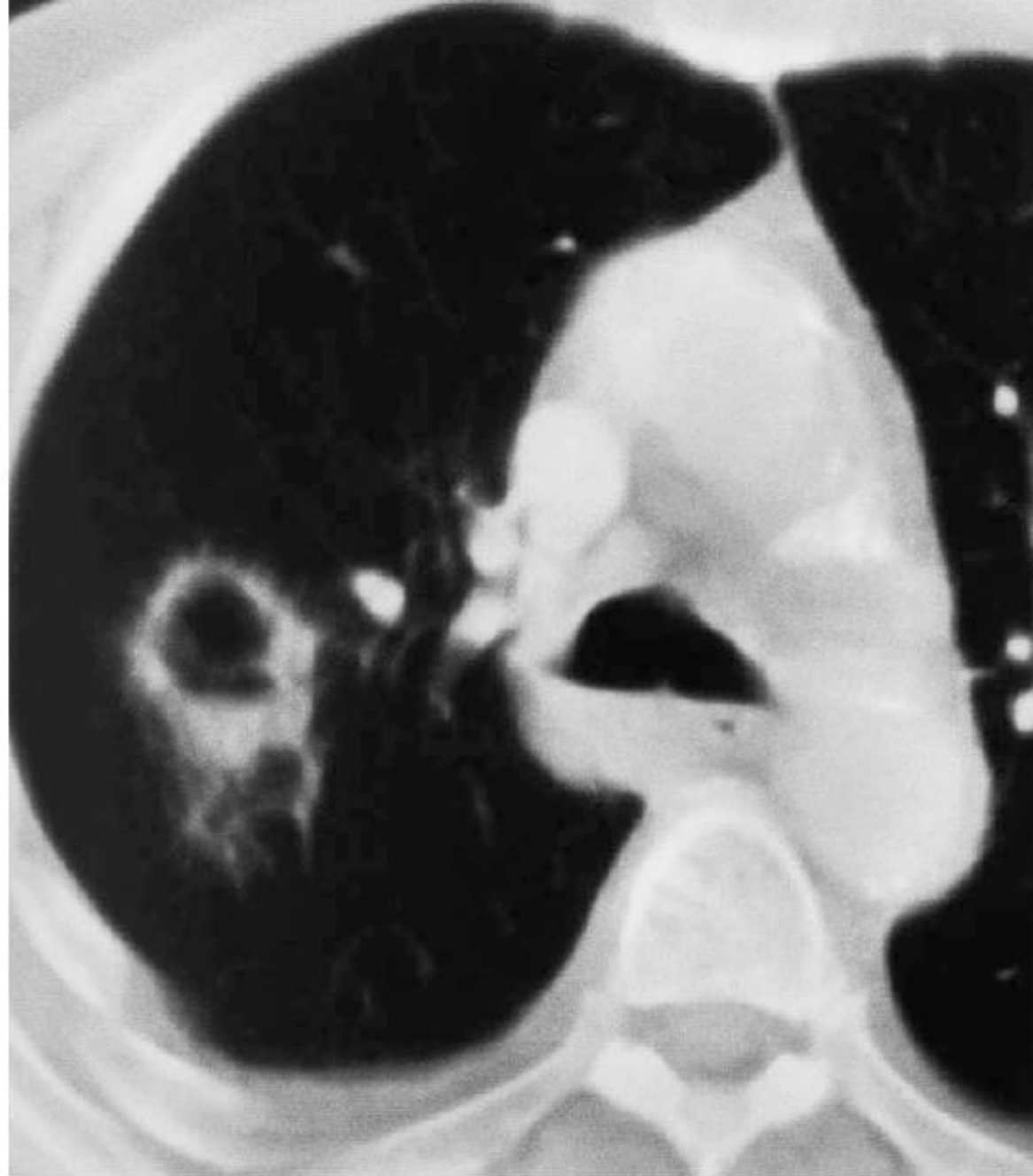

Fig. 13.108 Cavitating metastasis from adenocarcinoma of the colon showing a relatively thin wall.



Hansell Imaging of Diseases of the Chest. 5th Ed

Fig. 13.82 Hodgkin lymphoma showing multiple cavitating pulmonary nodules (and right paratracheal nodal enlargement).

■ C: cancer

- Primary bronchogenic carcinoma: most frequently SCC
- Pulmonary metastasis: most frequently SCC, also adenocarcinoma, sarcoma

■ A: autoimmune;

- Wegener Granulomatosis, rheumatoid arthritis (rheumatoid nodules) etc.

■ V: vascular (both bland and septic pulmonary emboli)

■ I: infection (bacterial/fungal) / inhalation

- pulmonary abscess
- fungal / parasite infection
- pulmonary tuberculosis
- pneumoconiosis

■ T: trauma - pneumatoceles

■ Y: youth

- CPAM (congenital pulmonary airway malformation)
- pulmonary sequestration
- bronchogenic cyst

Wegener Granulomatosis

- Granulomatosis with polyangiitis (GPA)
- **c-ANCA** positive vasculitis affecting small to medium-sized arteries, capillaries and veins
- The classic triad of organ involvement consists of:
 - lungs: involved in 95% of cases
 - upper respiratory tract / sinuses: 75-90%
 - kidneys: 80%

Wegener Granulomatosis

■ Lung parenchymal change

□ Single or **multiple pulmonary nodules**/masses: multiple多(75%)

- 最常見的表現
- Size: 1~10cm; number: 大多<10
- Ill-defined or irregular margined, no zonal predominance
- **50%會開洞**，通常是**irregular, thick walled**
- 少: pleural effusion(<10%), mediastinal/hilar LAP
- 經過治療之後，這些nodules or cavities會消失或是留下scar
- CT scan : nodules with irregular margin，沿著peribronchovascular分布

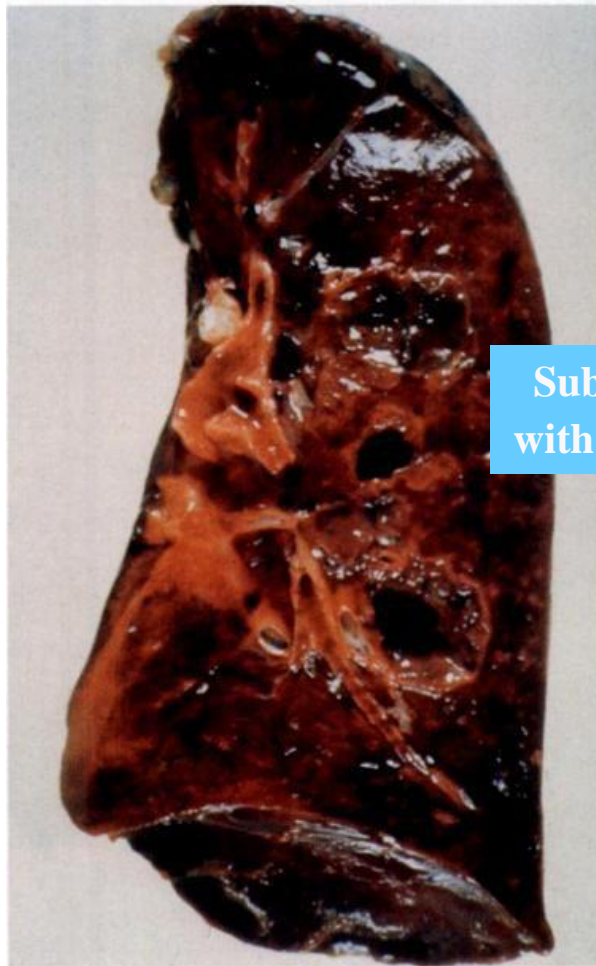□ Localized or diffuse consolidation / GGO

- 通常代表pulmonary hemorrhage, secondary infection, alveolitis
- A focal area of dense consolidation, patchy bilateral areas of consolidation, or diffuse air-space consolidation

■ Airway narrowing:

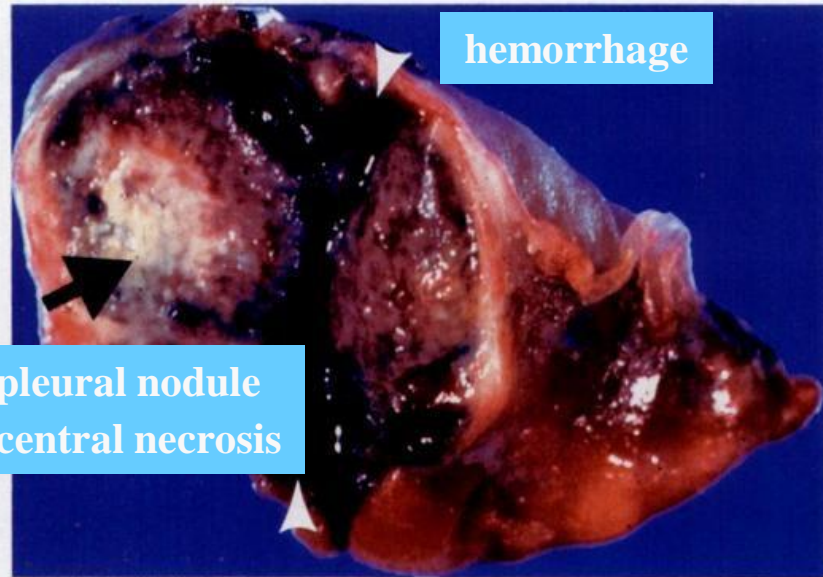
□ Subglottic stenosis of trachea: 最常見

Wegener Granulomatosis



1a.

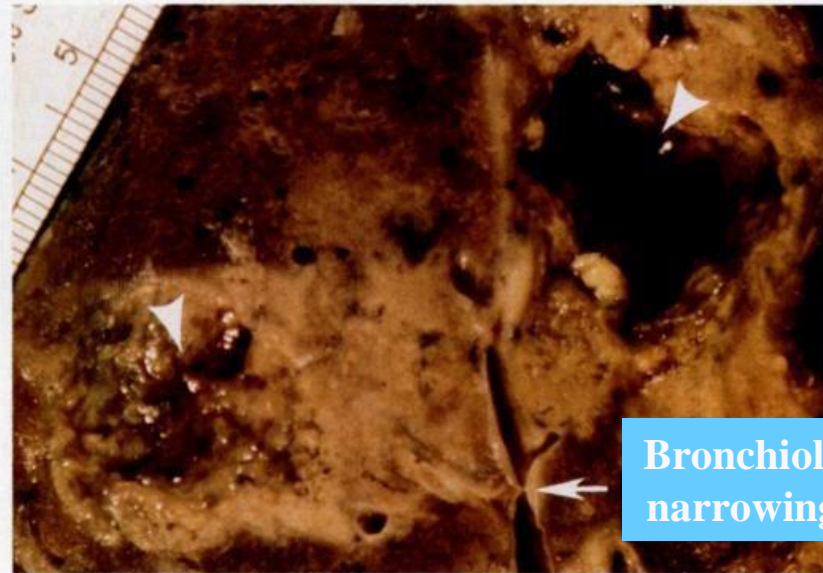
Multiple cavitary and
necrotic nodules



hemorrhage

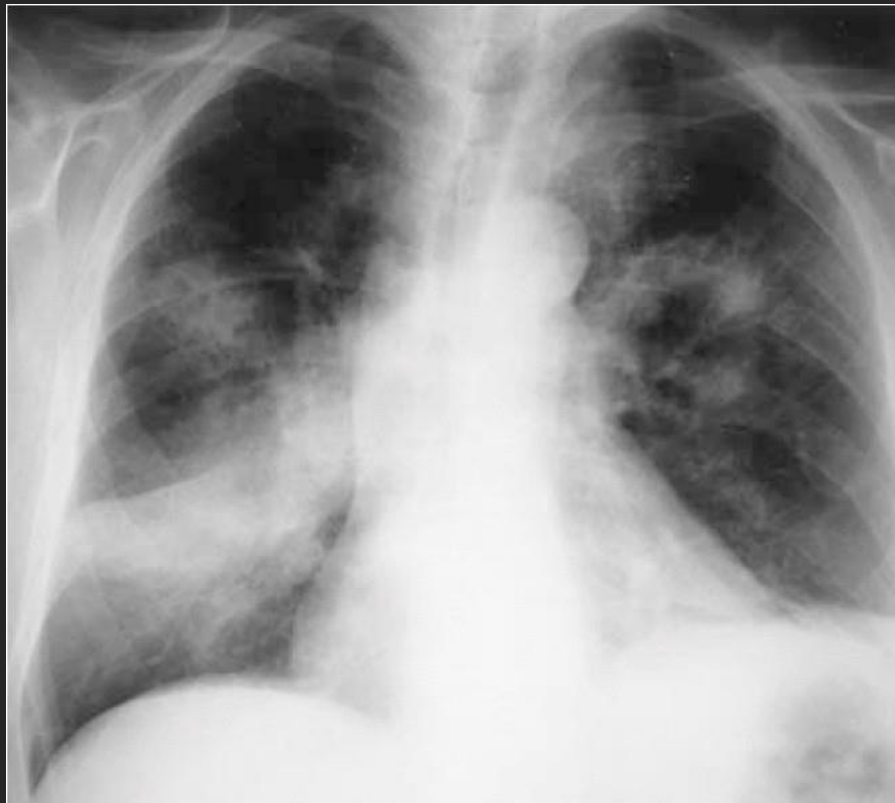Subpleural nodule
with central necrosis

1b.

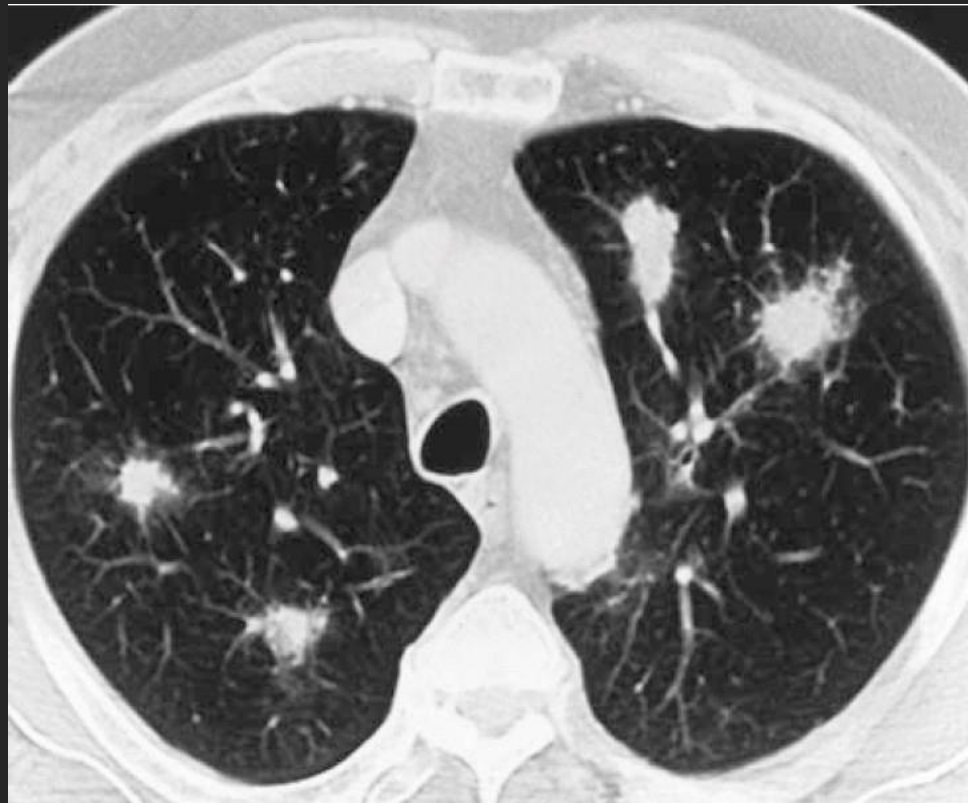

Bronchiole
narrowing

Wegener Granulomatosis



bilateral irregular nodules and a mass in the right lower lobe



multiple irregular nodules in a **peribronchovascular** distribution

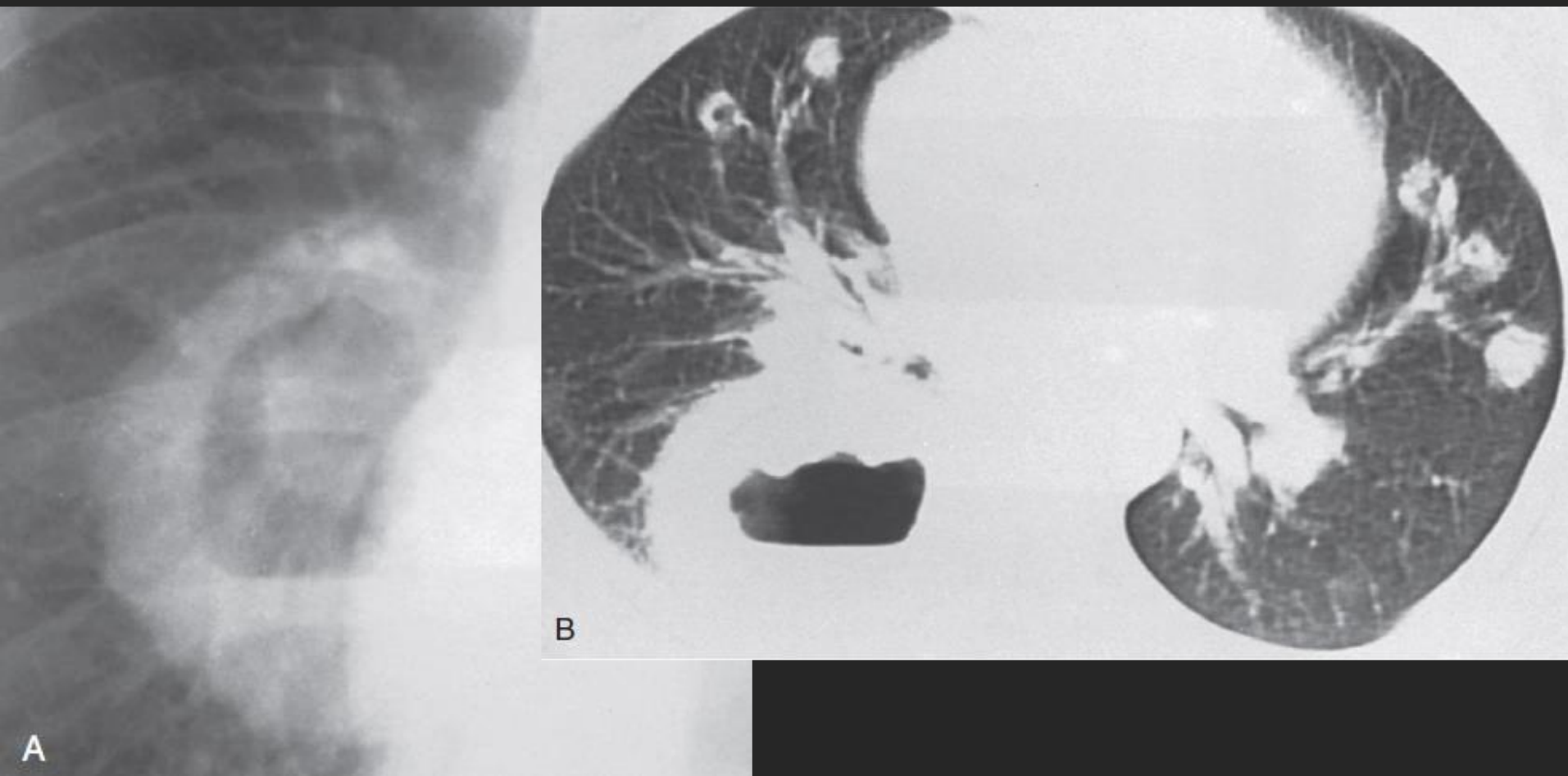
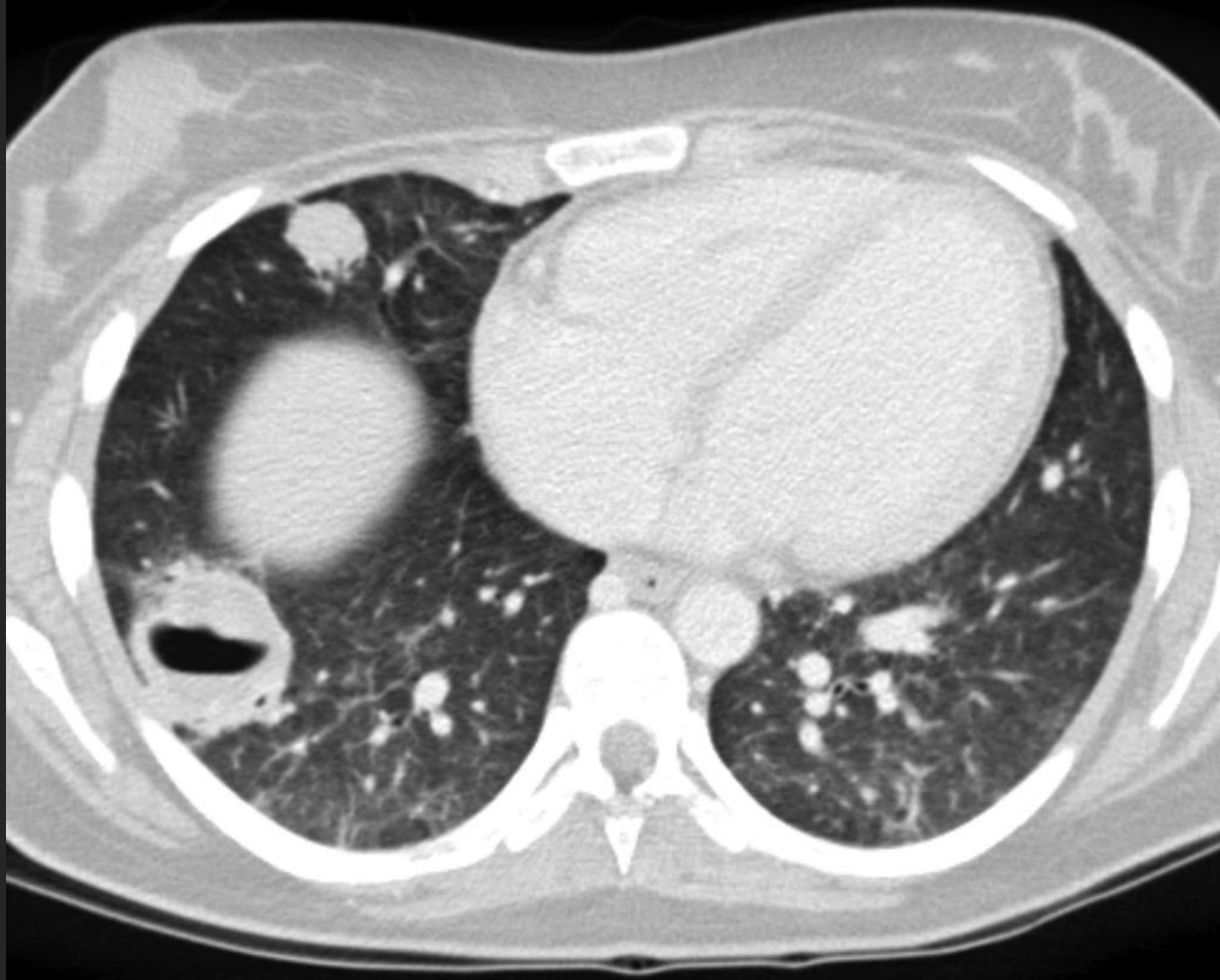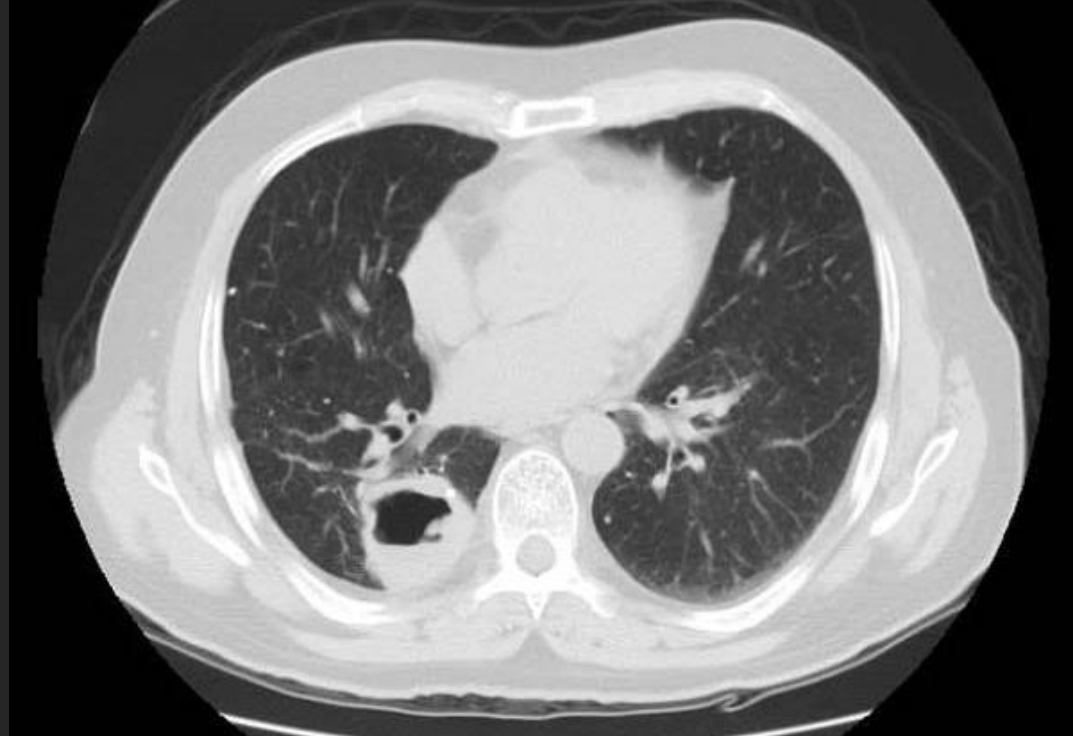

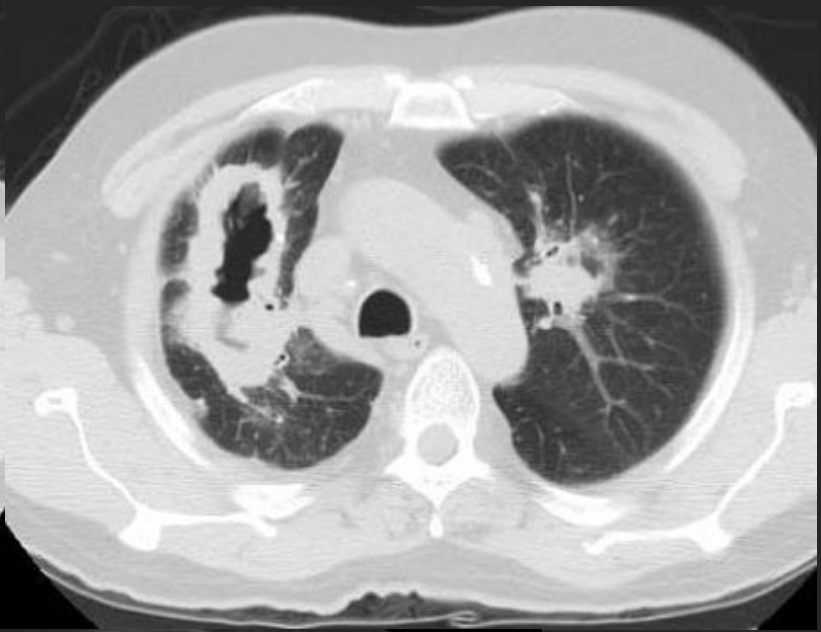
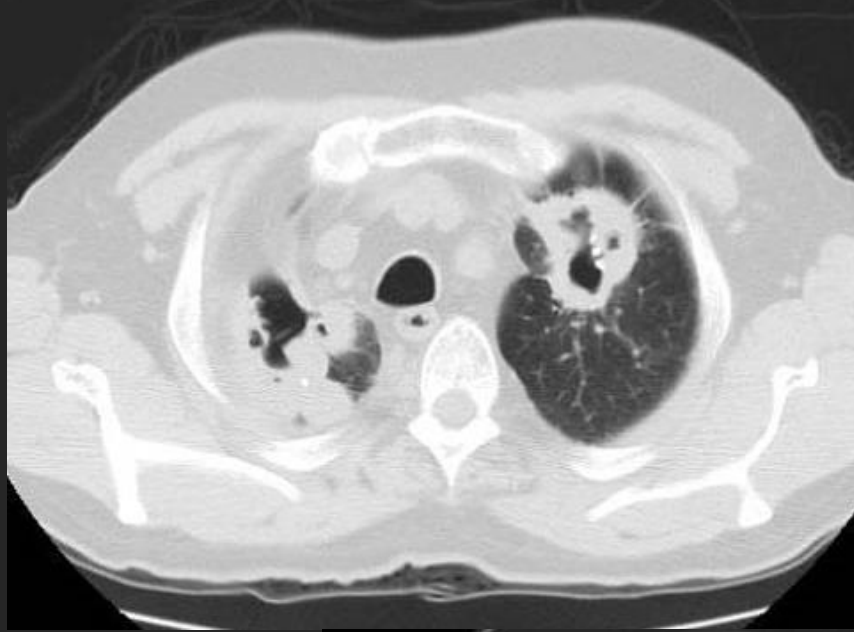Figure 24-9 **A**, Wegener's granulomatosis is the cause of this large, thick-walled cavity with an air-fluid level. Additional nodules are minimally visible on the plain film. **B**, CT of the same patient shows additional nodules, some of which are cavitary. This appearance of multiple cavitary nodules with a large, dominant cavity is more typical of Wegener's than a solitary cavity would be.





Rheumatoid Arthritis

- Pleural Disease
- Pulmonary fibrosis
- **Pulmonary nodules**
 - Uncommon; pathology identical to subcutaneous nodules
 - Usually associated **with advanced disease** and **subcutaneous nodules**.
 - Usually **multiple and well circumscribed**, they often result in thick-walled cavities.
- Airway diseases
- Bone change

Box 10.21 Pleuropulmonary lesions in rheumatoid disease

- Pleural
 - Pleuritis
 - Effusion
 - Pleural thickening
 - Necrobiotic nodule
 - Empyema
 - Pneumothorax/bronchopleural fistula
- Interstitial pneumonia
 - NSIP
 - UIP
 - Organizing pneumonia
 - LIP
 - Upper lobe fibrosis
- Nodule
 - Necrobiotic nodules
 - Caplan syndrome
 - Lymphoid hyperplasia
- Pulmonary hypertension
- Airway disease
 - Bronchitis
 - Bronchiectasis
 - Bronchiolitis: obliterative bronchiolitis; follicular bronchiolitis
- Drug-related disease
- Amyloidosis
- Lung cancer

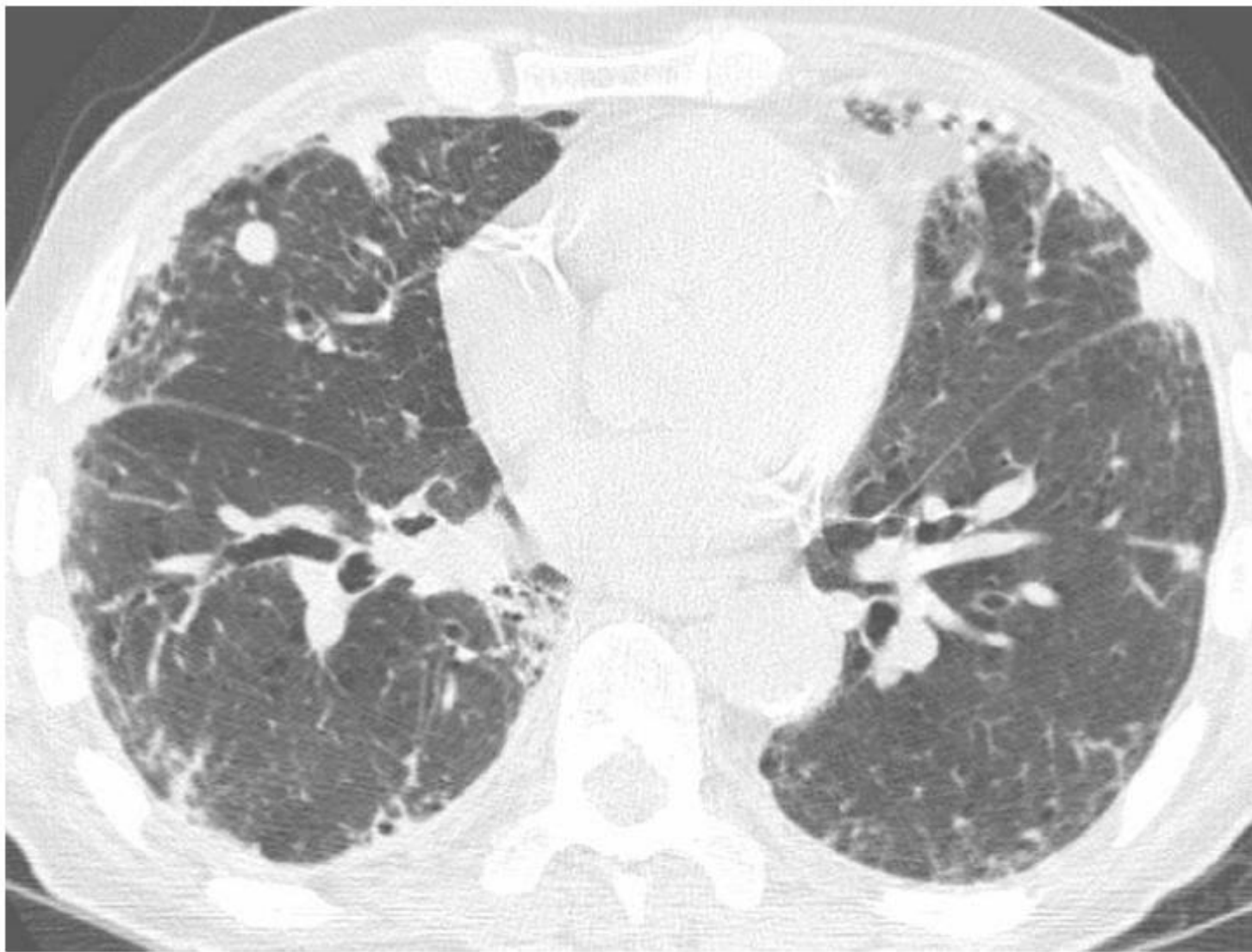


Fig. 10.33 Lung nodules in rheumatoid arthritis. CT shows a well-defined nodule in the right middle lobe, likely a rheumatoid nodule, and several triangular subpleural nodules which may represent lymphoid hyperplasia. All were stable on follow-up. There is a background UIP pattern.

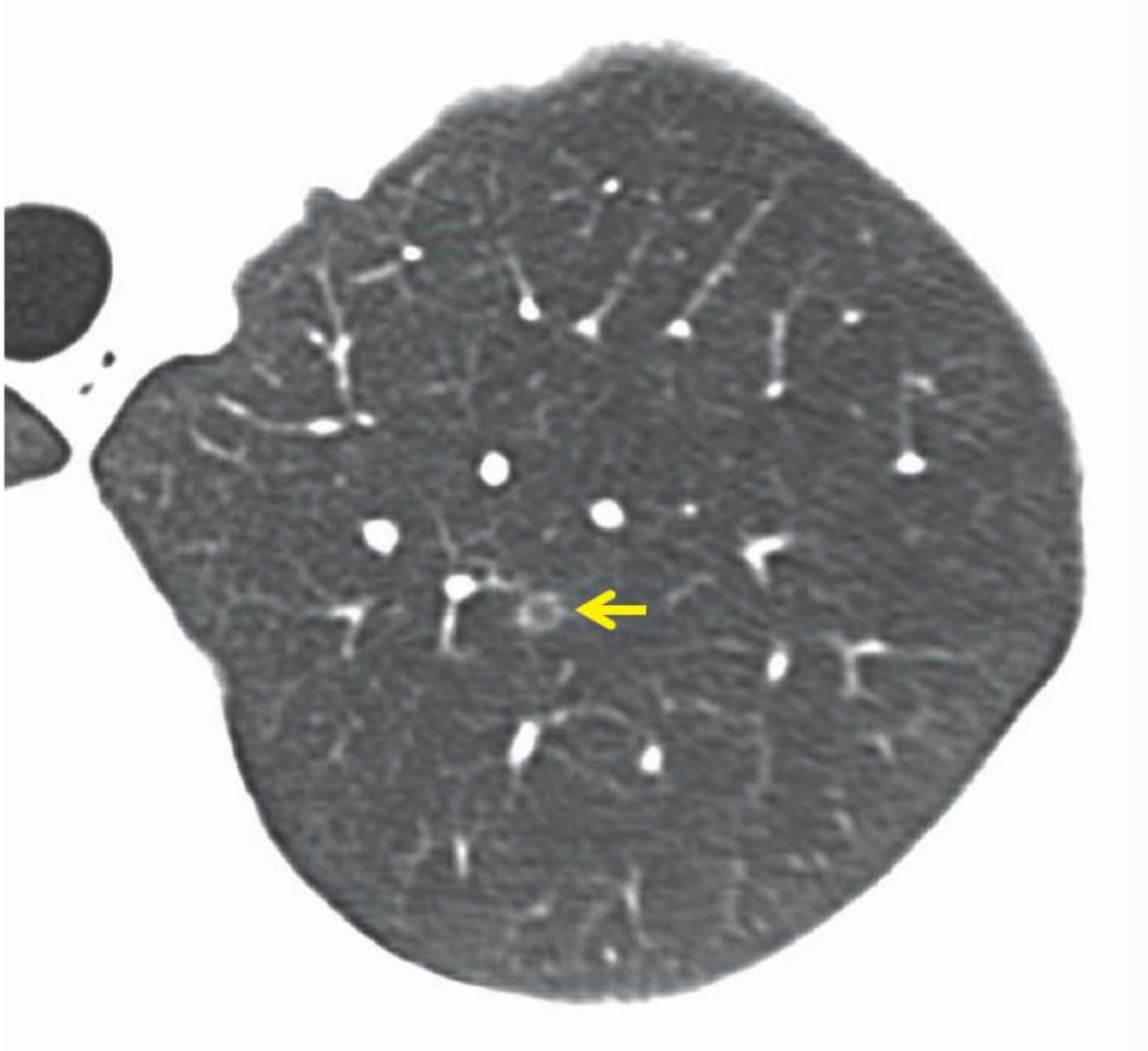


Fig. 10.34 Cavitory rheumatoid nodule. CT through the left upper lobe shows a small thin-walled cavitary nodule (arrow), which resolved on follow-up.

■ C: cancer

- Primary bronchogenic carcinoma: most frequently SCC
- Pulmonary metastasis: most frequently SCC, also adenocarcinoma, sarcoma

■ A: autoimmune;

- Wegener Granulomatosis, rheumatoid arthritis (rheumatoid nodules) etc.

■ V: vascular (both bland and septic pulmonary emboli)

■ I: infection (bacterial/fungal) / inhalation

- pulmonary abscess
- fungal / parasite infection
- pulmonary tuberculosis
- pneumoconiosis

■ T: trauma - pneumatoceles

■ Y: youth

- CPAM (congenital pulmonary airway malformation)
- pulmonary sequestration
- bronchogenic cyst

Vascular Lesions

- 大多為multiple
- **Wegener granulomatosis & rheumatoid nodules:**
 - 為CVD中兩者最常發生開洞
- **Pulmonary infarction:**
 - Occur in area of **infarction > 4cm** in diameter and happen **2 weeks** after appearance of the consolidation.
- **Septic emboli**
 - Search for the infectious source

Septic Emboli

■ Risk factors:

- IV drug abuser (septic phlebitis, IE), alcoholism, skin infection, venous catheter,
- Immunocompromised patient, esp. lymphoma and organ transplant

■ Most common pathogen:

- staphylococcus

■ Best diagnostic clues:

- Multiple, bilateral patchy areas of **consolidation** with rapid evolving into ill-defined **cavitary nodules**
 - Air-bronchogram (25%)
 - **Rapid cavitation**, often thick-walled
 - 有時會呈wedge-shapes
- Mainly over **lung bases** and **subpleural** location, due to hematogenous spreading

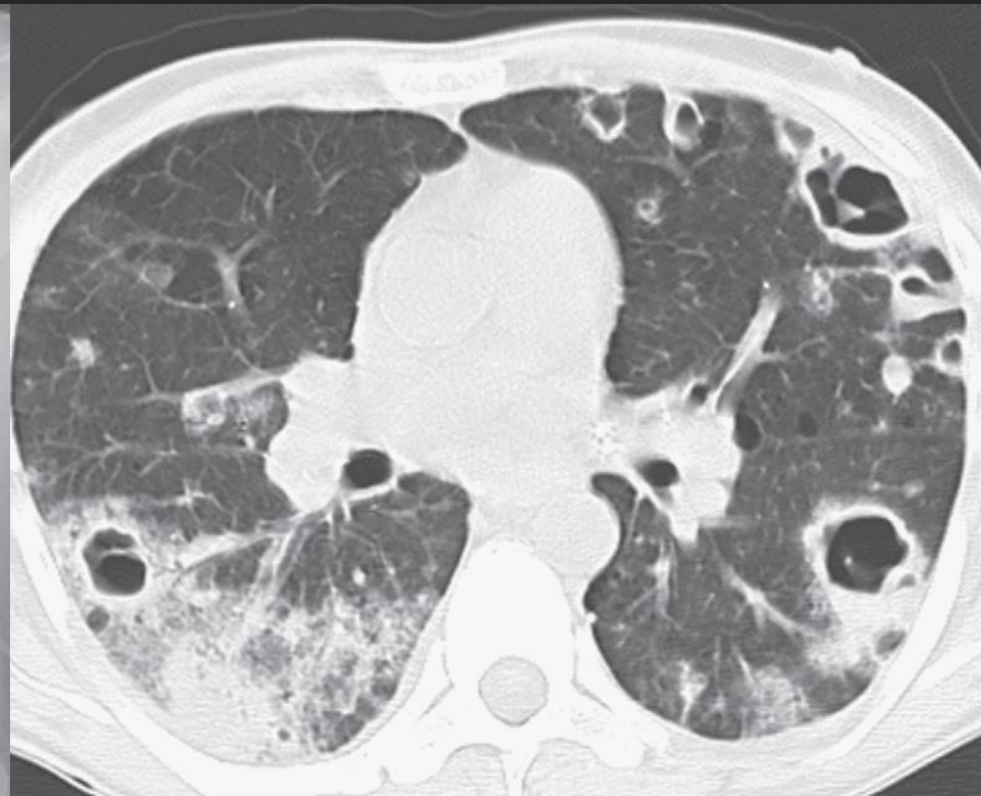
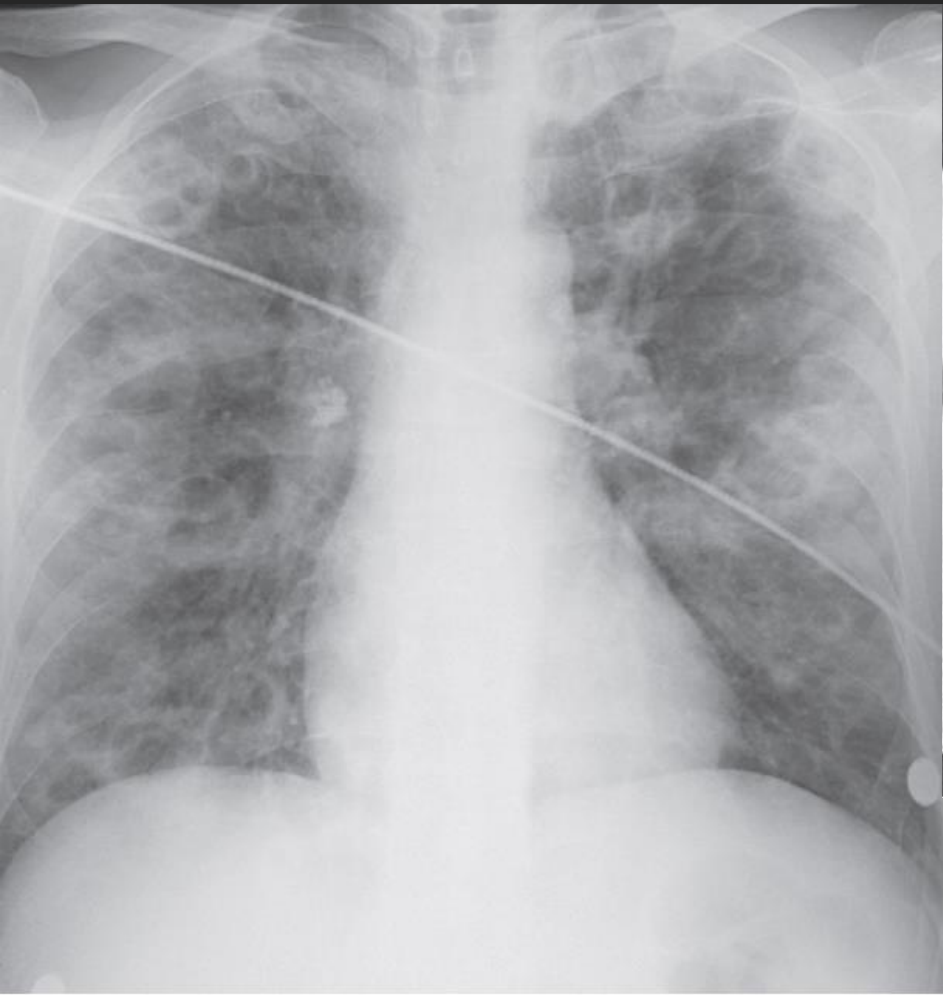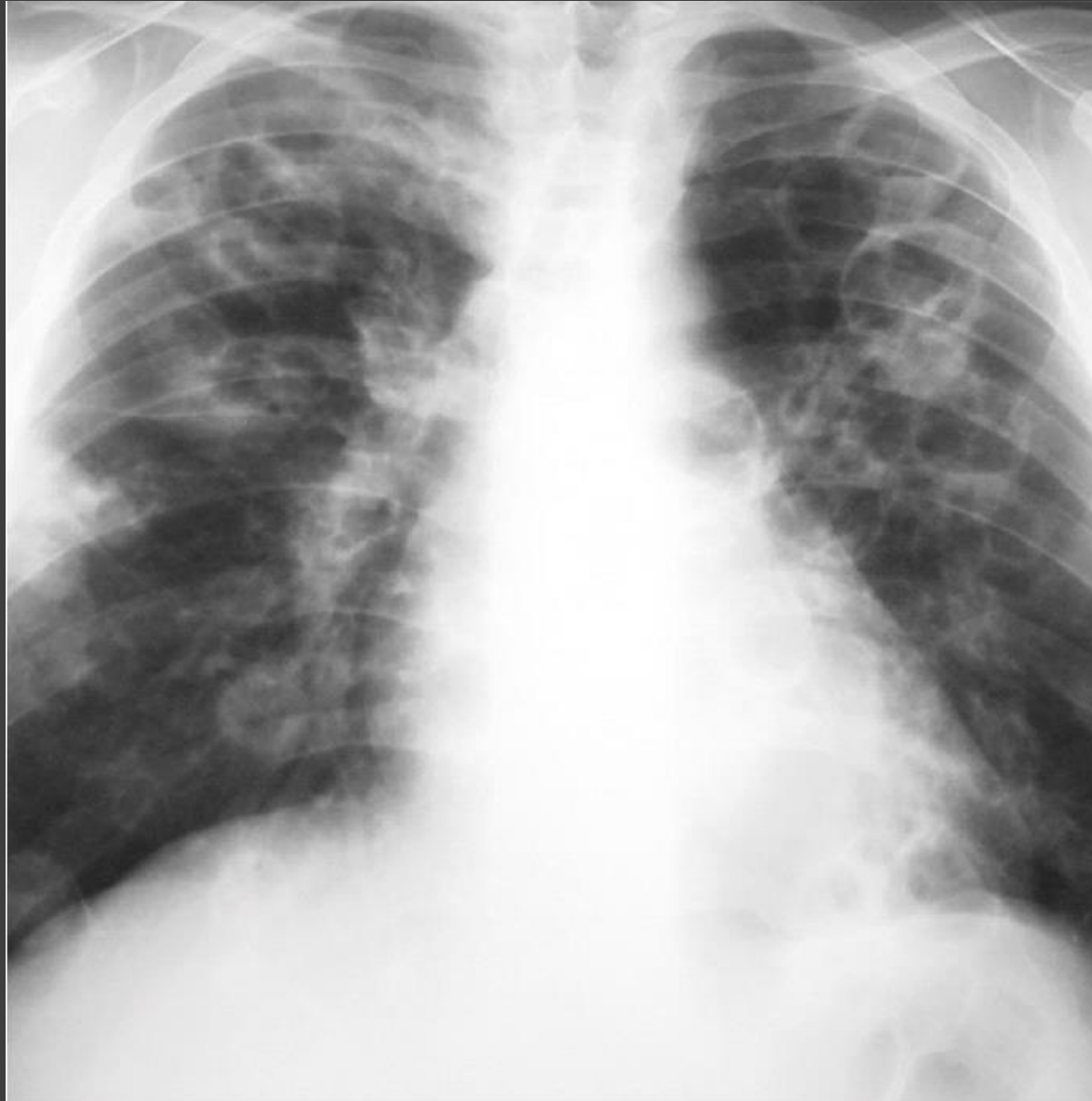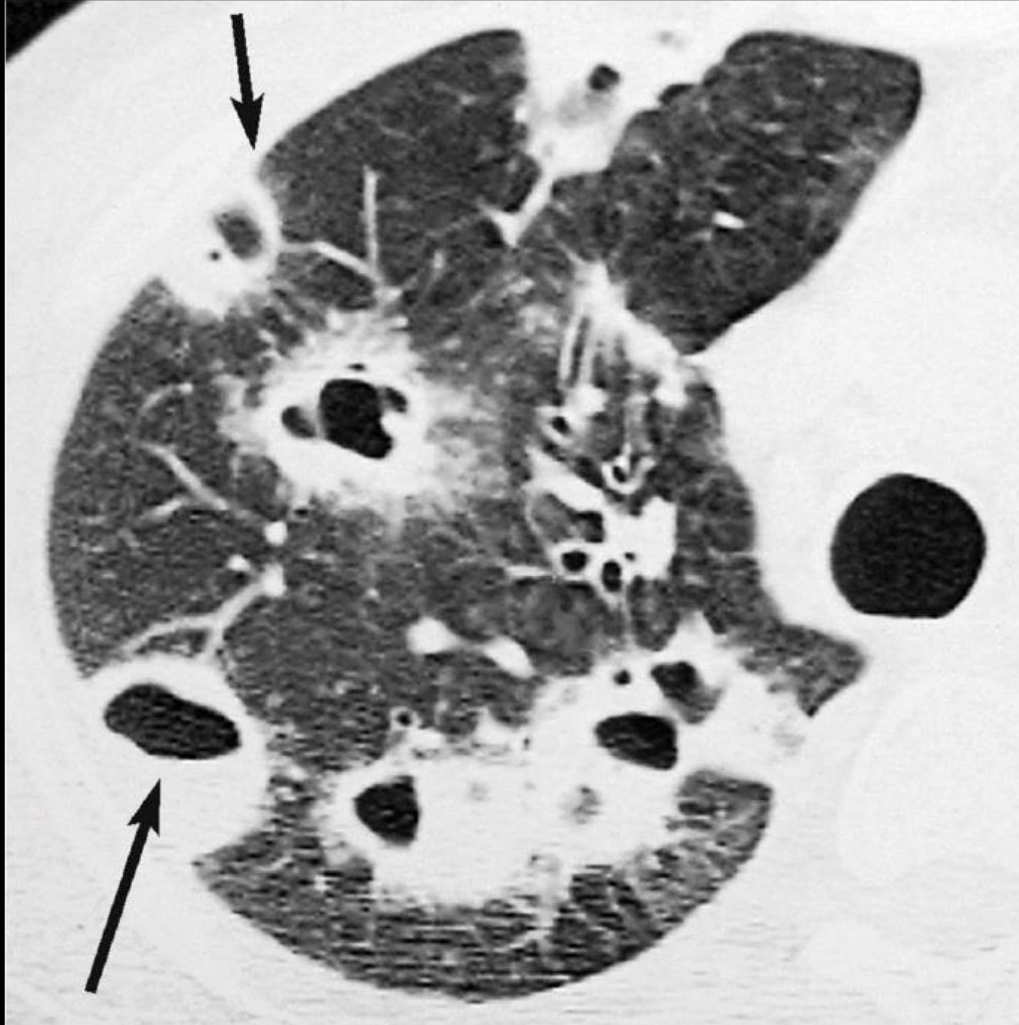


Figure 24-7 **A**, Numerous bilateral cavities are scattered throughout the lungs. **B**, CT reveals the cavities to have a peripheral distribution and vary in size. There is some surrounding air-space consolidation and ground-glass opacity in the superior segment of the right lower lobe. This is the result of MRSA septic emboli from an infected dialysis catheter.

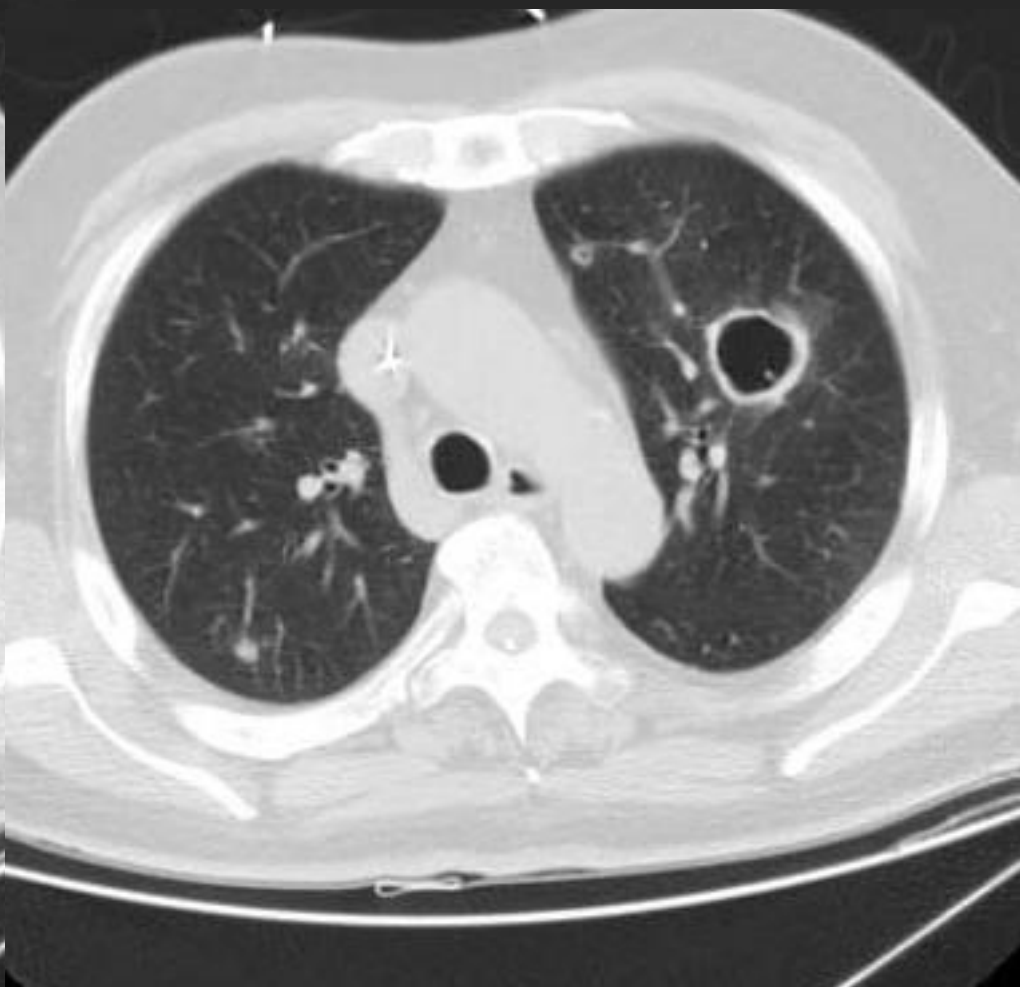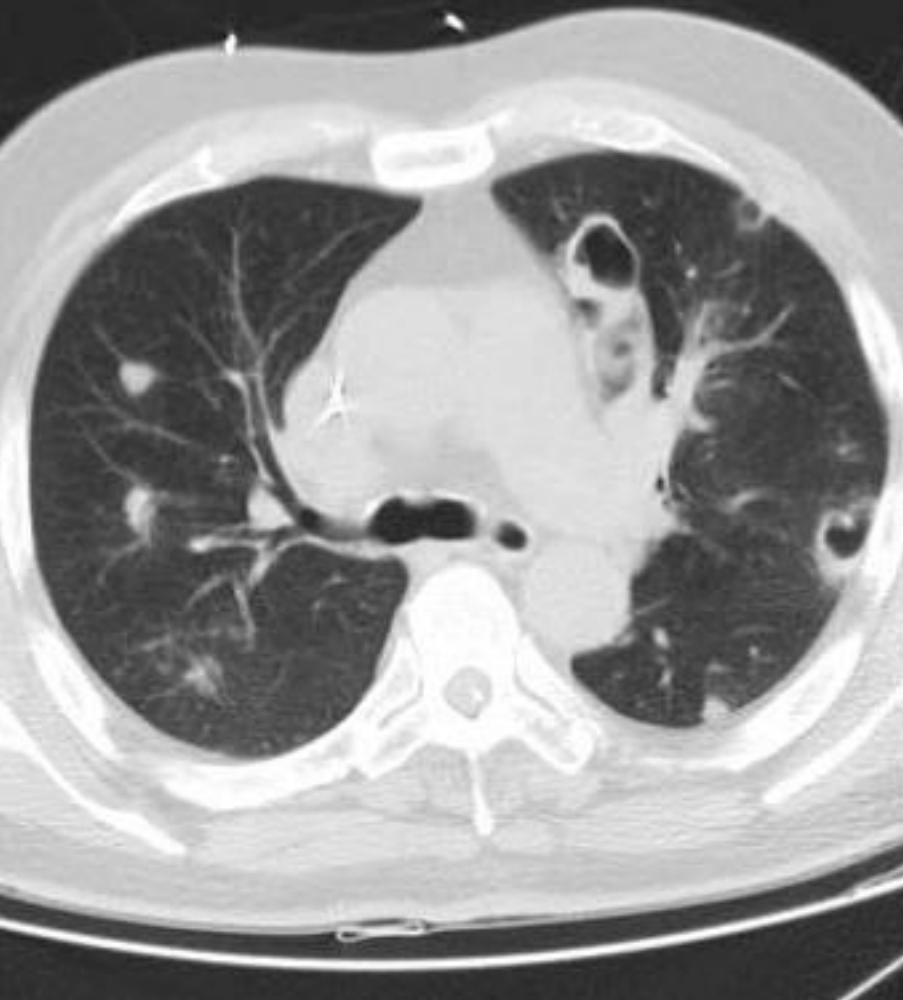Septic Embolism



Septic Embolism



- Discrete nodules with varying degrees of **cavitation** and **subpleural**, **wedge-shaped** heterogeneous areas of increased attenuation with rim-like peripheral enhancement.
- The nodules tend to be most numerous in the **lower lobes**.
- A vessel can be seen leading directly to the nodules (**feeding vessel sign**)



■ C: cancer

- Primary bronchogenic carcinoma: most frequently SCC
- Pulmonary metastasis: most frequently SCC, also adenocarcinoma, sarcoma

■ A: autoimmune;

- Wegener Granulomatosis, rheumatoid arthritis (rheumatoid nodules) etc.

■ V: vascular (both bland and septic pulmonary emboli)

■ I: infection (bacterial/fungal) / inhalation

- pulmonary abscess
- fungal / parasite infection
- pulmonary tuberculosis
- pneumoconiosis

■ T: trauma - pneumatoceles

■ Y: youth

- CPAM (congenital pulmonary airway malformation)
- pulmonary sequestration
- bronchogenic cyst

Infection

■ Bacteria

- ☐ Septic emboli
- ☐ Lung abscess
- ☐ Pneumonia: *S. aureus*, GNB, aspiration, nocardiosis

■ Mycobacteria:

- ☐ TB
- ☐ NTM

■ Fungal

- ☐ Aspergillosis
- ☐ Mucormycosis
- ☐ Coccidioidomycosis
- ☐ Cryptococcosis

Pyogenic Abscess

CXR findings:

- Thick-walled spherical cavity with **shaggy** and **irregular inner** border, often containing **air-fluid level**
- Begin as a focus of **consolidation**:
 - Extensive peri-cavitary consolidation suggest abscess rather than neoplasm: 在cavitary lesion 的周圍會有一些 infiltration or consolidative change , 代表從necrotizing pneumonia 而來
- **Dependent portion** if related to **aspiration**:
 - Supine: B2, B6
 - Upright: lower lobes

Pyogenic Abscess

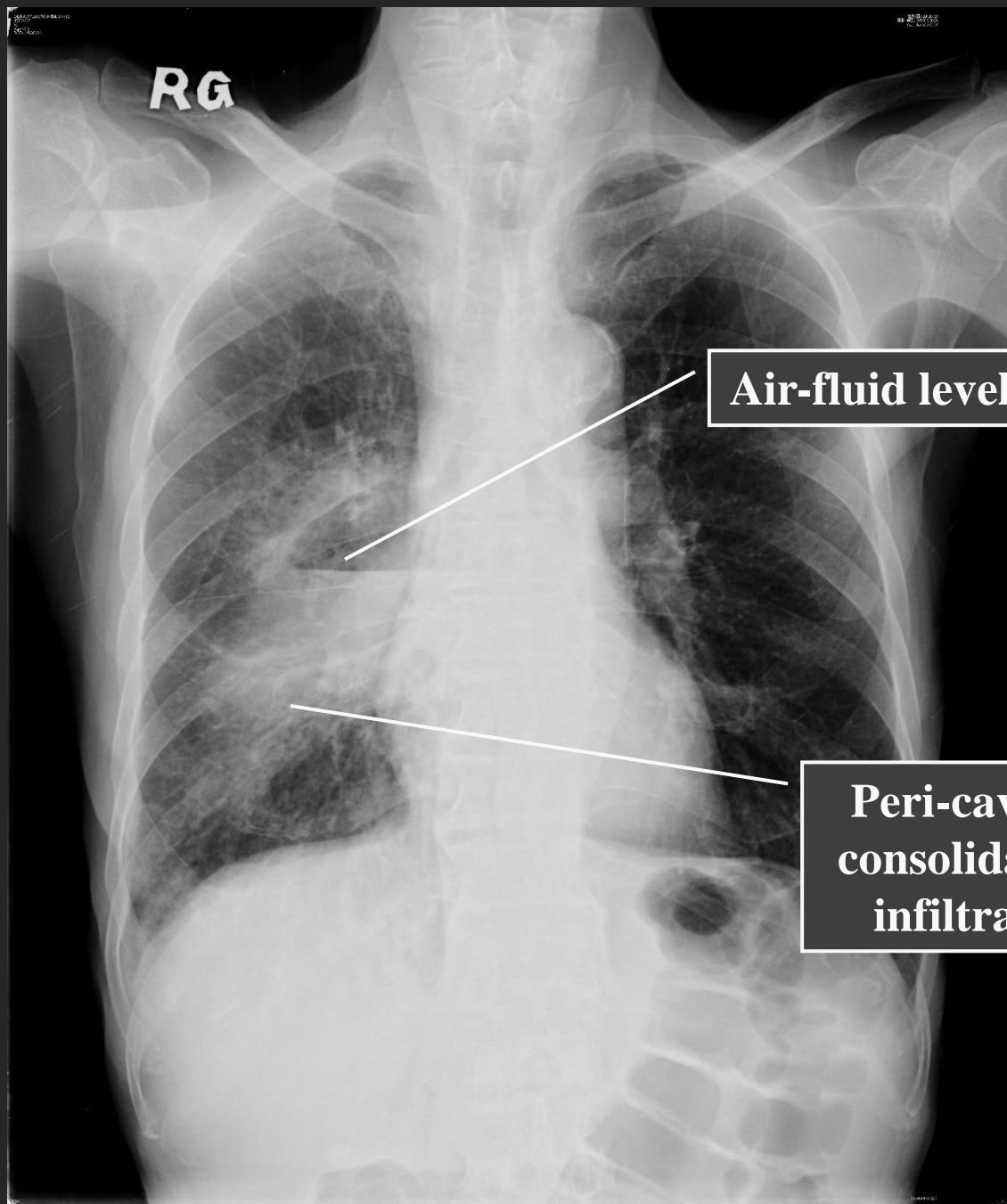
- Pathogenesis:

- Virulent pathogen → vasculitis → thrombosis → necrosis → cavity formation

- Pathogen:

- Most common pathogen

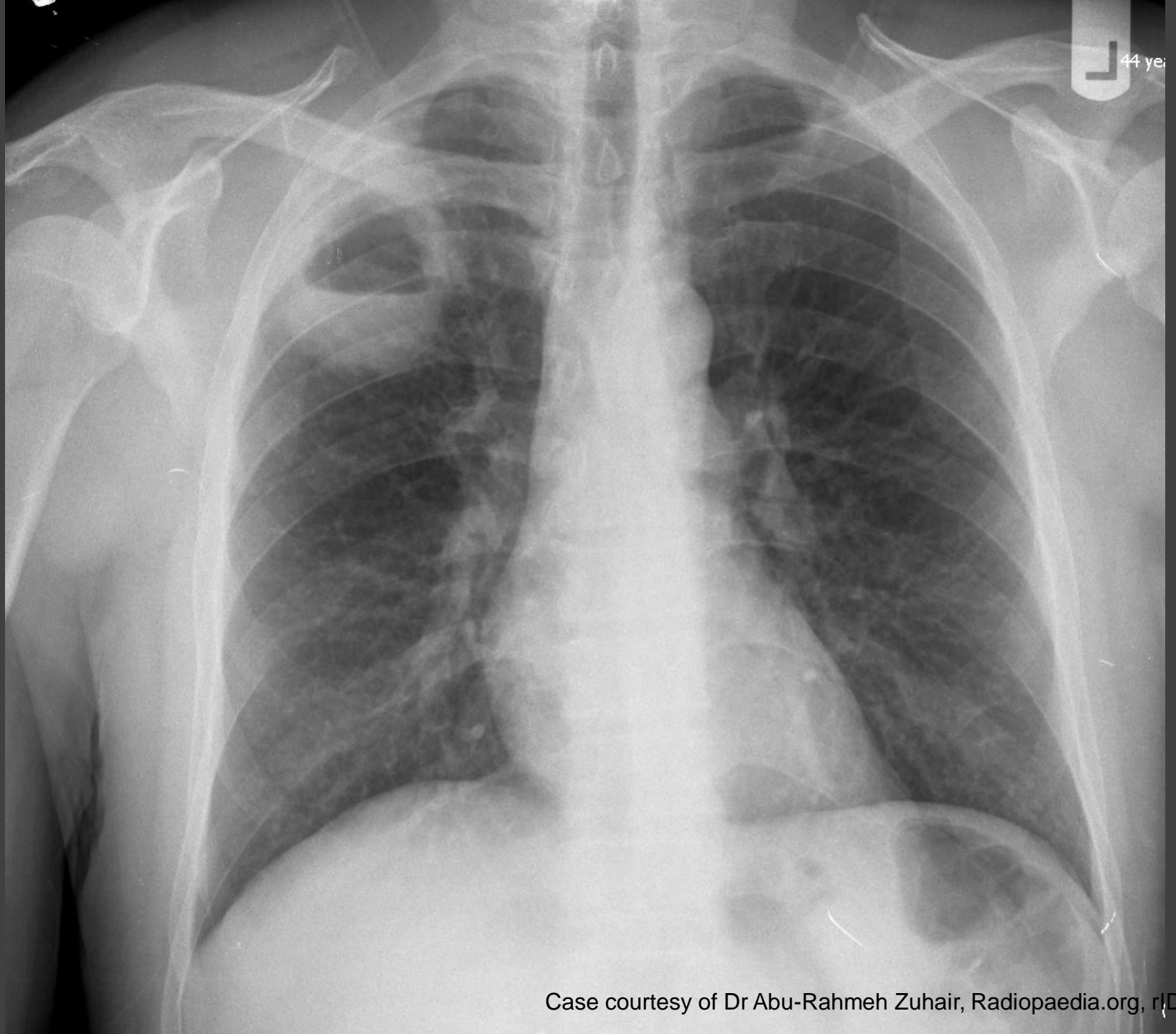
- GPC: Staphylococcus, β -hemolytic streptococcus
 - GNB: Klebsiella, Pseudomonas, E. coli
 - Anaerobes

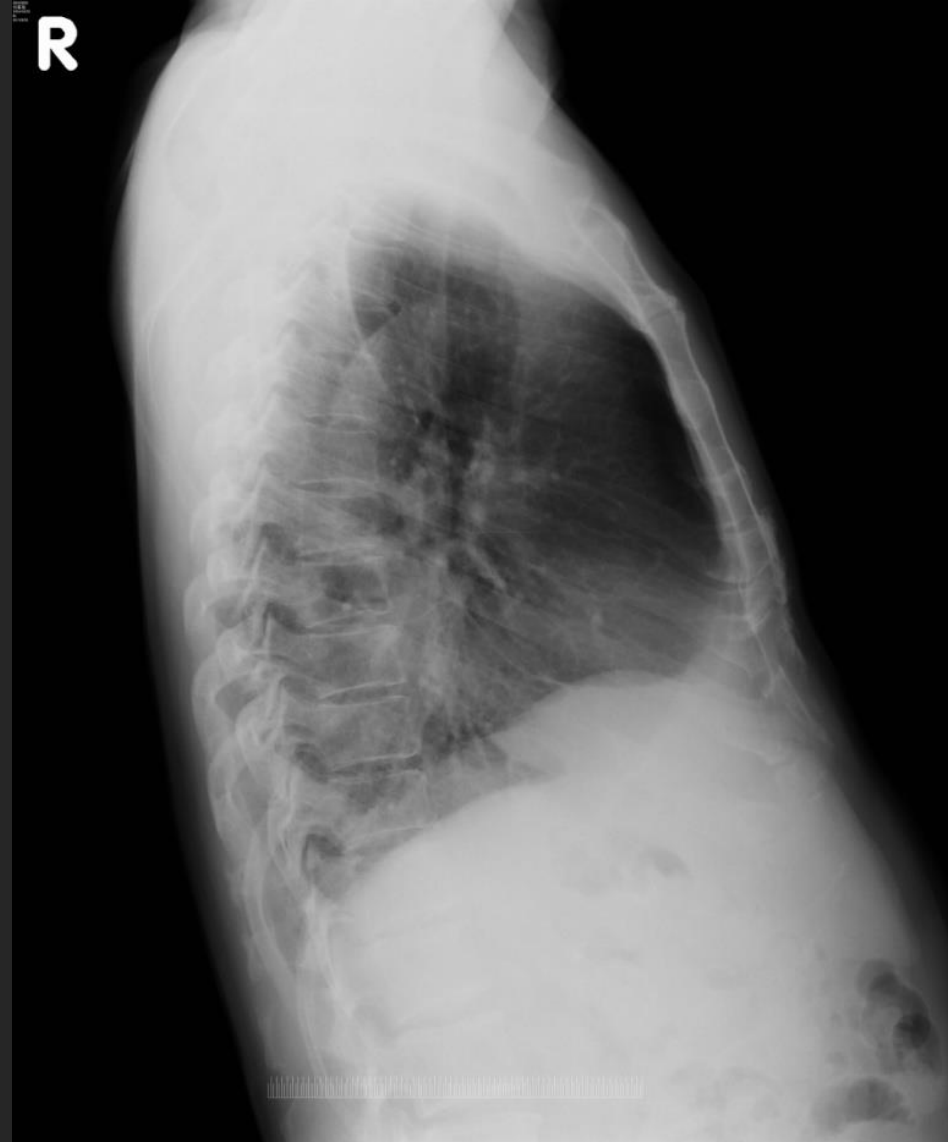
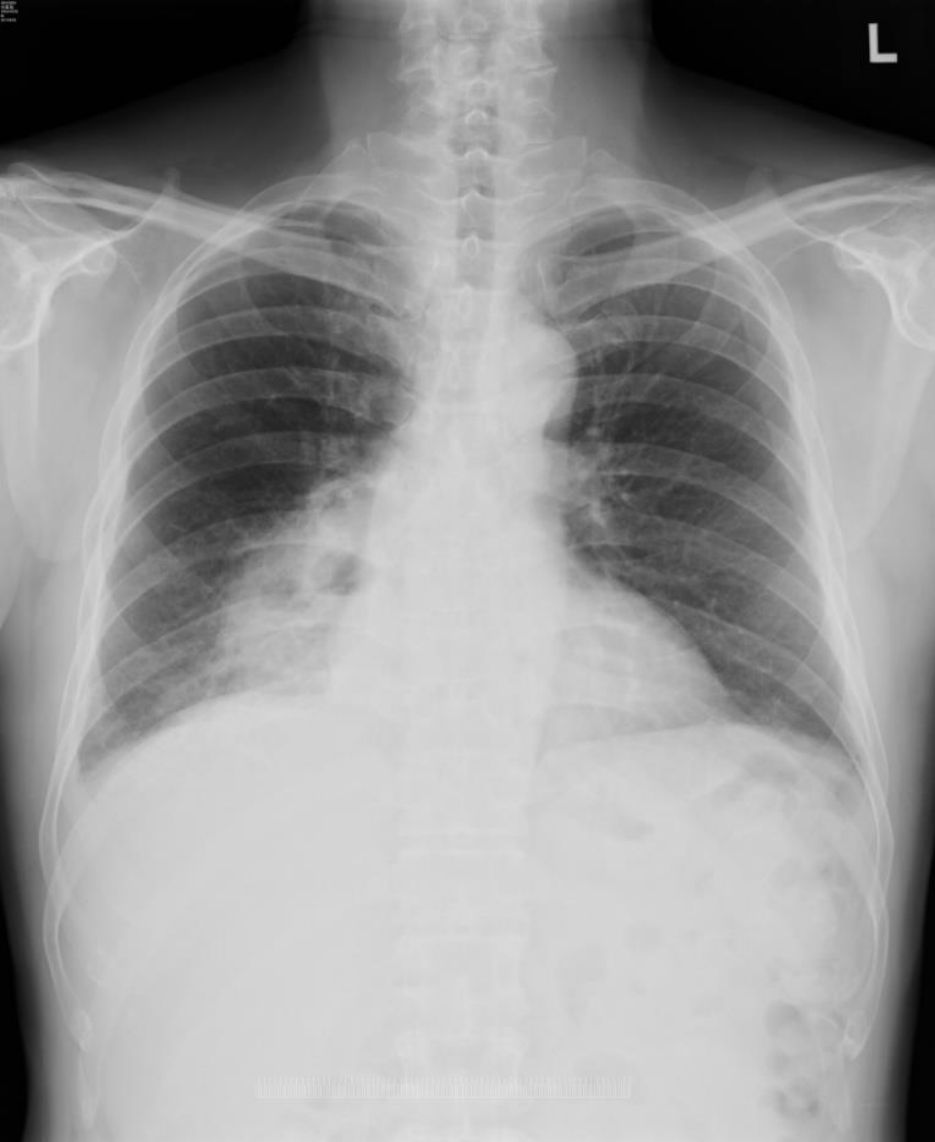

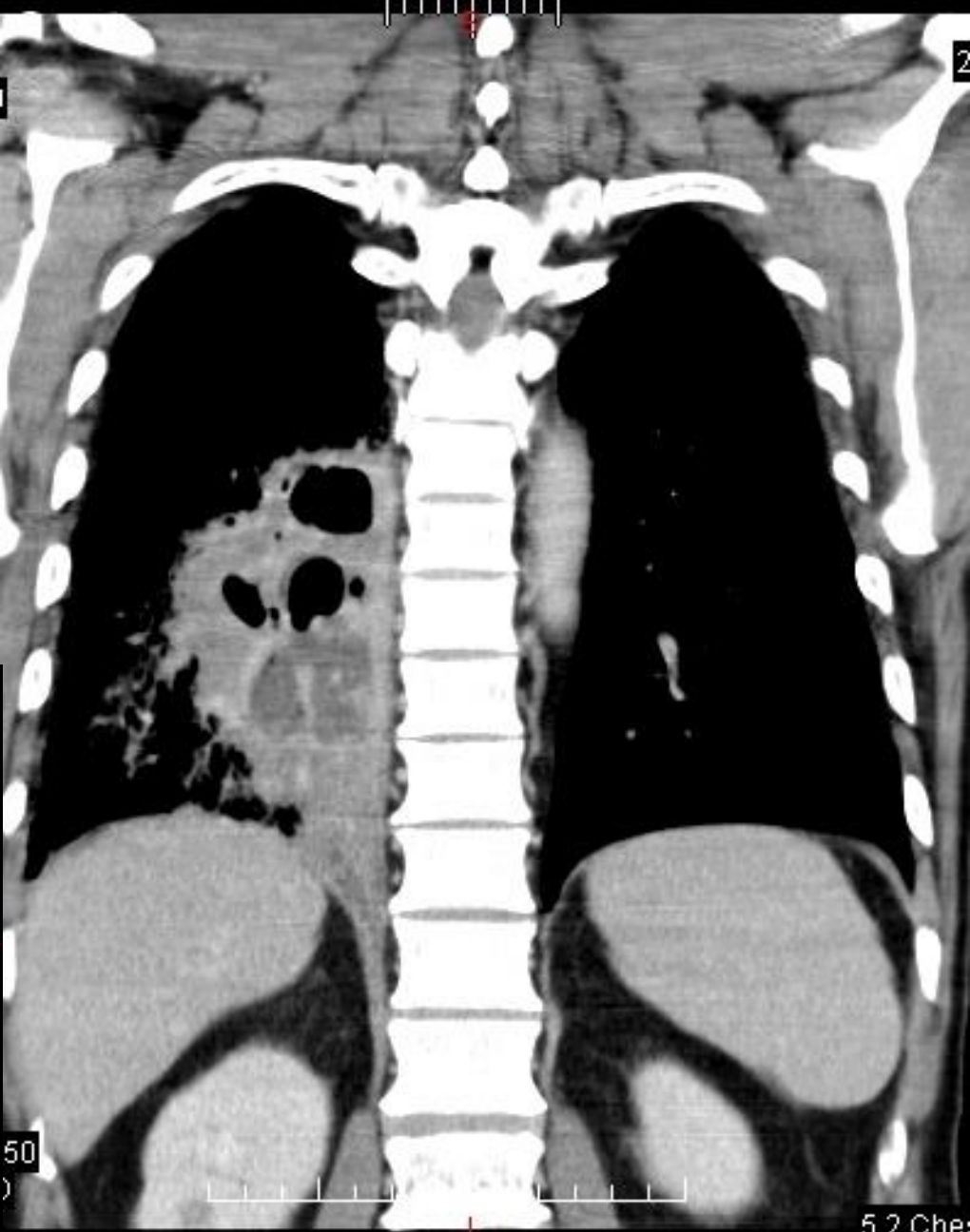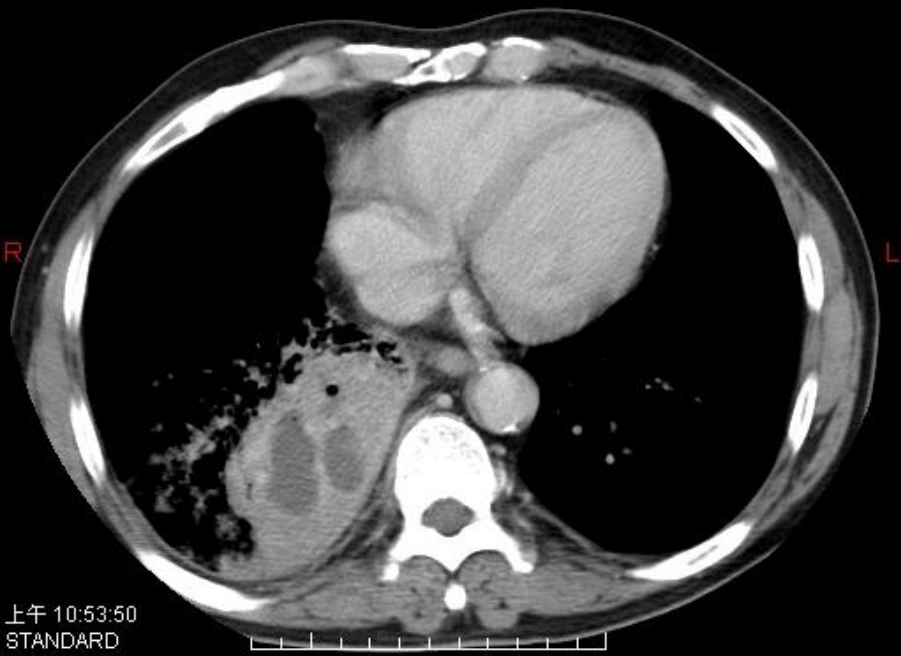
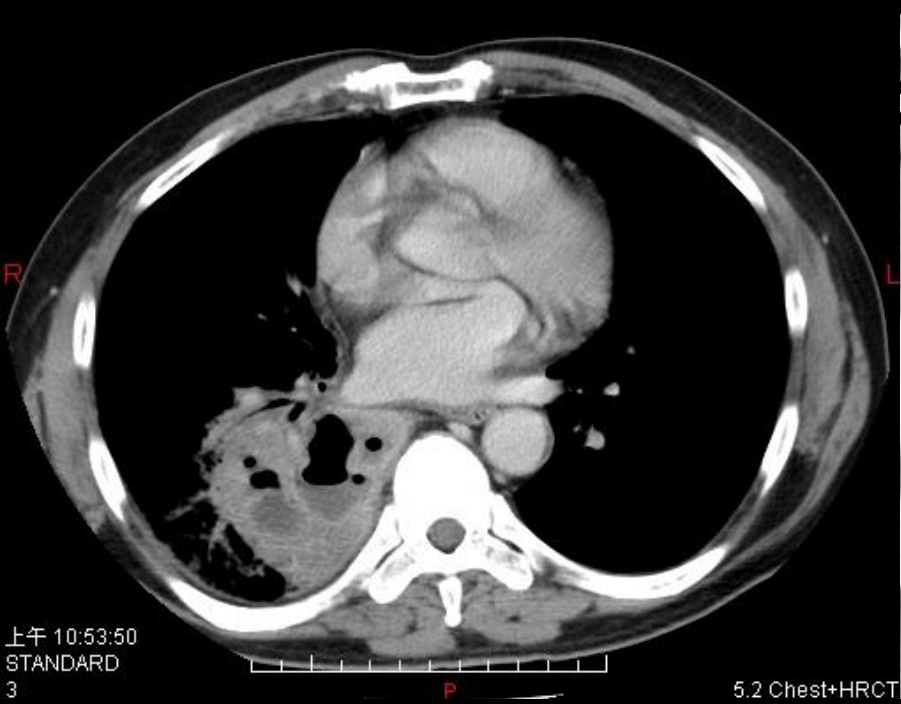
Lung abscess, *K. pneumoniae*

Air-fluid level

**Peri-cavitary
consolidation /
infiltration**







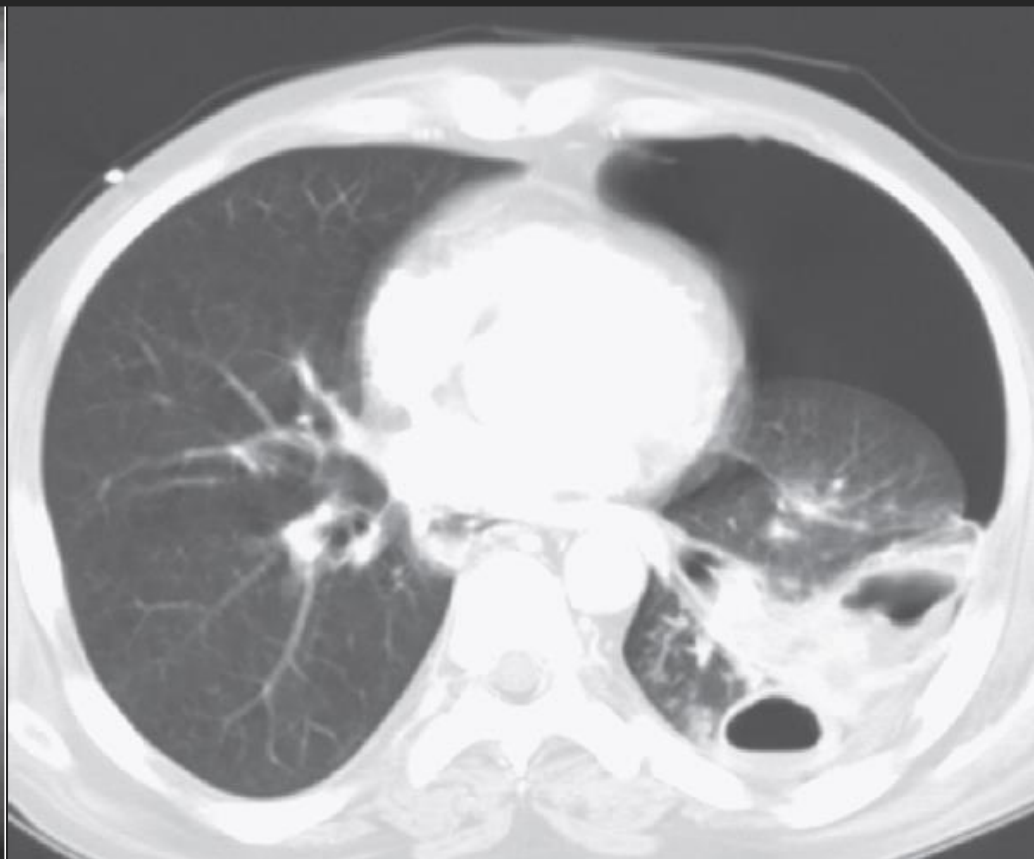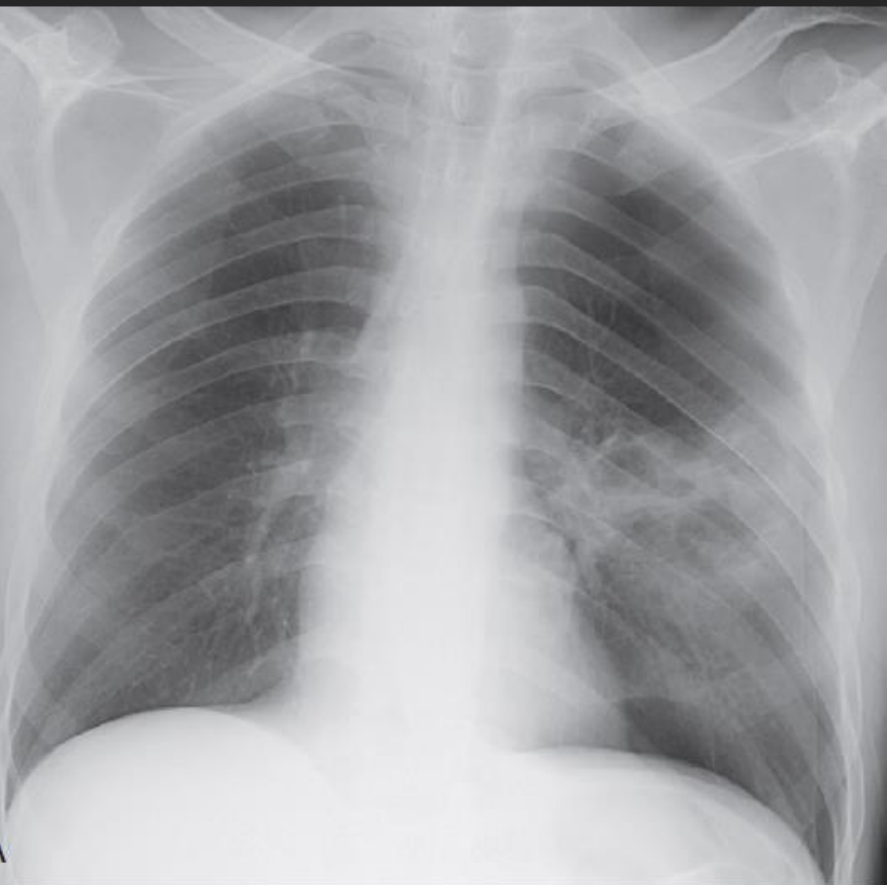


Figure 24-5 **A**, Localized area of air-space consolidation with multiple, eccentric lucencies and left pneumothorax in this patient with elevated WBC count and productive sputum is most suggestive of a necrotizing pneumonia. **B**, Computed tomography (CT) confirms consolidation with multiple cavities and a large pneumothorax. This is a gram-negative pneumonia, which is complicated by cavitation with bronchopleural fistula.

Tuberculosis

■ Location

- Apical, posterior segment of upper lobe (RB1, 2, LB1+2) & superior segment of lower lobe (B6)

■ TB in cavitory phase

- **active and at risk of dissemination**
- Hematogenous spreading:
 - diffuse fine nodules, miliary pattern
- Bronchogenic spreading:
 - larger (2-5mm) and ill-defined alveolar pattern

Tuberculosis

- Features suggesting of TB cavity
 - Surrounding associated **reticular scar**
 - **Volume loss** in the involved lobe
 - Associated **pleural thickening**
 - **Calcified** hilar or mediastinal **lymph nodes**

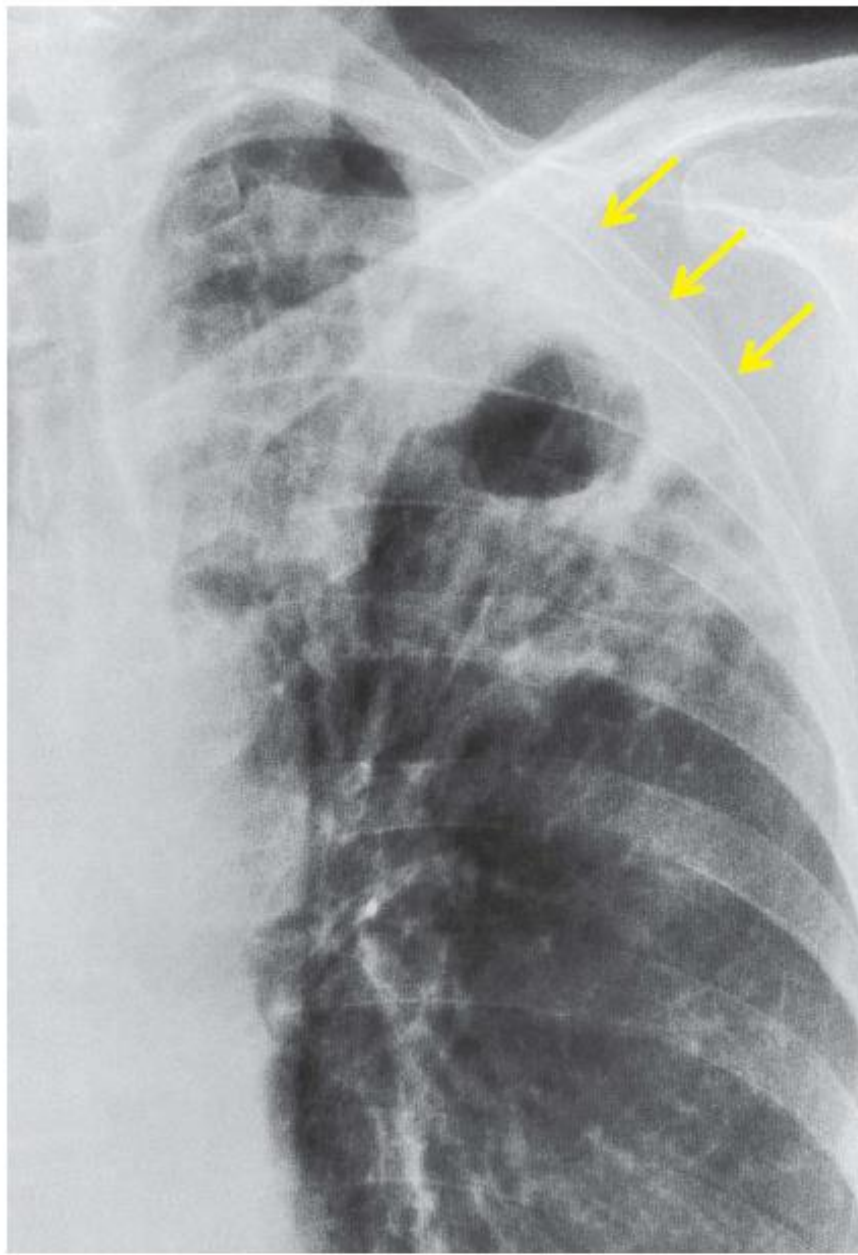


Fig. 5.58 Cavitory reactivation tuberculosis showing localized pleural thickening (arrows).

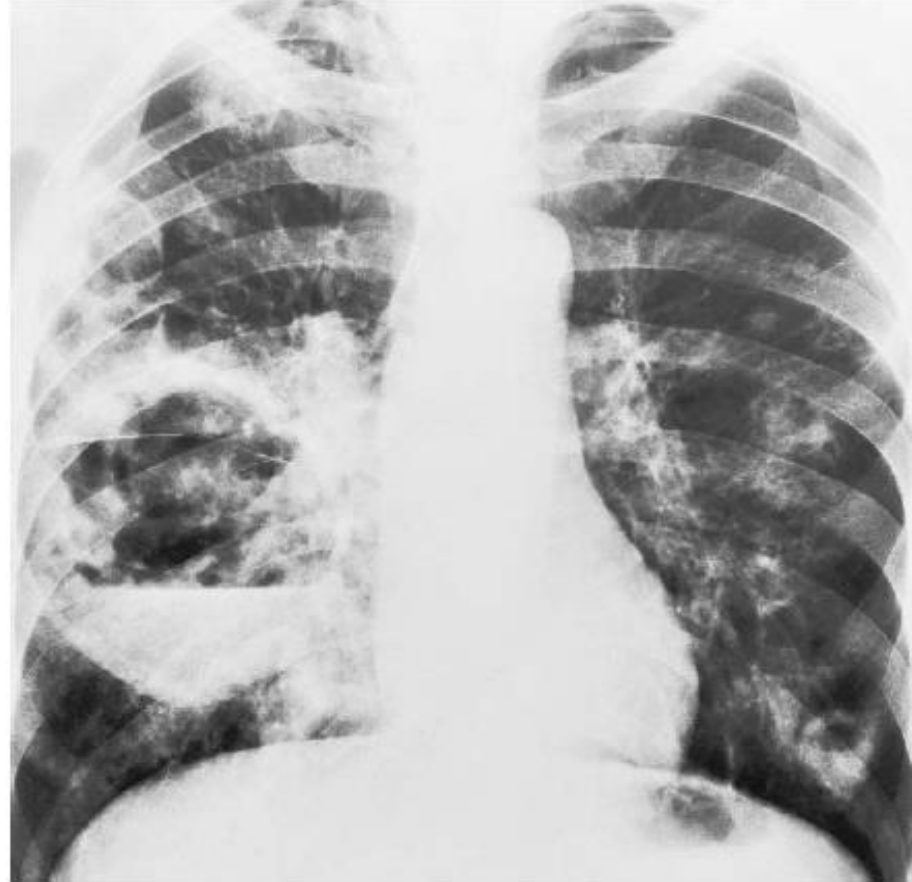
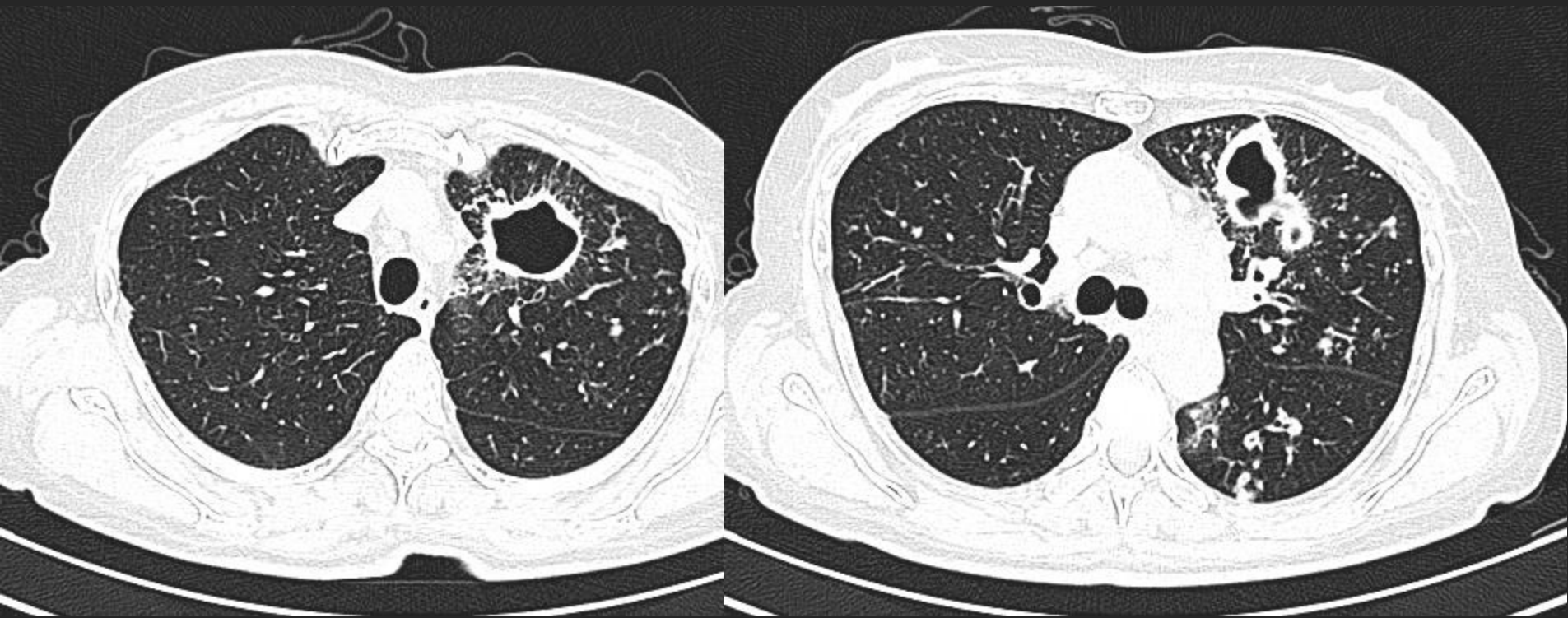
Fig. 5.59 Reactivation tuberculosis with a large right lower lobe cavitory lesion containing an air-fluid level. Other, smaller cavitory lesions are present in other lobes.



Aspergilloma

- Characterized by Aspergillus infection without tissue invasion.
- It typically leads to conglomeration of intertwined **fungal hyphae admixed with mucus and cellular debris** within a **pre-existent pulmonary cavity or ectatic bronchus**.
 - Cause of cavity formation :
 - **TB and sarcoidosis**: 最常見
 - 其他：bronchogenic cyst, pulmonary sequestration, and pneumatoceles secondary to PCP in AIDS patients
- Clinical:
 - May be asymptomatic
 - **Hemoptysis**: 最常見的症狀
 - Surgical intervention if life-threatening
 - Pulmonary arterial embolization in patient with poor lung reserve

Aspergilloma

■ Ball-in-hole:

- A solid, round or oval mass with soft-tissue opacity within a lung cavity.
- Although the term *mycetoma* is frequently used to describe these **fungal balls**, it is **an incorrect term to use**

■ Air-crescent sign:

- The mass is separated from the wall of the cavity by an airspace of variable size and shape.
- Other causes of air-crescent sign: Angioinvasive aspergillosis, echinococcal cyst, and, rarely, TB, Rasmussen aneurysm in a TB cavity, lung abscess, bronchogenic carcinoma, hematoma, and PCP.

■ The aspergilloma usually **moves when position changes**

■ Thickening of the cavity wall and adjacent pleura

■ May resolve spontaneously, possible related to hypersensitivity reaction

Figure 40

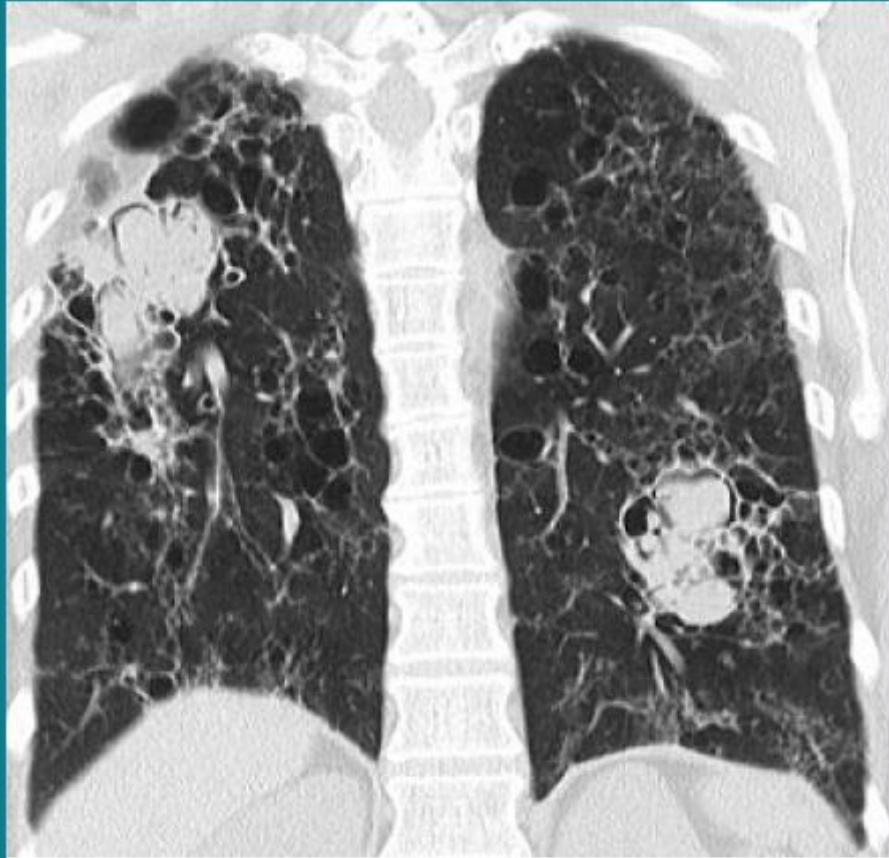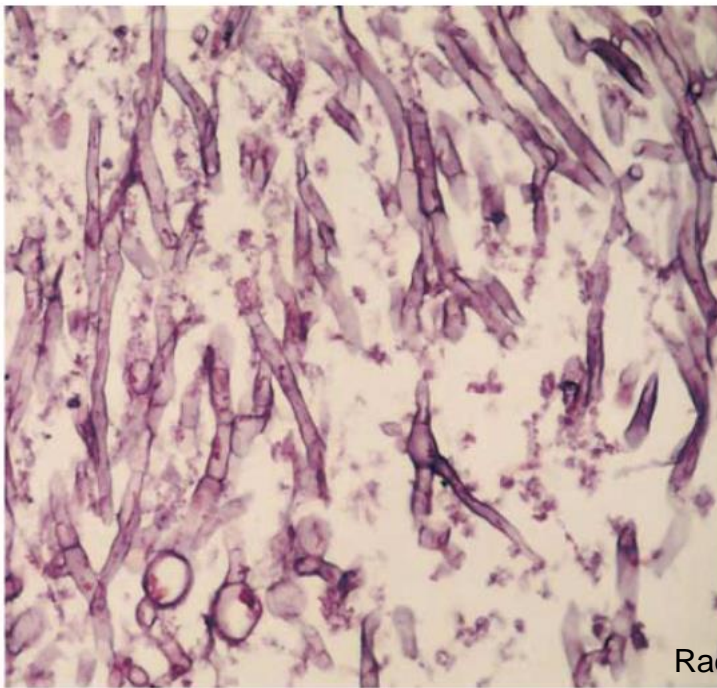
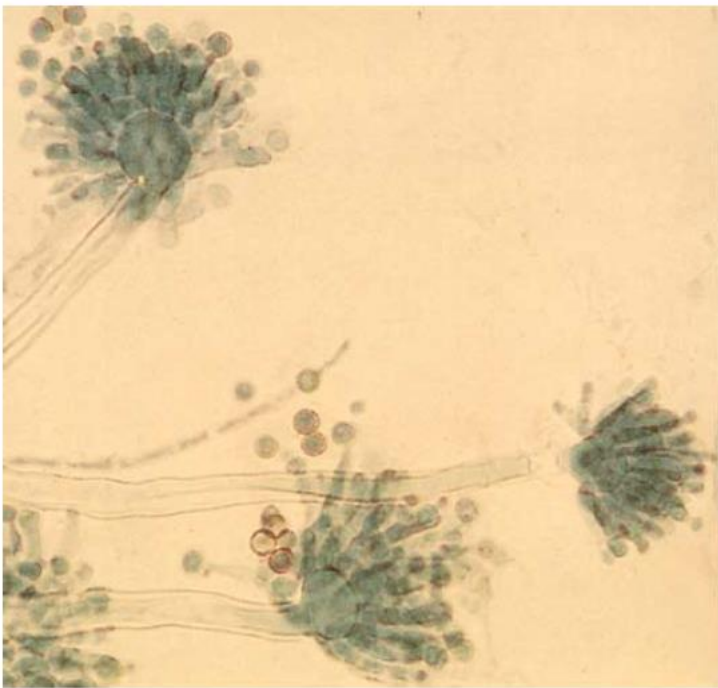

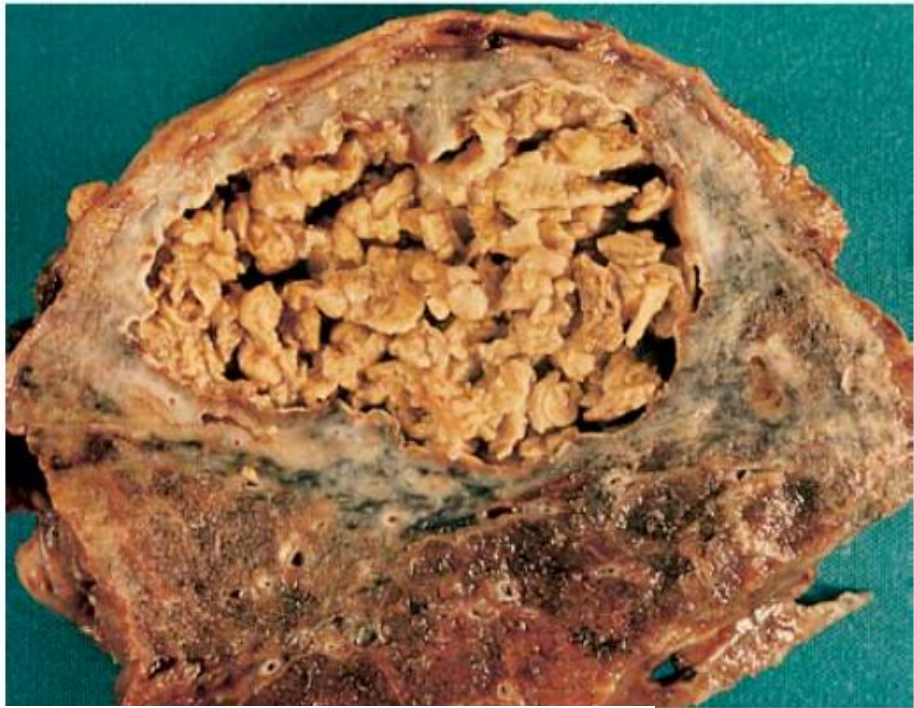
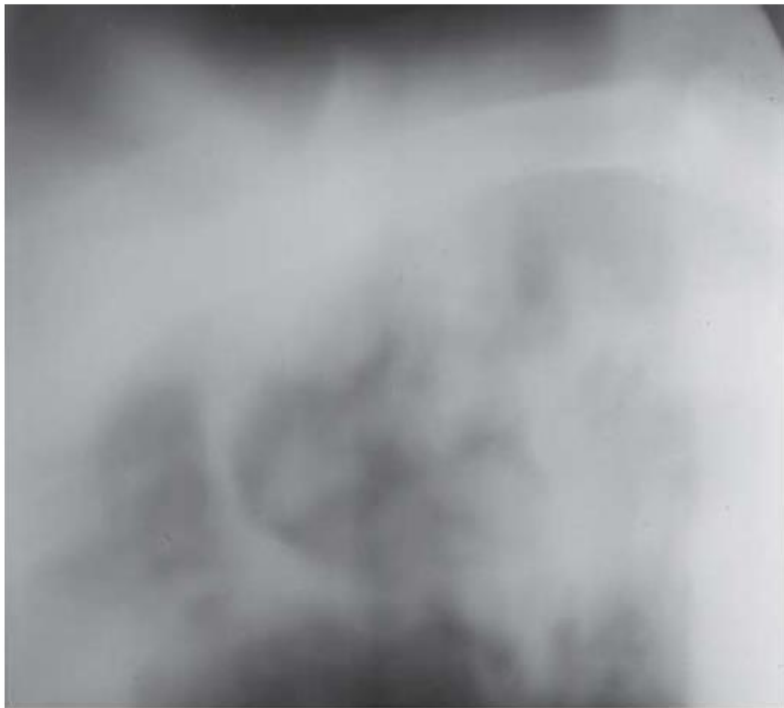Figure 40: Coronal CT scan shows mycetomas in both lungs.

mycetoma

Pathology.—A mycetoma is a discrete mass of intertwined hyphae, usually of an *Aspergillus* species, matted together by mucus, fibrin, and cellular debris colonizing a cavity, usually from prior fibrocavitary disease (eg, tuberculosis or sarcoidosis).

Radiographs and CT scans.—A mycetoma may move to a dependent location when the patient changes position and may show an air crescent sign (Fig 40). CT scans may show a spongelike pattern and foci of calcification in the mycetoma (93). A synonym is *fungus ball*. (See also *air crescent*.)



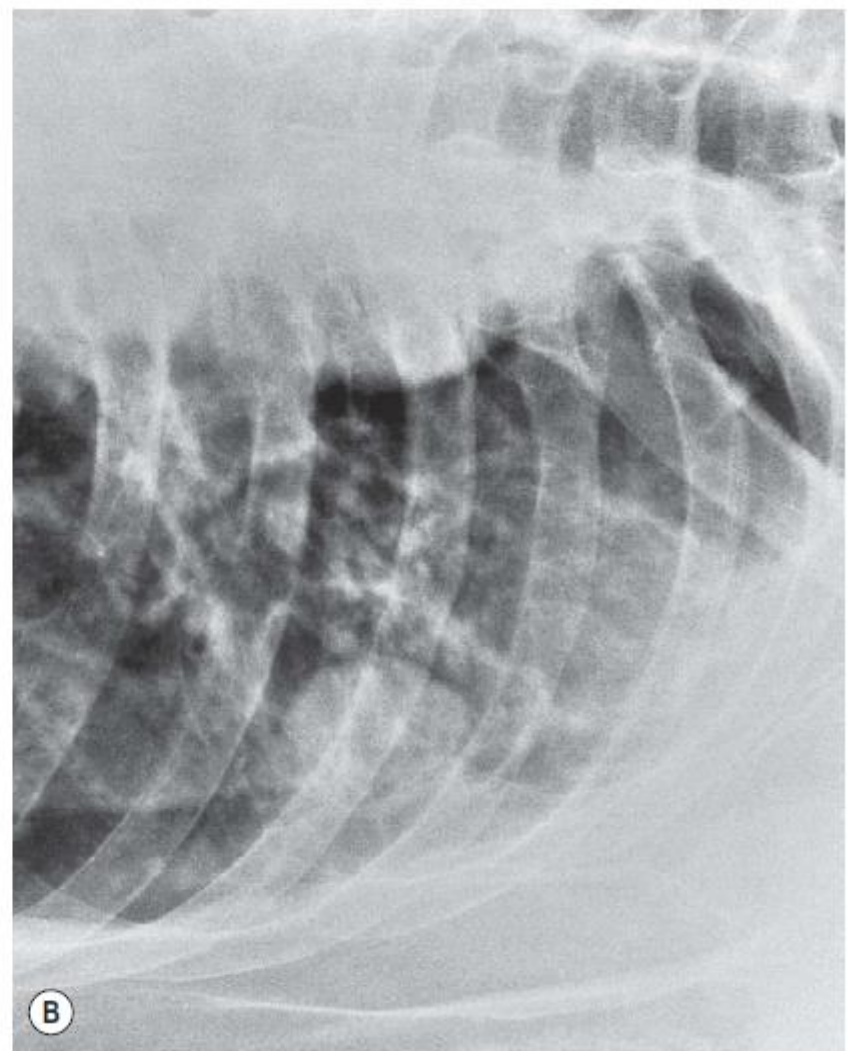
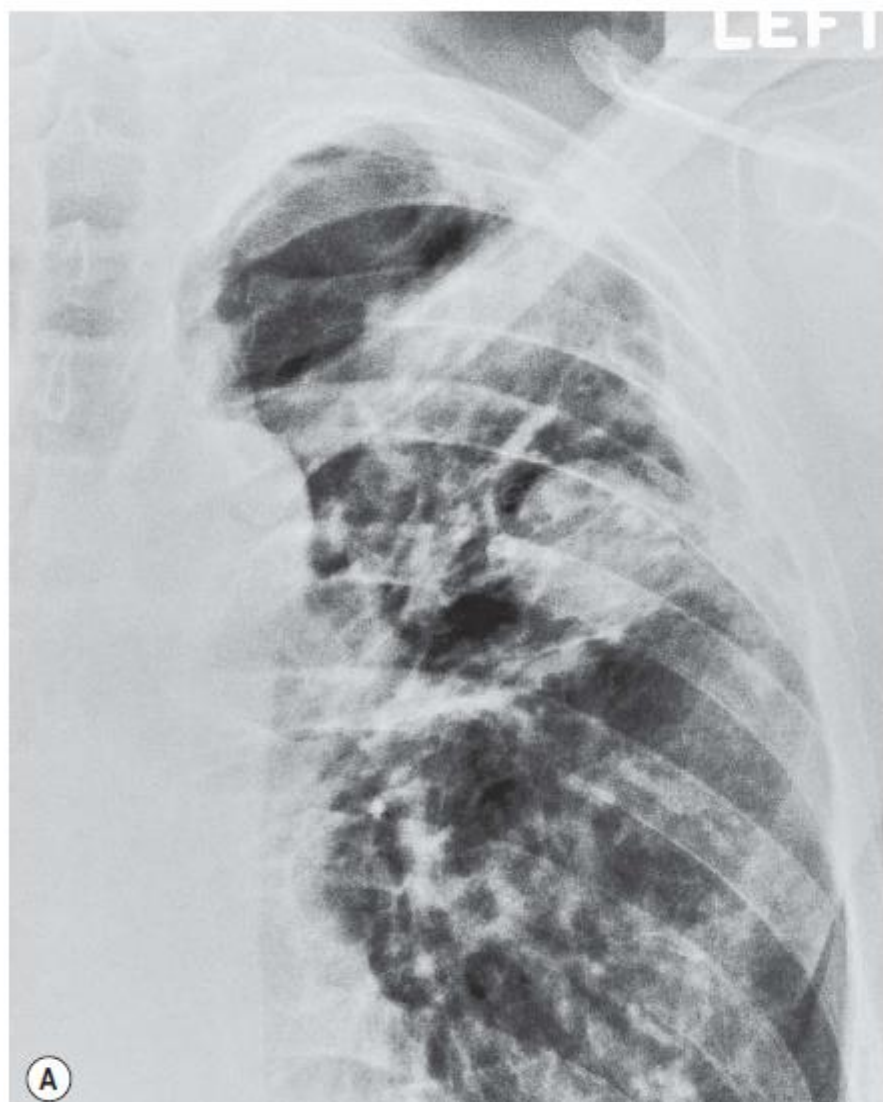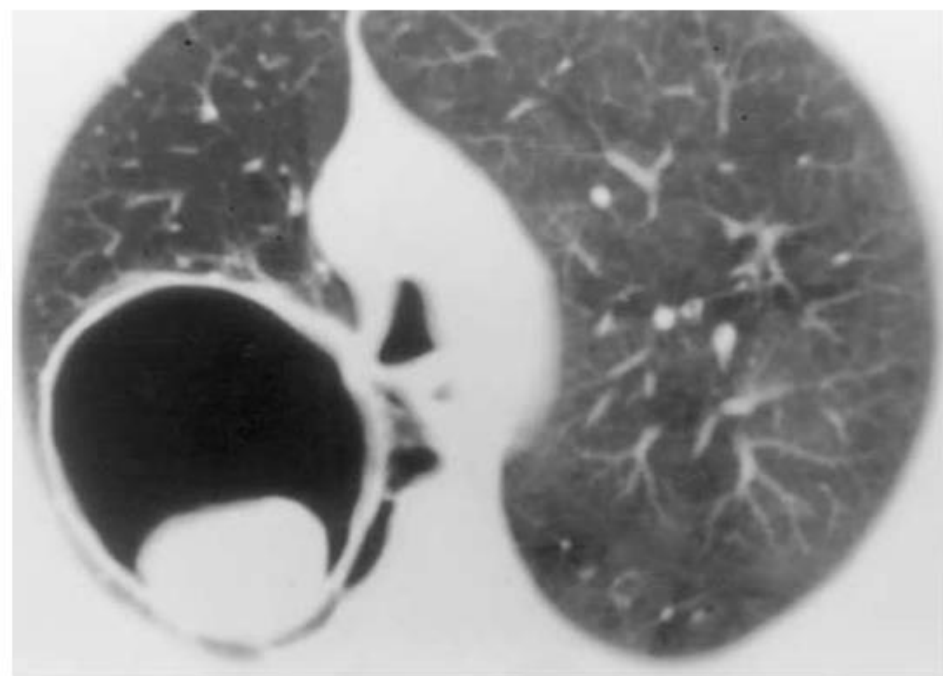
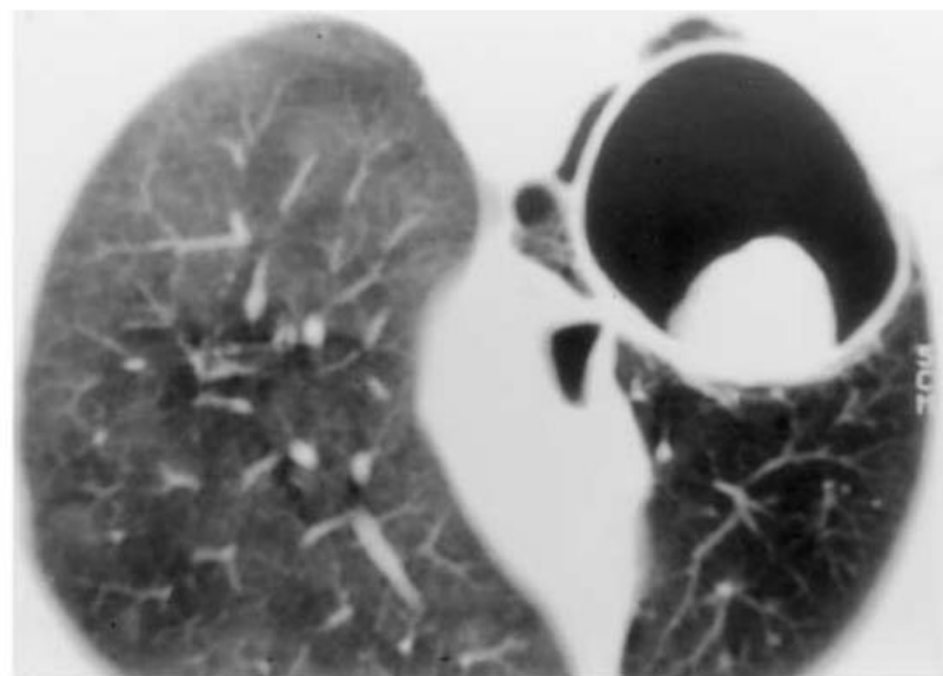


Fig. 5.127 A cavity containing an intracavitary fungus ball. Note the crescent of air above the mycetoma, adjacent pleural thickening, and movement of the fungus ball. In this case the underlying fibrocavitary disease was atypical mycobacterial infection. **A**, Frontal view. **B**, Lateral decubitus view. **C**, A frontal view 1 year earlier shows the preexisting cavity with an air–fluid level but no easily recognizable mycetoma.



a.



b.

Figure 5. Mobile aspergilloma within a pulmonary cystic cavity in a 43-year-old man. Chest CT scans obtained with the patient supine (**a**) and prone (**b**) show a change in the position of the aspergilloma. *A fumigatus* was discovered at bronchoscopy. (Courtesy of Josep M. Mata, MD, Unidad Diagnóstica de Alta Tecnología, Sabadell, Spain.)

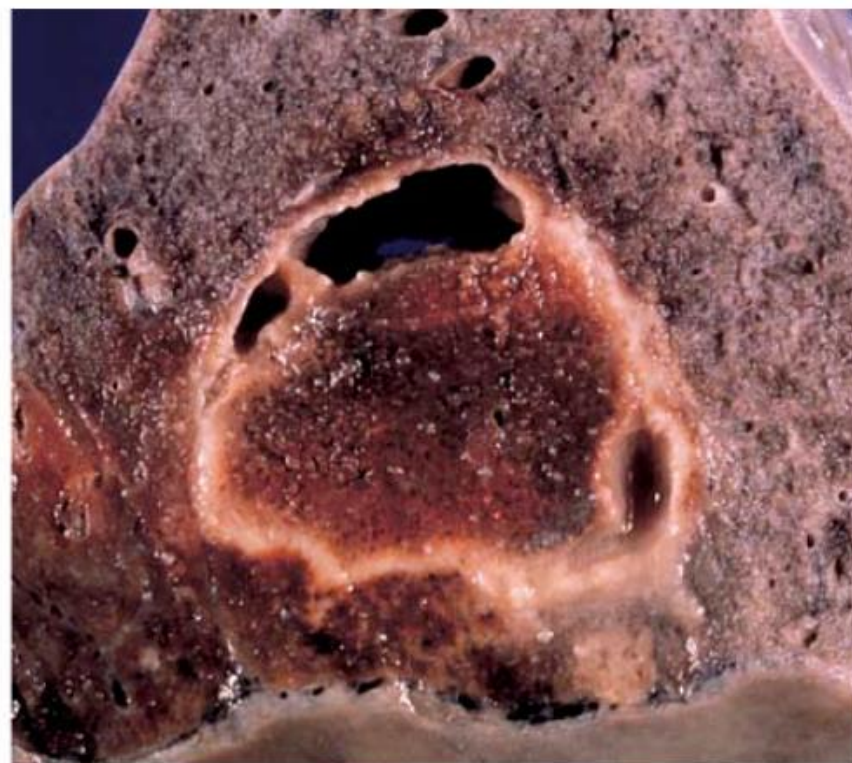
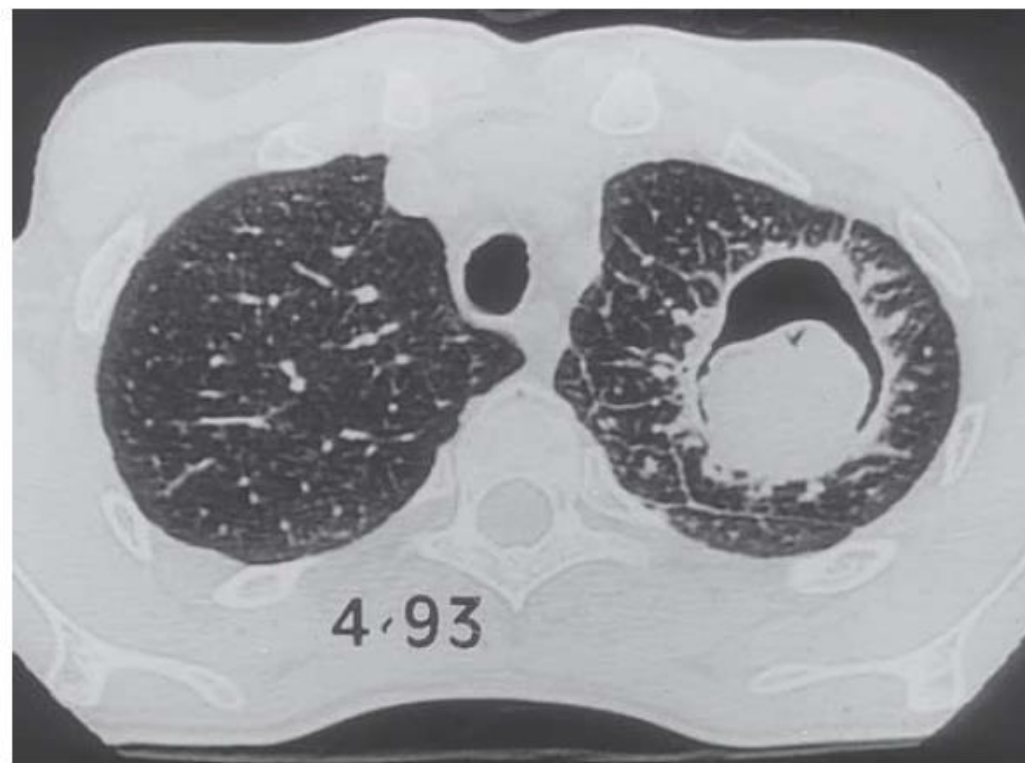
Figure 3

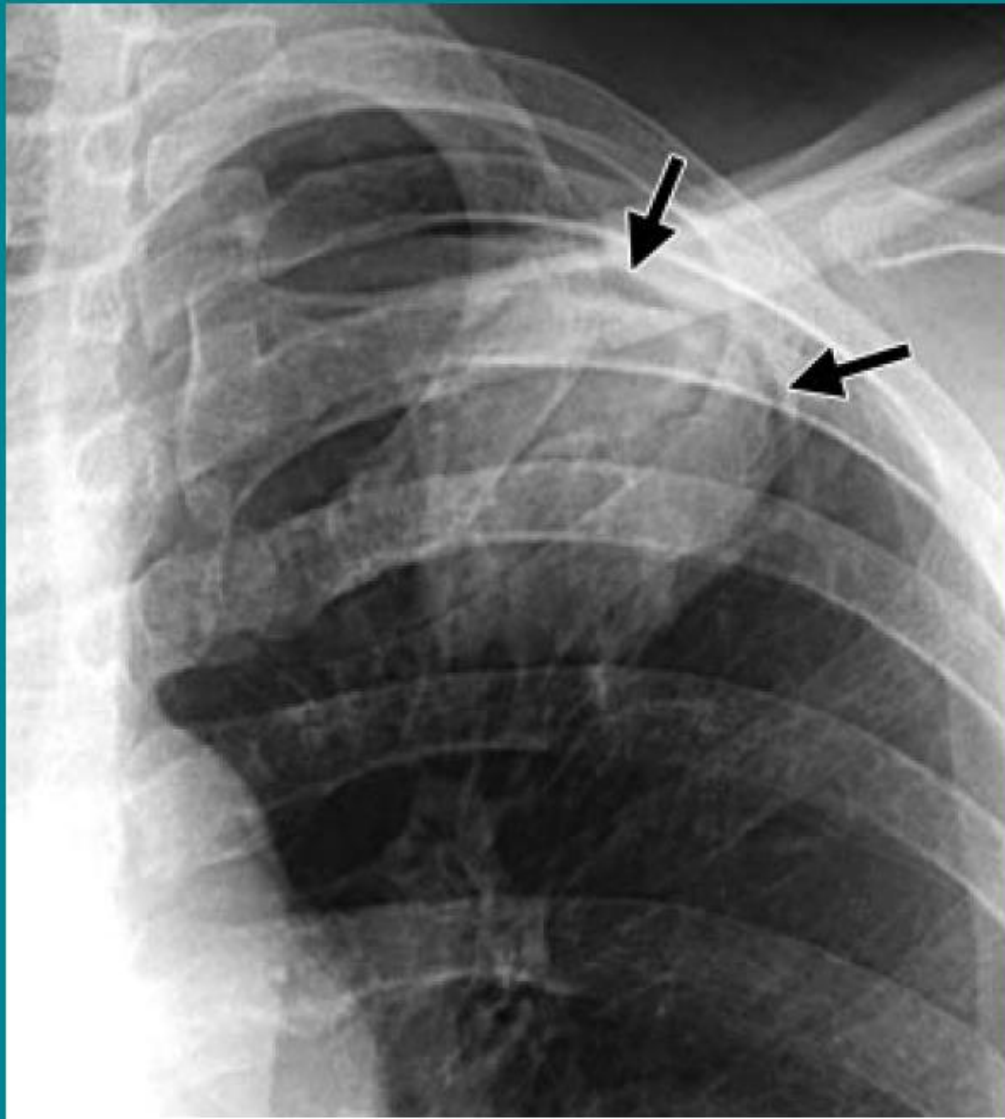

Figure 3: Magnified chest radiograph shows air crescent (arrows) adjacent to mycetoma.

air crescent

Radiographs and CT scans.—An air crescent is a collection of air in a crescentic shape that separates the wall of a cavity from an inner mass (Fig 3). The air crescent sign is often considered characteristic of either *Aspergillus* colonization of preexisting cavities or retraction of infarcted lung in angioinvasive aspergillosis (9,10). However, the air crescent sign has also been reported in other conditions, including tuberculosis, Wegener granulomatosis, intracavitary hemorrhage, and lung cancer. (See also *mycetoma*.)



a.

b.

Figure 18. Angioinvasive aspergillosis in a 54-year-old man. **(a)** Thin-section CT scan (lung window) shows a cavitated nodule with air crescent formation. **(b)** Photograph of the pathologic specimen shows a thick-walled cavity with corresponding air crescent formation.

Cryptococcus

■ 分類：

- Pulmonary nodules or masses with well- or ill-defined margins
- Segmental or lobar consolidation
- Small nodular or reticulonodular opacities

■ Immunocompetent patient

- Solitary or multiple **pulmonary nodules** or masses (最常見)
 - 0.5~5cm in size; more common in **lower and peripheral lung**
- Focal areas of consolidation: air-bronchogram (+)

■ Immunocompromised patient

- Wide varieties, including single nodules, multiple nodules that progressed to confluence and/or **cavitation**, segmental consolidation, bilateral bronchopneumonia, or mixed patterns.
- Adenopathy, miliary pattern, cavitation and pleural effusions are limited in these patient

Box 5.14 Cryptococcosis (torulosis)

(A) Immunocompetent individuals*

- Single or multiple pulmonary nodules. Well-defined nodules 1–10 cm in diameter consisting of a fungal mass without reaction or an encapsulated mass with possible central necrosis. No calcification. Cavitations rare
- Single or multiple areas of segmental or lobar consolidation. Air bronchograms sometimes seen. Pleural effusions rare. Cavitation rare
- Hilar and mediastinal adenopathy may be seen
- Rarely a disseminated pattern of bronchopneumonia with nodular or irregular densities

(B) Immunocompromised individuals

- Immunocompromise may be mild – diabetes mellitus, alcoholism – or more severe – HIV, hematologic malignancies, organ transplantation or chemotherapy
- Findings as for (A), with the following features:
 - Cavitation is commonly seen in both nodules and areas of consolidation (in up to 40% of cases)
 - Pleural effusions frequent
 - Hilar and mediastinal adenopathy is a more prominent feature
 - Diffuse dissemination in the lungs is common
 - Systemic dissemination of infection very common, especially to the meninges

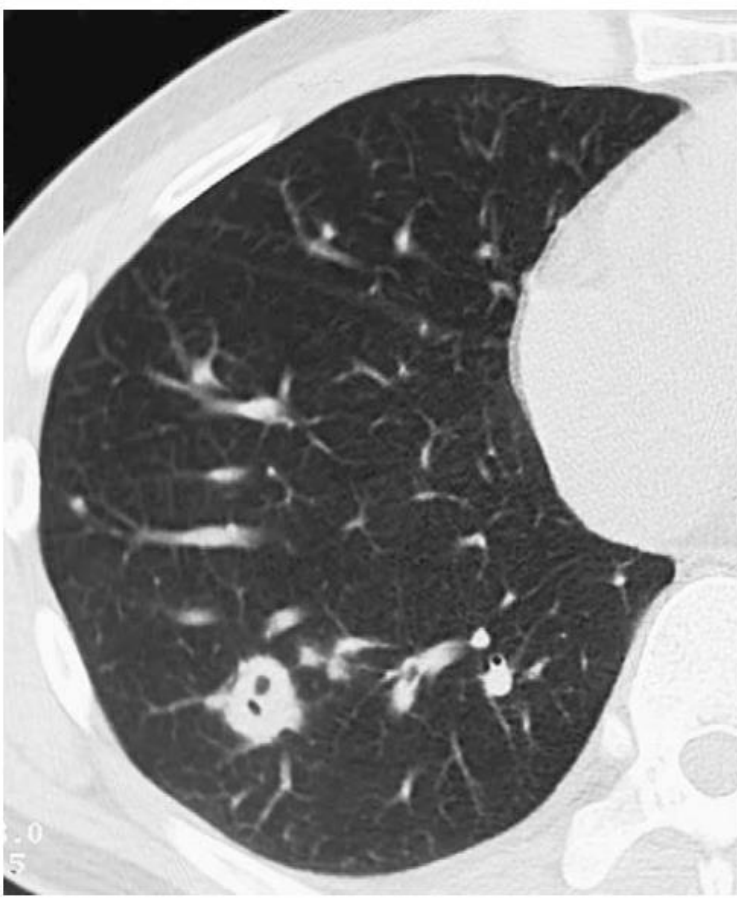


Fig. 5.111 Nonspecific cavitating nodule in the right lower l caused by *Cryptococcus*. (Courtesy of Dr. M Ujita.)

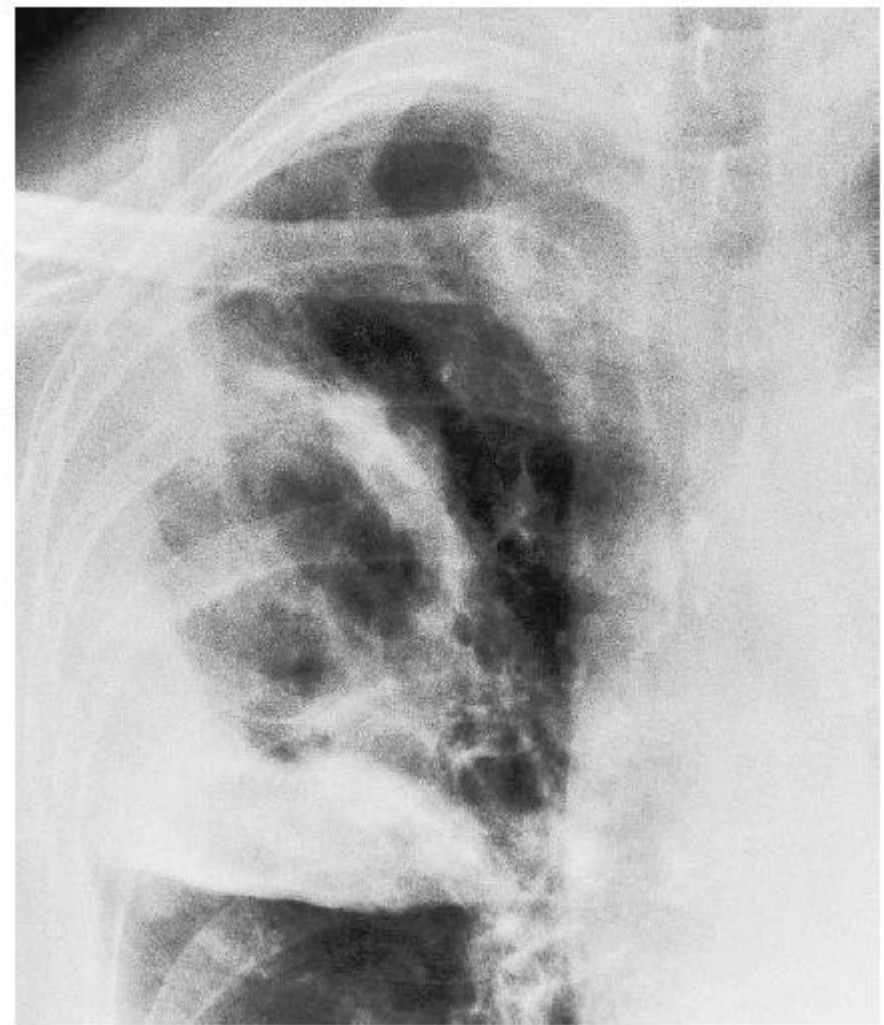


Fig. 5.113 Cryptococcal pneumonia with extensive cavitation in the right upper lobe.

Thoracic Cryptococcosis: Immunologic Competence and Radiologic Appearance

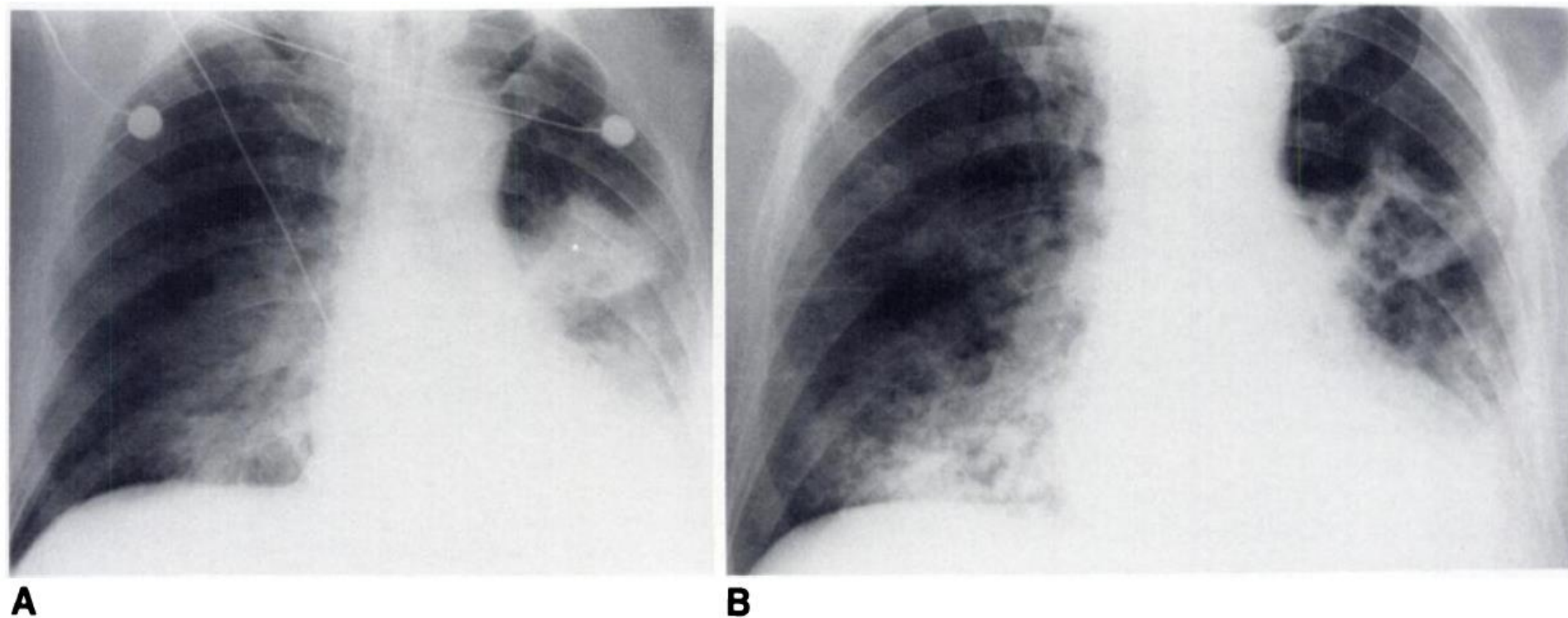
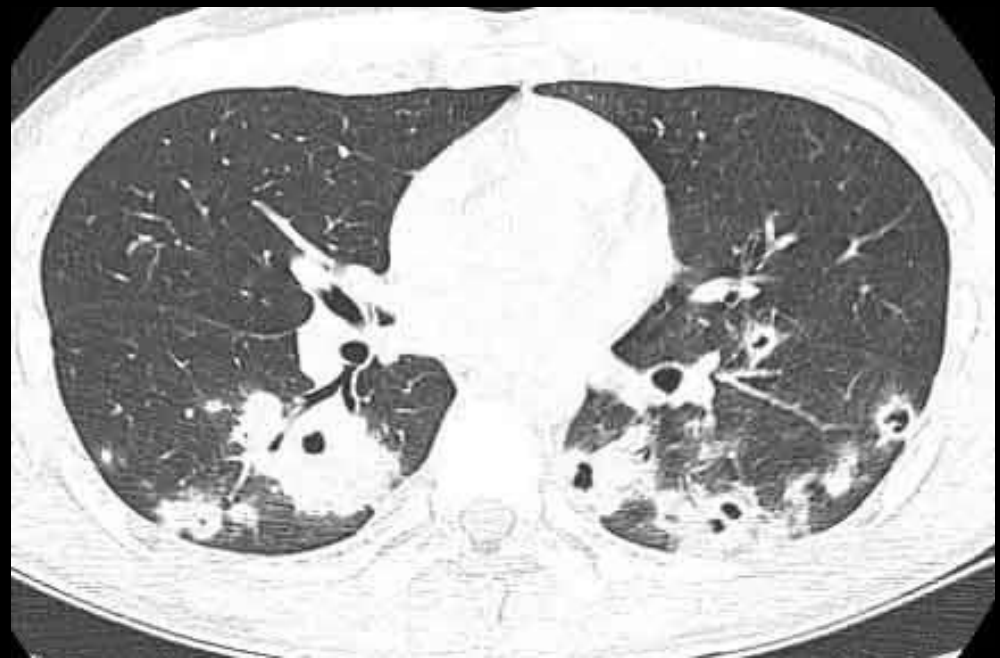
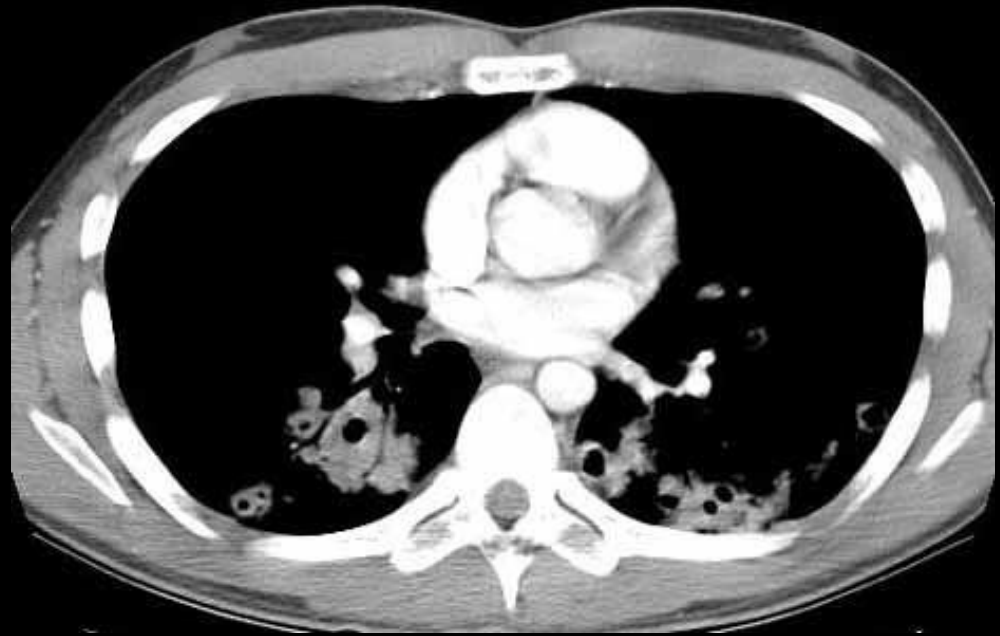
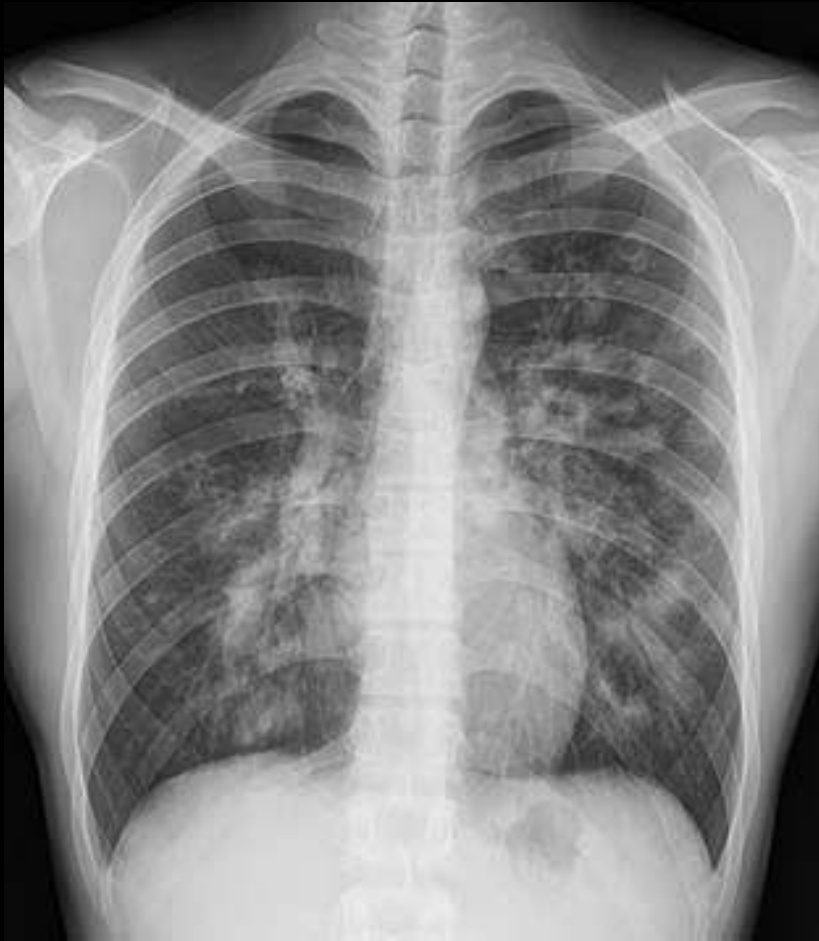
Fig. 4.—Cryptococcosis in compromised host, who had history of alcohol abuse. **A**, Patchy consolidation in both lungs. **B**, 15 days later. Cavitation has developed in left-upper-lobe consolidation.

Cryptococcal pneumonia



Echinococcosis (條蟲)

- 在histology下，**cysts**分成三層
 - 外：**Pericyst**, composed of fibroblasts, giant cells, and eosinophils, which form a **rigid fibrous layer**
 - 中：An **acellular** middle laminated membrane with nutrient functions
 - 內：A thin, translucent **inner germinal layer**, which contain various scolices and generates daughter cysts
- 影像學檢查最常見的表現：**Cystic lesions**
 - Solitary (60% of cases) or multiple
 - Unilateral or bilateral (20%–50%)
 - Predominantly found in the **lower lobes** (60%)(血行性)
 - 1~20 cm

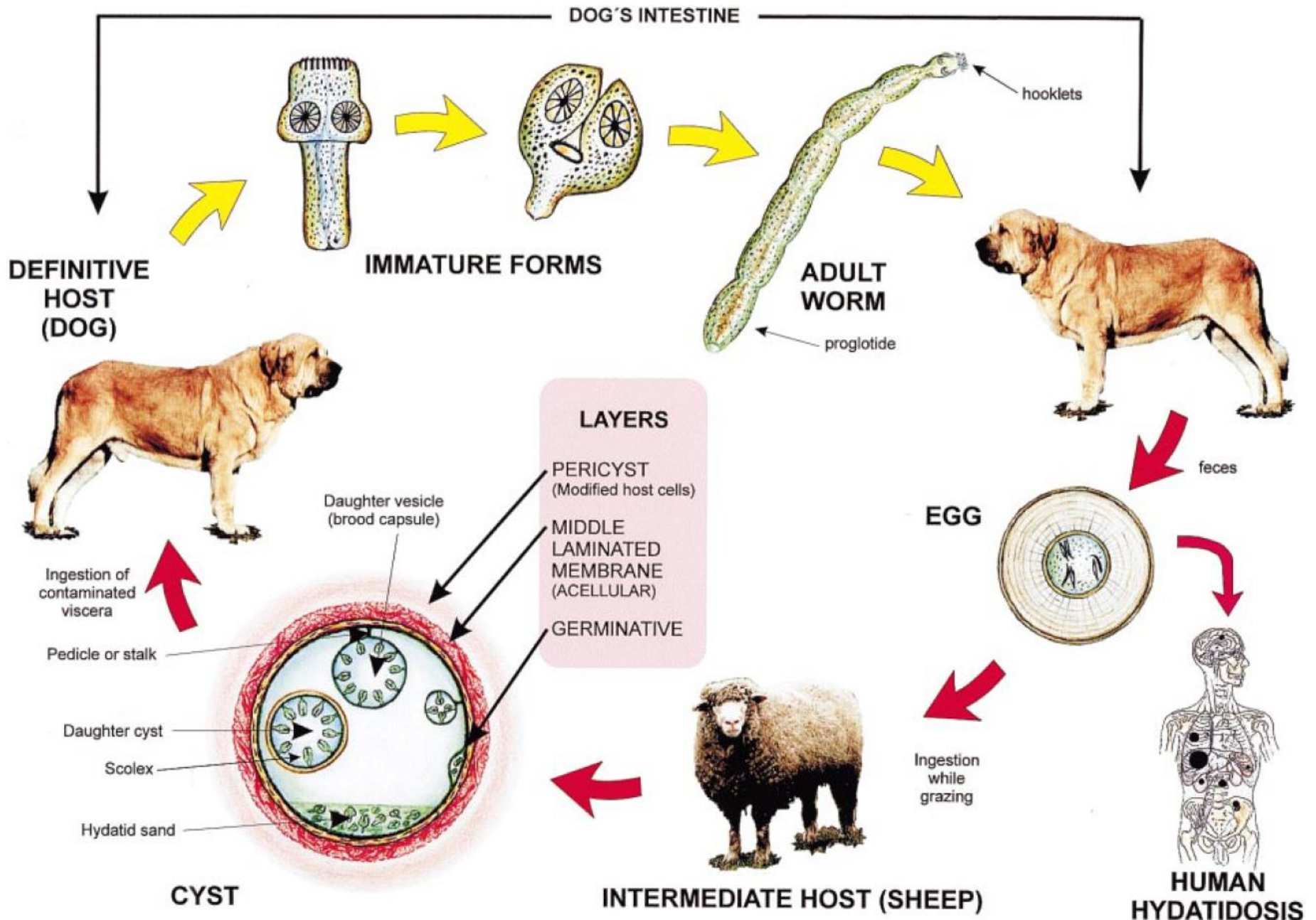


Figure 2. Life cycle (dog-sheep cycle) of *E. granulosus*. Diagram shows the most prevalent life cycle of *E. granulosus*, in which a dog and sheep serve as the definitive and intermediate hosts, respectively. Radiographics. 2000;20(3):795-817

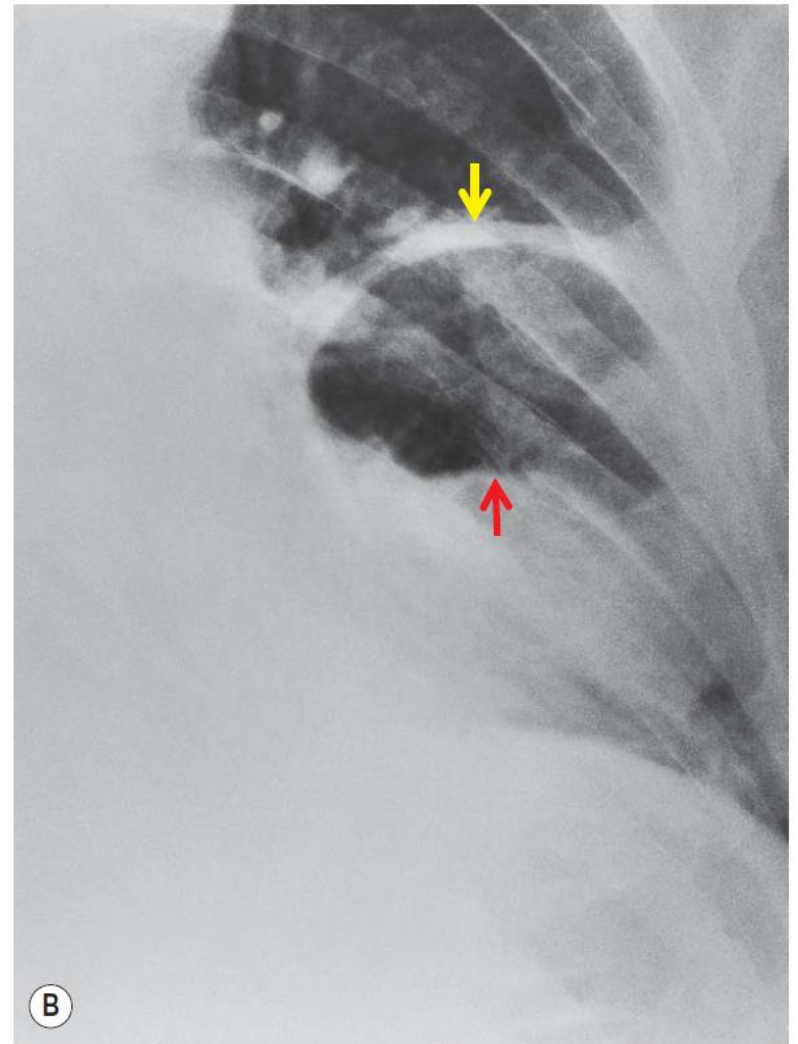
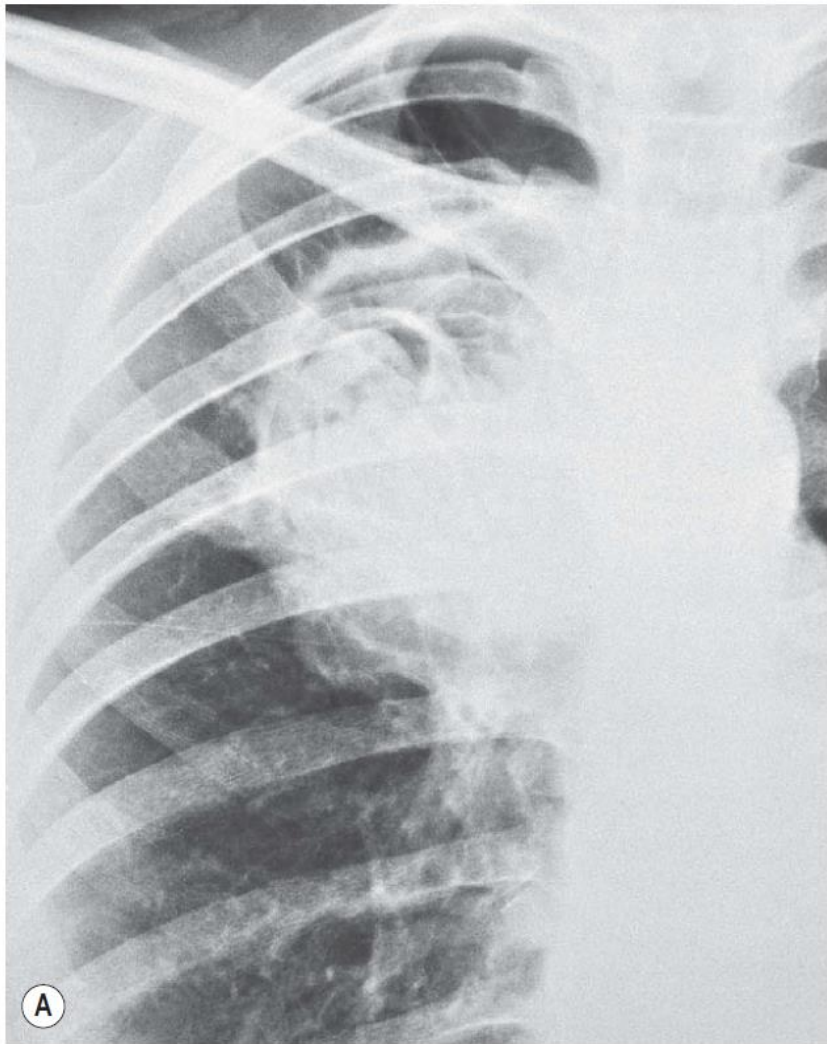
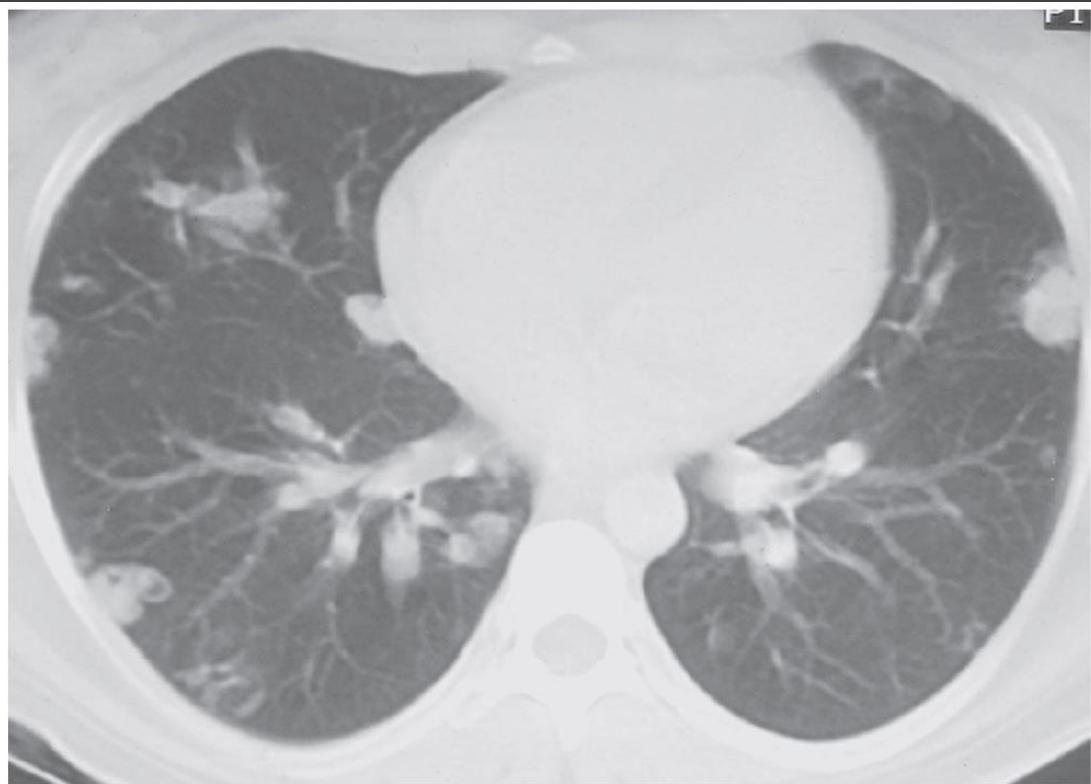
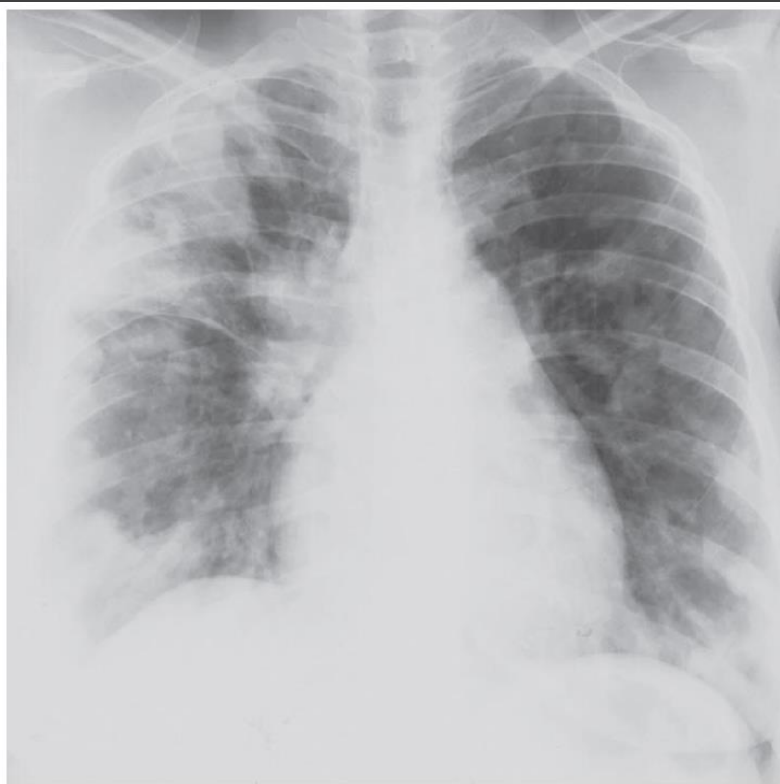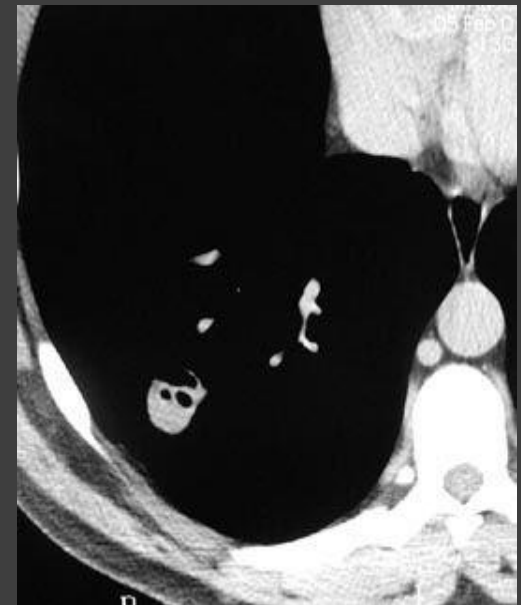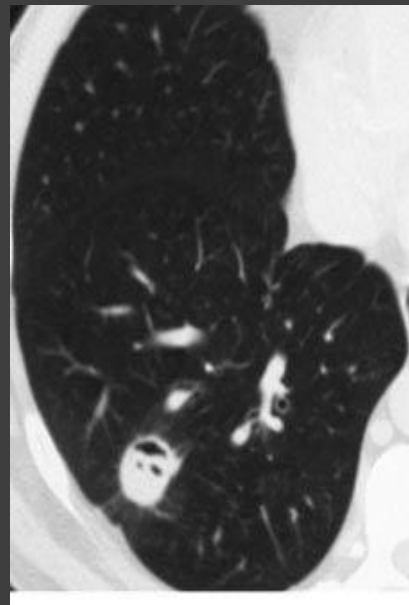
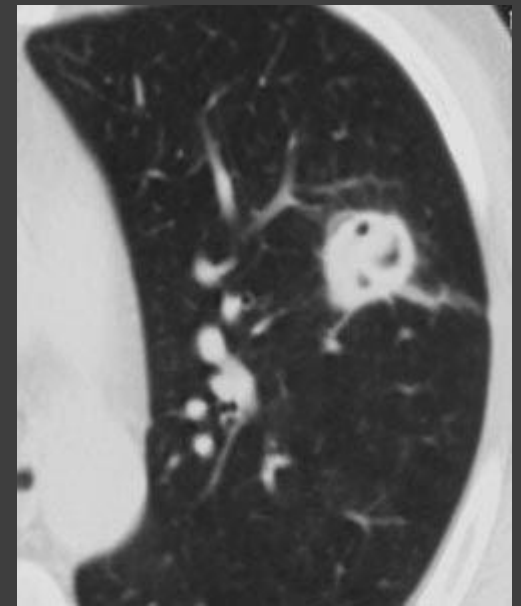
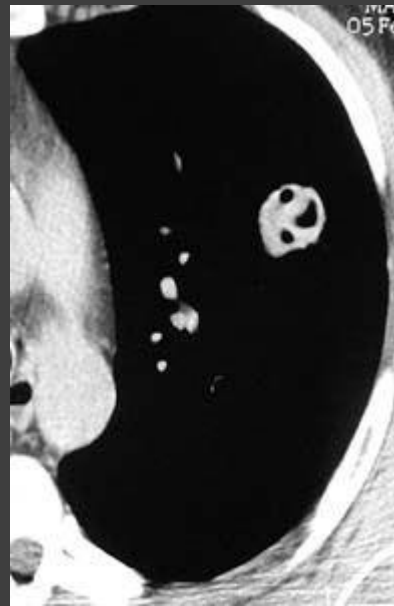


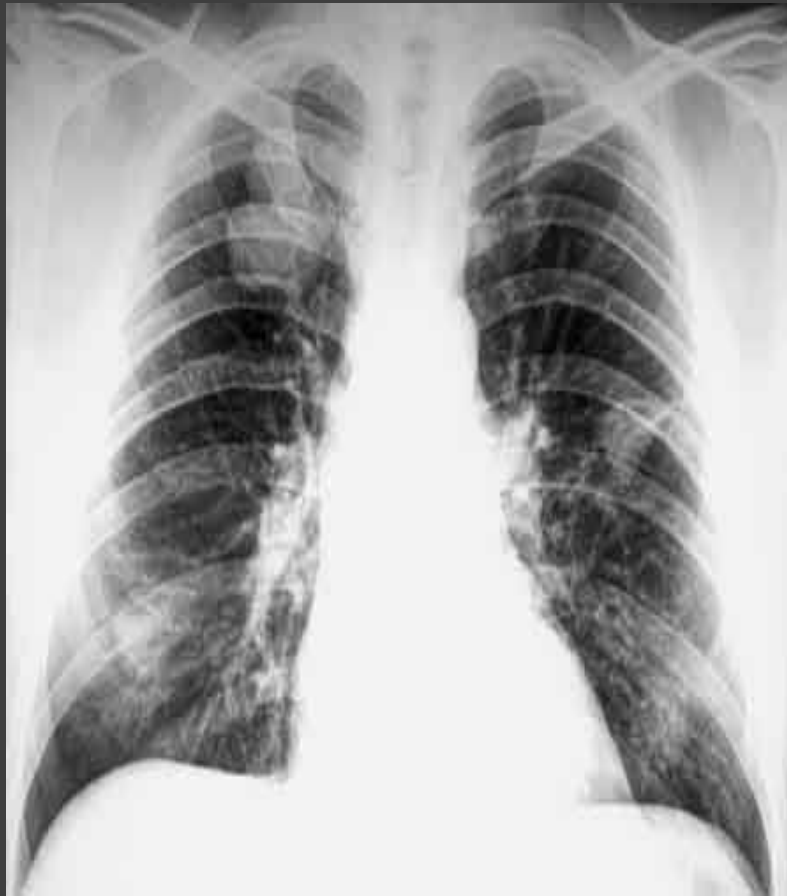Fig. 5.158 Ruptured hydatid cyst. **A**, A complicated mass containing, from above, pericyst, ectocyst, and daughter cyst. There are air crescents between the ectocyst and pericyst and also between the daughter cyst and ectocyst. **B**, Another patient, showing pericyst (yellow arrow) and ectocyst (red arrow) with air between them.

Echinococcosis (Hydatid Cyst)

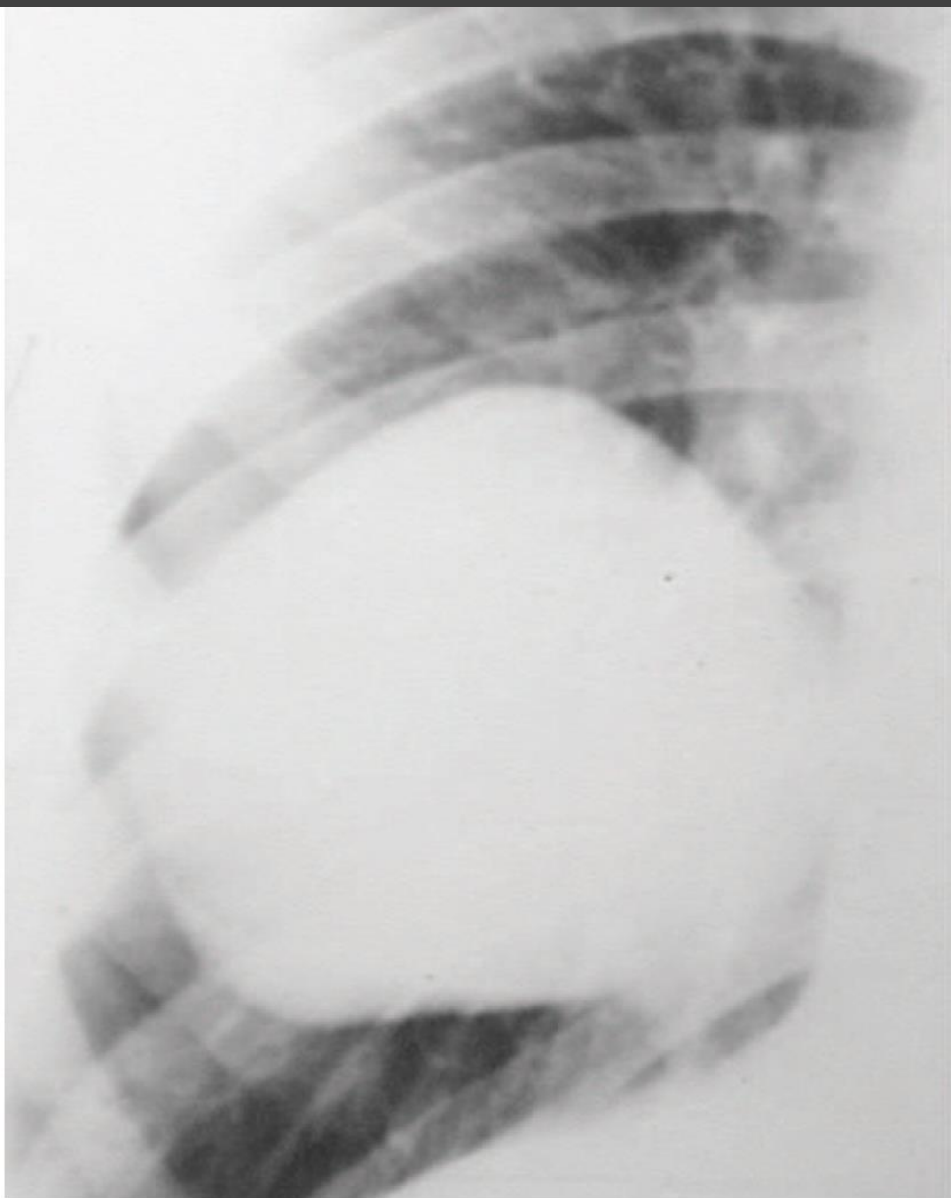


Echinococcosis (Hydatid Cyst)

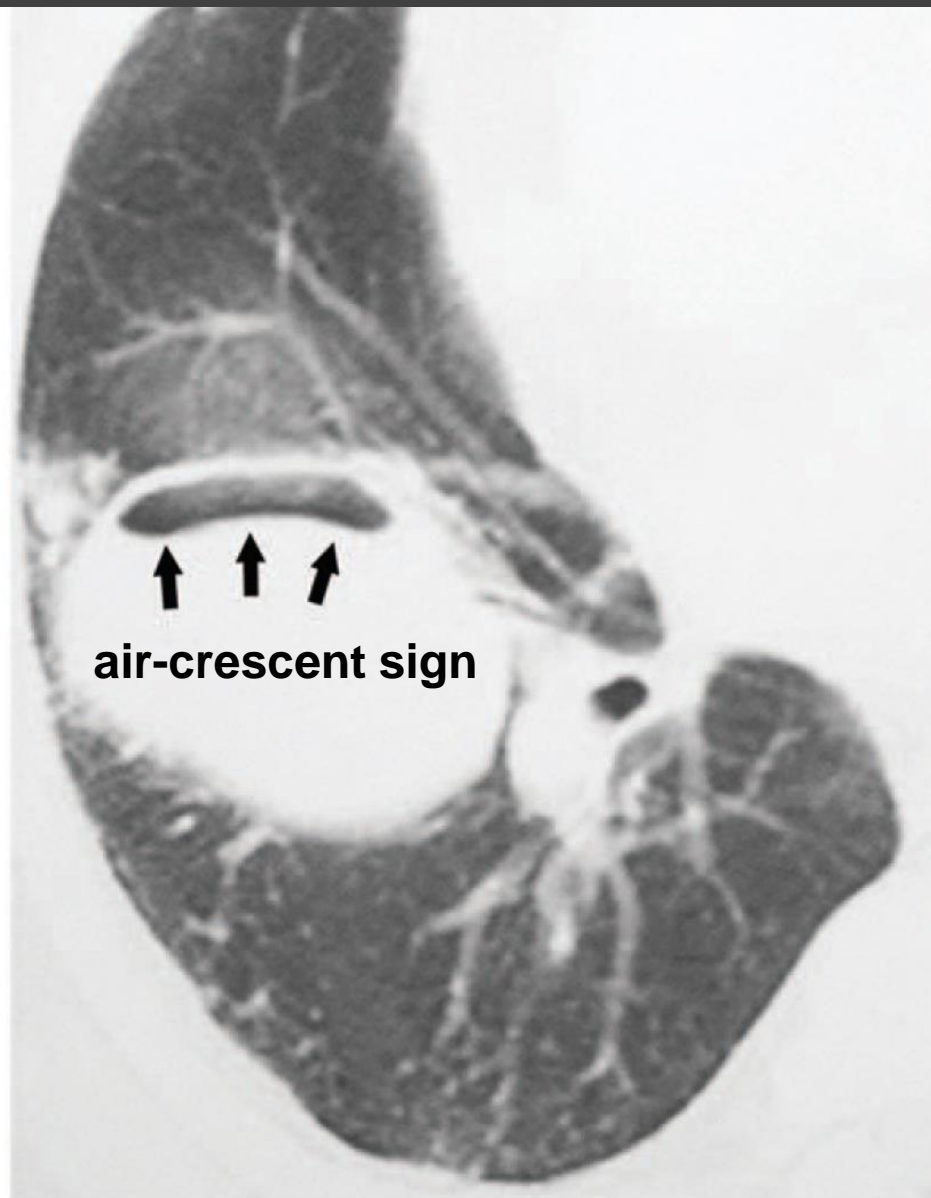


Echinococcosis (條蟲)

- Echinococcosis有些與bronchus有交通，其內容物由支氣管引流出而形成cyst，有些cyst的 fibrous layer (pericyst) 及 laminated layer (endocyst) 之間可見成半月形的空氣 (**air-crescent sign**)。
- 當endocyst 破裂後，其內之液體經由氣道引流而出，此時可見air-fluid level，且fluid level上有laminated layer漂浮於水面上，有如漂浮在水面上的睡蓮，稱為**water-lily sign**。如果fluid完全咳出，則裡頭殘留的solid part會落到dependent portion處，稱為**mass within a cavity sign**

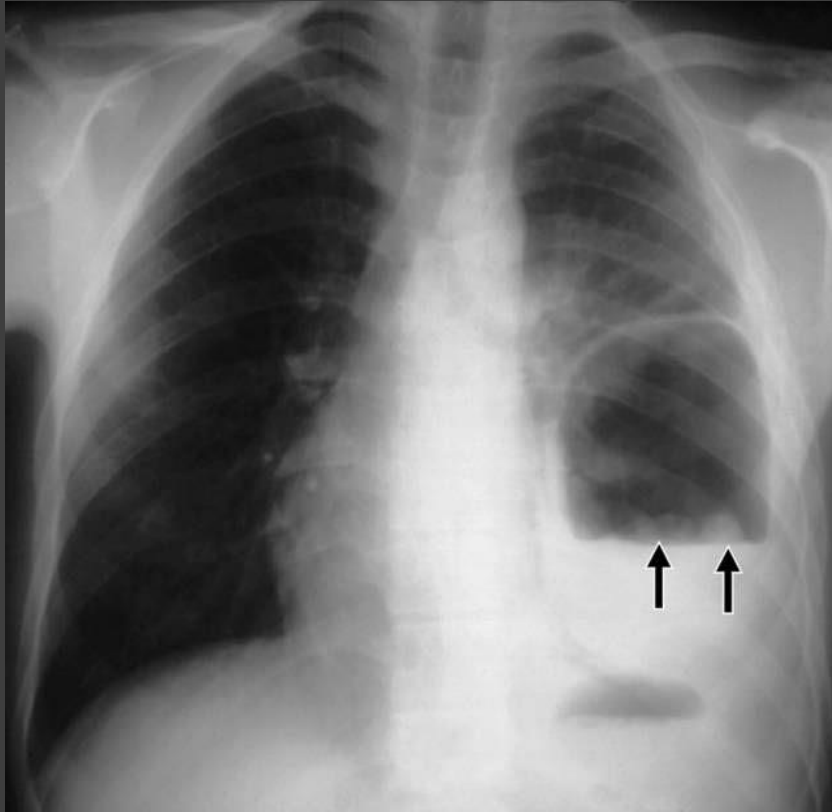


22.

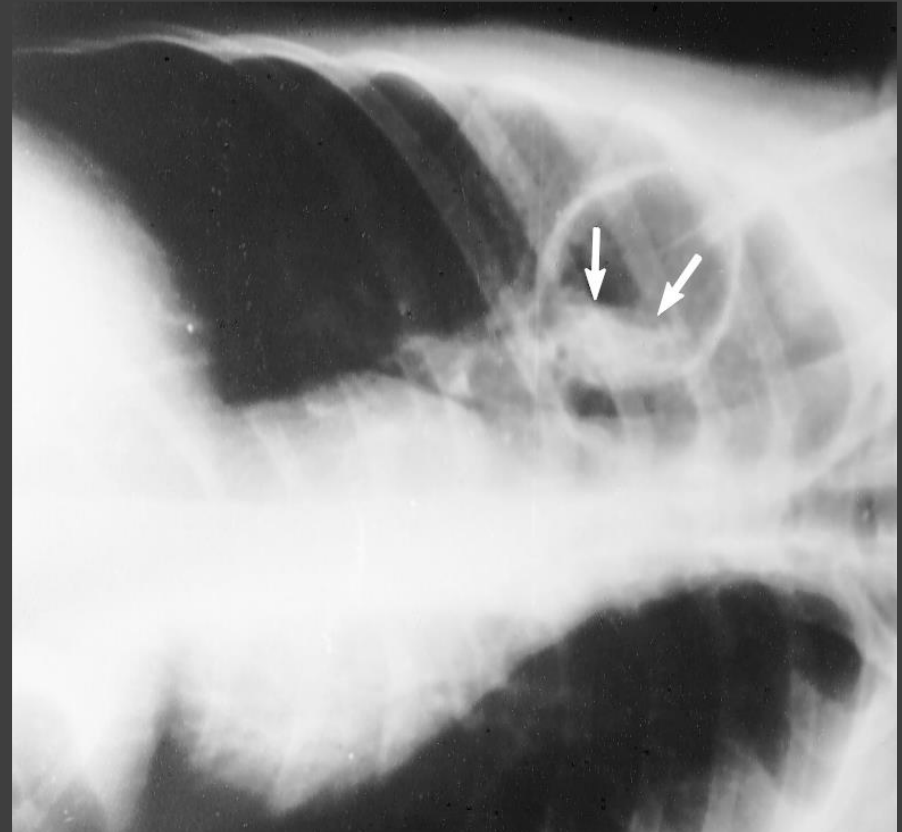


23a.

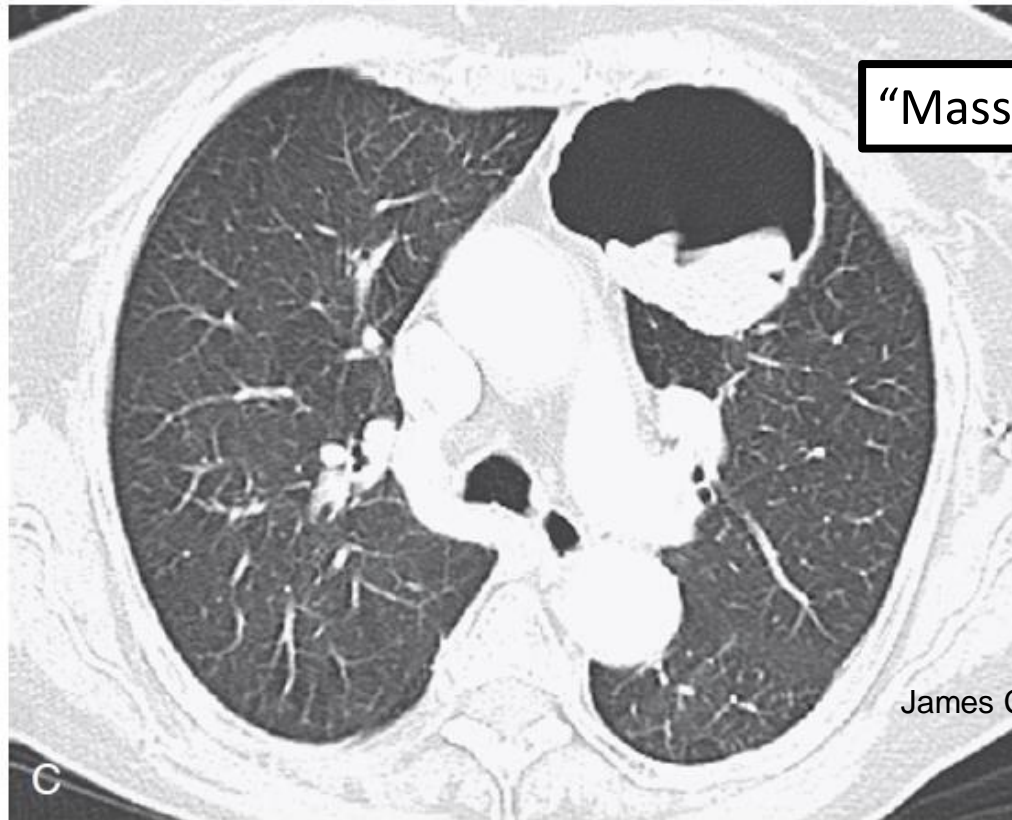
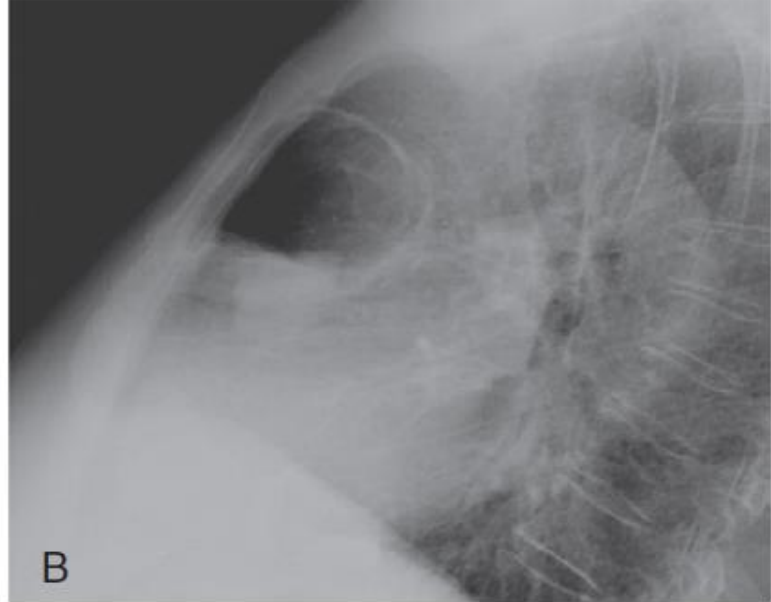
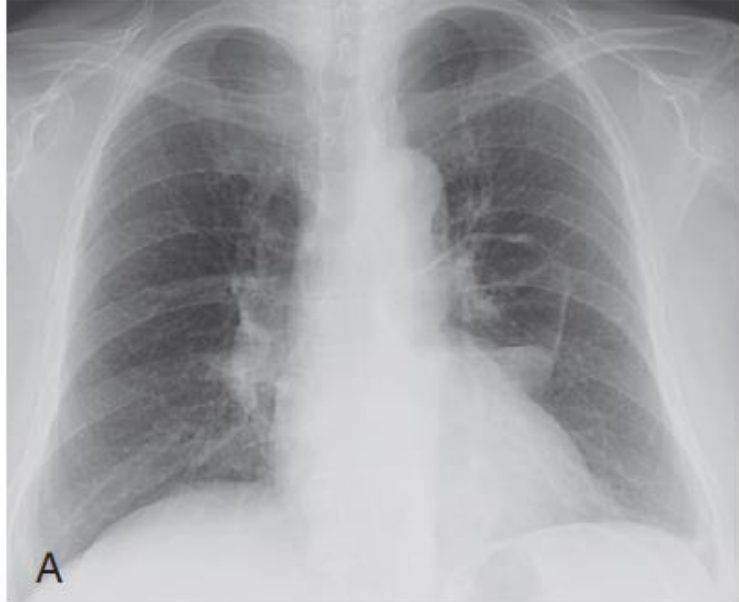Echinococcosis (Hydatid Cyst)



Water-lily sign



“Mass within a cavity” sign



“Mass within a cavity”

Inhalation Diseases

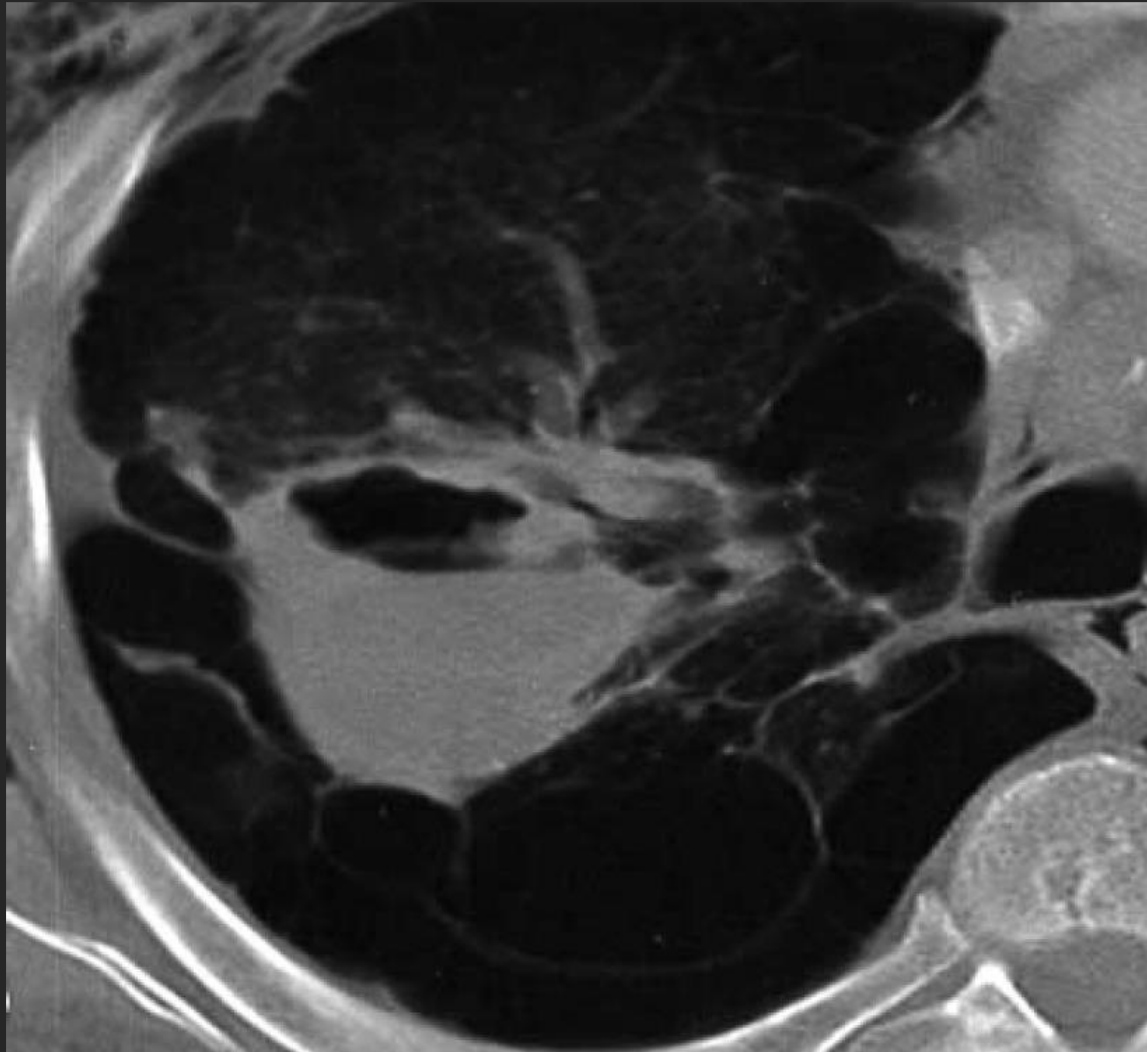
■ Pneumoconiosis:

- Ischemic necrosis of the conglomerated mass

■ Silicosis:

- May cavitation by itself, but less frequent
- Most likely due to **TB superinfection**
TB must be ruled out in all patients with silicosis + cavitation

coal worker's pneumoconiosis



air–fluid level within liquefied progressive massive fibrosis of 6 cm diameter.

Cystic Lesions

Solitary:

- Pneumatocele
- Bullae
- Cyst
 - Bronchogenic cyst
 - Intrapulmonary sequestration

Multiple: 4L-P-2B-2C

- LIP
- LAM
- PLCH
- Laryngeal papillomatosis
- Pneumatocele
- Bullae
- Bowel herniation
- Cystic bronchiectasis
- CCAM

■ C: cancer

- Primary bronchogenic carcinoma: most frequently SCC
- Pulmonary metastasis: most frequently SCC, also adenocarcinoma, sarcoma

■ A: autoimmune;

- Wegener Granulomatosis, rheumatoid arthritis (rheumatoid nodules) etc.

■ V: vascular (both bland and septic pulmonary emboli)

■ I: infection (bacterial/fungal) / inhalation

- pulmonary abscess
- fungal / parasite infection
- pulmonary tuberculosis
- pneumoconiosis

■ T: trauma - pneumatoceles

■ Y: youth

- CPAM (congenital pulmonary airway malformation)
- pulmonary sequestration
- bronchogenic cyst

Pneumatocele

- **A thin wall space**, caused by
 - **infection**: *S. aureus* in **infants** & children
PCP in AIDS
 - **trauma**
- Invariably transient
- Mechanism:
 - **Check valve** obstruction of the airways
 - Subpleural collection of air, dissection occurs through the interstitium of the lung

R

Post pneumonia pneumatocele

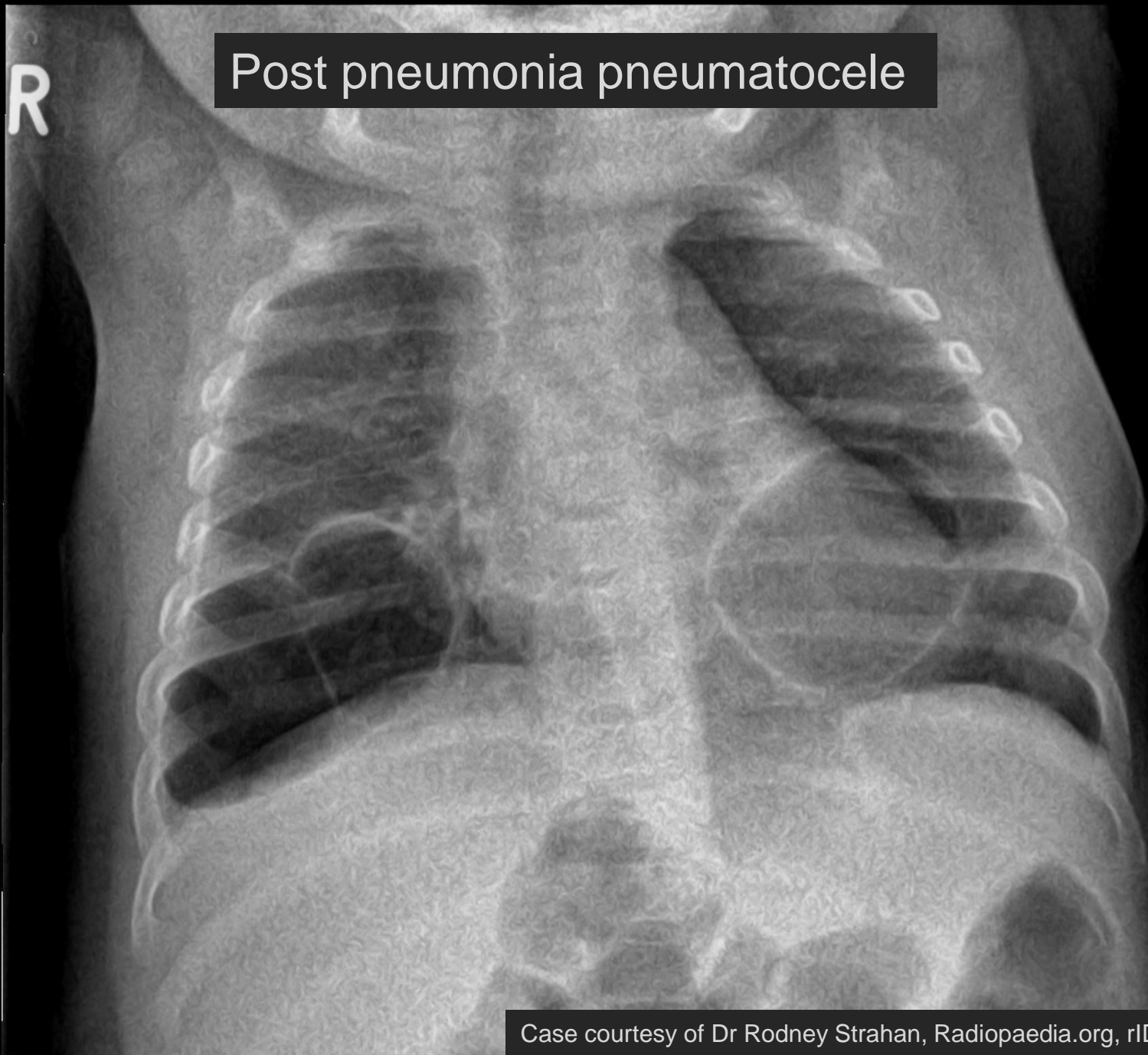

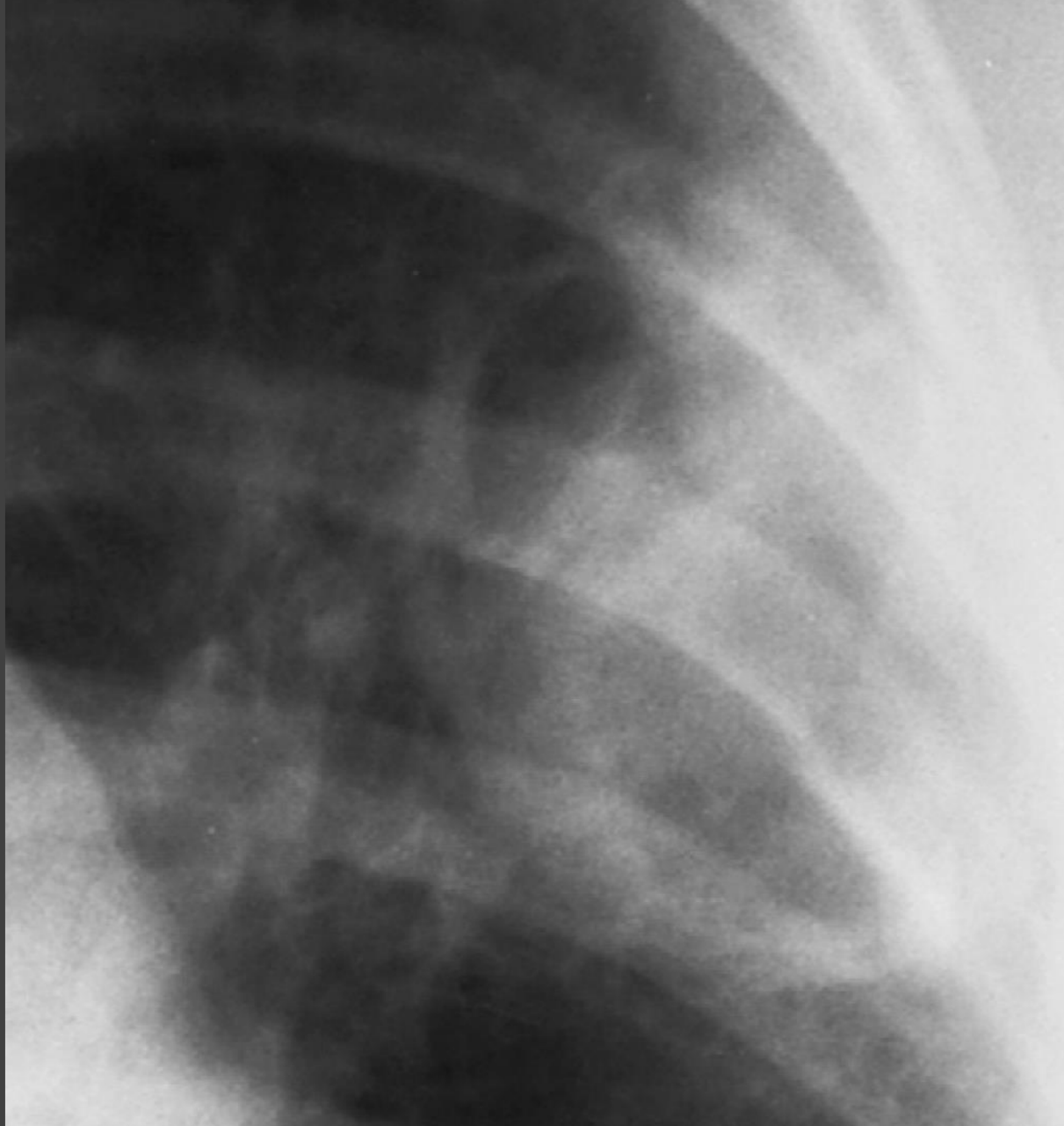
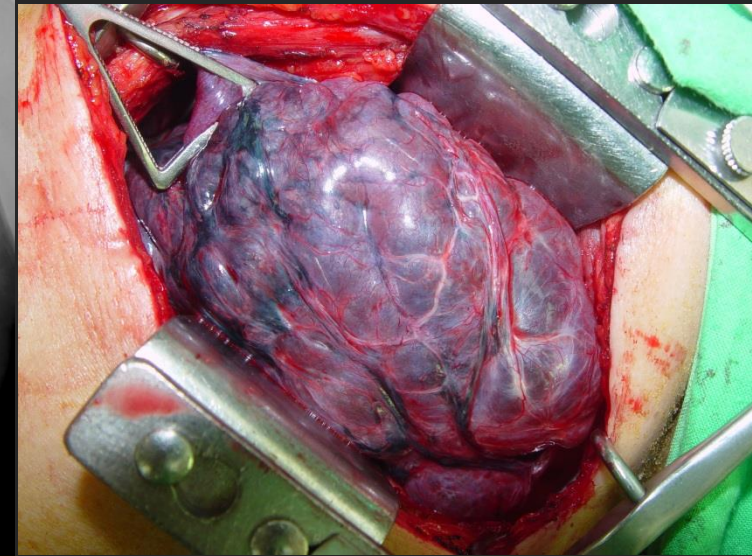
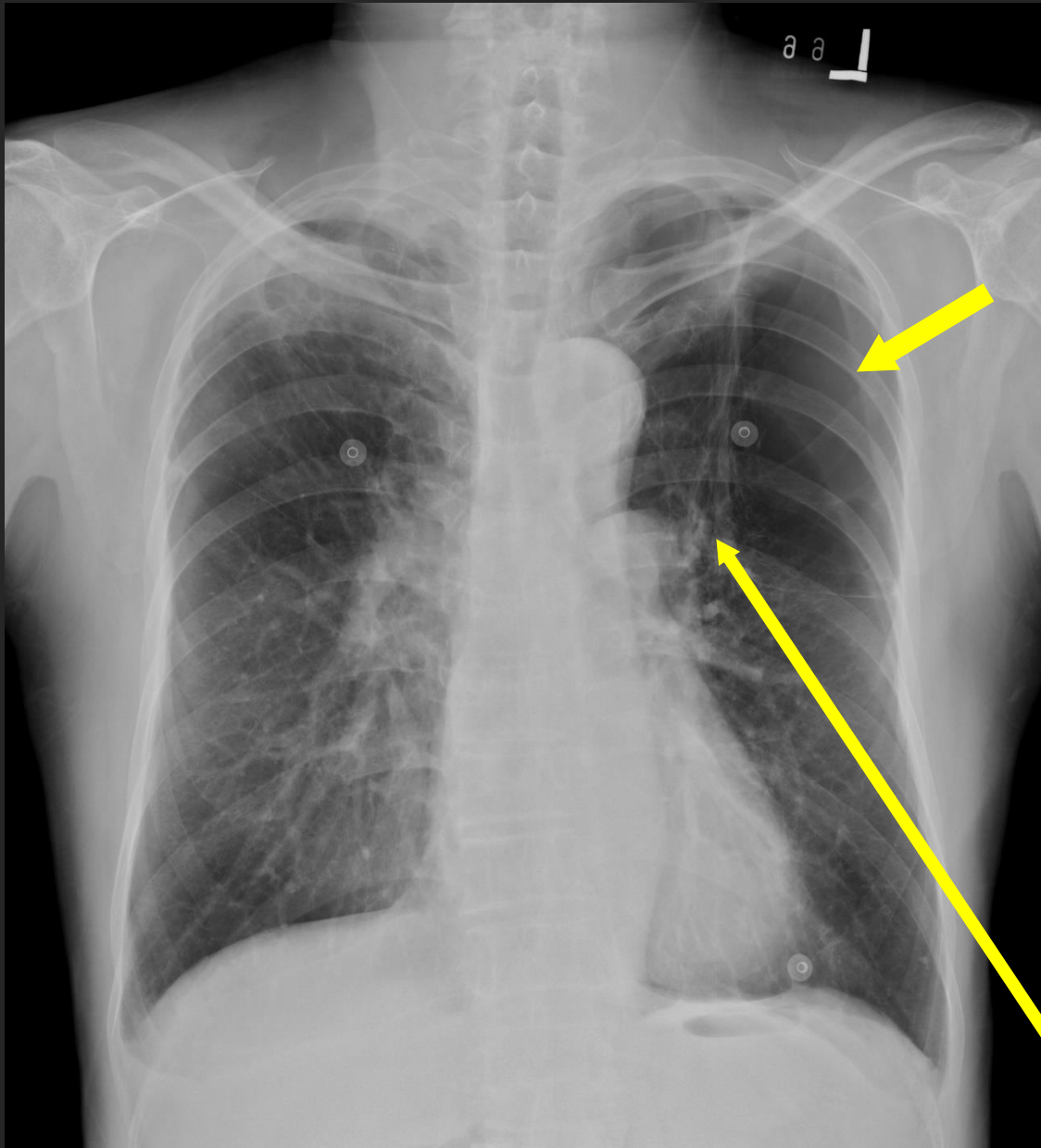


Figure 23-12 This lucency developed in an area of consolidation that resulted from pulmonary contusion following a crush injury to the left chest. This is a so-called *traumatic lung cyst* or *pneumatocele*.

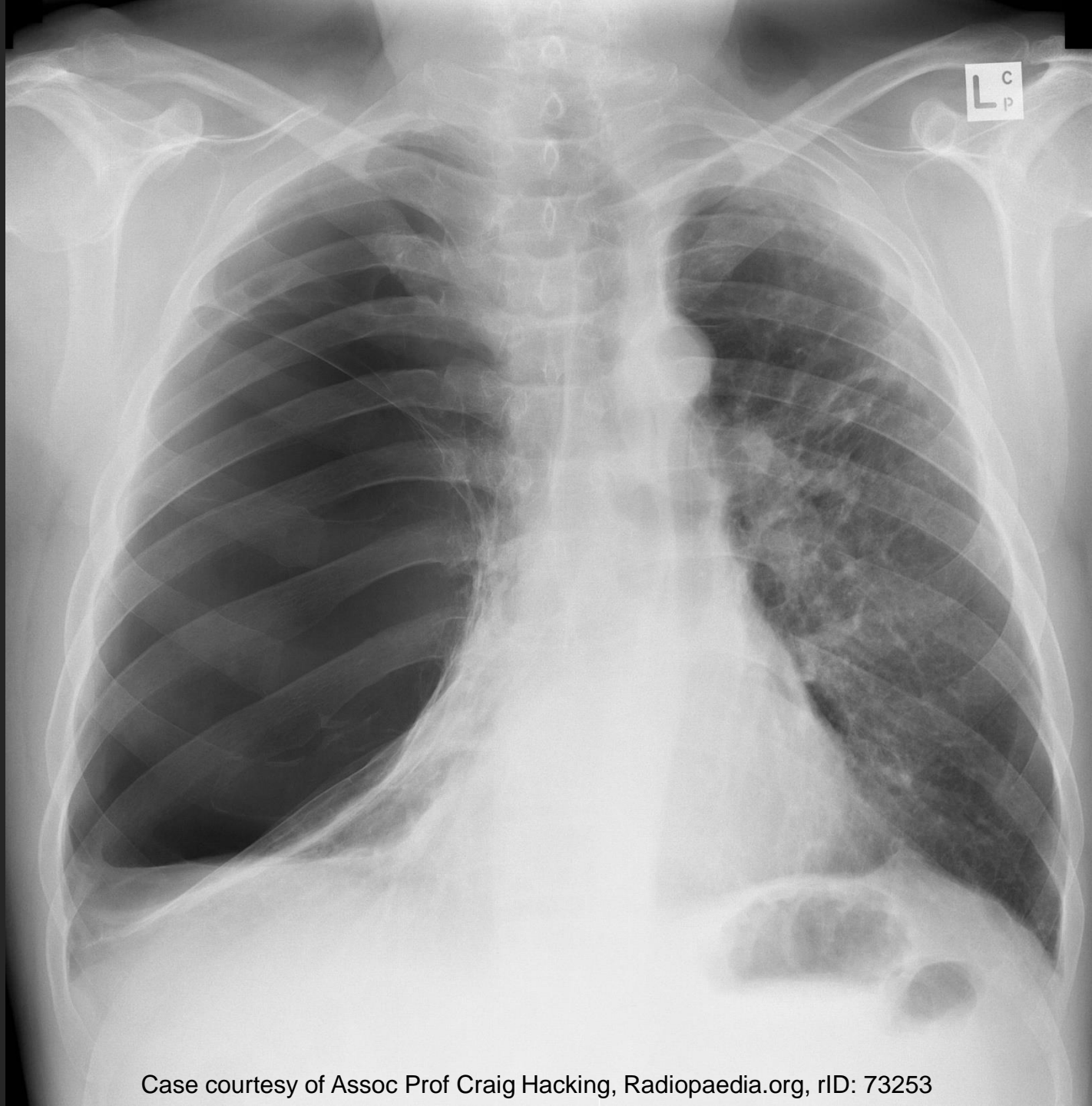Bulla

- A **sharp-demarcated, air-containing space ≥ 1 cm in diameter** that possess a **smooth wall ≤ 1 mm in thickness**.
- Usually occurs with other lung disease (**emphysema or infection**).
- If caused by infection, frequent with adjacent parenchymal scarring °
- Secondary sign: **compression or displacement of adjacent structures** (lung and mediastinum).
- Bullae are characteristically poorly ventilated and unperfused.

Bullae



compression or
displacement of
adjacent structures



Bleb

- Localized collection of air located **within the pleura.**
- Most common occurs over **lung apex, diameter < 1 cm.**
- Mechanism: alveolus rupture -> air dissection through interstitial tissue into the thin fibrous layer of visceral pleura.

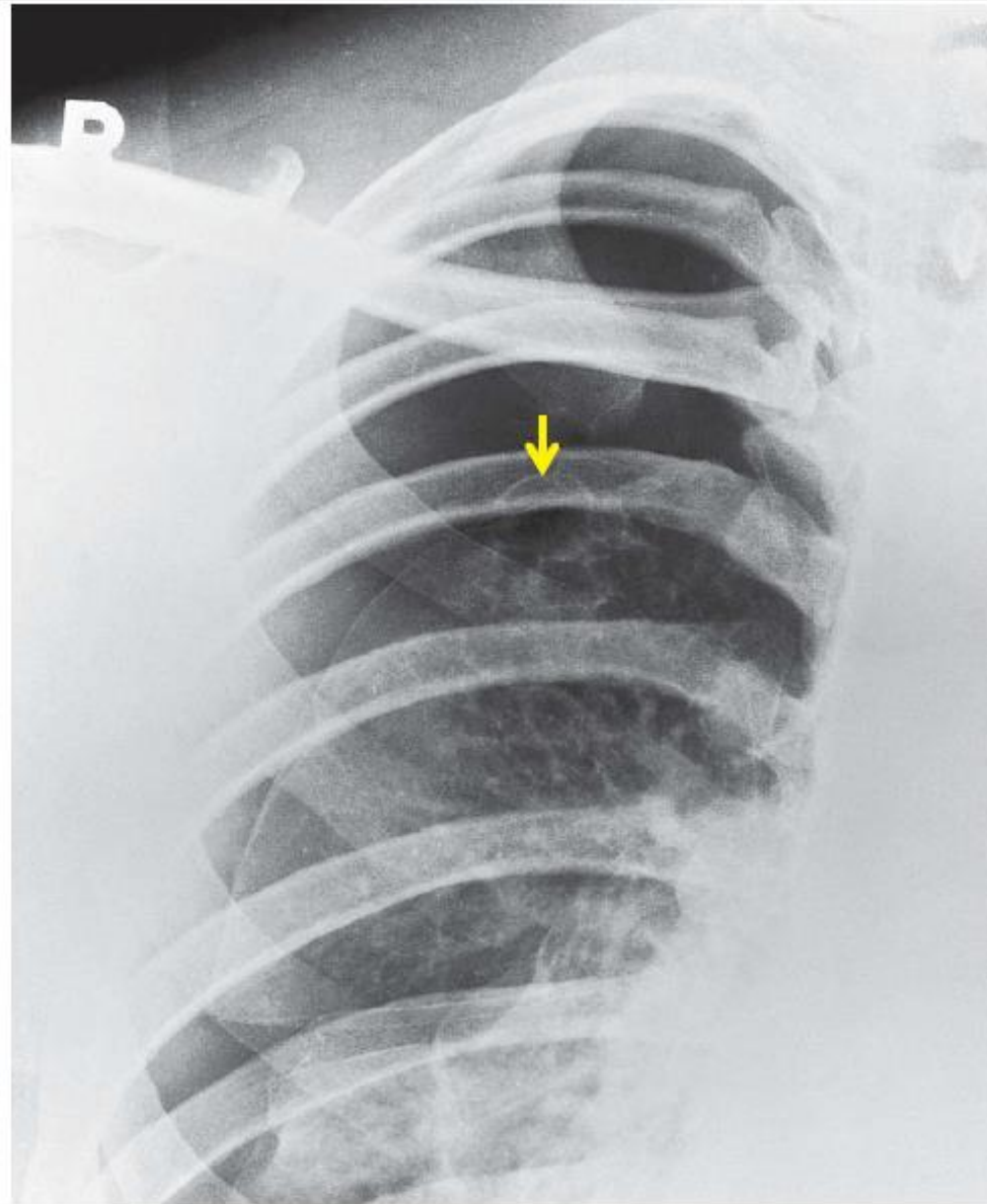
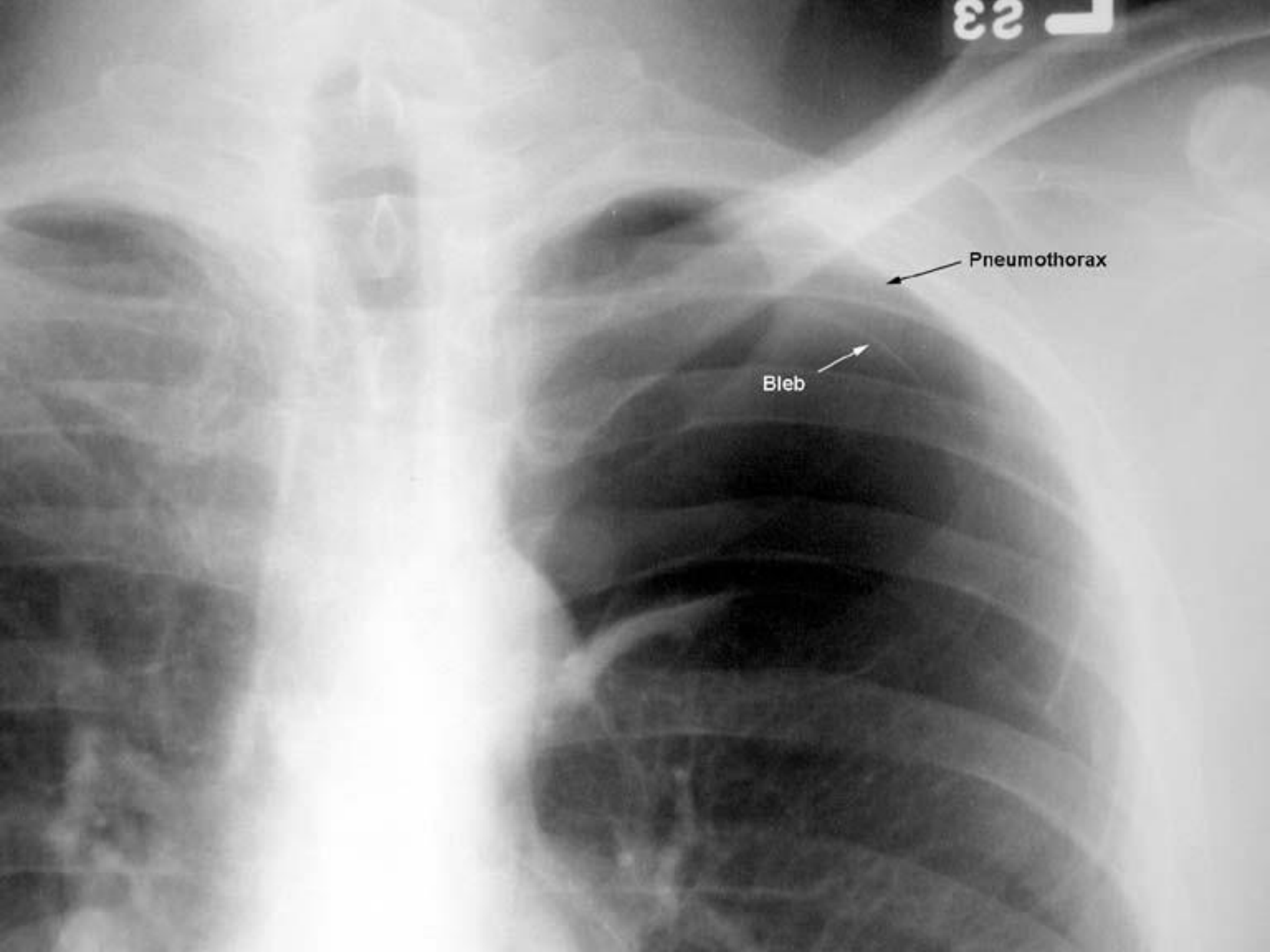


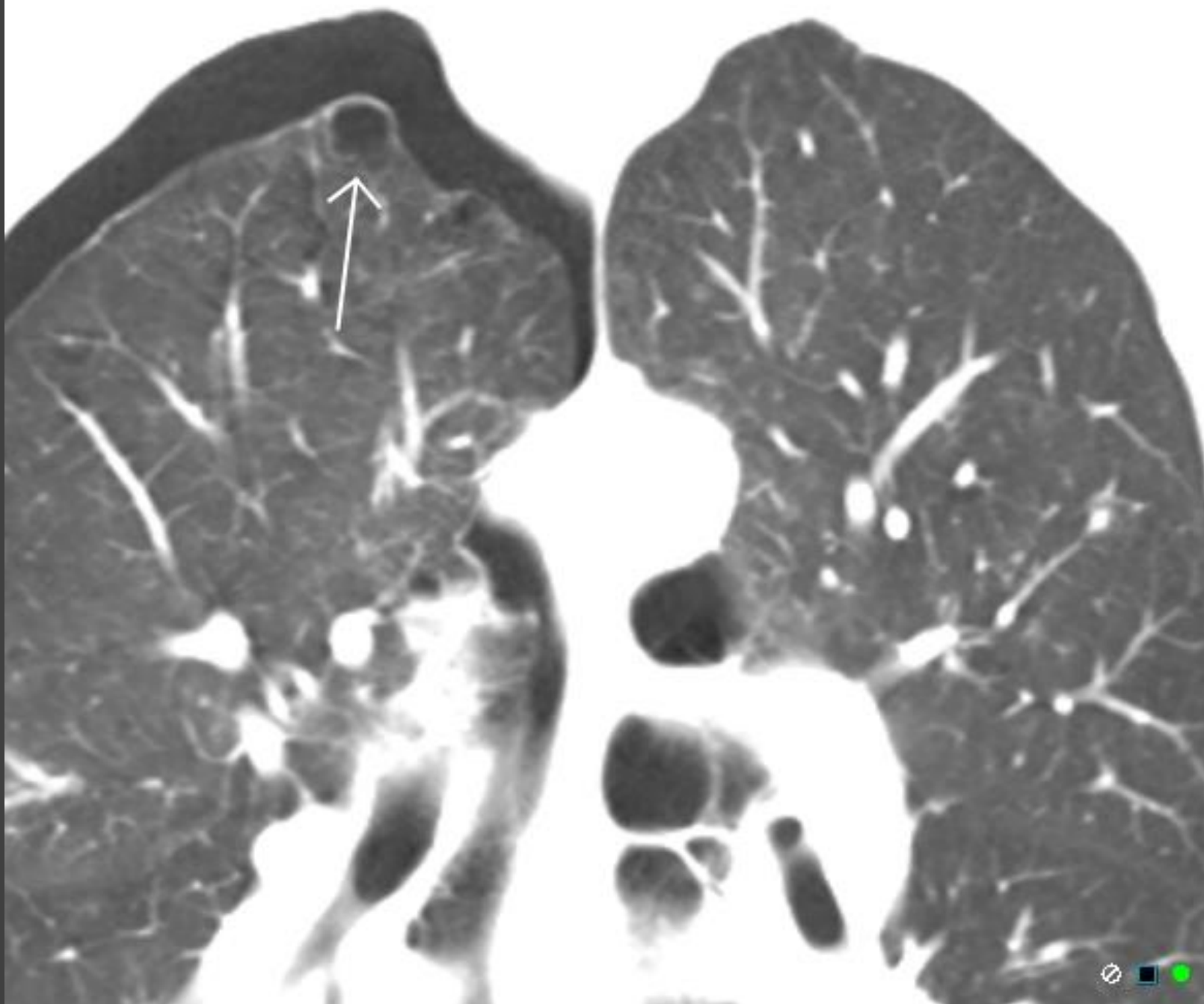
Fig. 15.56 Primary spontaneous pneumothorax. Visceral pleural line is clearly demonstrated together with lateral avascular space. There is a pleural bleb at the apex of the lung (arrow), a common finding. Such blebs are usually not detectable when the lung reexpands.



22

Pneumothorax

Bleb



■ C: cancer

- Primary bronchogenic carcinoma: most frequently SCC
- Pulmonary metastasis: most frequently SCC, also adenocarcinoma, sarcoma

■ A: autoimmune;

- Wegener Granulomatosis, rheumatoid arthritis (rheumatoid nodules) etc.

■ V: vascular (both bland and septic pulmonary emboli)

■ I: infection (bacterial/fungal) / inhalation

- pulmonary abscess
- fungal / parasite infection
- pulmonary tuberculosis
- pneumoconiosis

■ T: trauma - pneumatoceles

■ Y: youth

- CPAM (congenital pulmonary airway malformation)
- pulmonary sequestration
- bronchogenic cyst

Bronchogenic Cysts

- Mechanism
 - congenital **malformations** of the bronchial tree (a type of bronchopulmonary foregut malformation).
- Usually **solitary, thin-walled, and spherical**
- Filled with mucoid or serous fluid and do not communicate with the airways unless infected.
- Pathology:
 - The wall **typically contains cartilage and smooth muscle** (important for diagnosis)

Bronchogenic Cysts

■ Mediastinal bronchogenic cyst (65-90%)

- 位置：中縱膈腔，
 - carinal area: ~50%
 - paratracheal area: ~20%
 - oropharyngeal wall: ~15%
 - retrocardiac area: ~10%
- Rarely communicates with airways
- Well-defined, homogeneous mass-like opacity

■ Pulmonary bronchogenic cyst

- typically **perihilar**, predilection for **lower lobes**
- Well-defined, homogeneous mass-like opacity
- Cystic when communicating with airway or esophagus

Box 16.8 Bronchogenic cysts

Pathology

- Single cyst lined by respiratory epithelium
- Contains mucoid material
- Associated anomalies – rare
- Location – 85% hilar or mediastinal

Clinical features

- May be asymptomatic
- Otherwise chest pain, cough, dyspnea, and fever if cyst is infected
- Rarely compressive effects, e.g. atelectasis, postobstructive pneumonia
- Treatment – usually surgical excision

Chest radiographs

- Well-circumscribed hilar or middle mediastinal mass
- Air–fluid level if cyst is communicating or infected
- Less commonly, a well-circumscribed lung mass – solid or containing an air–fluid level.

Chest CT

- Well-circumscribed mass usually adjacent to trachea or major bronchi
- Molded to adjacent structures without remarkable compressive effects
- Variable CT density of cyst contents –10 HU to +120 HU or even higher
- About half of water, half of soft tissue attenuation
- Cyst wall thin and smooth
- Cyst may contain milk of calcium or wall calcification
- Gas content indicates communication or infection

Bronchogenic Cyst

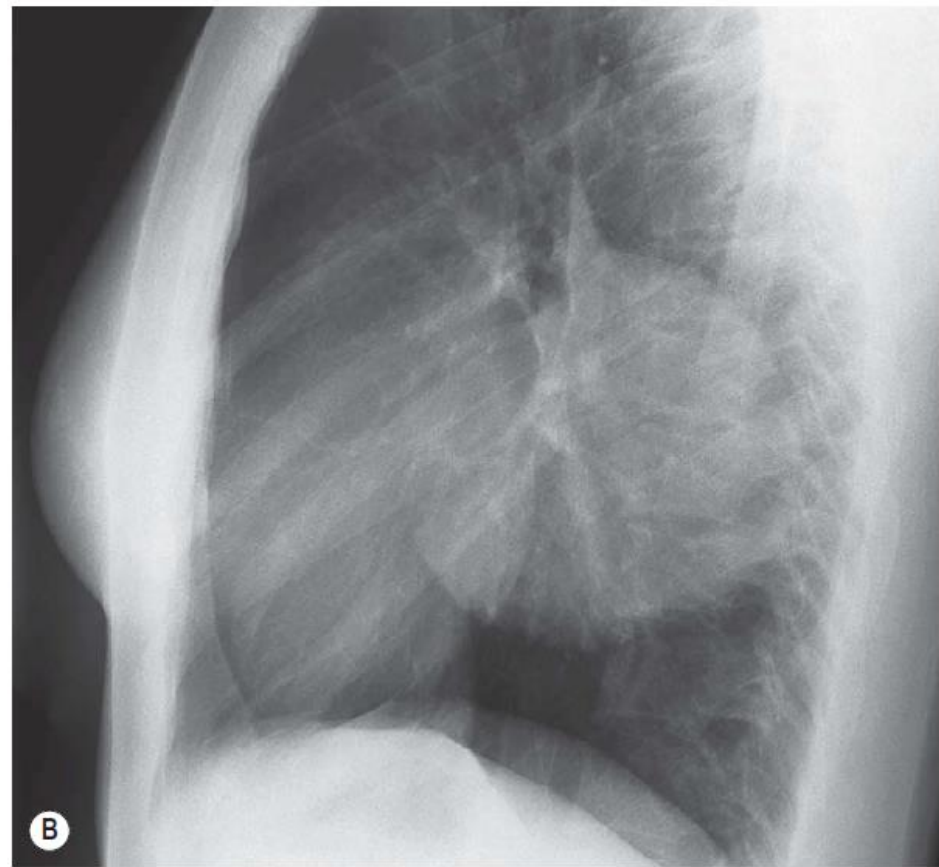
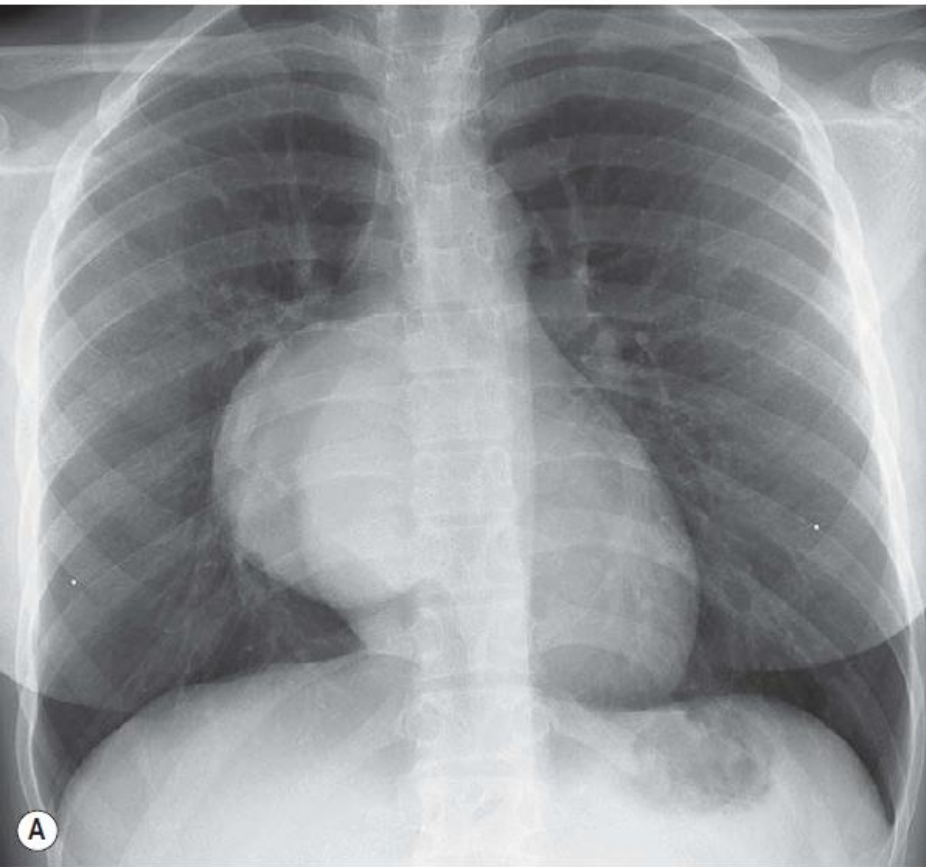


Fig. 16.32 Bronchogenic cyst in a young woman with cough. **A**, Frontal and **B**, lateral chest radiographs show a large, smooth, well-margined mass in the middle mediastinum – the most common location for a bronchogenic cyst.

Bronchogenic Cyst

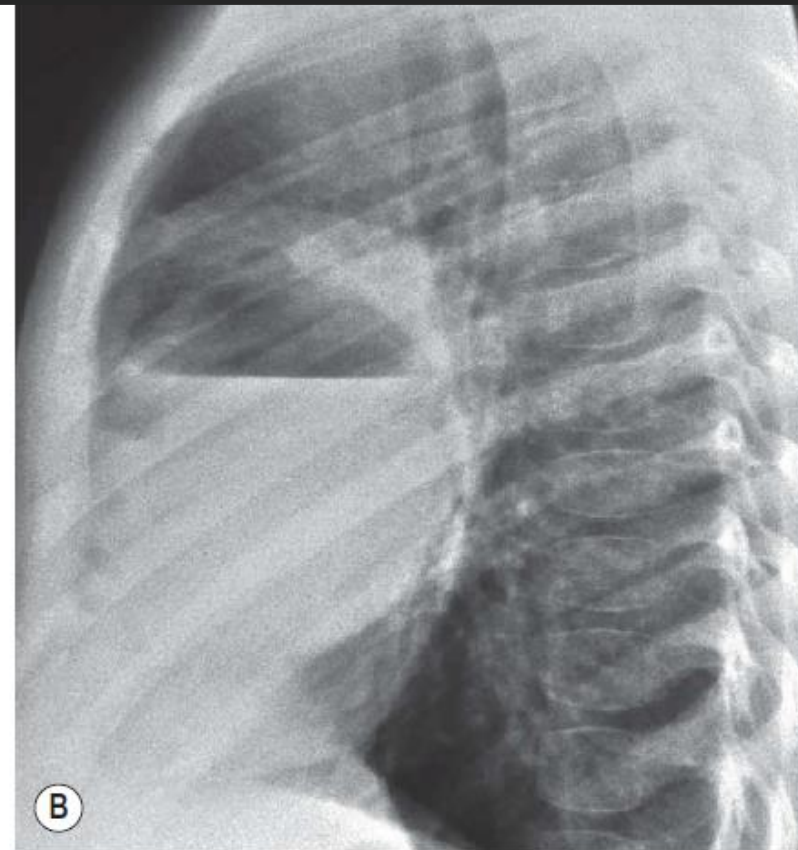
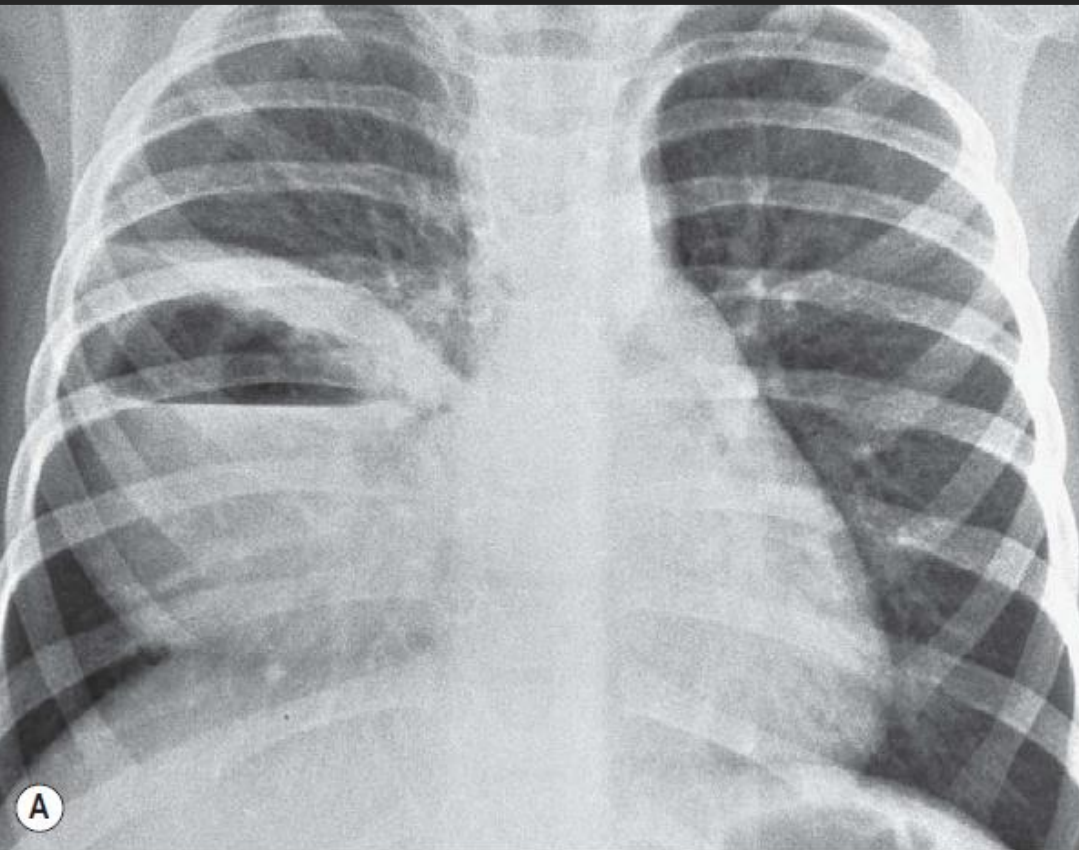
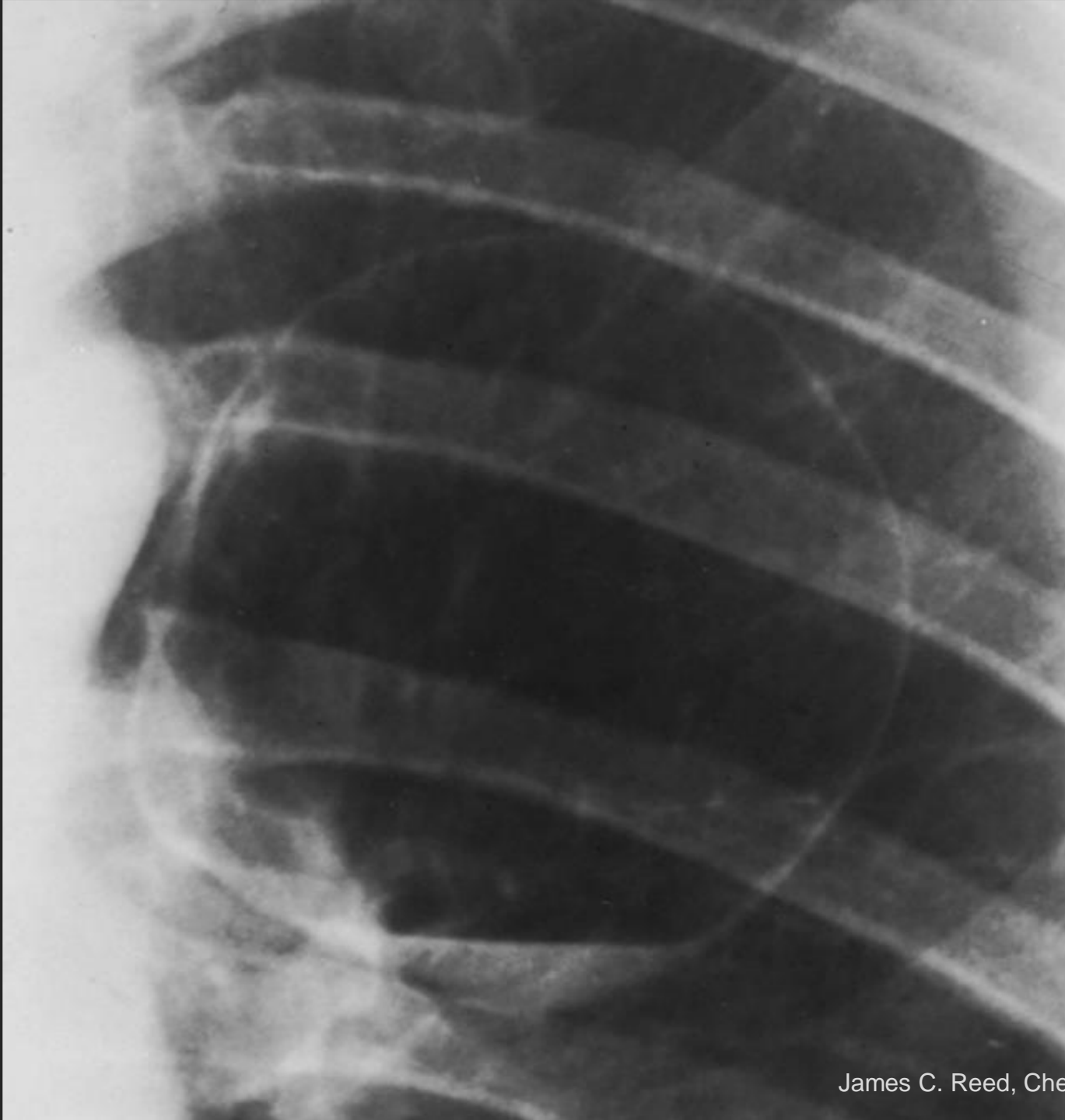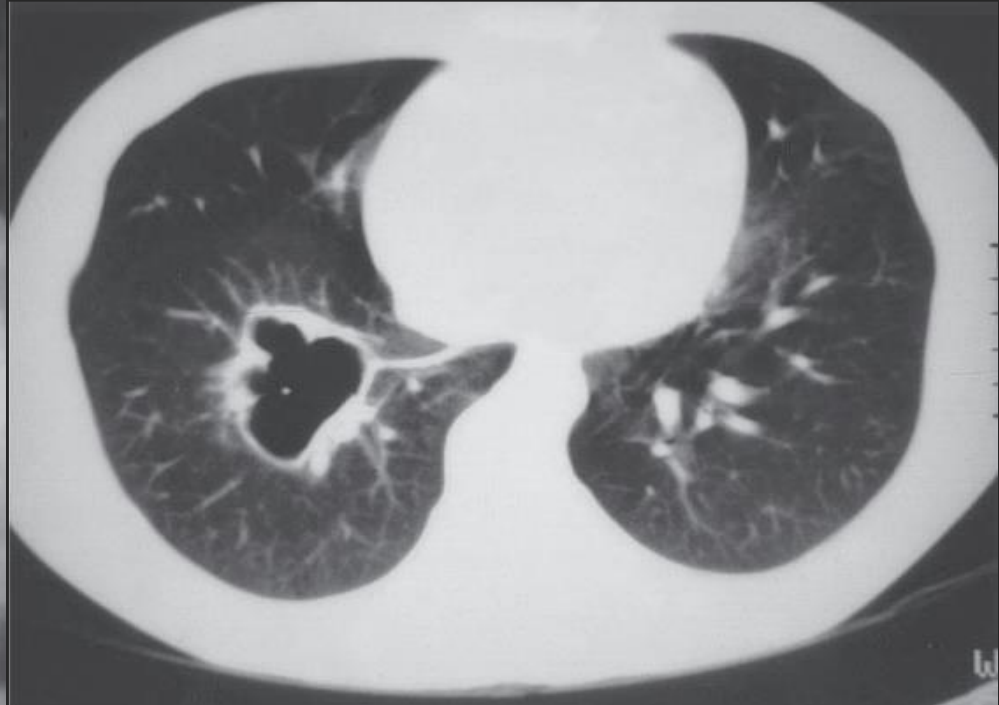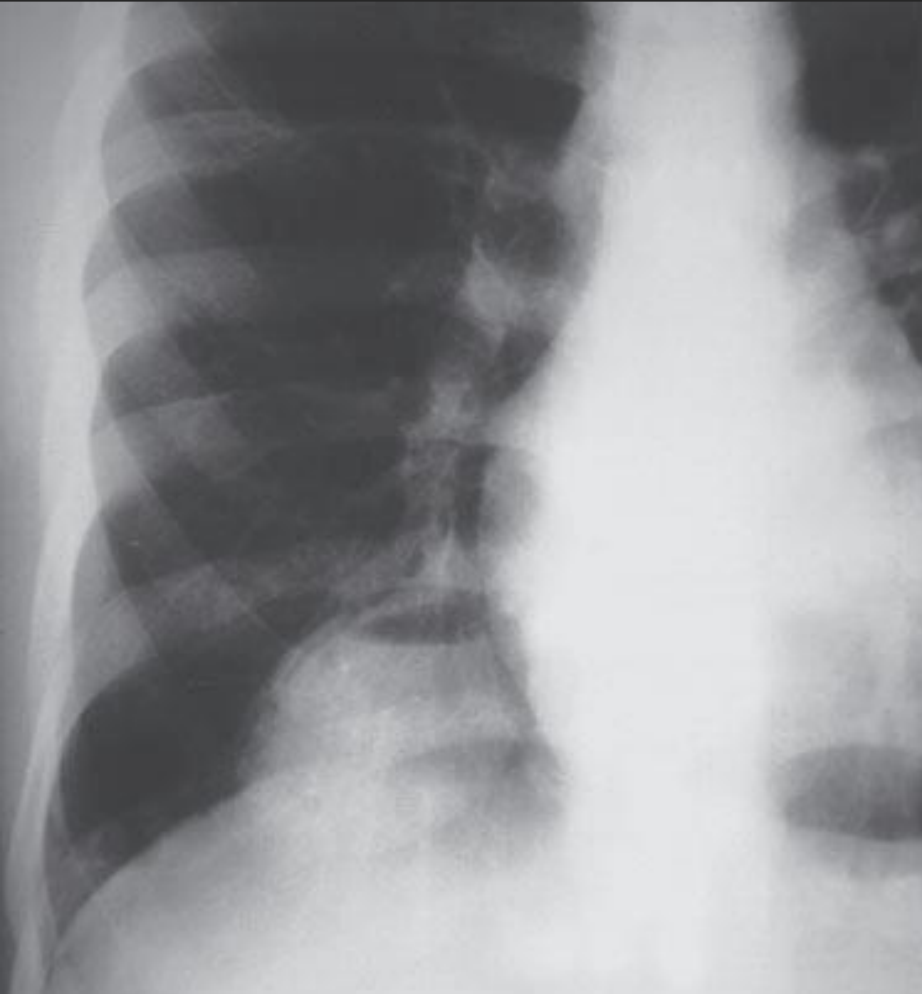


Fig. 16.33 Infected intrapulmonary bronchogenic cyst in a child. **A**, Frontal and **B**, lateral chest radiographs show a large right-sided intrapulmonary mass with an air–fluid level. The cyst wall is thickened by inflammation.



Bronchogenic Cyst



Pulmonary Sequestration(游離肺)

- intralobar(75%), extralobar(25%)

- **Intralobar:**

- Almost always within lower lobe; **Left** > Right
- Shares the visceral pleura of an normal lung
 - 與其它正常之肺葉共同包於一臟層肋膜(visceral pleura)
- Lacks a normal communication to the tracheobronchial tree.
 - 其血流供應來自於體循環（主動脈）之分枝，而非肺動脈
- Supplying vessels:
 - A - aortic branch; V - pulmonary v. → LA
- Most intralobar sequestration appear to have an acquired origin, which a portion of lung that has acquired a systemic blood supply subsequent to **chronic post-obstructive pneumonia**.

Intralobar Sequestration

Does not have a normal connection to the tracheo-bronchial tree.

A systemic artery typically arises from the distal thoracic aorta (A) to supply the lesion

肺在胚胎期的發生過程中，形成一獨立肺葉，其血流供應來自於體循環（主動脈）之分枝，而非肺動脈

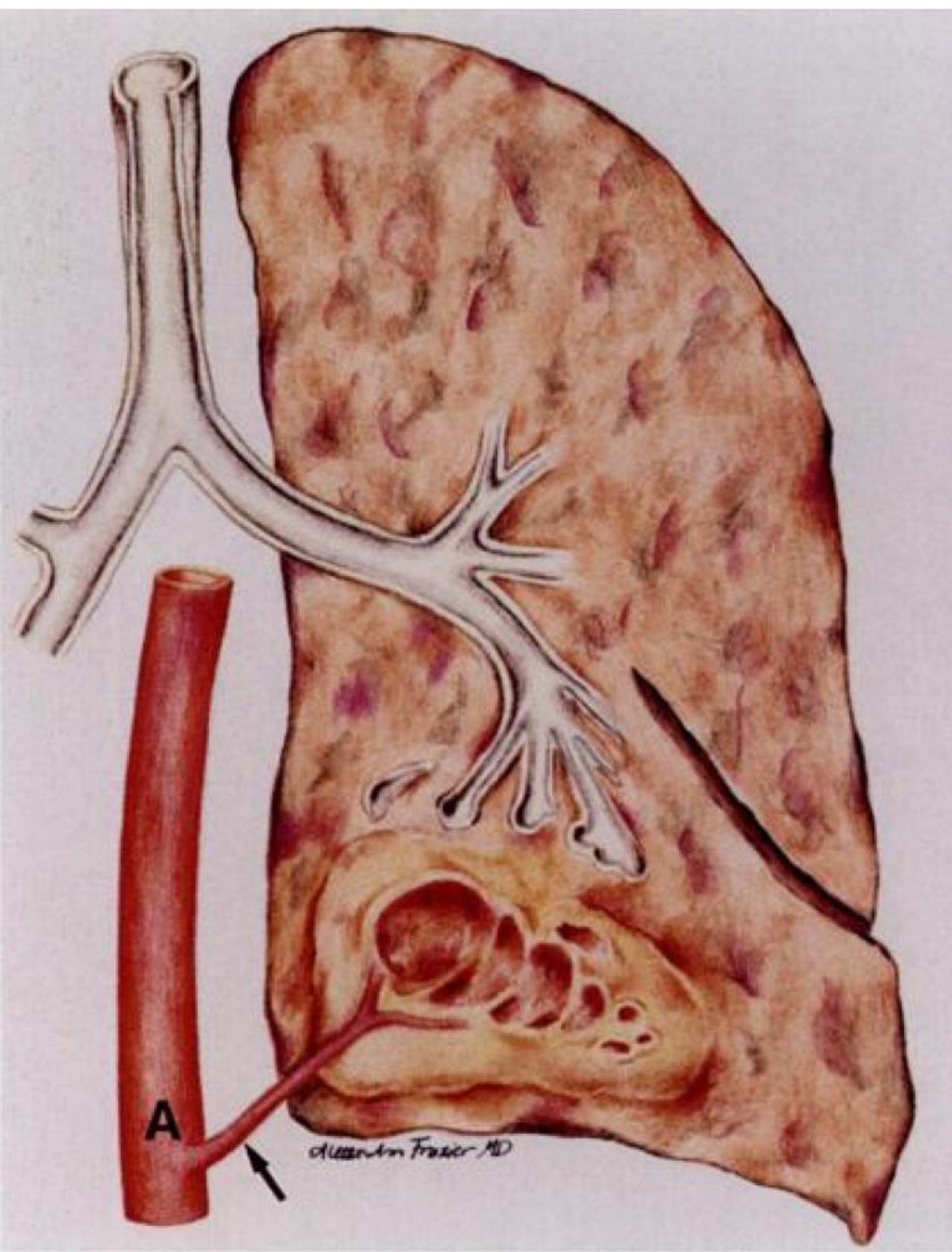


Table 16.2 Intralobar versus extralobar sequestration

Parameter	Intralobar sequestration	Extralobar sequestration
Etiology	Chronic infection, congenital	Congenital
Relation to normal lung	Within normal lung	Separate with own pleural covering
Venous drainage	Pulmonary	Systemic
Side affected	Left 60–70%	Left 90%
Associated congenital anomalies	Uncommon	Frequent
Age at diagnosis	50% by age 20	60% in first year
Sex ratio	M = F	M/F = 4 : 1
Infection or communication with normal lung	Common	Rare

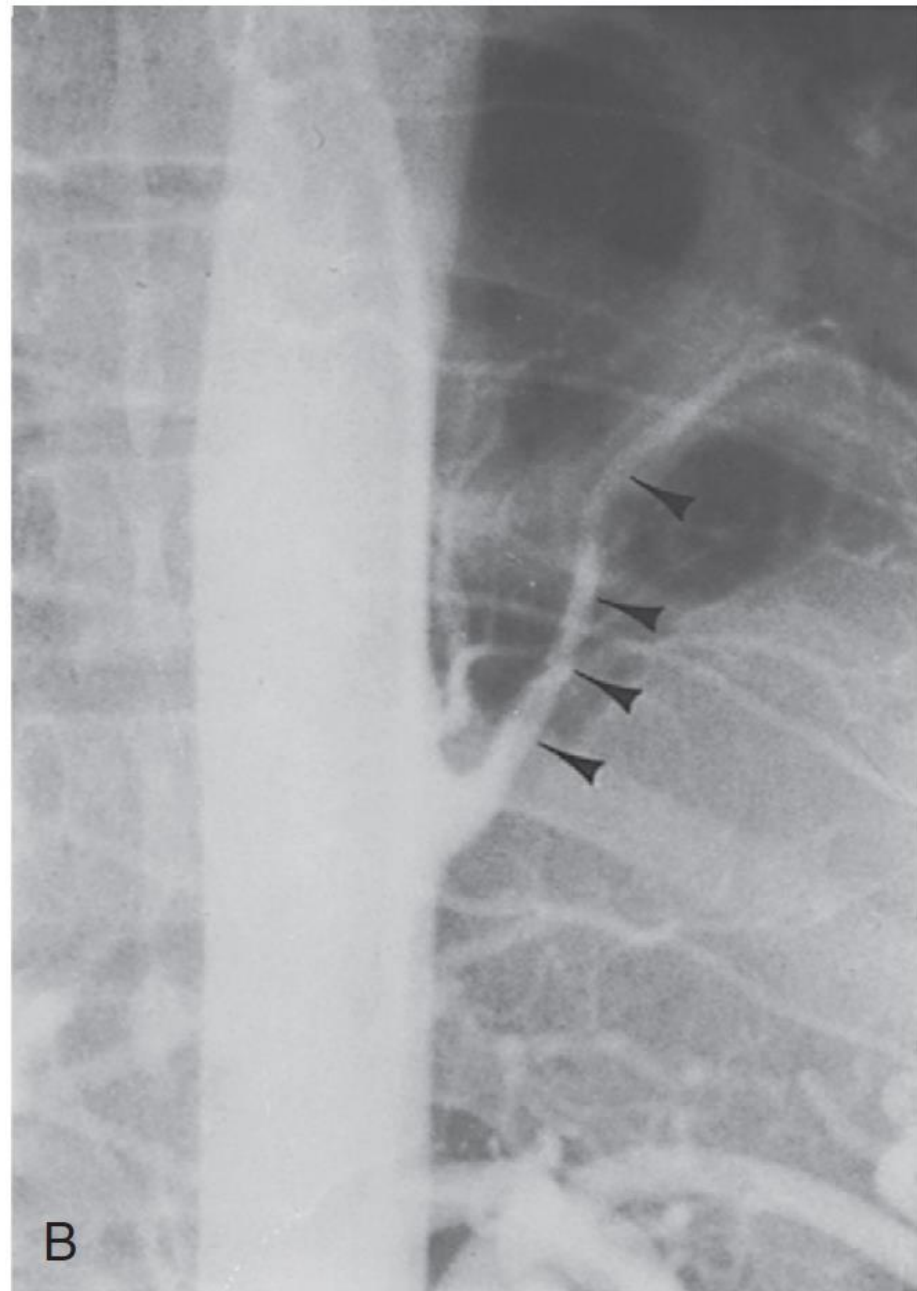
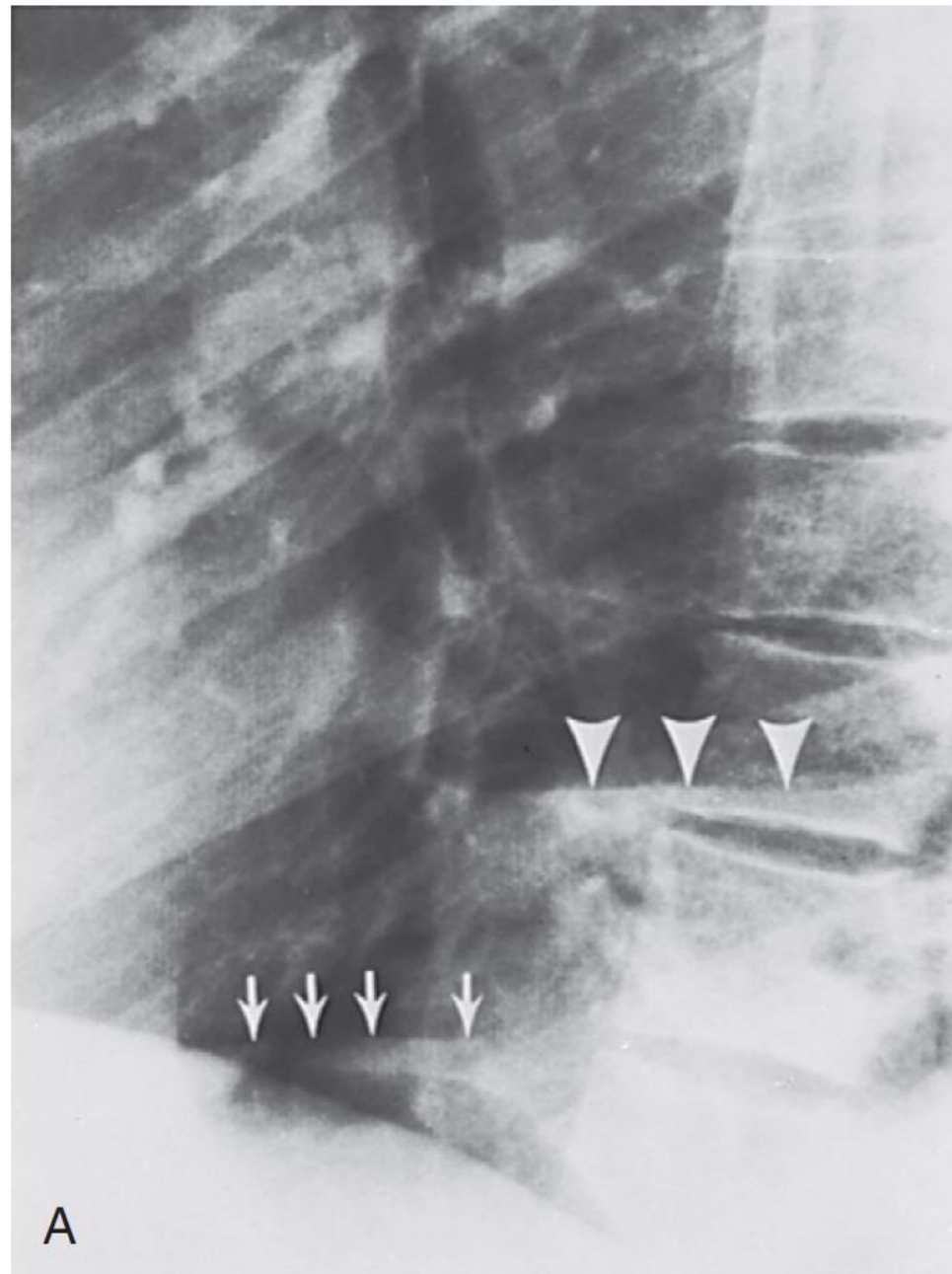
Pulmonary Sequestration(游離肺)

■ Uncomplicated:

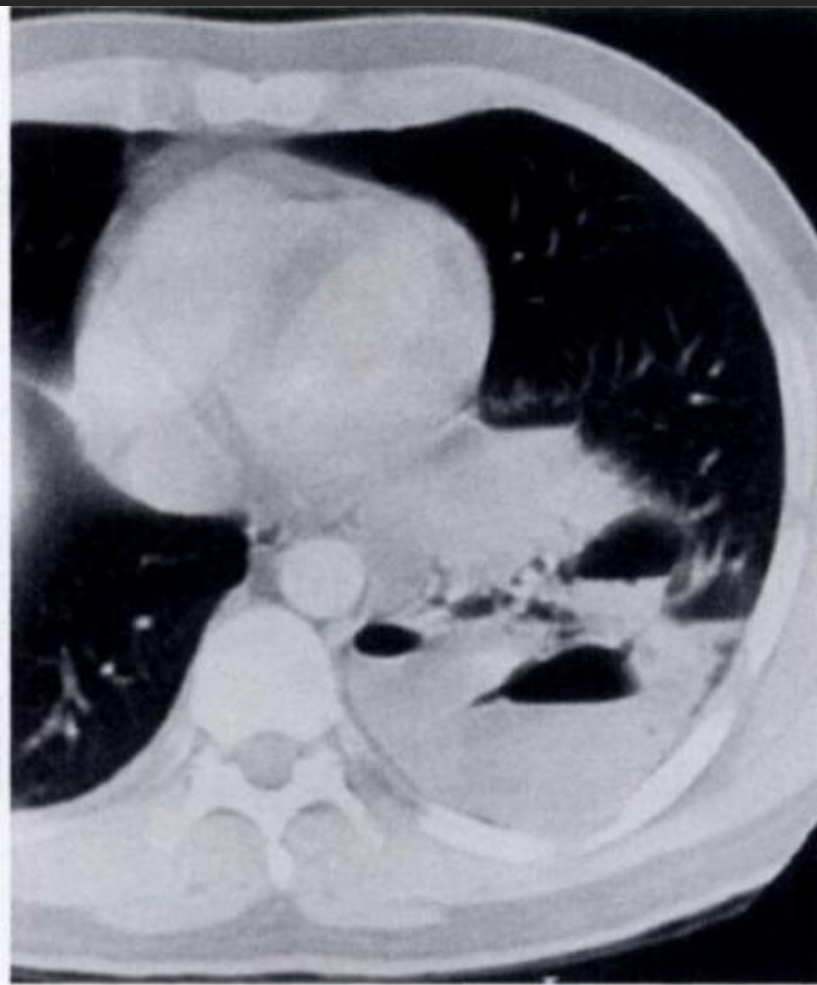
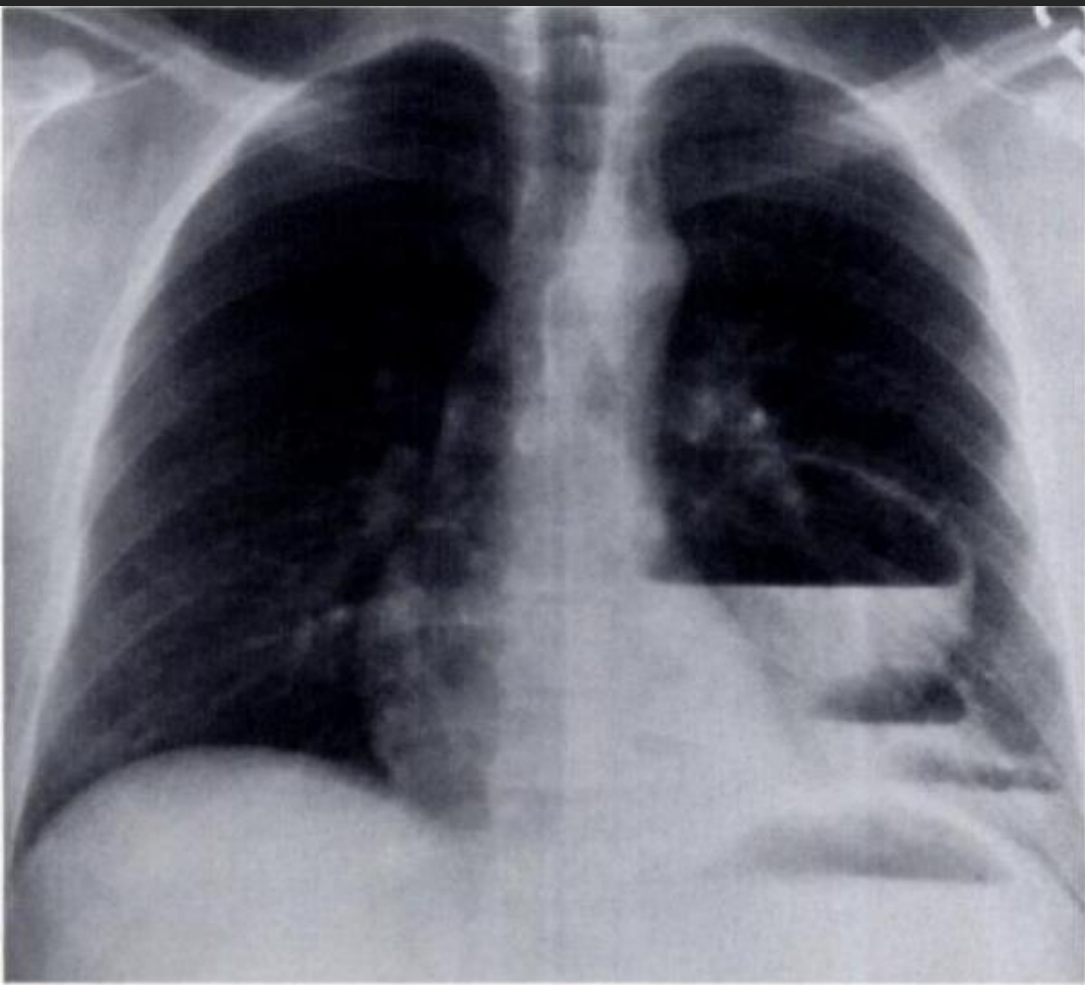
- A homogeneous **consolidation** with irregular margins or as a uniformly dense **mass** with smooth or lobulated contours, located in the posterior basal portion of a **lower lobe (B10)**
- Intralobar sequestration should always be considered in **recurrent or persistent pneumonia localized to the lower lobe.**

■ Complicated with advanced chronic infection

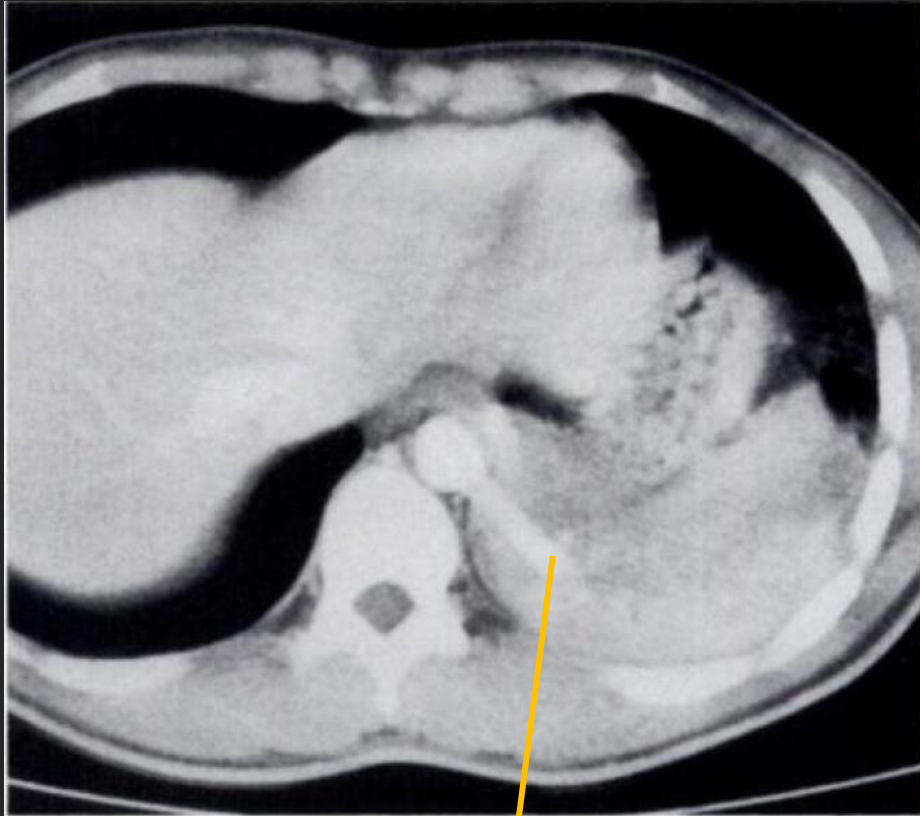- Predominantly ***cystic/cavitary lesion***, which manifests as closely related “ring” shadows, 從single large cyst到 multiple cysts of variable size.
- 有1/3 cystic intralobar sequestration會出現air-fluid level，表示lesion至少有部分與tracheobronchial tree相通。



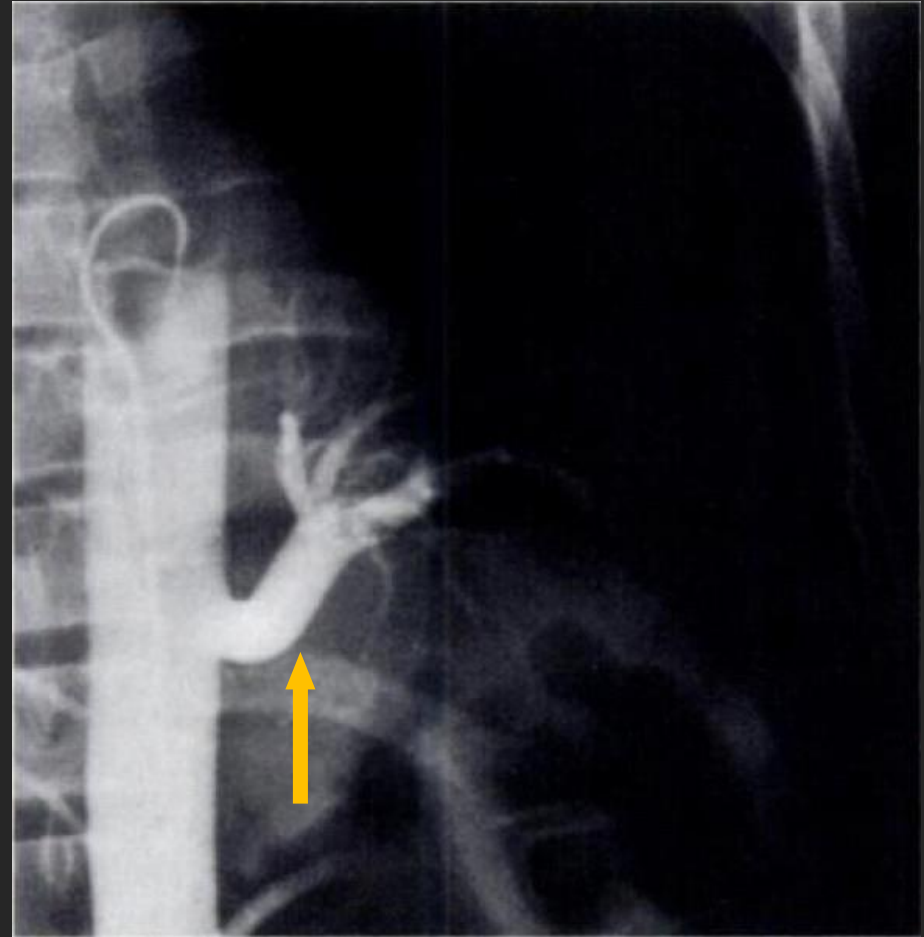
Intralobar Sequestration



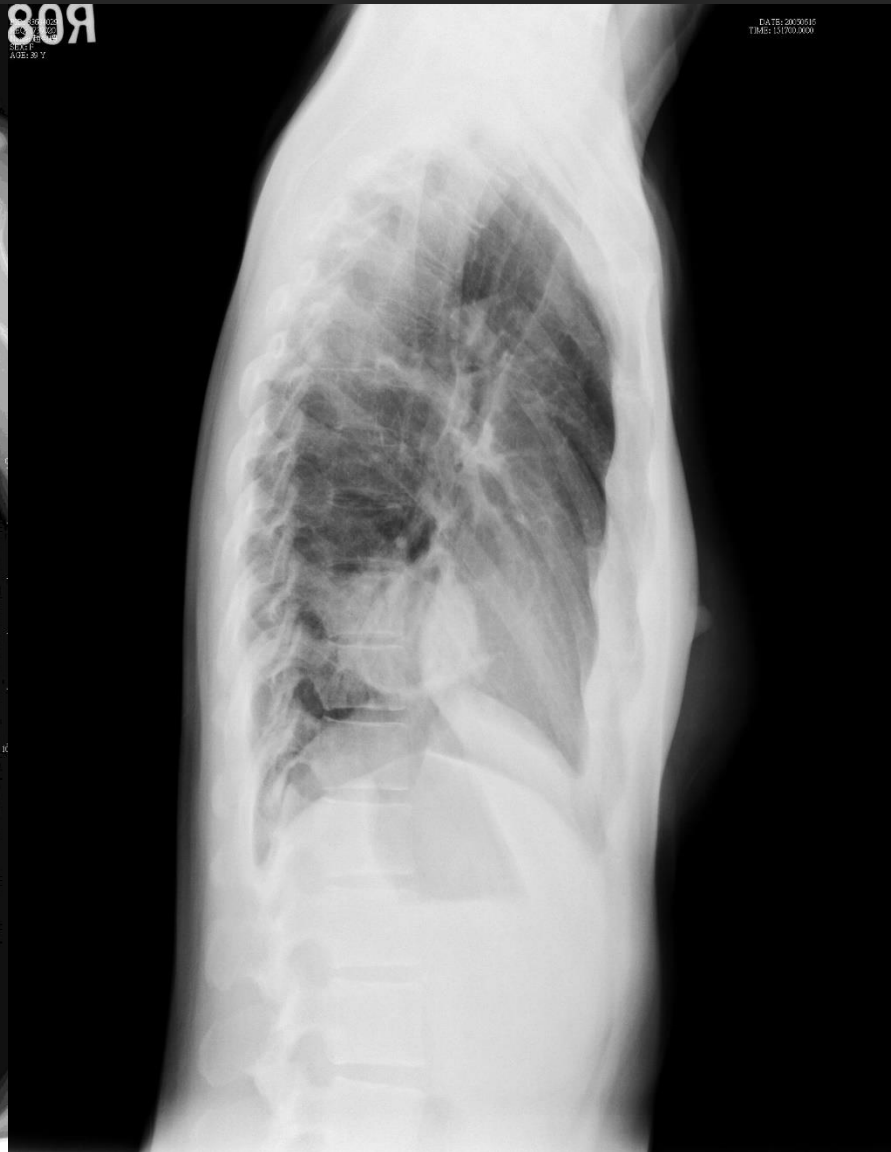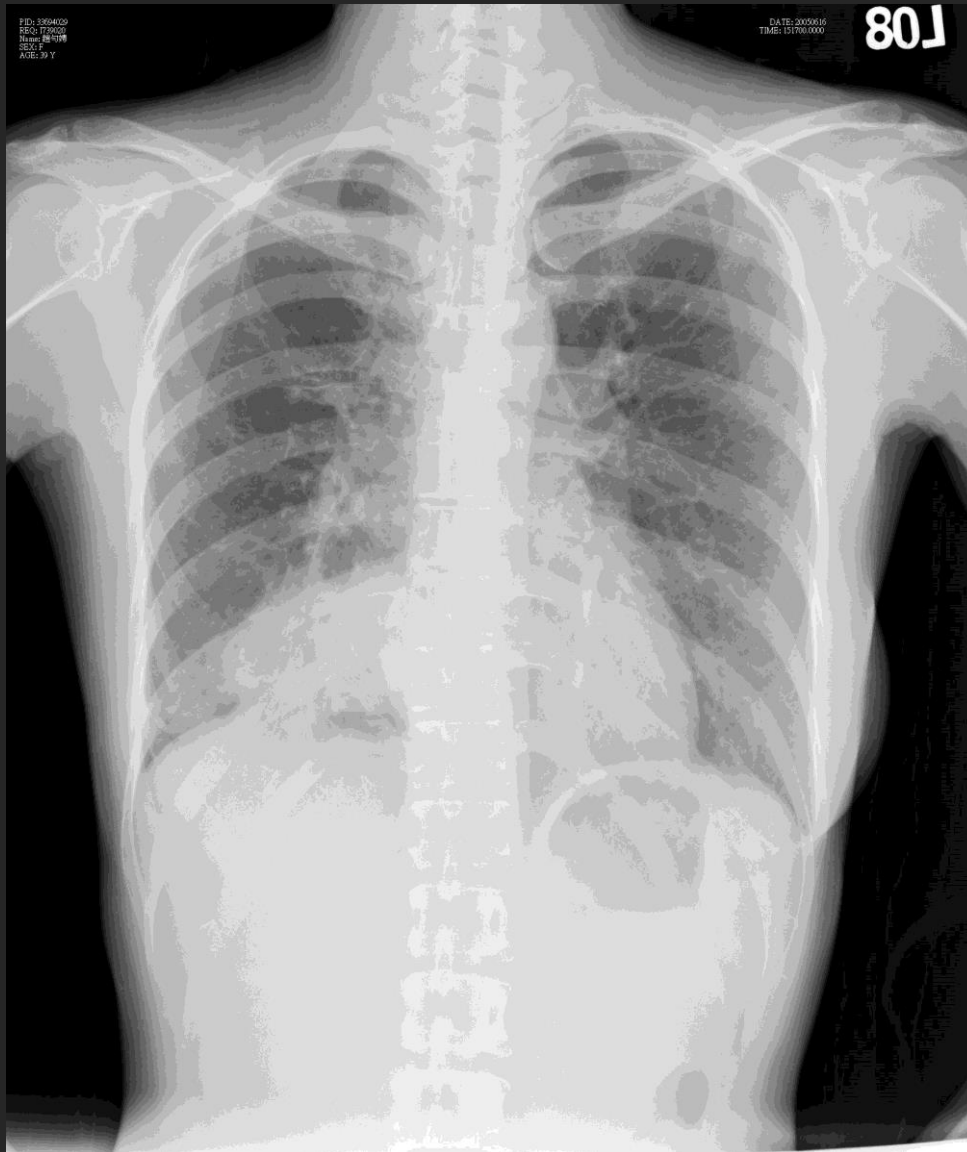
Intralobar Sequestration



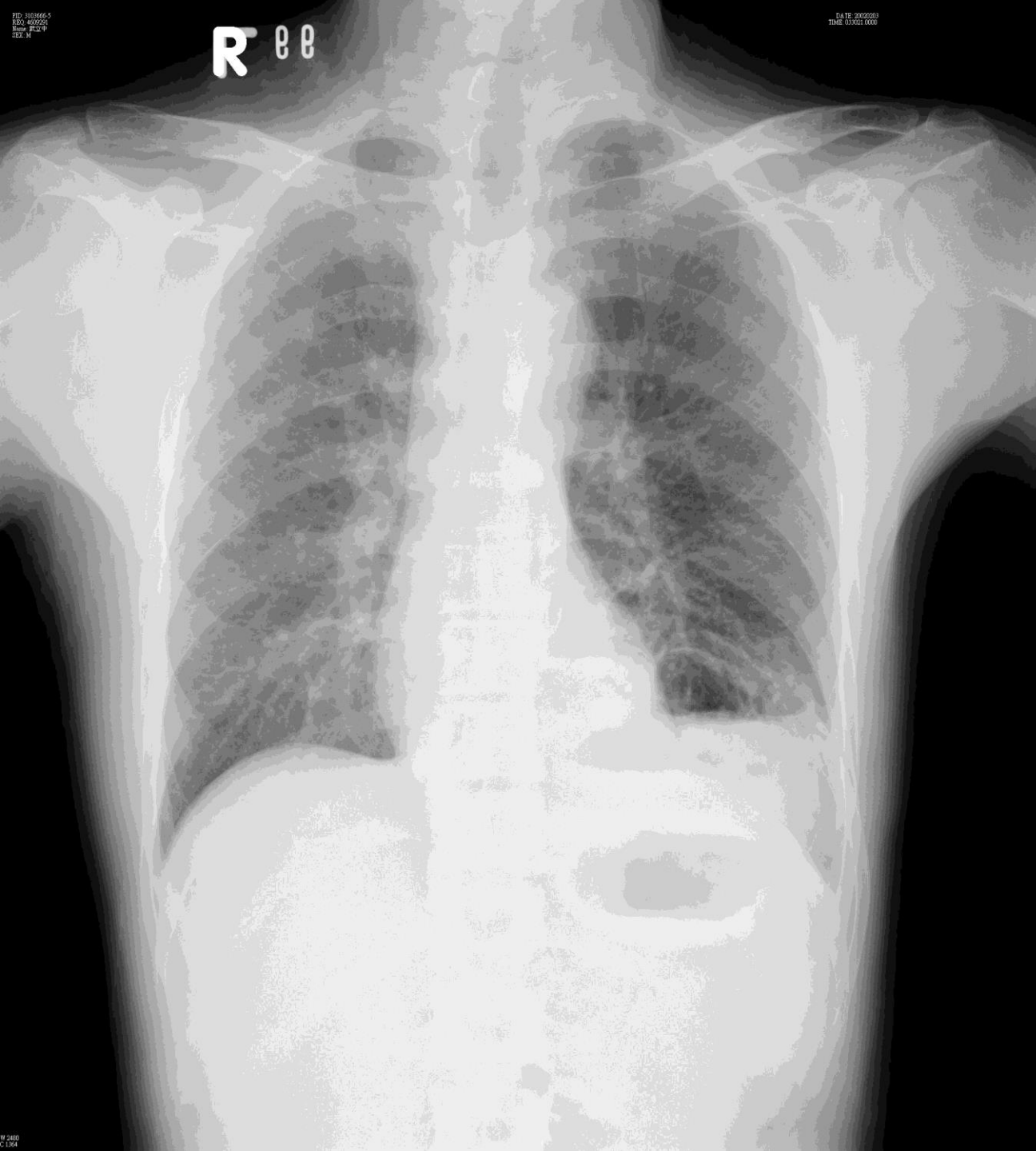
A large artery from D-aorta
supplying sequestration



Intralobar Sequestration



R 00



Intralobar Sequestration

D/D: 單側下肺野paravertebral region的mass lesion

- 1. Intralobar sequestration
 - 2. Bronchogenic cyst
 - 3. Neurogenic tumor
 - 4. Lateral thoracic meningocele
 - 5. Pleural tumor
- } 年輕人
- } 後縱膈病灶

D/D: 在下肺野的Cavitary / cystic lesion + Air-fluid level

1. Intralobar sequestration
2. Obstructive pneumonitis
3. Lung abscess
4. Cystic bronchiectasis
5. CCAM
6. Hiatal hernia

Multiple Cystic lesion: 4L

- Lymphocytic interstitial pneumonitis (**LIP**)
- Lymphamgioleiomyomatosis (**LAM**)
- Pulmonary Langerhan cell histiocytosis (**PLCH**)
- Laryngeal papillomatosis

Lymphangioleiomyomatosis

■ Pathology:

- Harmatomatous proloferation of smooth muscle around lymphatics and blood vessels

■ Clinical

- **childbearing-age women**
- Recurrent **pneumothorax** and **chylothorax**
- Dyspnea

■ Best clinical diagnostic clue:

- Paradoxical coarse interstitial thickening (diffuse) in **hyperinflated lung** of childbearing-age women

Lymphangioleiomyomatosis

CXR

■ Lung:

- Reticular interstitial thickening, **honeycombing**
- Normal or increased lung volume

■ Pleura

- Recurrent spontaneous **pneumothorax, pleural effusion**

HRCT

■ Lung

- **Thin-wall cysts, uniform size**, diffuse distribution (no predilection)

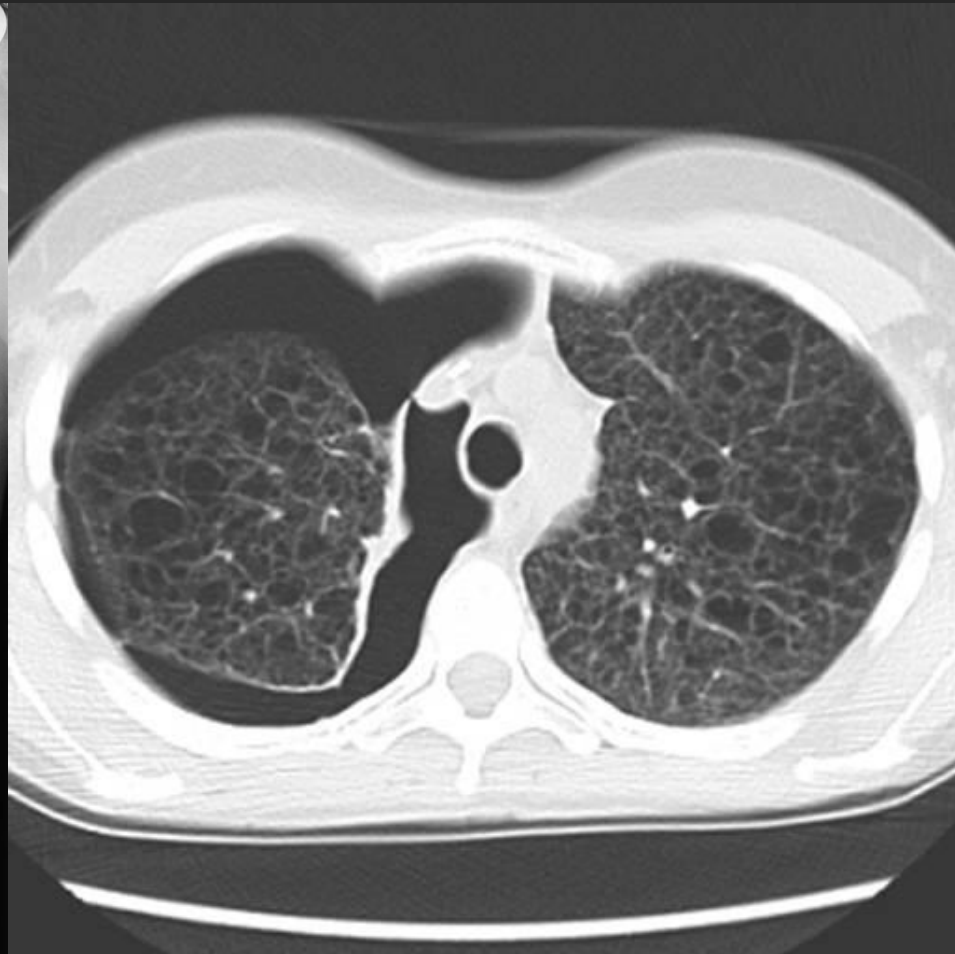
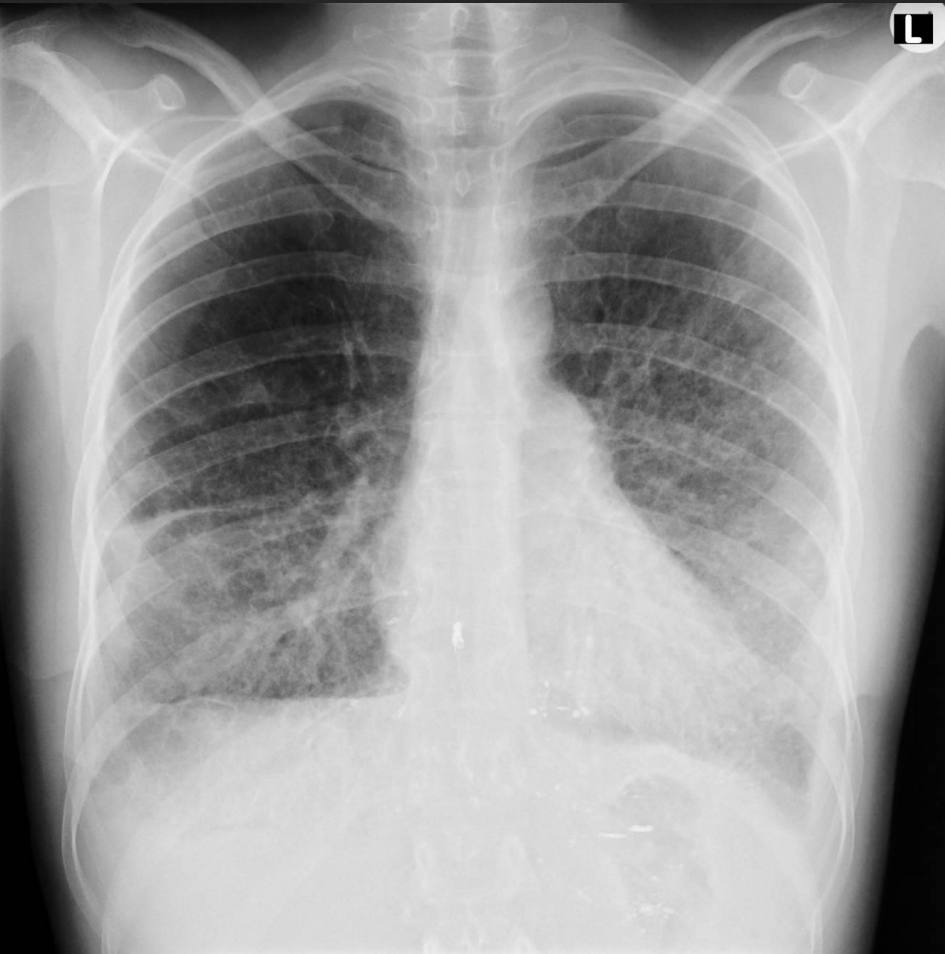
■ Pleural

- Pneumothorax or pleural effusion

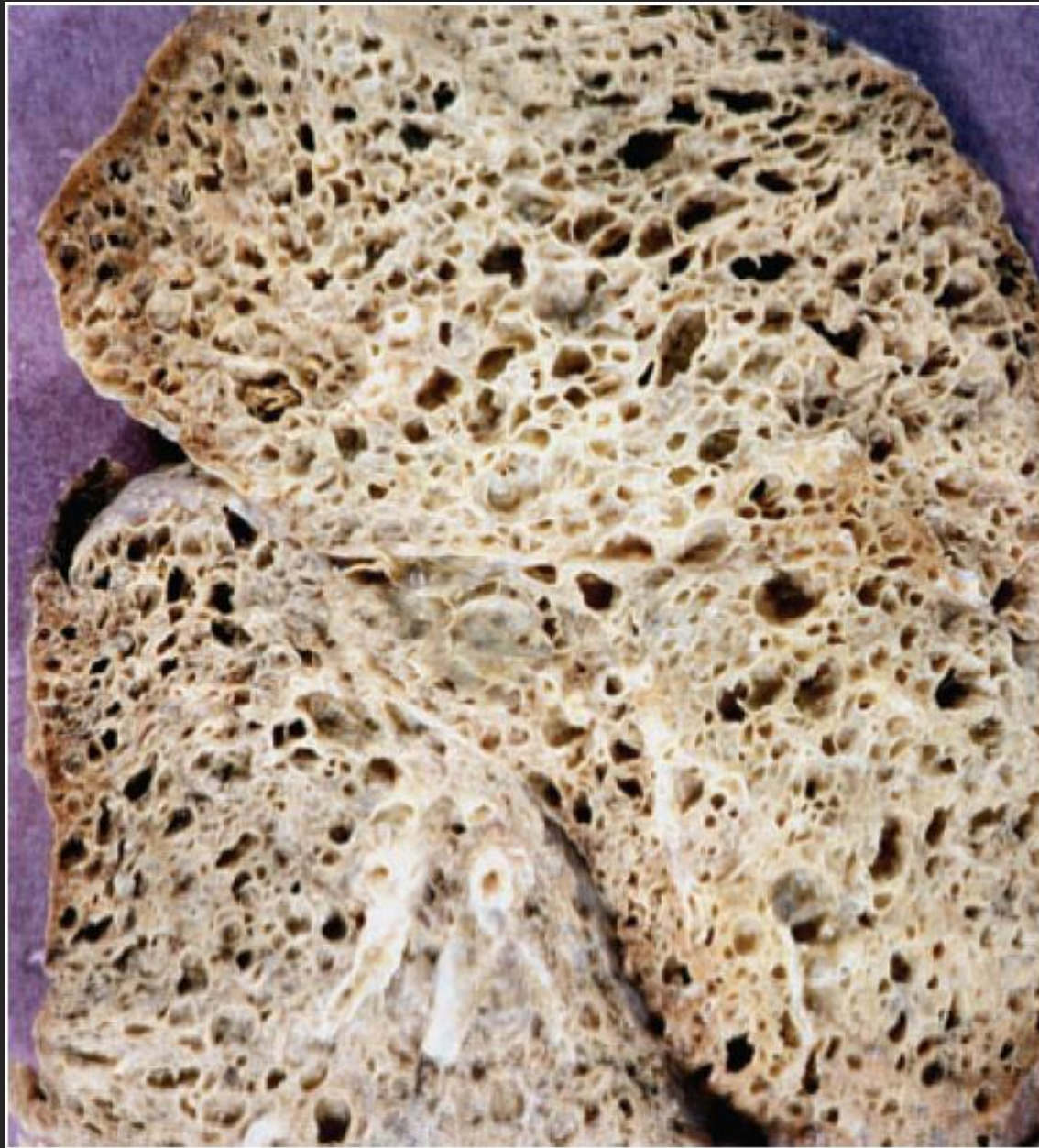
■ Other

- Mediastinal LAP, retroperitoneal LAP, renal angiomyolipoma

Lymphangioleiomyomatosis



LAM



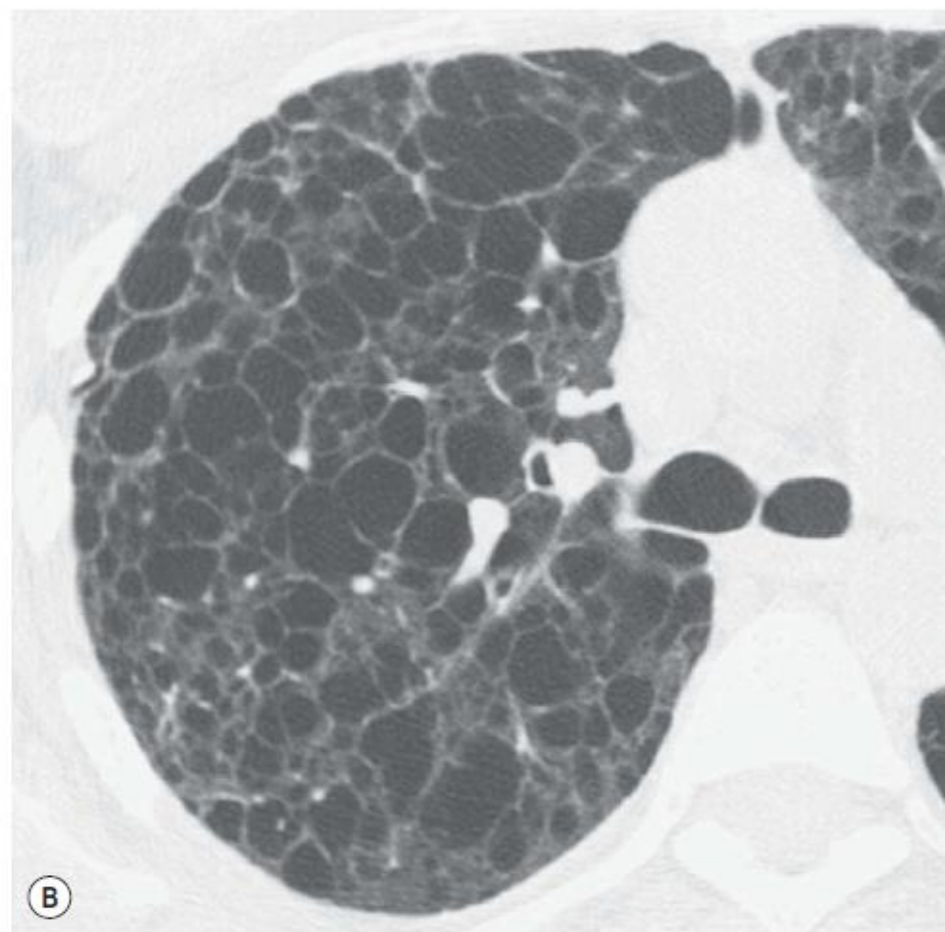
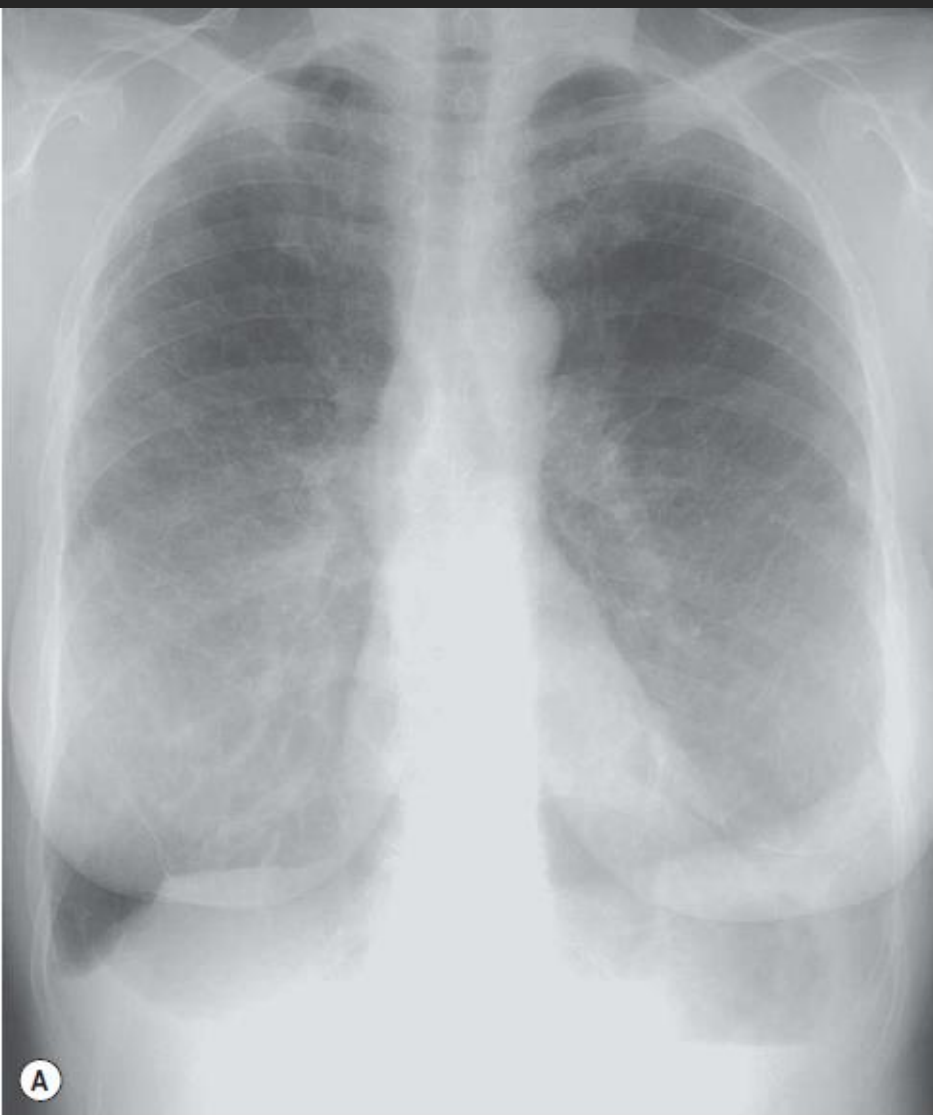

Fig. 11.65 A 54-year-old woman with LAM. **A**, Chest radiograph shows marked hyperinflation with a diffuse coarse reticular pattern. There is a small left effusion. **B**, CT shows profuse round cysts, each with a well-defined thin wall. The cysts are so numerous that they appear clustered.

Pulmonary Langerhans cell histiocytosis (PLCH)

- Age: 20-40y/o, M=F
- **Smoking**
- PLCH病理下的特徵為Langerhans' cell不正常的增生並且聚集在細支氣管、小的肺動脈和小的肺靜脈處，常被描述成沿著 bronchovascular bundle 分布。
 - 隨著疾病進展進而造成組織發炎、開洞、囊泡、和纖維化的發生。
- Associated with ALL & AML
- more common in Caucasian populations

Pulmonary Langerhans cell histiocytosis (PLCH)

CXR

- Early: multiple ill-defined nodular pattern; 1~10mm
- More advanced: **reticulonodular**
- End-stage: coarse reticular pattern, **cystic** about 1cm
- Bilateral, symmetric, **upper and mid lung zone, sparing C-P angle**
- Spontaneous pneumothorax
- Lung volume: preserved or increased
- Pleural effusion, hilar/mediastinal LAP: 很少見

Pulmonary Langerhans cell histiocytosis (PLCH)

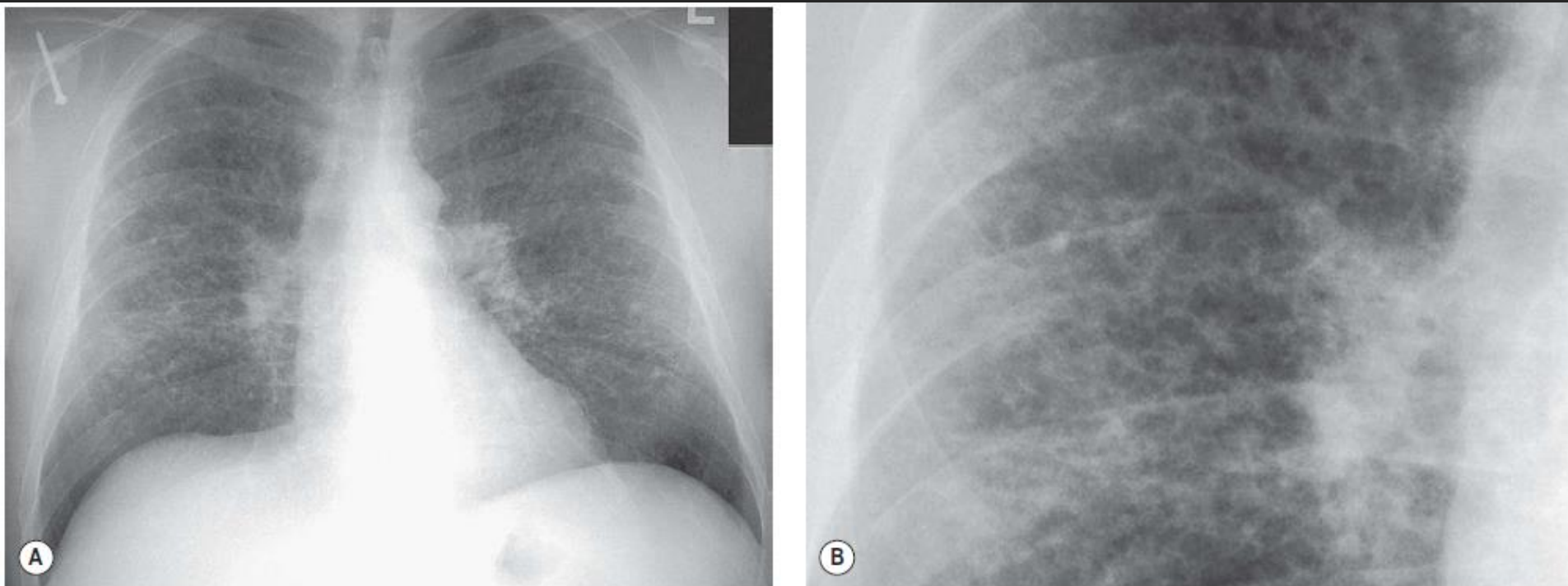


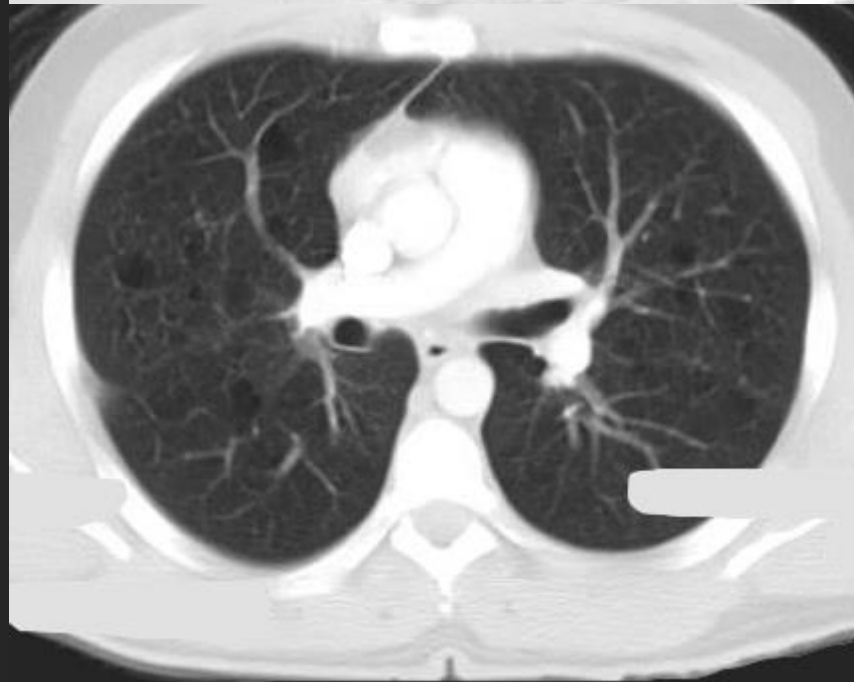
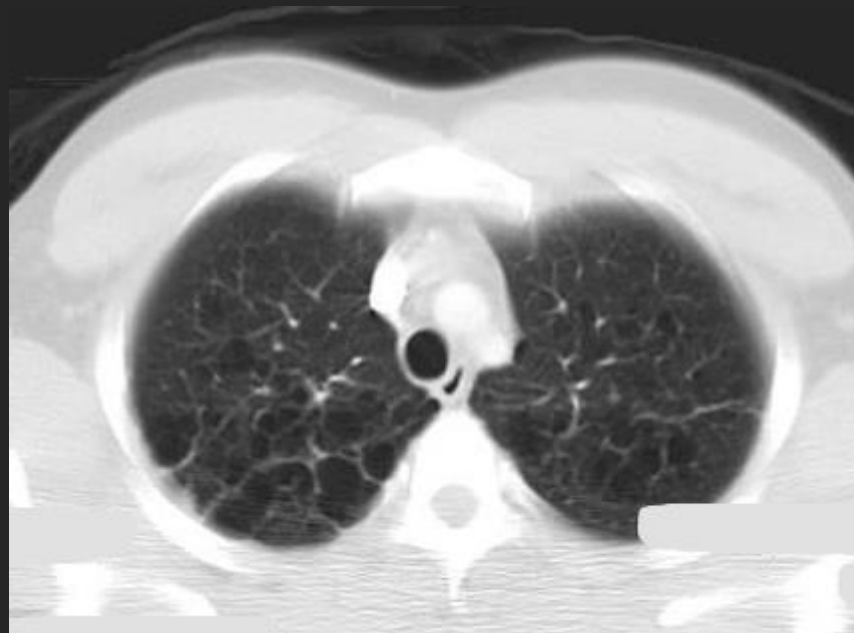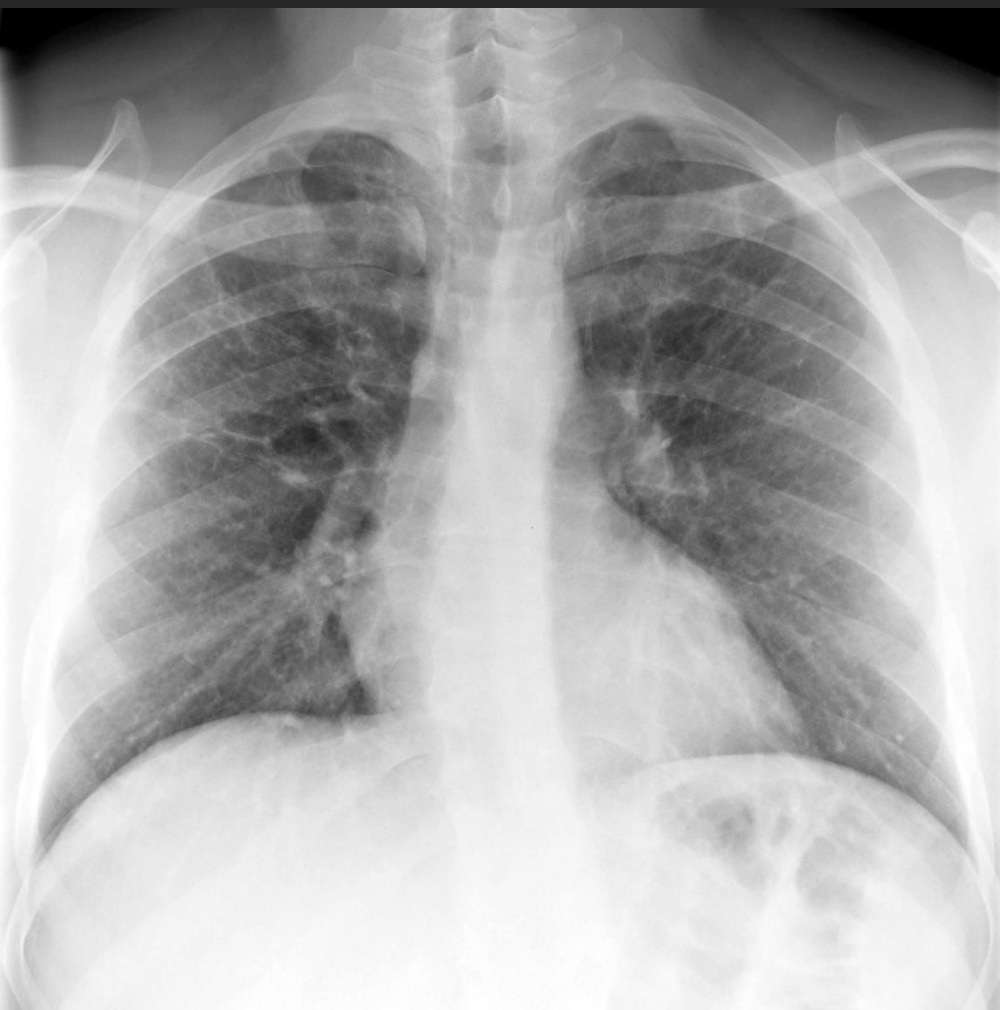Fig. 8.6 A, Chest radiograph with B, magnified view shows characteristic features of pulmonary Langerhans cell histiocytosis. There is a diffuse parenchymal abnormality due to cysts and nodules, with upper and mid-lung predominance, and sparing of costophrenic sulci. Lung volumes are preserved. Enlargement of central pulmonary arteries suggests pulmonary arterial hypertension.

Pulmonary Langerhans cell histiocytosis (PLCH)

HRCT

- Cyst (80%), nodule (60-80%)
- Cyst: **variable size, variable wall thickness (thicker wall over upper lung), confluent or bizarre shape**
- Pulmonary parenchyma between cyst: normal
- Dx progression → less nodule and cysts become more prominent
- Most severe in **upper and mid lung zones** with lung **base sparing** in all stages
- Less common (each 10%): cavitated nodule, reticulation, GGO

PLCH



Pulmonary Langerhans cell histiocytosis (PLCH)

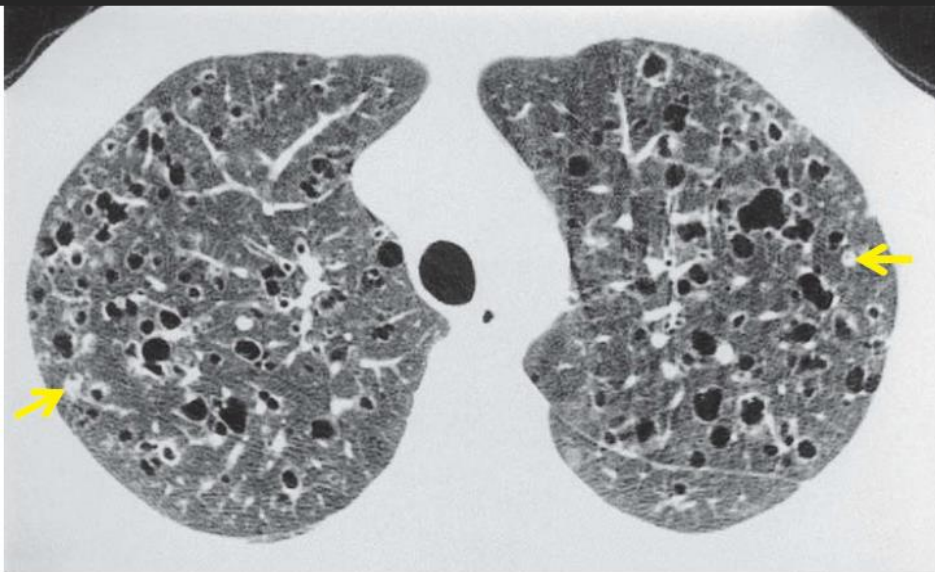
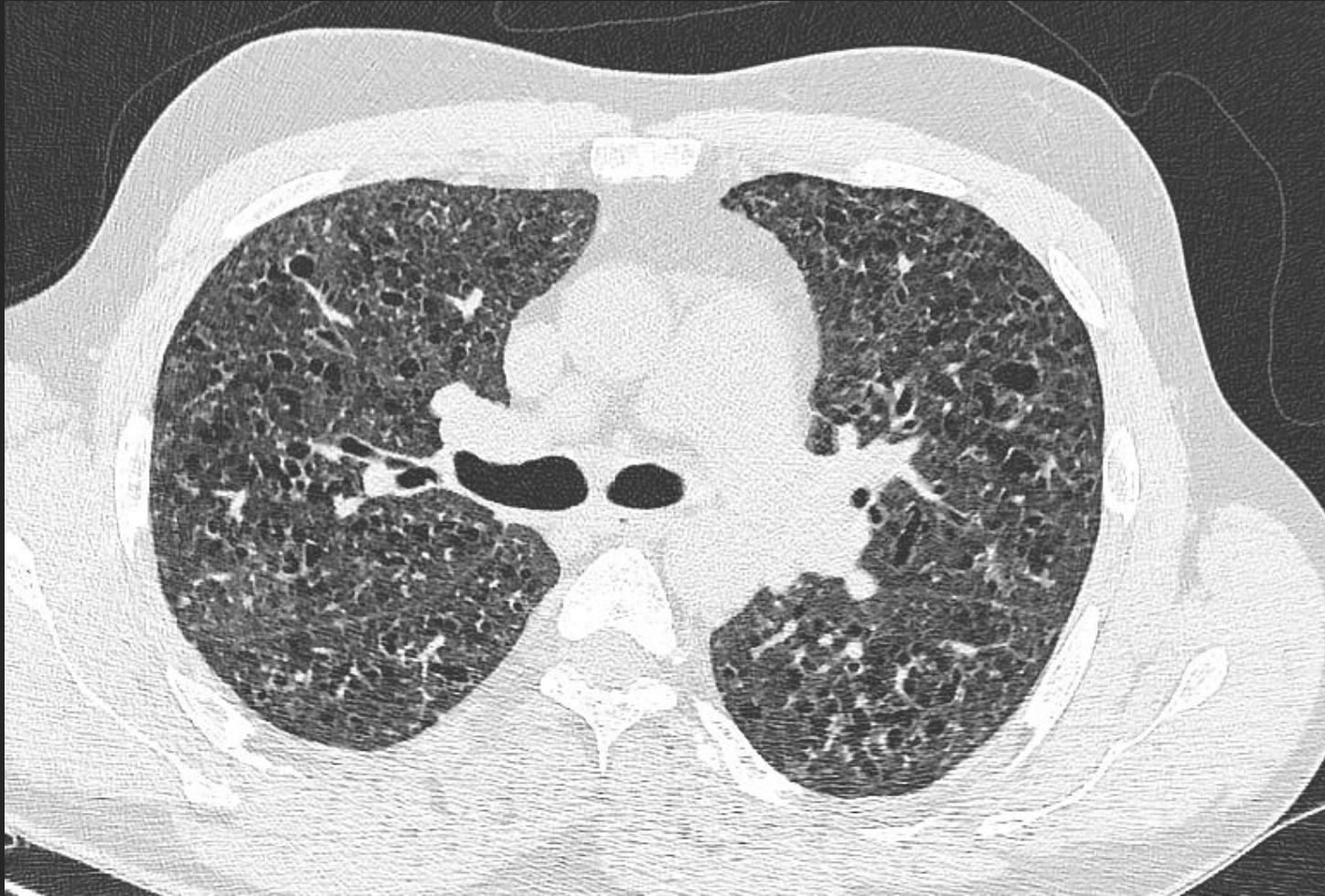


Fig. 8.7 Pulmonary Langerhans cell histiocytosis. CT through the upper lungs shows a characteristic combination of thin-walled cysts and poorly defined nodules. Two of the nodules are just beginning to cavitate (arrows); cavitation is thought to be the earliest stage of cyst formation.

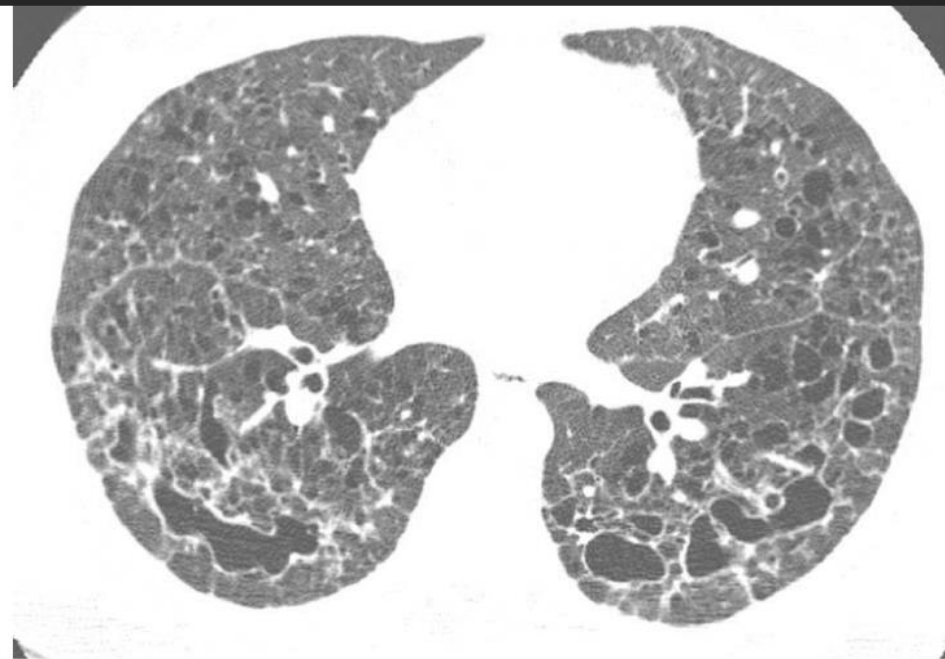

Fig. 8.9 Pulmonary Langerhans cell histiocytosis. CT shows numerous irregularly shaped cysts. A few small nodules are visible.

Pulmonary Langerhans cell histiocytosis (PLCH)



Differential diagnosis: cystic lesions

■ PLCH:

- ☐ Preceded by **multiple ill-defined nodules**
- ☐ **Variable in size and wall thickness** (thicker over upper lung)
- ☐ Predominant in upper and middle lung zones and **spare lung bases**

■ LAM:

- ☐ **Diffusely** throughout the lungs, **including C-P angles**
- ☐ **Thin-walled**
- ☐ Affect **women** almost exclusively

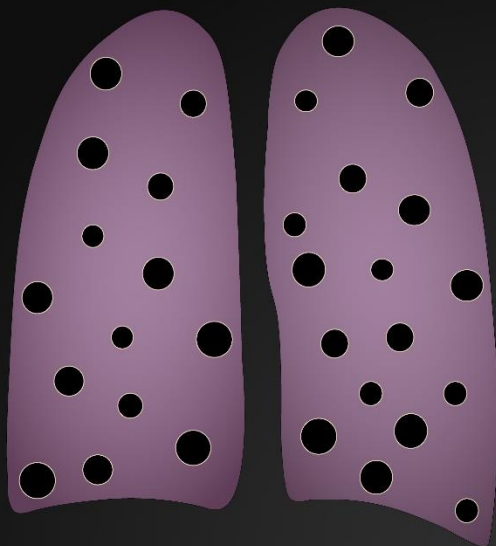
■ Emphysema

- ☐ Represent destroyed lung parenchyma, **lack definable walls**

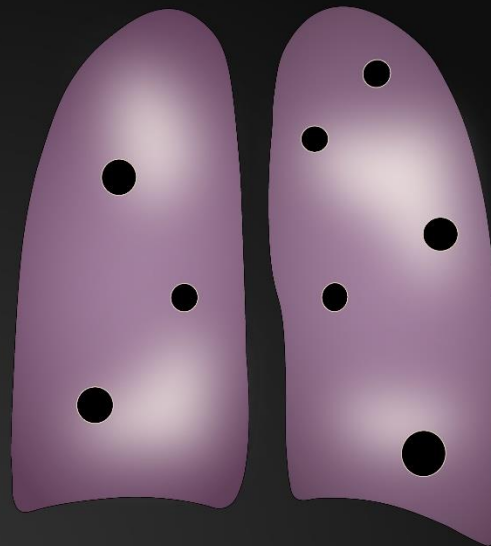
■ Cystic bronchiectasis

- ☐ Communicating branching pattern seen on contiguous CT images

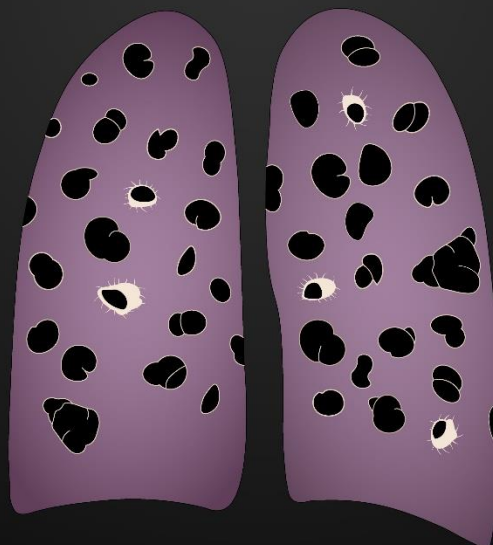LAM



LIP



LCH

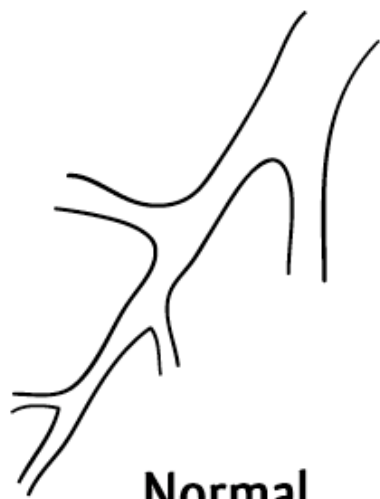

S Hapu

CC NC BY SA
Radiopaedia.org

Cystic Bronchiectasis


- One of the 3 types of bronchiectasis (cylindrical, varicose, saccular (cystic))
- Most severe type in bronchiectasis
- **Not true cavity**, but ballooned dilatation of multiple terminal bronchi
- Causes:
 - Congenital
 - Cystic fibrosis
 - **Recurrent infection**: pneumonia, **TB**, agammaglobulinemia
 - ABPA: central type of bronchiectasis



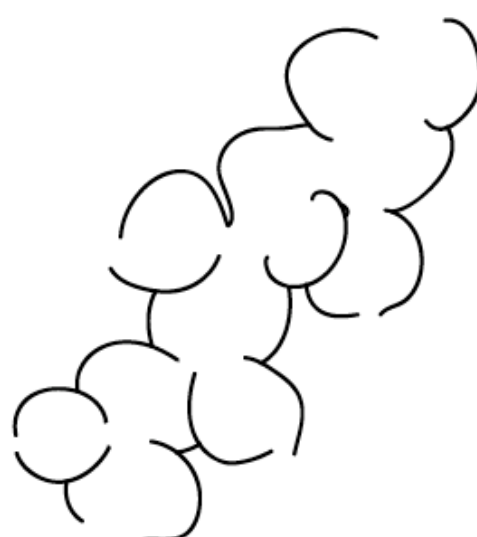
Normal



Cylindrical

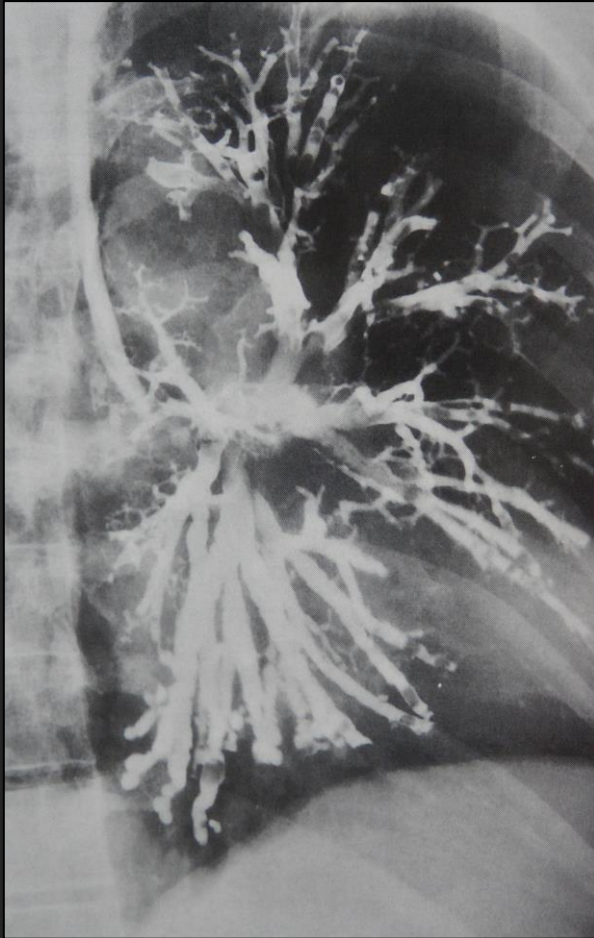


Varicose

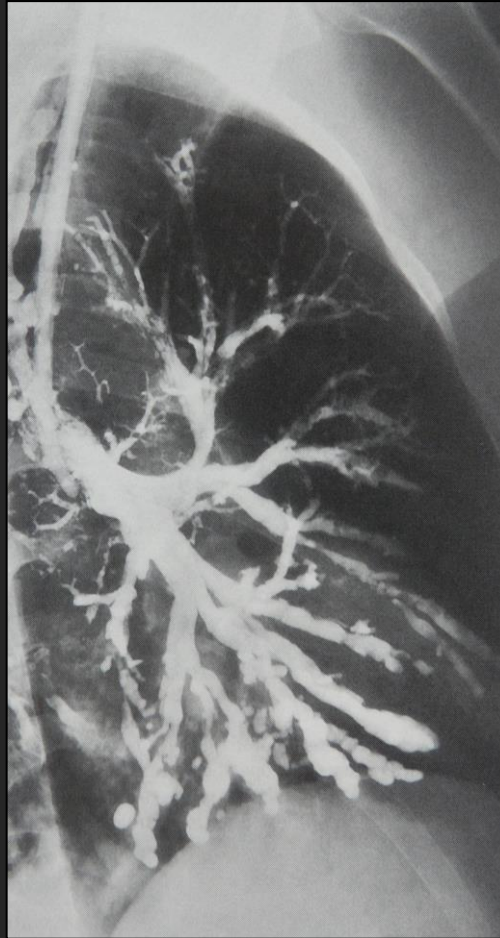


Cystic

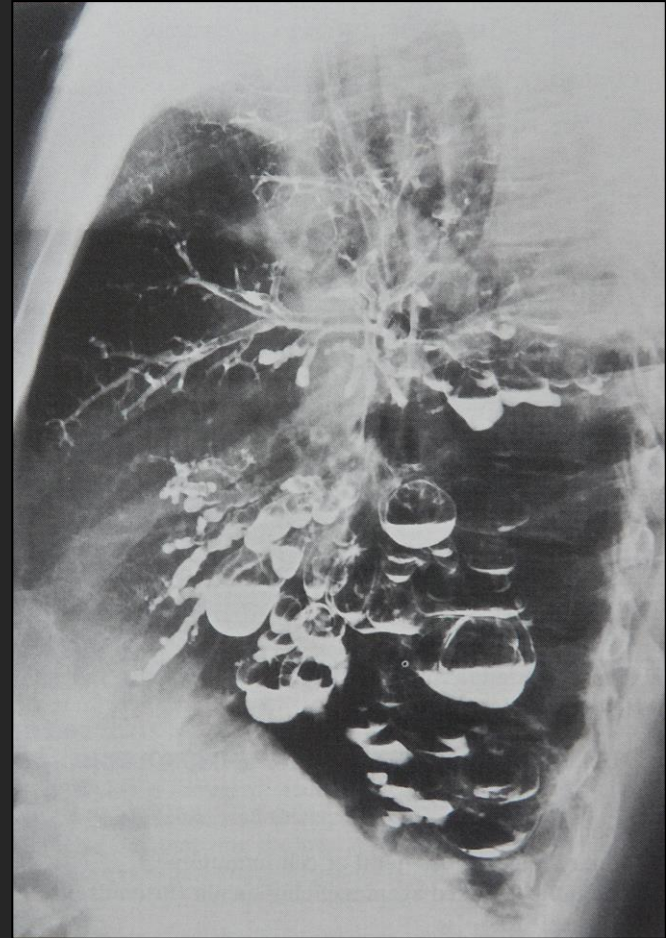
Bronchography in bronchiectasis



Cylindrical

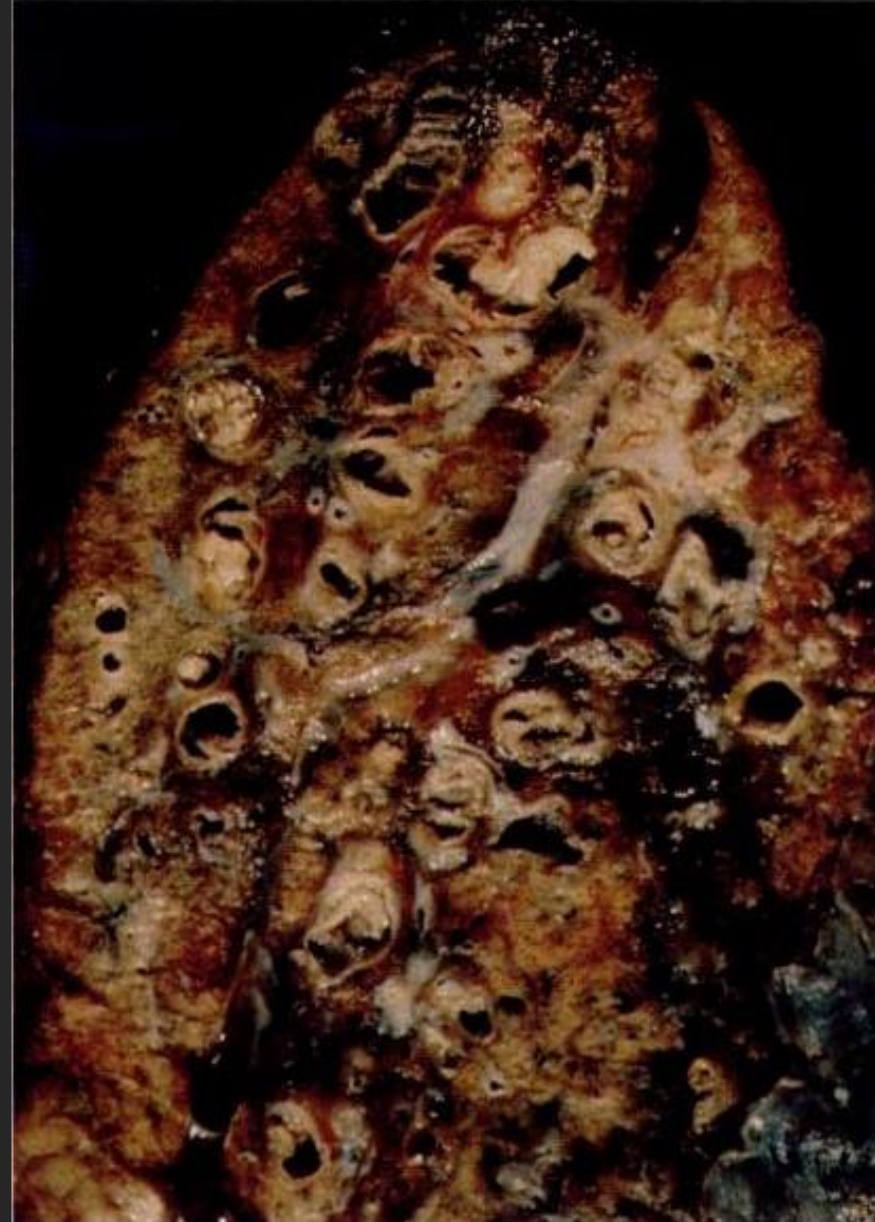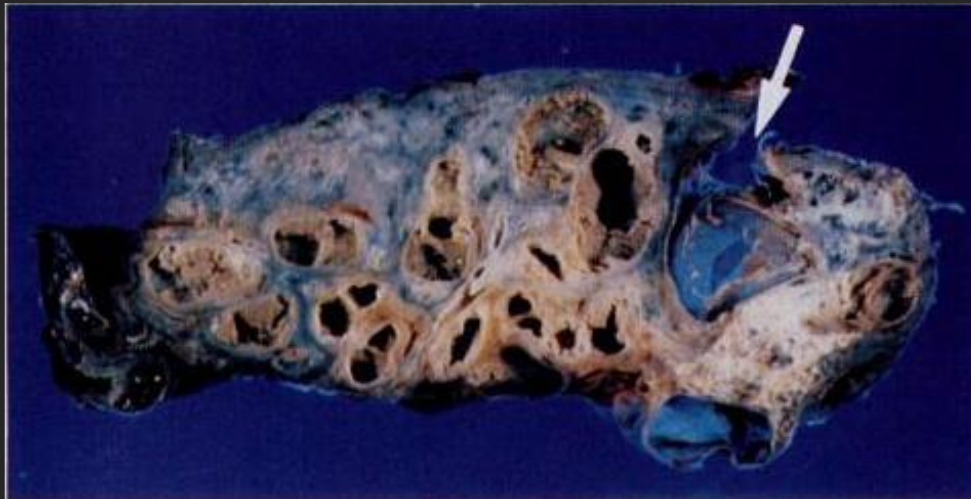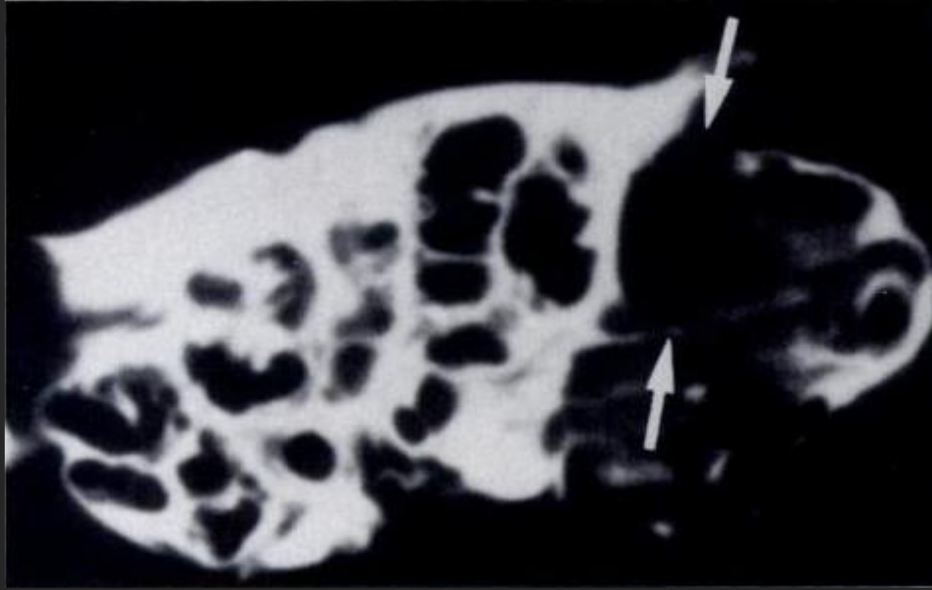


Varicose

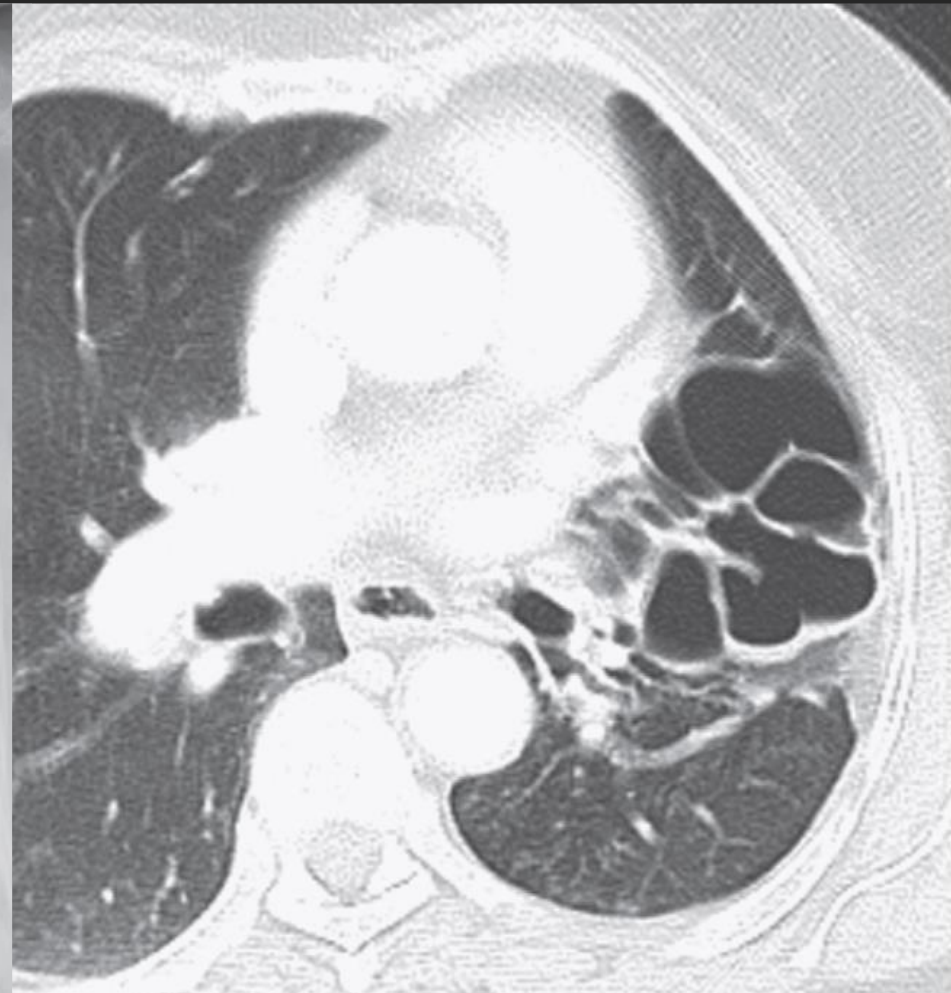
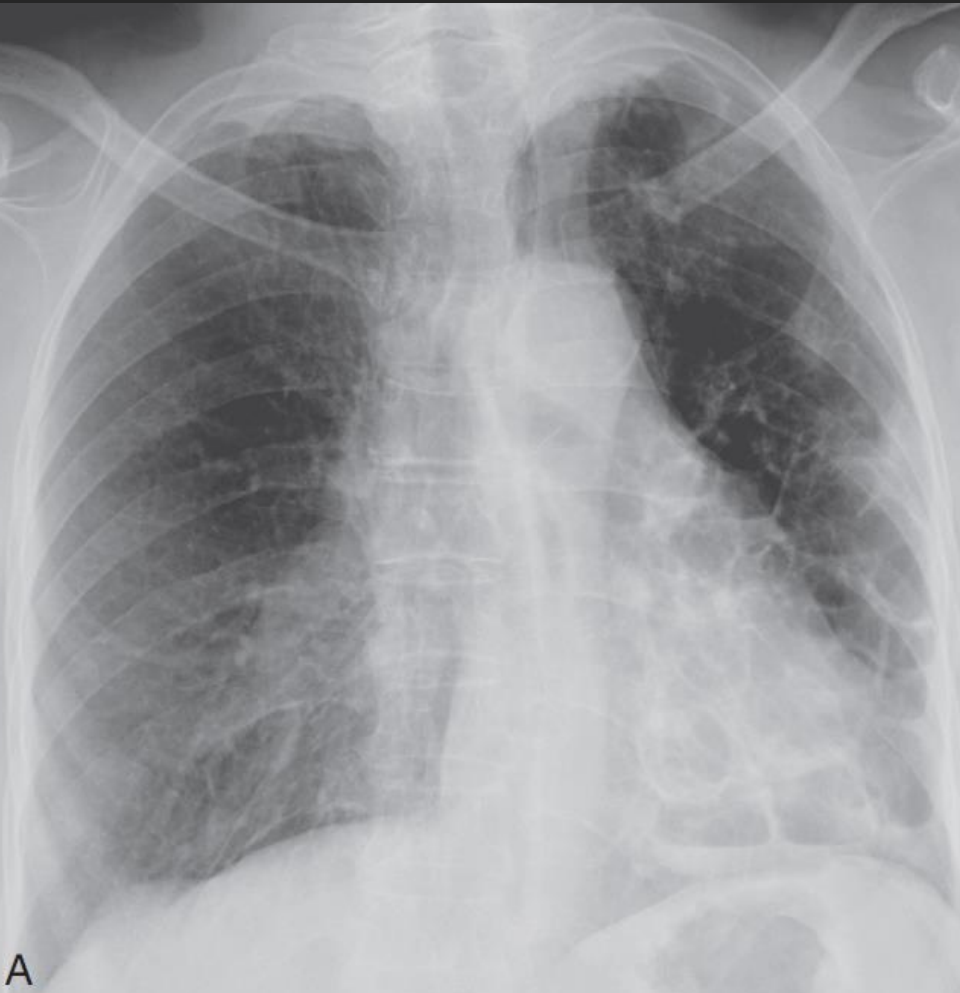


Saccular

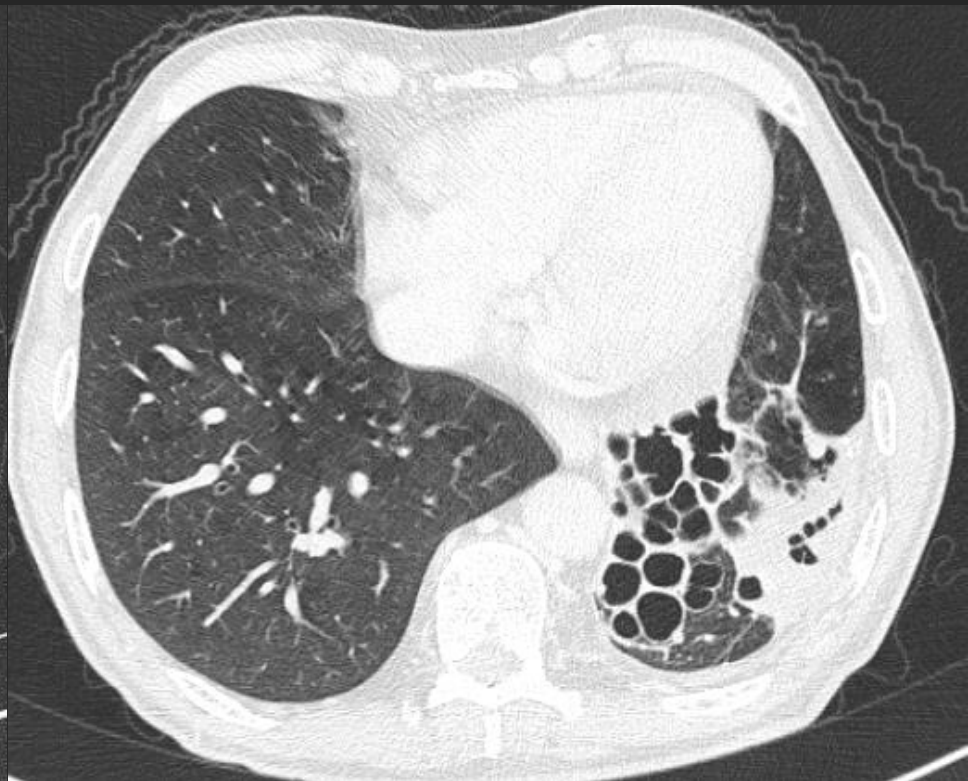
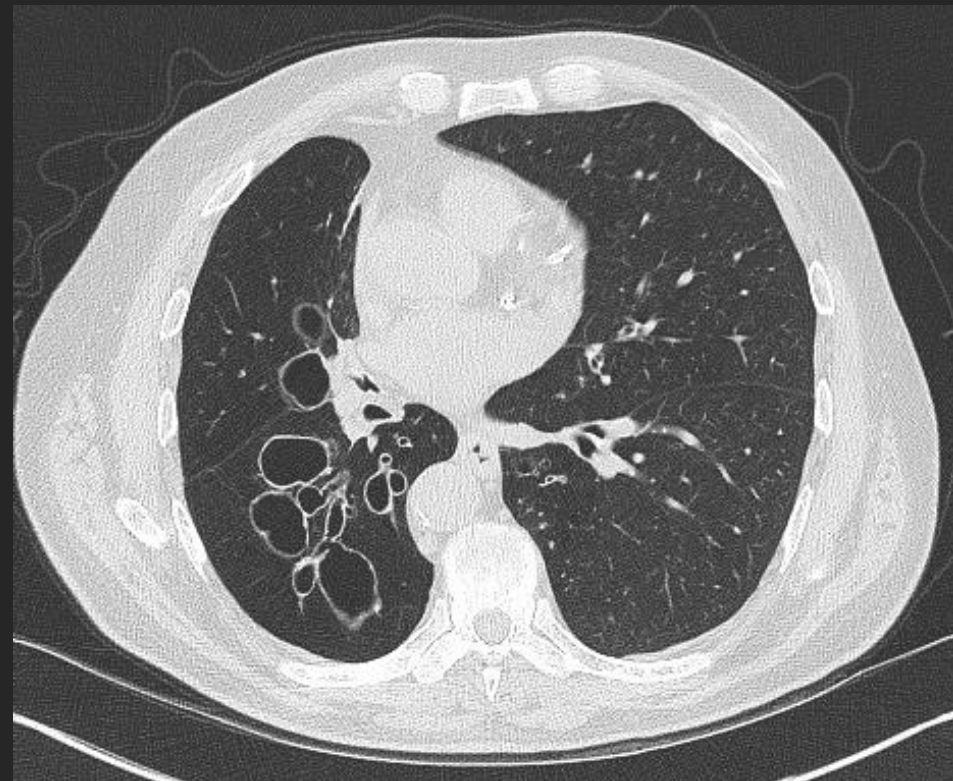
Cystic Bronchiectasis



Cystic Bronchiectasis



Cystic Bronchiectasis



Case courtesy of Dr Ian Bickle, Radiopaedia.org, rID: 50417

Case courtesy of Dr Varun Babu, Radiopaedia.org, rID: 45101

Congenital pulmonary airway malformation (CPAM)

- Congenital Cystic Adenomatoid Malformation (**CCAM**)
- Adenomatoid **proliferation of bronchiole that form cysts** instead of normal alveoli
- Usually < 2y/o
- CXR:
 - Usually **unilateral, lower lobes**
 - Single or multiple
 - **Expansion of the involved hemithorax**
 - Shift of mediastinum to contralateral side
- CT scan:
 - Complex conglomeration of multiple **cysts in a lower lobe**

Congenital pulmonary airway malformation (CPAM)

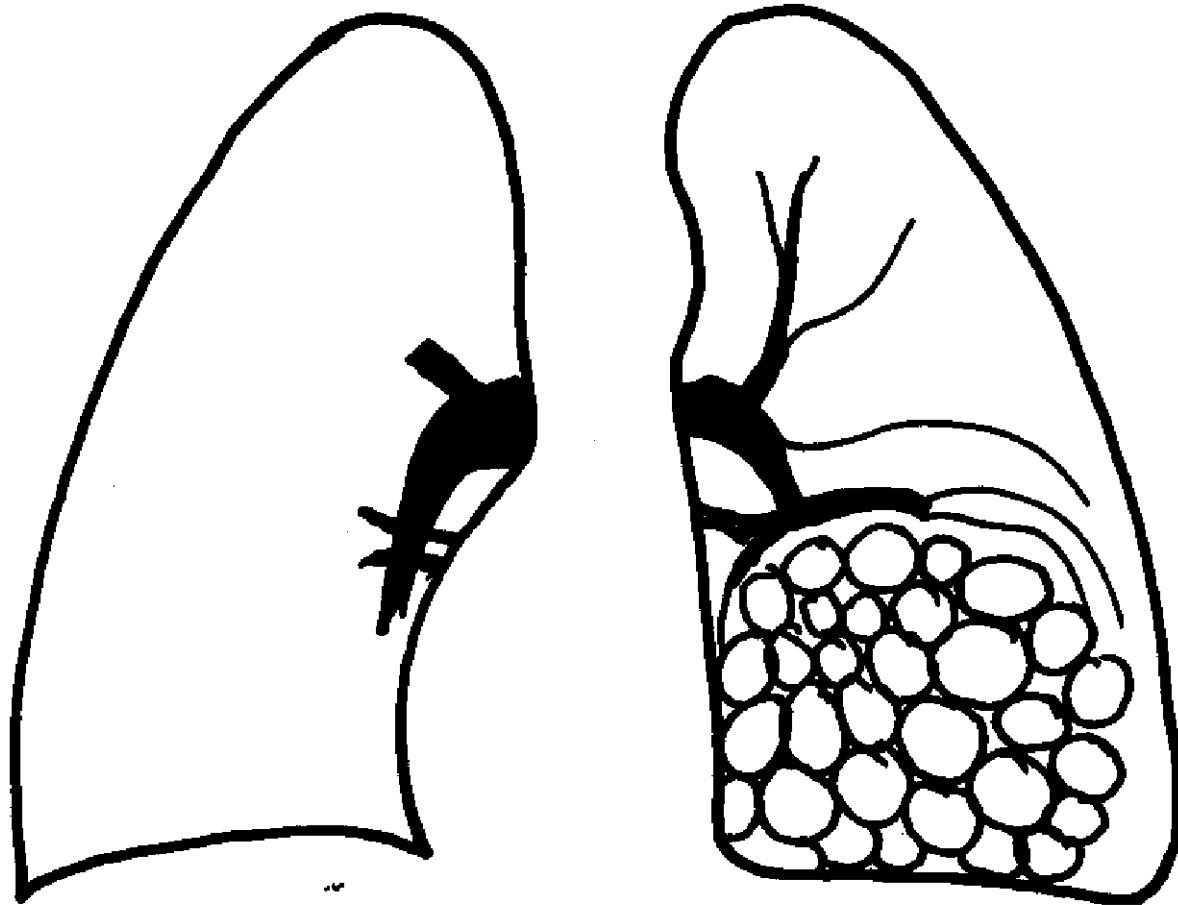


Fig. 68 Congenital cystic adenomatoid malformation. Overexpanded cystic area with vascular displacement

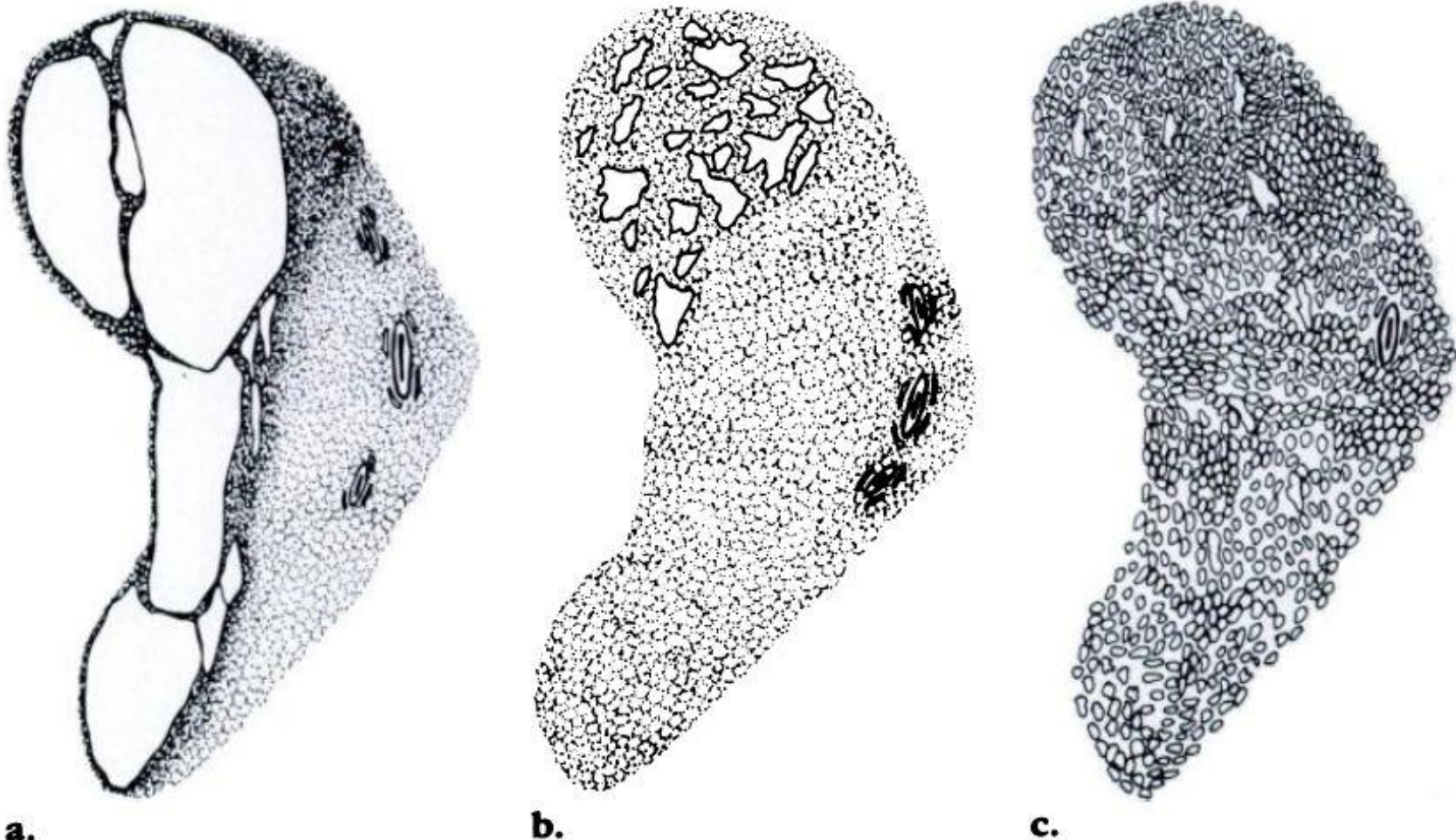


Figure 1. Diagram of the three types of congenital cystic adenomatoid malformation. (Reprinted, with permission, from reference 10.) (a) Type I lesions have large cysts of variable sizes (2–10 cm). Dominant cysts may occur. (b) Type II lesions have smaller cysts resembling back-to-back bronchioles. The lesion blends with the adjacent normal lung. (c) Type III lesions have numerous glandlike (adenomatoid) structures along with scattered, thin-walled bronchiolelike structures. The lesion tends to involve an entire lobe.

Congenital pulmonary airway malformation (CPAM)

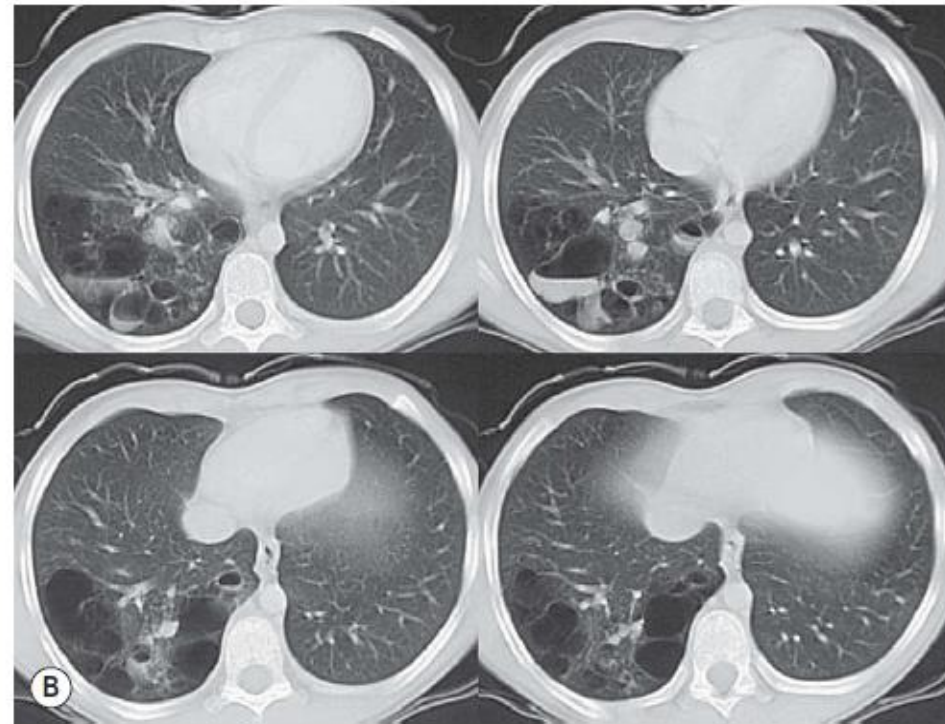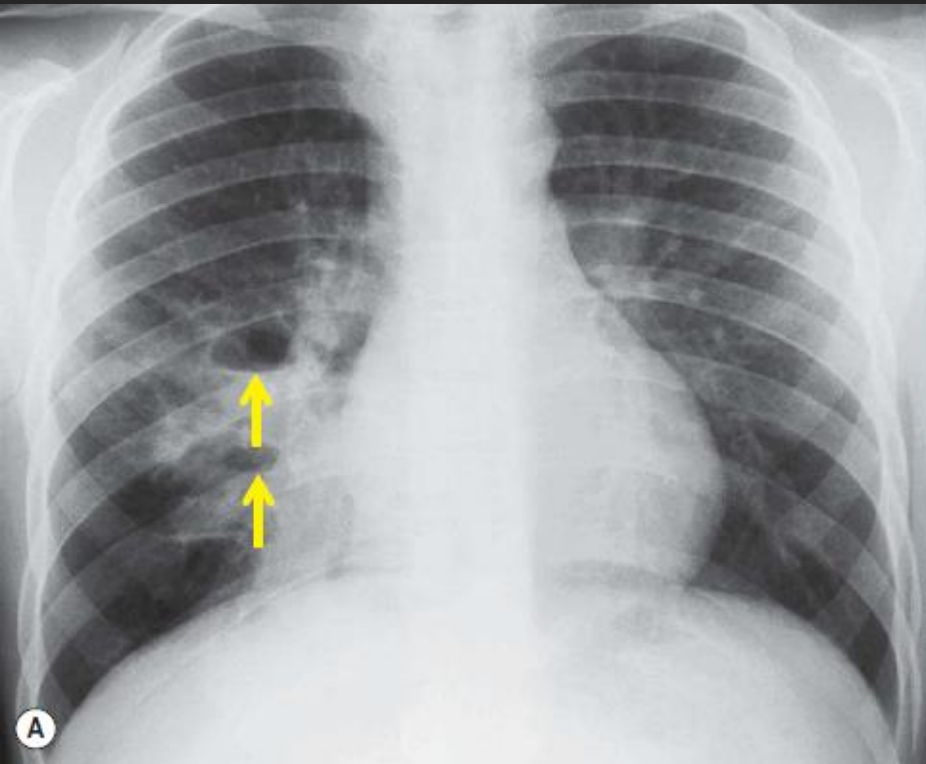
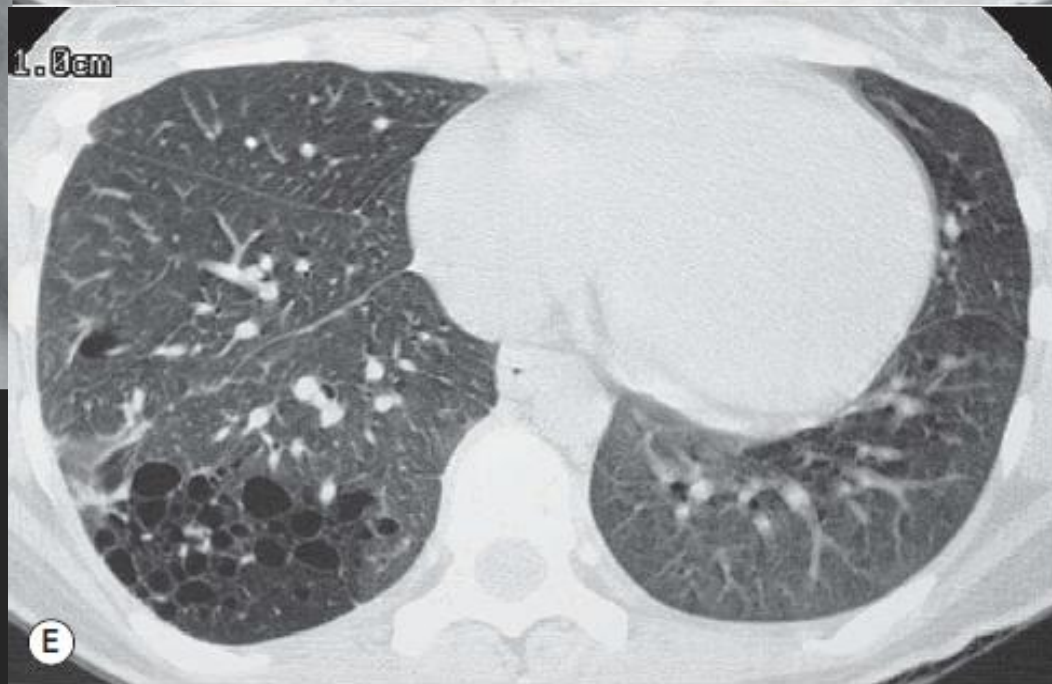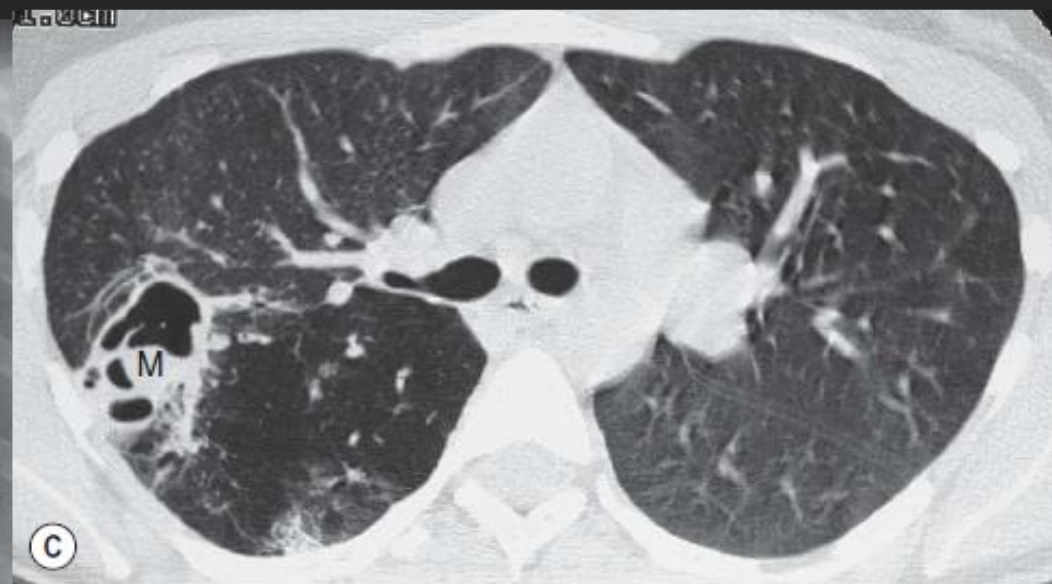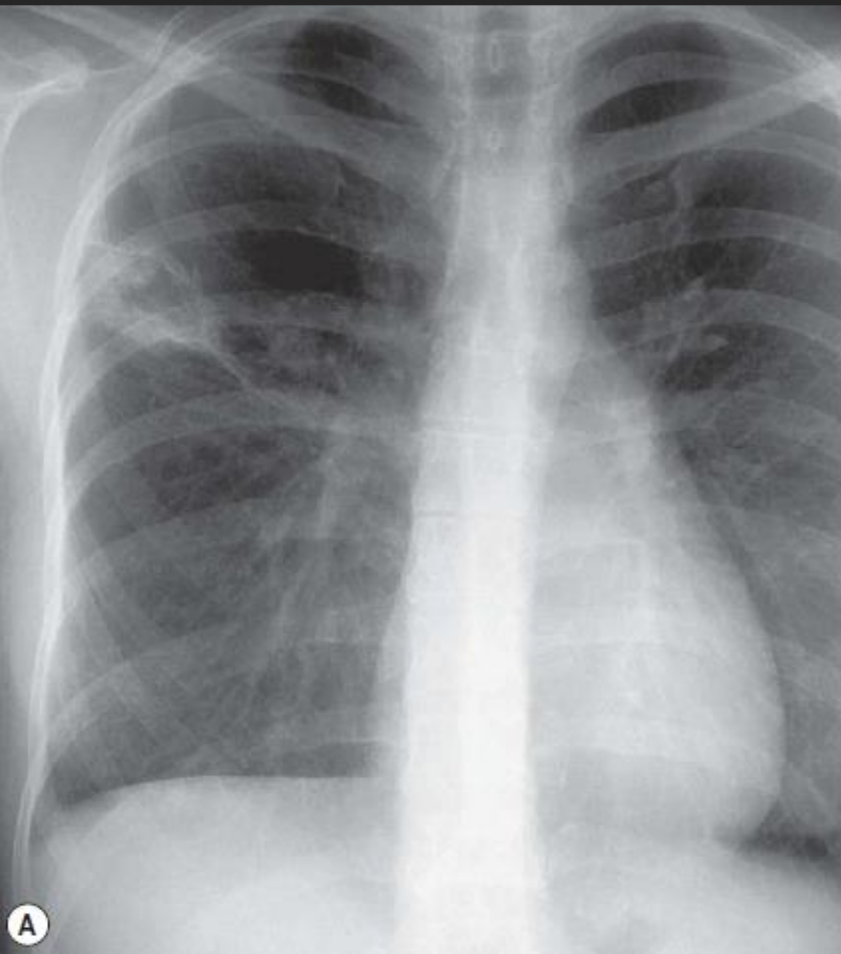


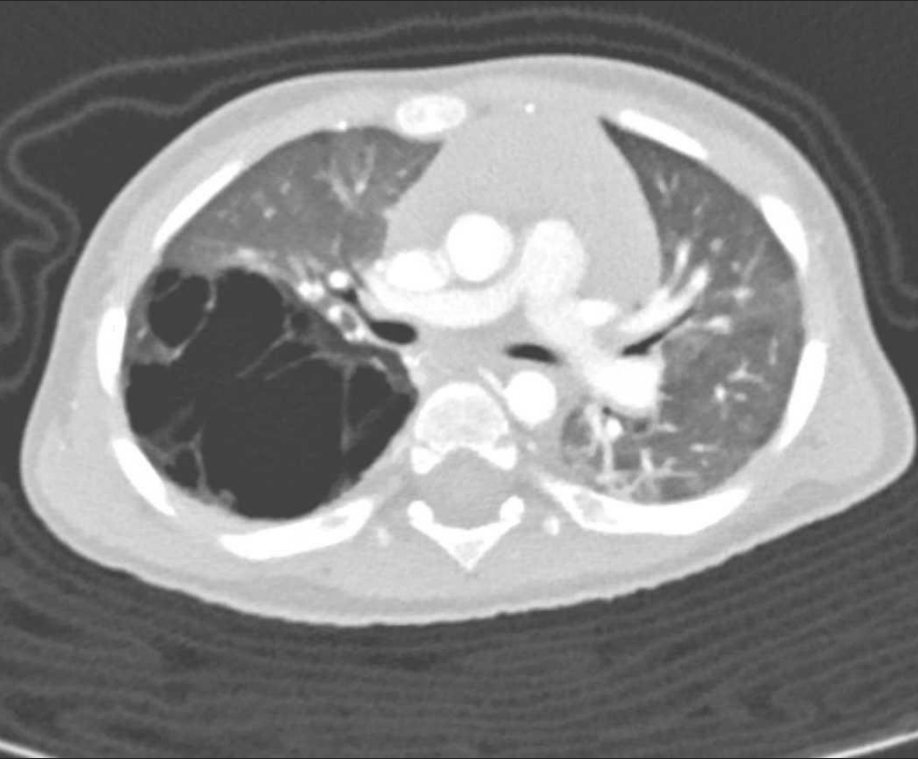Fig. 16.50 Congenital cystic adenomatoid malformation of the right lung in a 7-year-old boy with a history of recurrent pneumonia. **A**, Frontal chest radiograph shows a heterogeneous right lung mass with multiple air-fluid levels (arrows). **B**, CT (lung window) shows a multicystic mass in the right lower lobe. (Courtesy of J R Galvin, MD, Armed Forces Institute of Pathology, Washington, DC, USA.)

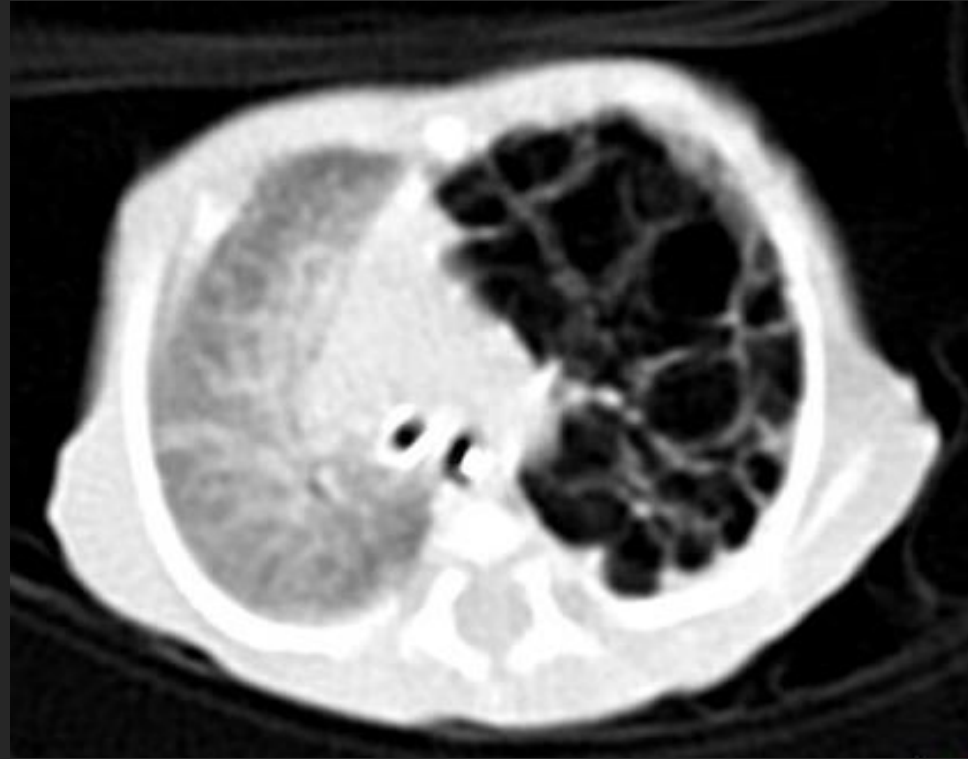CPAM + Aspergilloma



Congenital pulmonary airway malformation (CPAM)



Case courtesy of Dr Yair Glick, Radiopaedia.org, rID: 73514



Case courtesy of Dr Ahmed Abdrabou, Radiopaedia.org, rID: 25491

Acknowledge

台北榮總

蕭逸函 醫師



Thanks for your attention!

安泰醫院胸腔內科 潘奕宏
990317kmuh@gmail.com

