


北京大學第一醫院

- 1912年北京医科专门学校成立
- 1914年民国教育部批准设立诊察所
- 1915年诊察所正式开诊
- 1946年与北京大學合并—“北大醫院”
- 誕生了北京大學腫瘤醫院、北京大學口腔醫院、北京大學精神病院



北京大學第一醫院
PEKING UNIVERSITY FIRST HOSPITAL



精准、转化、整合 —介入呼吸病学未来展望

北京大学第一医院呼吸和危重症医学科

北京胸部微创手术中心

王广发



北京大学第一医院
PEKING UNIVERSITY FIRST HOSPITAL

来自呼吸系统疾病的挑战!

- Lung Cancer:
 - crude incidence rate: 49.35 per 100,000 population¹
 - crude mortality rates: 47.51 per 100,000 men and 22.69 per 100,000 women(2008)²
- Pulmonary tuberculosis:
 - incidence: 91.6 per 100,000 person-year³
- COPD: prevalence 8.2%⁴
- Asthma: prevalence in Children 3.3%⁵
 - ILD: Male 31.5 / 100,000/yr , femal 26.1 per 100,000/yr

1. Chen WQ, et al. Thoracic Cancer. 2010;1(1):35-40
2. She J, et al. Chest. 2013;143(4):1117-1
3. Chen W, et al. PLoS One. 2013;8(3):e58171.
4. N. Zhong, et al., Am J Respir Crit Care Med, 2007
5. Li F, et al. BMC Public Health 2011; 11: 437.



The Full Spectrum of Interventional Pulmonology Technologies

- Fundamental bronchoscopy
- Advanced diagnostic bronchoscopy
 - TBNA, EBUS, Navigation bronchoscopy.....
- Therapeutic bronchoscopy technologies
 - Electrocautery, Cryotherapy, APC, Laser, Stents, Balloon dilation, Brachytherapy, PDT, Rigid bronchoscopy, Fistula plugging.....
 - Mini-tracheostomy
- Therapeutic modalities for chronic airway diseases
 - BLVR, Rheoplasty.....
 - Bronchial Thermoplasty for Asthma
- Thoracoscopy
- Vascular interventional technologies
- Trans-thoracic Interventional technologies



医学的未来发展

- 精准医学
- 转化医学
- 整合医学



北京大学第一医院
PEKING UNIVERSITY FIRST HOSPITAL



介入呼吸病学的热点领域

- 诊断

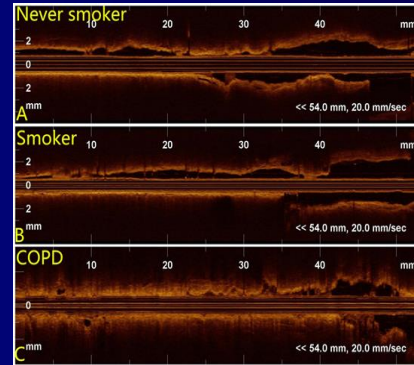
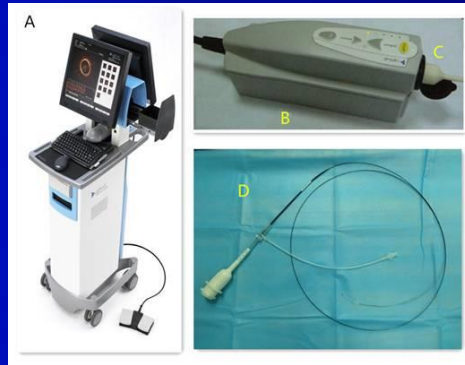- 早期肺癌的诊断
- 慢性气道疾病的早期诊断与研究
- 弥漫性肺病的诊断与研究
- 感染性疾病的病原学诊断及耐药检测
- 胸膜疾病的诊断

- 治疗

- 早期肺癌的微创治疗
- 慢性气道疾病的治疗
- 中心气道狭窄的治疗
- 气管支气管瘘及持续漏气的治疗
- 胸膜疾病的治疗



OCT用于早期COPD诊断与研究



- Modification of Methodology make OCT can measure the 5th generation airways to the 9th
- OCT can be used to find the early change of COPD
- IOS parameters are correlated with OCT changes

Chen Y, et al. Validation of human small airway measurements using endobronchial optical coherence tomography. *Respir Med.* 2015

Ding M, et al. Measuring Airway Remodeling in Patients With Different COPD Staging Using Endobronchial Optical Coherence Tomography. *Chest.* 2016. 150(6): 1281-129

Su ZQ, et al. Significances of spirometry and impulse oscillometry for detecting small airway disorders assessed with endobronchial optical coherence tomography in COPD[J]. *International journal of COPD*, 2018

Su ZQ, et al. Evaluation of the normal airway morphology using optical coherence tomography. *Chest.* 2019

Courtesy of Dr. Li Shiyue



北京大学第一医院
PEKING UNIVERSITY FIRST HOSPITAL

支气管镜采样技术与现代生物学结合

- 灌洗液
- 刷检
- 冲洗
- 可见病变活检
- TBLB
- 针吸活检
- 微生物组学
- 基因组学
- 蛋白质组学
- 表观遗传组学
- 代谢组学

- 间质性肺炎诊断、机制的研究及生物标志的寻找
- 感染性疾病的诊断及耐药监测
- 肿瘤的诊断及分子分型



Thermal Liquid Biopsy (TLB)

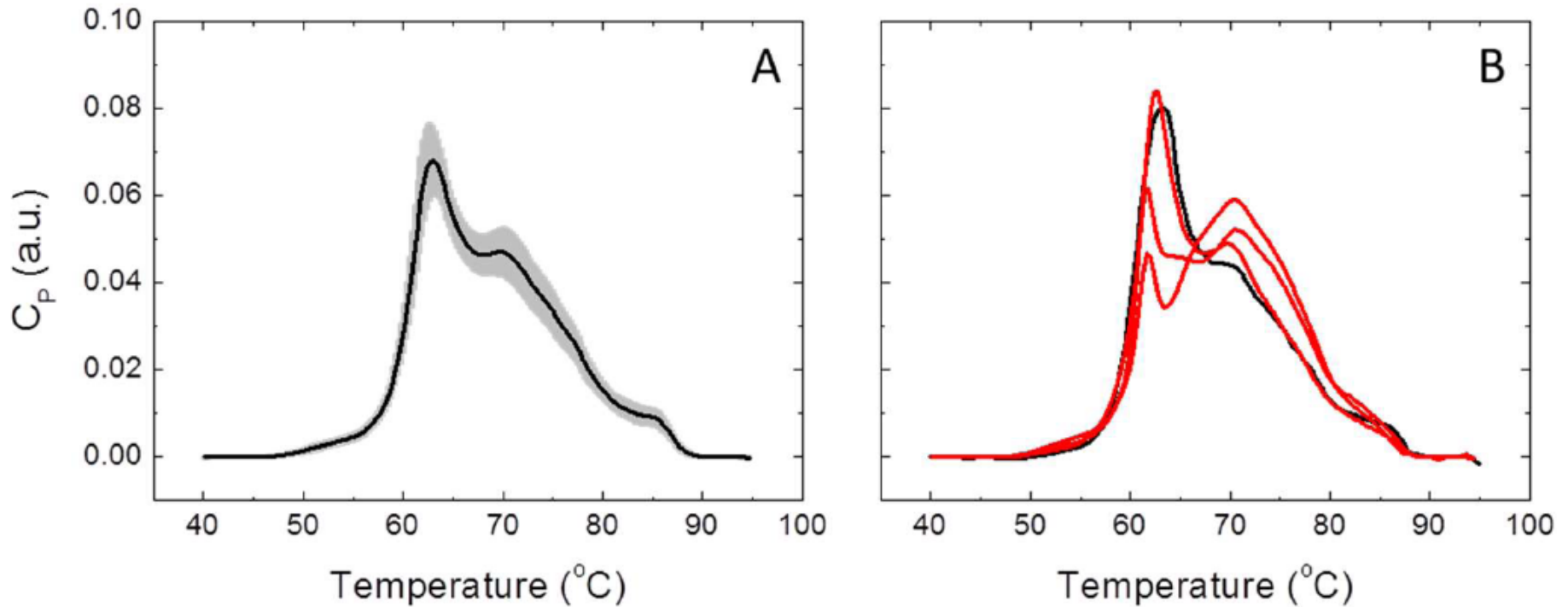


Figure 1. Thermal liquid biopsy (TLB) serum thermograms for healthy control (HC) and lung cancer patient (LCP) individuals. (A) Average TLB thermogram calculated with all subjects belonging to the HC group (continuous line) is shown together with the standard deviation of the thermograms at each temperature (shaded region). (B) TLB thermogram for a healthy subject (black line) compared to three thermograms from lung cancer patients (red lines).

Rodrigo A, et al. *Cancers (Basel)*. 2019 Jul 19;11(7). pii: E1012. doi: 10.3390/cancers11071012.

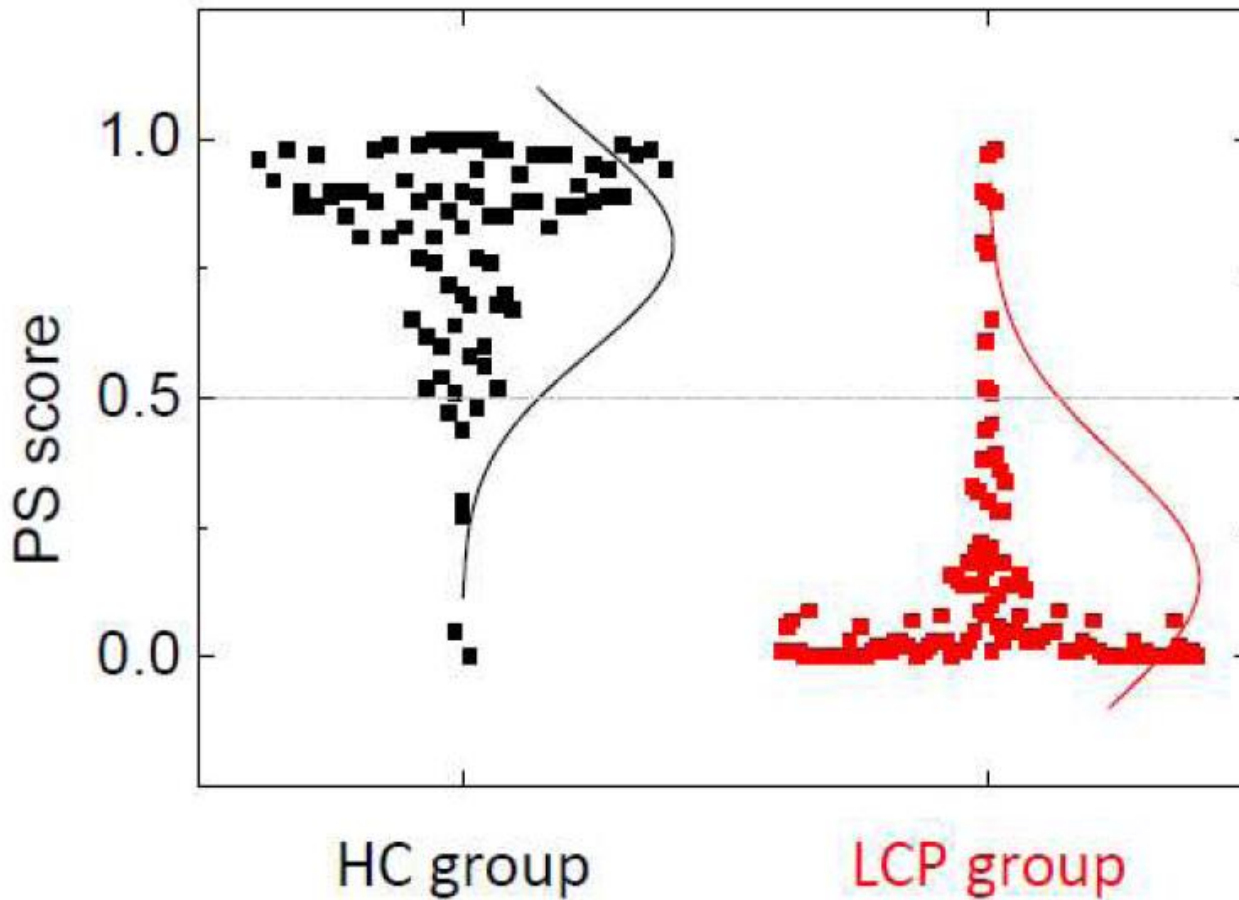
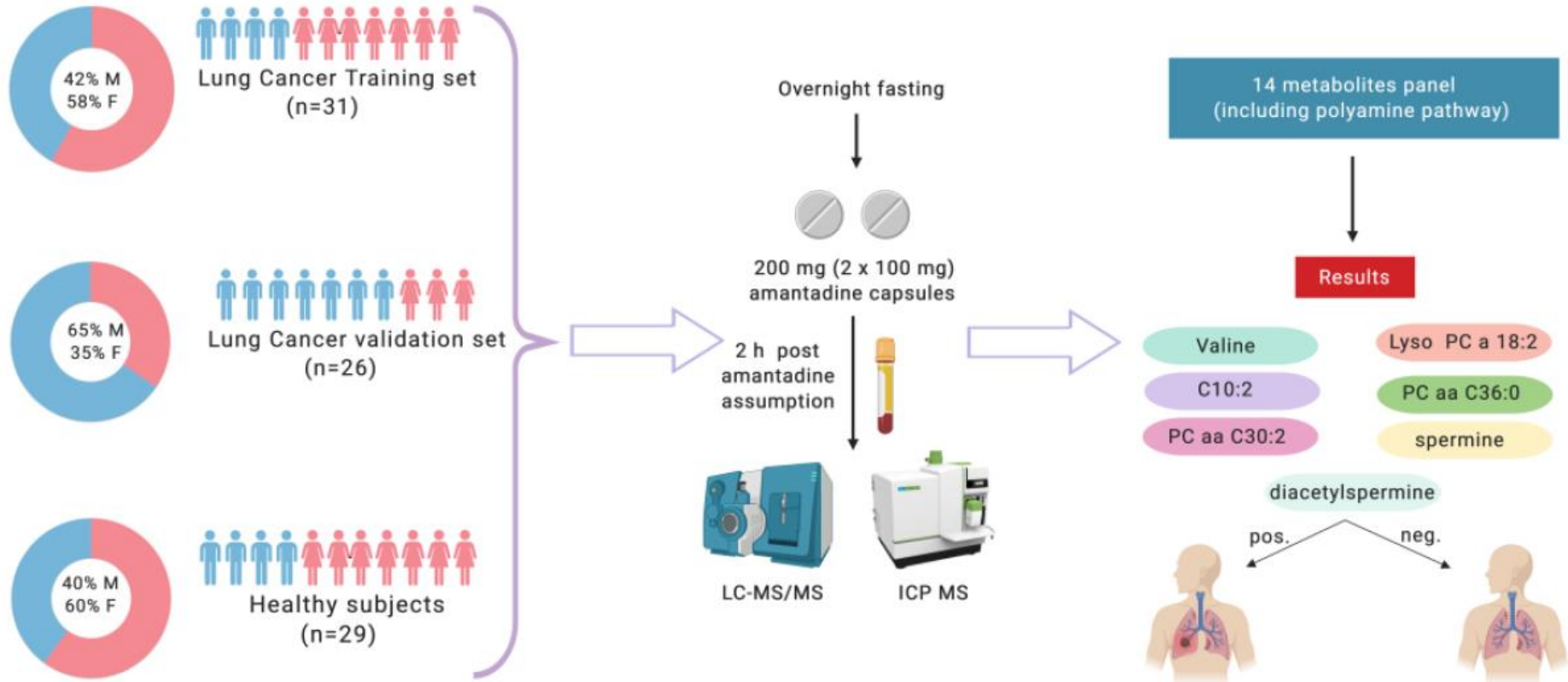


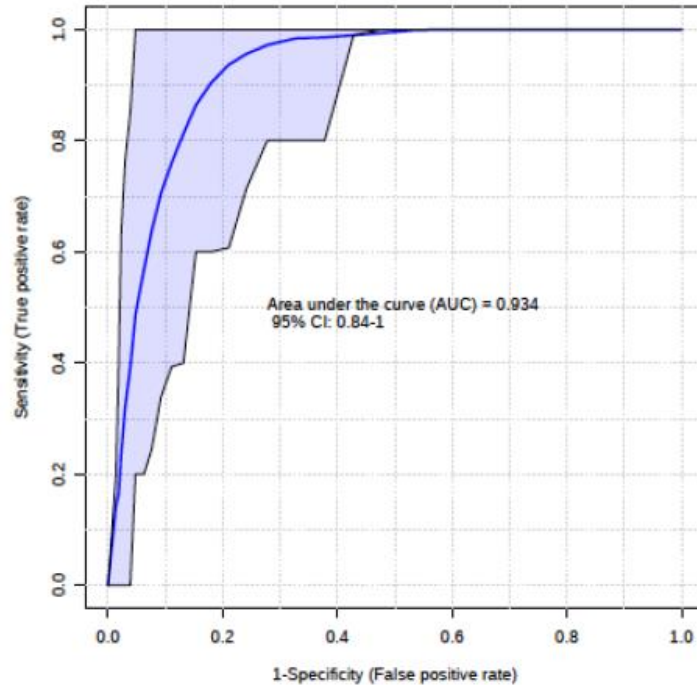
Figure 3. Distribution of the probability score (PS) score within healthy individuals (HC group) and lung cancer patients (LCP group). The lines represent an equivalent Gaussian distribution. The PS score threshold for discriminating between an unaltered (associated with healthy status) and altered (associated with lung cancer status) serum proteome thermal liquid biopsy (TLB) thermogram is 0.5 (grey dotted line). It can be observed that seven healthy subjects are assigned a PS score lower than 0.5 (8% false positive rate) and 11 lung cancer subjects are assigned a PS score higher than 0.5 (10% false positive rate).

Liquid Biopsy in Lung Cancer Screening: The Contribution of Metabolomics

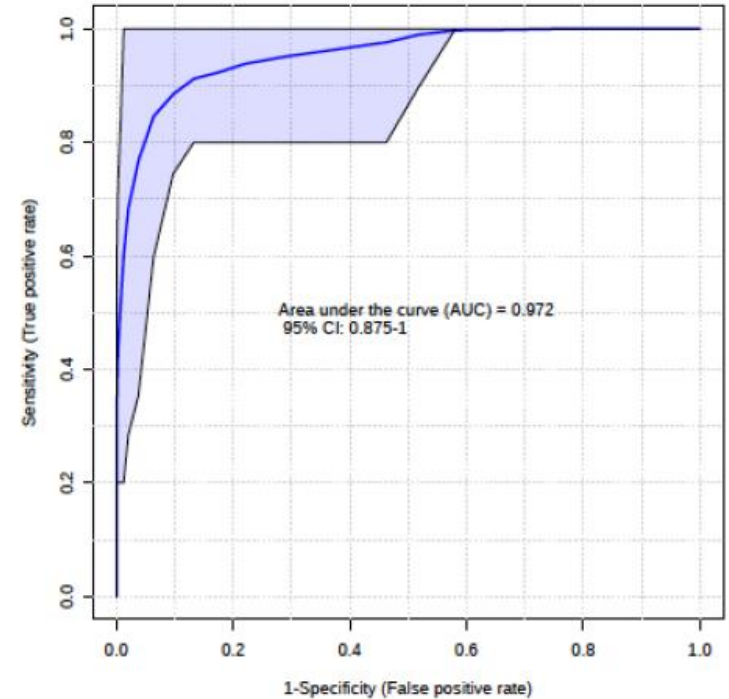


Singhal S, et al. Cancers (Basel). 2019 Jul 29;11(8). pii: E1069. doi: 10.3390/cancers11081069

A

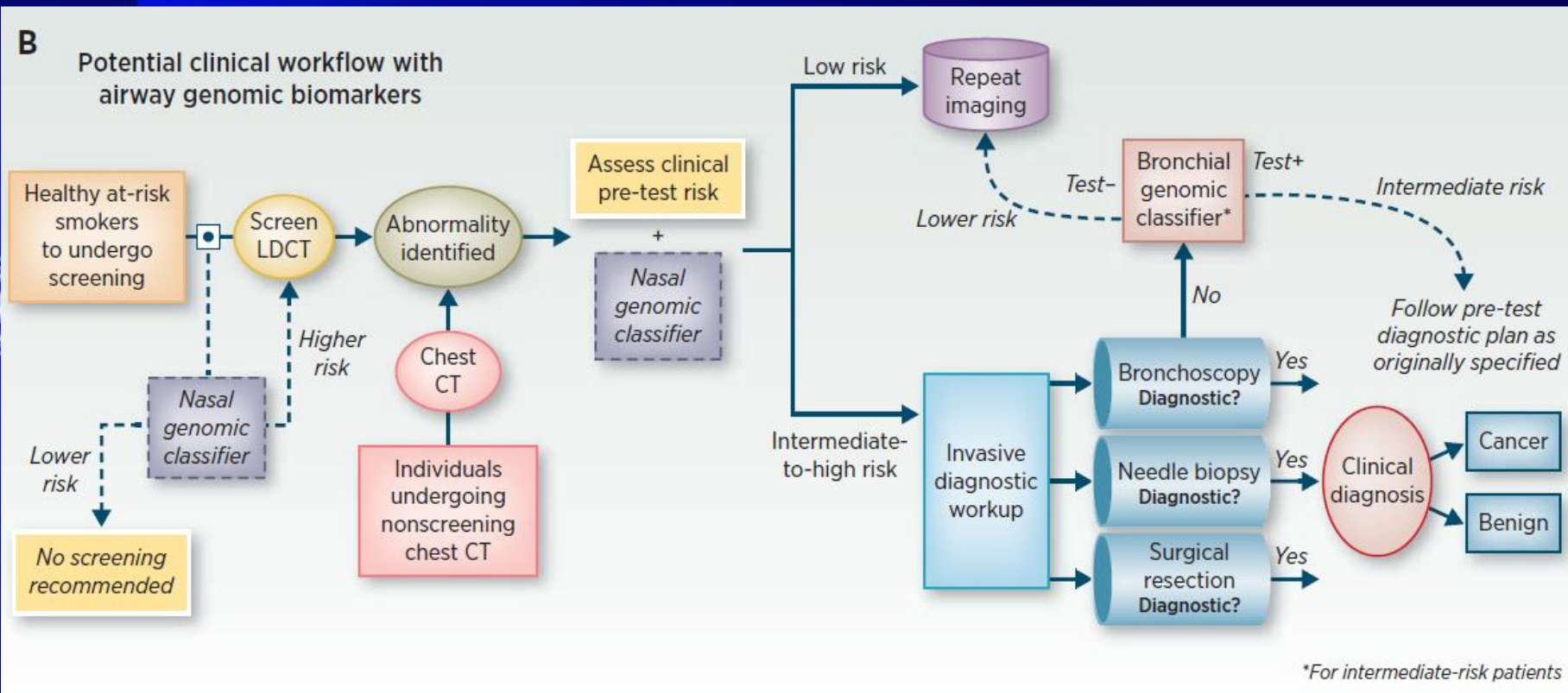


B



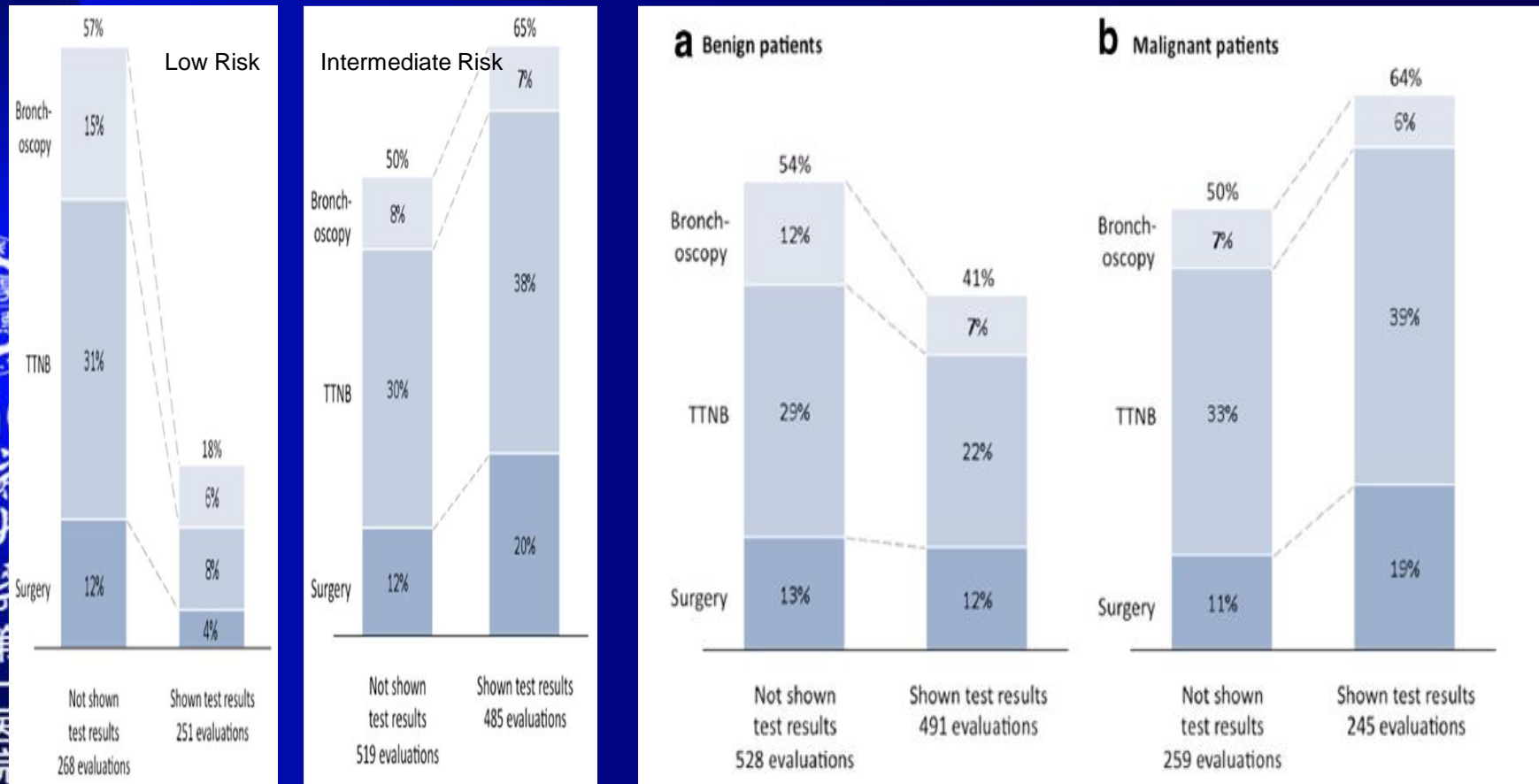
linear regression multivariate modeling with multiple combinations of metabolites 5 metabolites included valine, putrescine, PC.ae.C36.0, PC.aa.C32.2 and C10.2 (A) and 3 key metabolites Valine, Spermine and Ornithine (B).

The Airway Transcriptome as a Biomarker for Early Lung Cancer Detection



Billatos E, et al. Clin Cancer Res. 2018 Feb 20. pii: clincanres.3187.2017. doi: 10.1158/1078-0432.CCR-16-3187.

Impact of a bronchial genomic classifier on clinical decision making in patients undergoing diagnostic evaluation for lung cancer



肺癌早期诊断技术需要整合

- 荧光支气管镜
- 窄谱成像技术
- 共聚焦荧光支气管镜
- 光相干断层扫描 (OCT)
- Raman spectroscopy
- 透视辅助
- CT辅助/Cone beam-CT
- 超细支气管镜
- EBUS
- 虚拟支气管镜
- 电磁导航

基于效果和卫生经济学



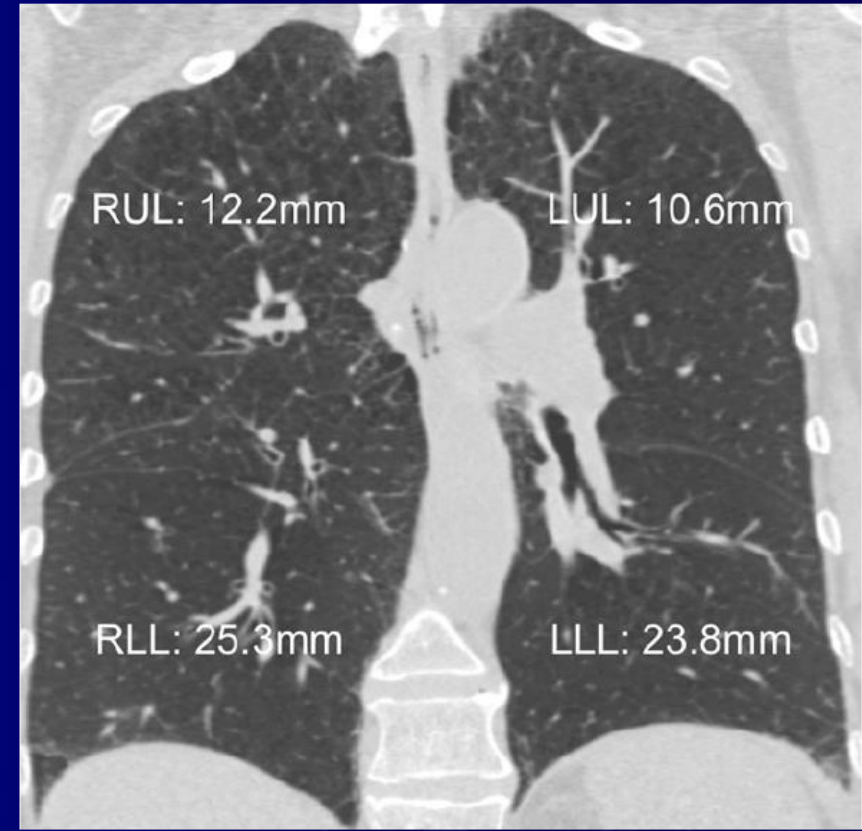
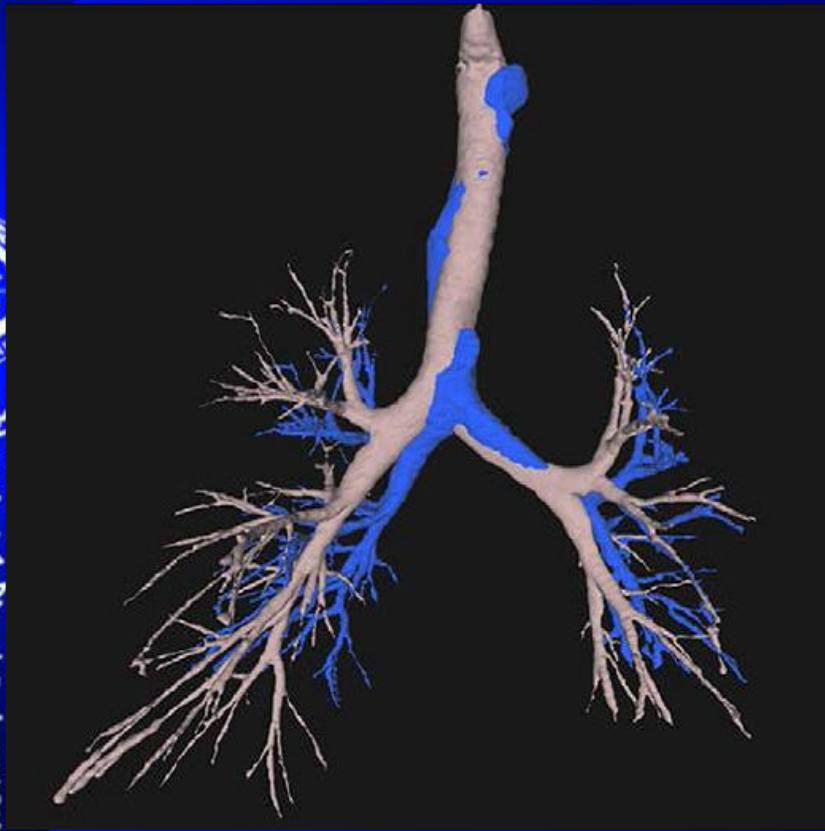The drawbacks of navigation technologies

- Not all technologies are real time
- All “maps” are not precision
 - The standardization of CT
 - The influence of respiration and heart beat



The effect of respiratory motion on pulmonary nodule location

Inspiration vs Expiration



肺癌早期介入诊断技术需要更多的转化 医学研究

- 呼吸门控技术的发展
- 精准定位技术
- 人工智能和机器人
- 新的成像技术

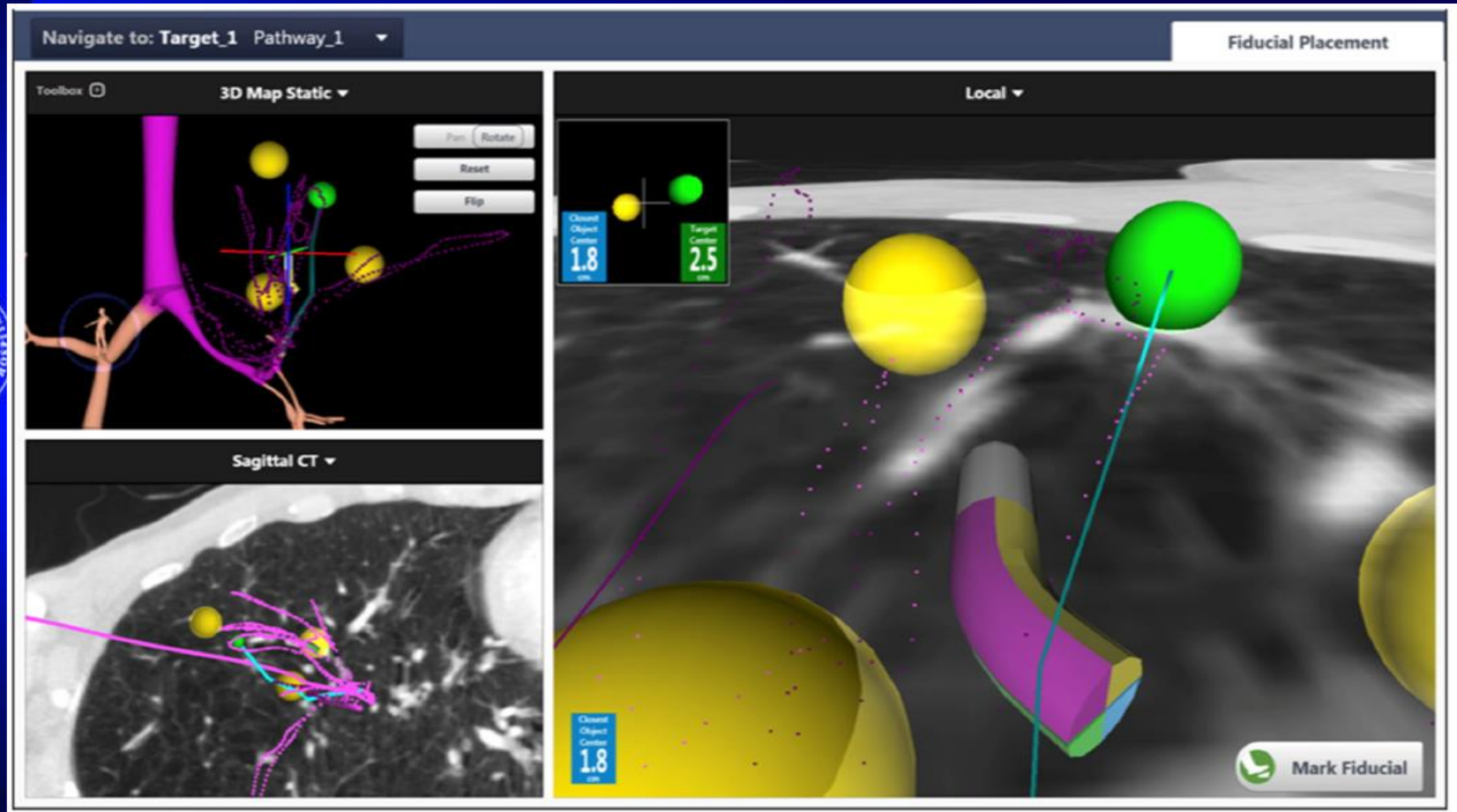


需要整合诊断和治疗技术

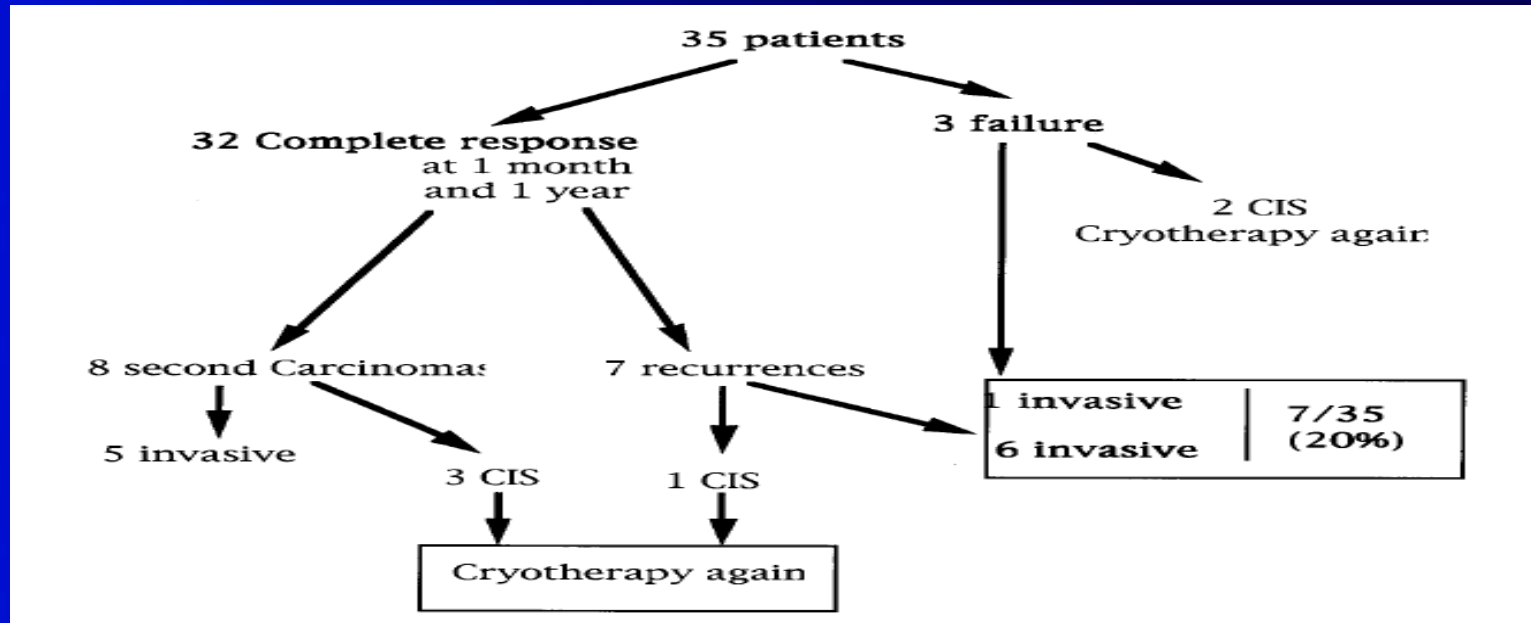
- 准确判断深度
- 精準定位
- 恰当的消蚀范围和深度
- 彻底的消蚀方法
- 肿瘤免疫的作用
- 长期疗效的确定
- 适应证的选择



Improved respiratory motion tracking through a novel fiducial marker placement guidance system during electromagnetic navigational bronchoscopy



Can bronchoscopic Interventional therapy be a choice of earlier lung cancer?



- Complete response rate at both 1 month and 1 year was 91%
- No severe adverse effect was noted
- Local recurrence was observed within 4 years in 28%
- 50% were long-term survivors

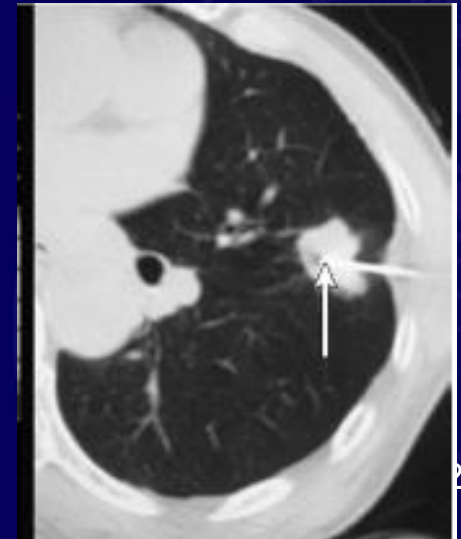


光动力治疗早期肺癌

Publication	Indication	Photosensitizer	No. of Patients	Outcome
Furukawa et al., 2005 (49)	CLELC	Porfimer sodium	93	CR: 92.8%/58.1% (less/greater than 1-cm lesion)
Corti et al., 2007 (51)	CLELC	Porfimer sodium II (50%), hematoporphyrin derivative (50%)	40	CR: 72%, PR: 20%, NR: 6%
Usuda et al., 2007 (52)	CLELC	Talaporfin sodium	29	CR: 92.1%, PR: 7.9%
Moghissi et al., 2007 (50)	CLELC	Porfimer sodium	21	CR: 100%
Endo et al., 2009 (41)	CLELC	Porfimer sodium	48	CR: 94%
Usuda et al., 2010 (54)	CLELC	Talaporfin sodium	75	CR: 94%/90.4% (less/greater than 1-cm lesion)
Usuda et al., 2010 (53)	CLELC	Talaporfin sodium	64	CR: 100%

Can transcutaneous interventional be used for early lung cancer ?

- Patients with biopsied stage I NSCLC determined by PET/CT
SLR (n = 25; 11 men, 13 women; median age 66 years, range 49 to 85 years),
RFA (n = 12; 8 men, 4 women; median age 74 years, range 62 to 83 years)
PCT (n = 27; 16 men, 11 women; median age 74 years; range 59 to 88 years)
- The probability of 3-year survival: ($p > 0.05$)
 - SLR, 87.1%
 - RFA, 87.5%,
 - PCT 77%



Zemlyak A, et al. J Am Coll Surg. 2010 Jul;211(1):68-72



可能用于早期肺癌消融的技术

可见部位

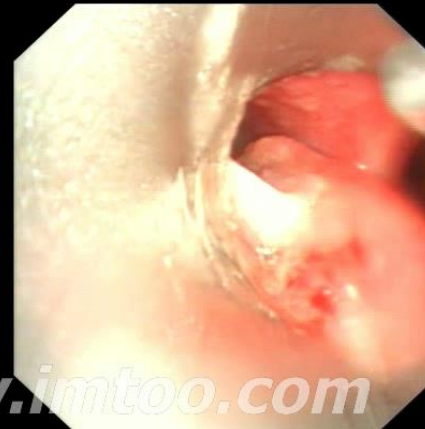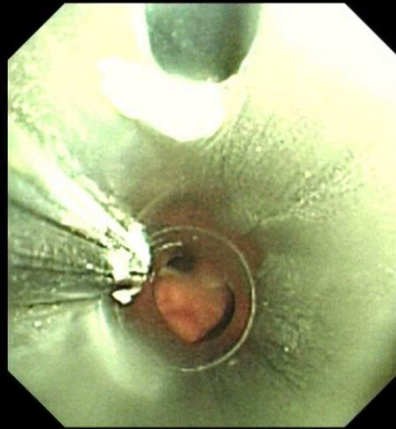
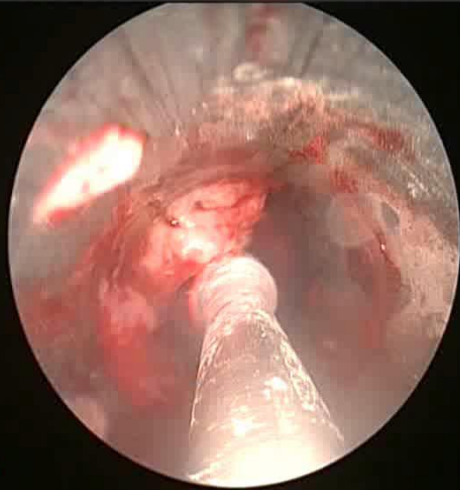
- 光动力
- 电烧蚀
- APC
- 激光
- 冷冻
- 海博技术
-

非可见部位

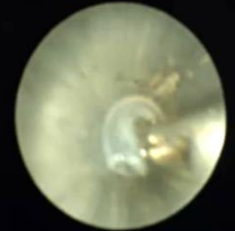- 间质光动力
- 氩氦刀
- 射频
- 粒子置入
- 热蒸汽
-



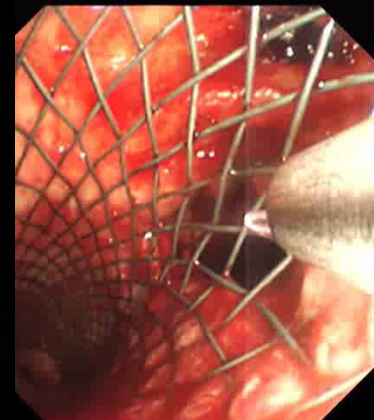
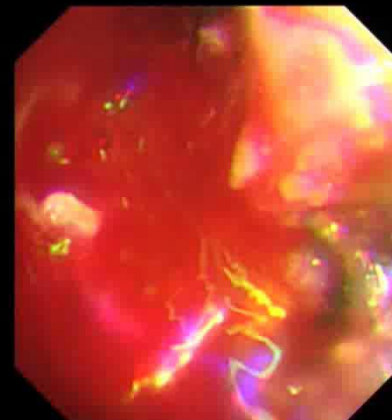
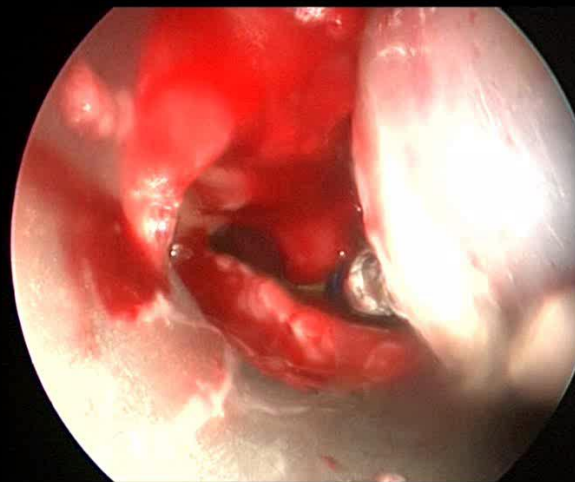
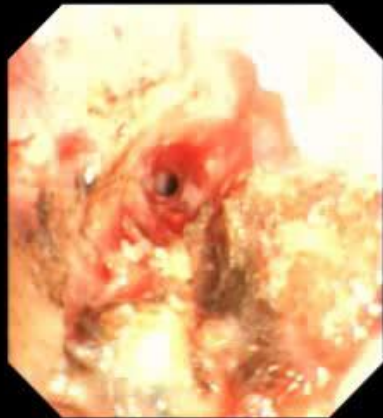
中心氣道病變的處理技術



5



v.imtuo.com




良性气道狭窄的精准治疗

- 外科手术**vs**腔镜下治疗
- 需要新型支架——改善组织相容性及适形性
- 新的弱刺激消融技术
- 软骨重建和再生技术
- 针对肉芽的靶向治疗？

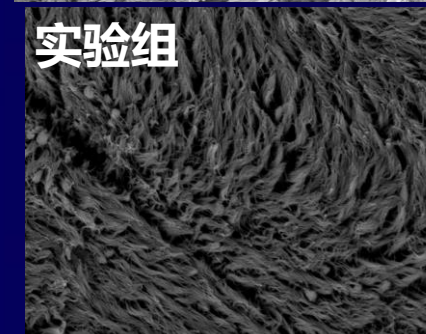
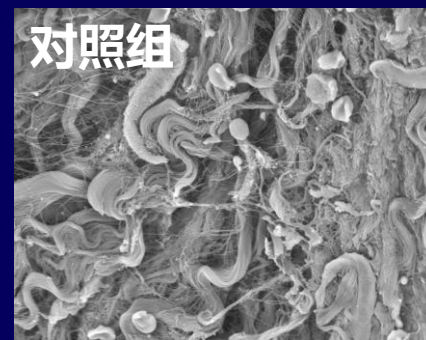
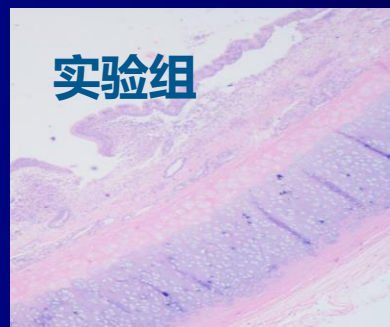
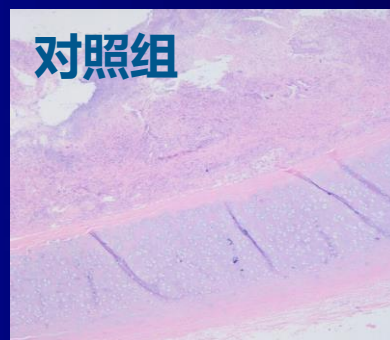
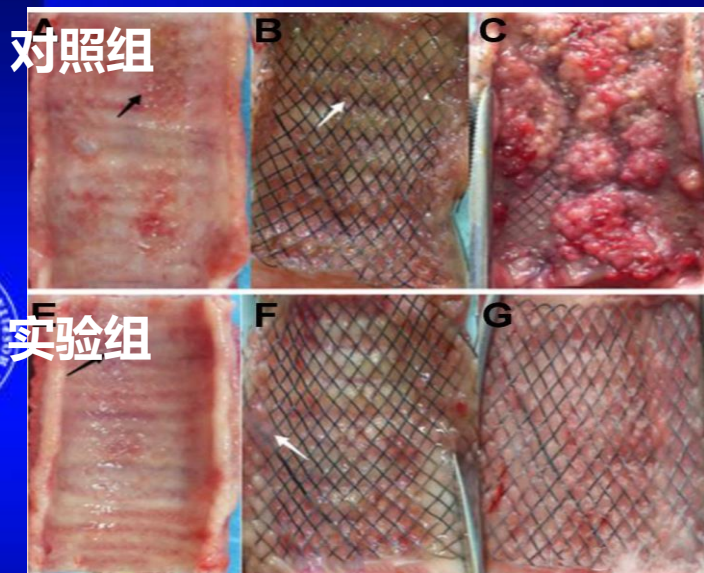


气道支架改善组织相容性的方向

- 镀膜或洗脱药物——针对上皮细胞及气道纤维组织增生
- 生物降解支架
 - 缺乏血流——降解速度慢？
 - 降解过程——断裂——利？弊？
 - 降解速度与瘢痕稳定时间的关系



紫杉醇洗脱支架的有效性和安全性



A、B: 对照组支架术后第1及第3个月
E、F: 实验组支架术后第1及第3个月
C: 对照组支架术后第5个月
G: 实验组支架术后第5个月

光镜: 支架置入5月
后气管上皮变化
(40倍)

电镜: 支架置入5月后
气管纤毛变化
(2000倍)


张杰团队



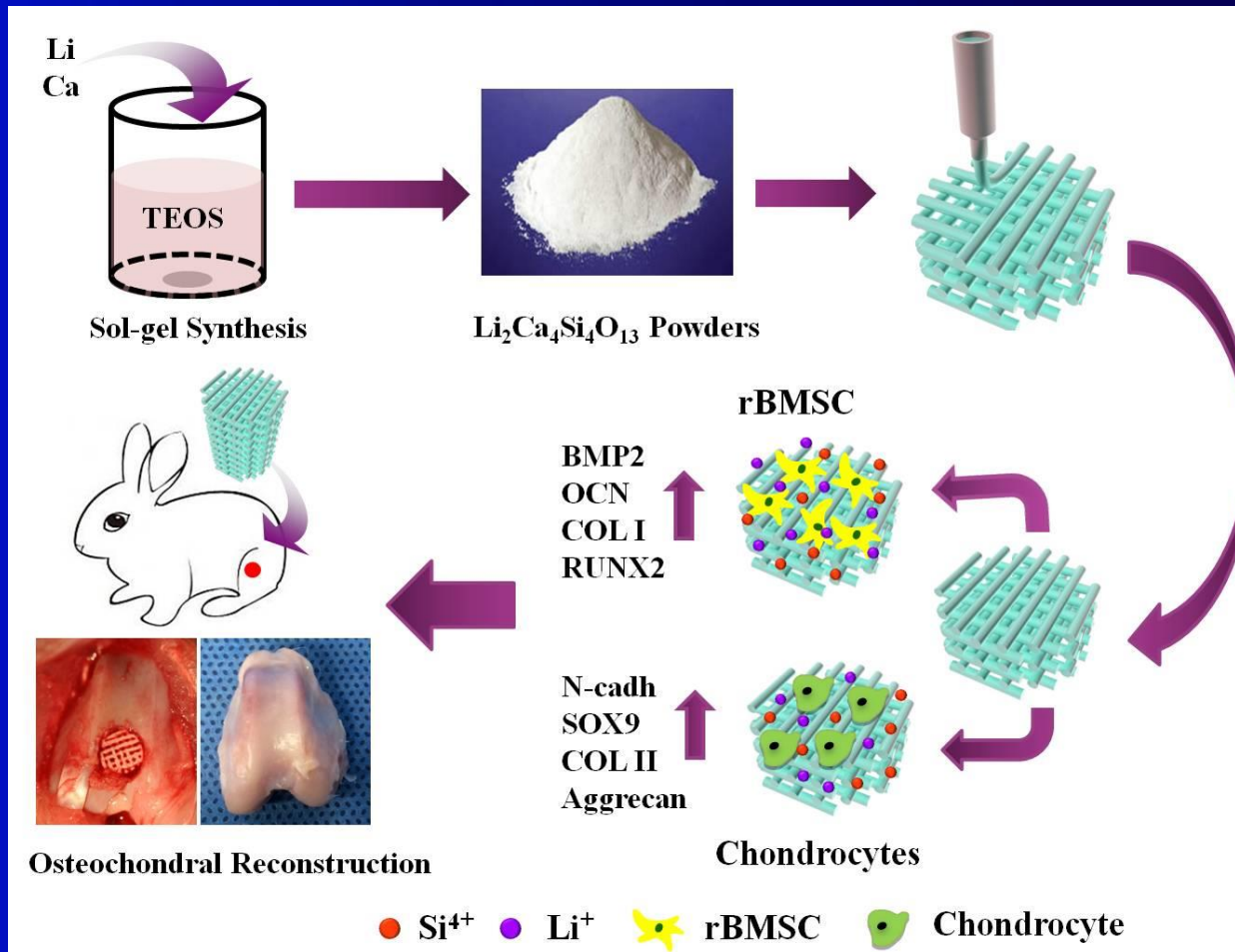
北京大学第一医院
PEKING UNIVERSITY FIRST HOSPITAL

改善支架的适形性

- 精确定制支架—3D打印
 - 减少成角
 - 减少移动
 - 张力适度



软骨再生技术

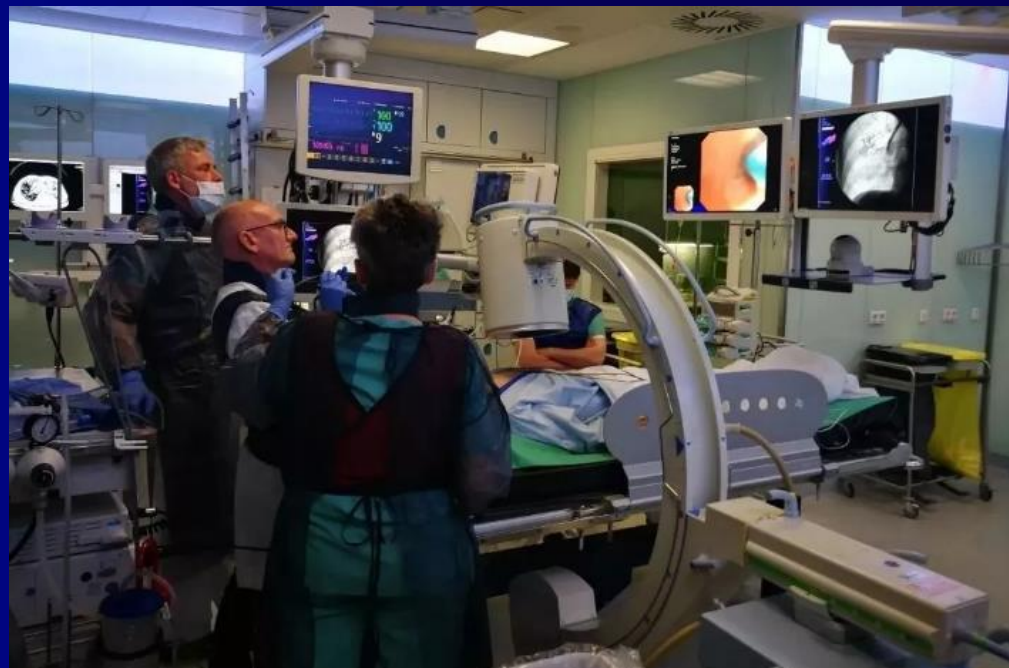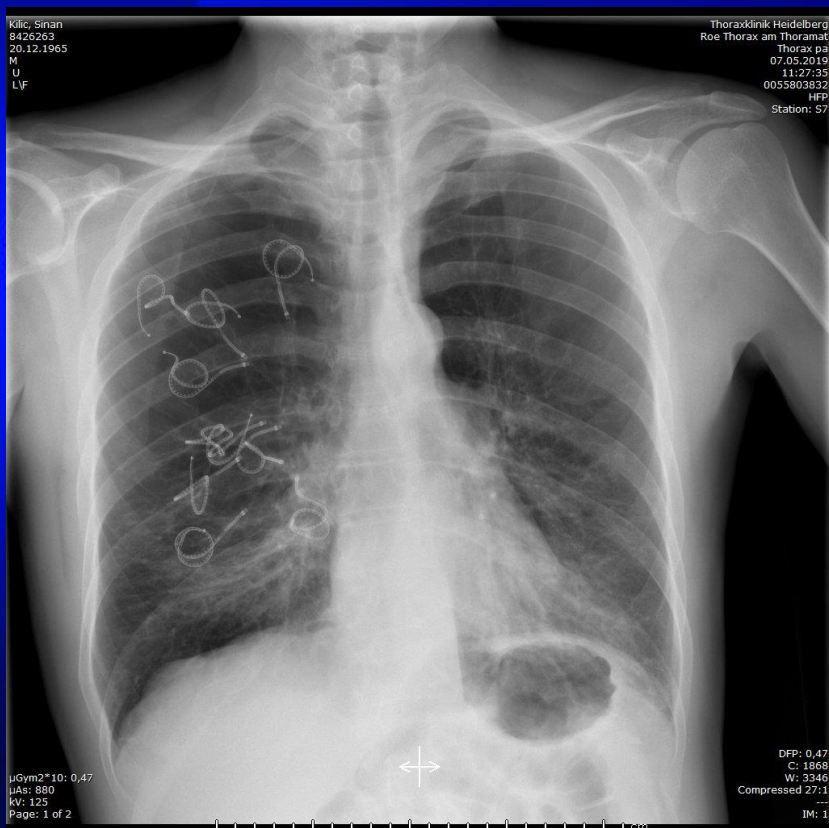


Bronchoscopic Interventional Procedures for COPD

- BLVR Valve
 - EBV&IBV
- Lung bending (Coil, Reverser)
- Biological gel
- Thermal Vapor Ablation
- Target Lung Denervation
- Cryo/thermo ablation for hypersecretion

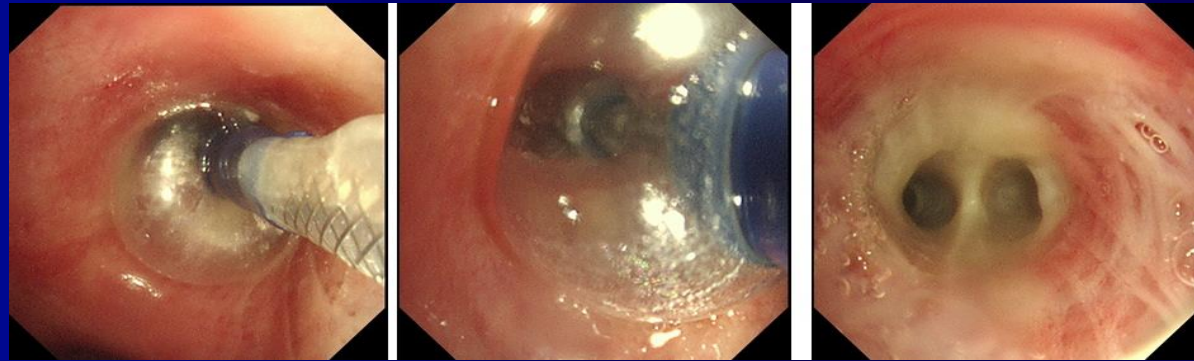


Reverser的首例人体试验

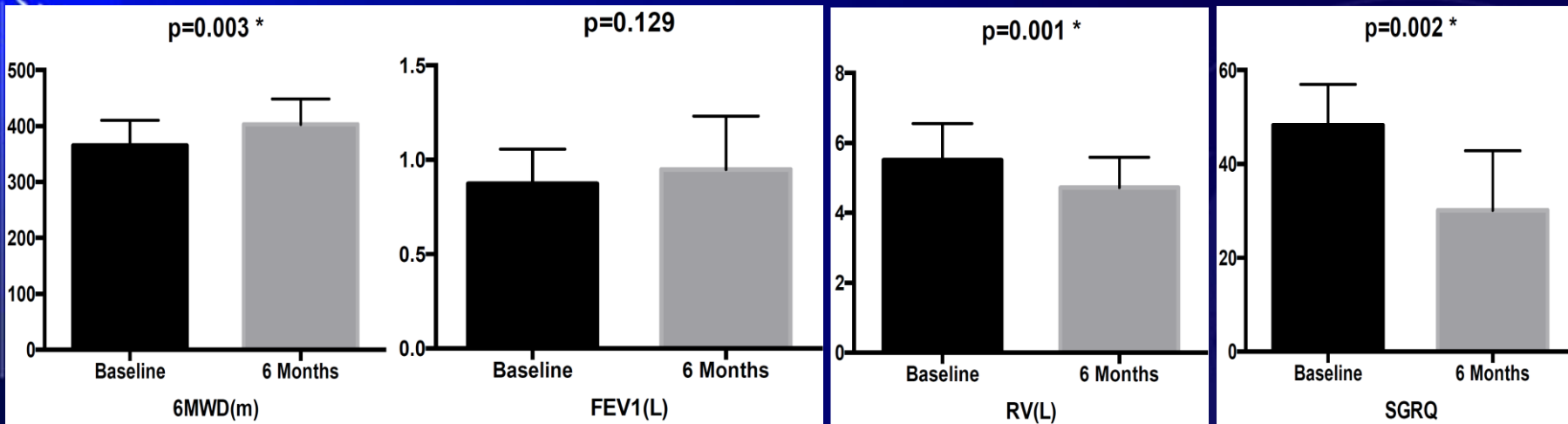


热蒸汽治疗COPD

- 四川大学华西医院
 - 重度COPD患者8例
 - 进行热蒸汽治疗
- 随访时间6月
男性，49-65岁

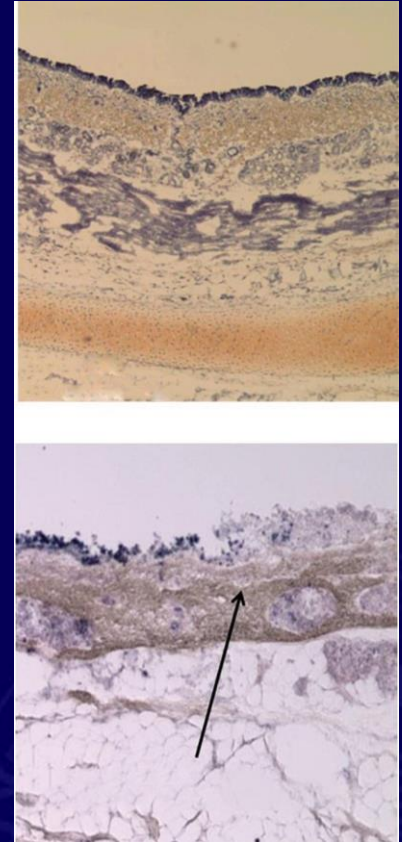


PEKING UNIVERSITY FIRST HOSPITAL



Liquid nitrogen metered cryospray

- 经支气管镜喷洒液氮至中央气道
- 冷冻消融厚度0.1-0.5mm
- 消除增生的杯状细胞及过多的腺体
- 上皮迅速再生
- 不形成瘢痕
- 正在进行临床研究——针对支气管炎型



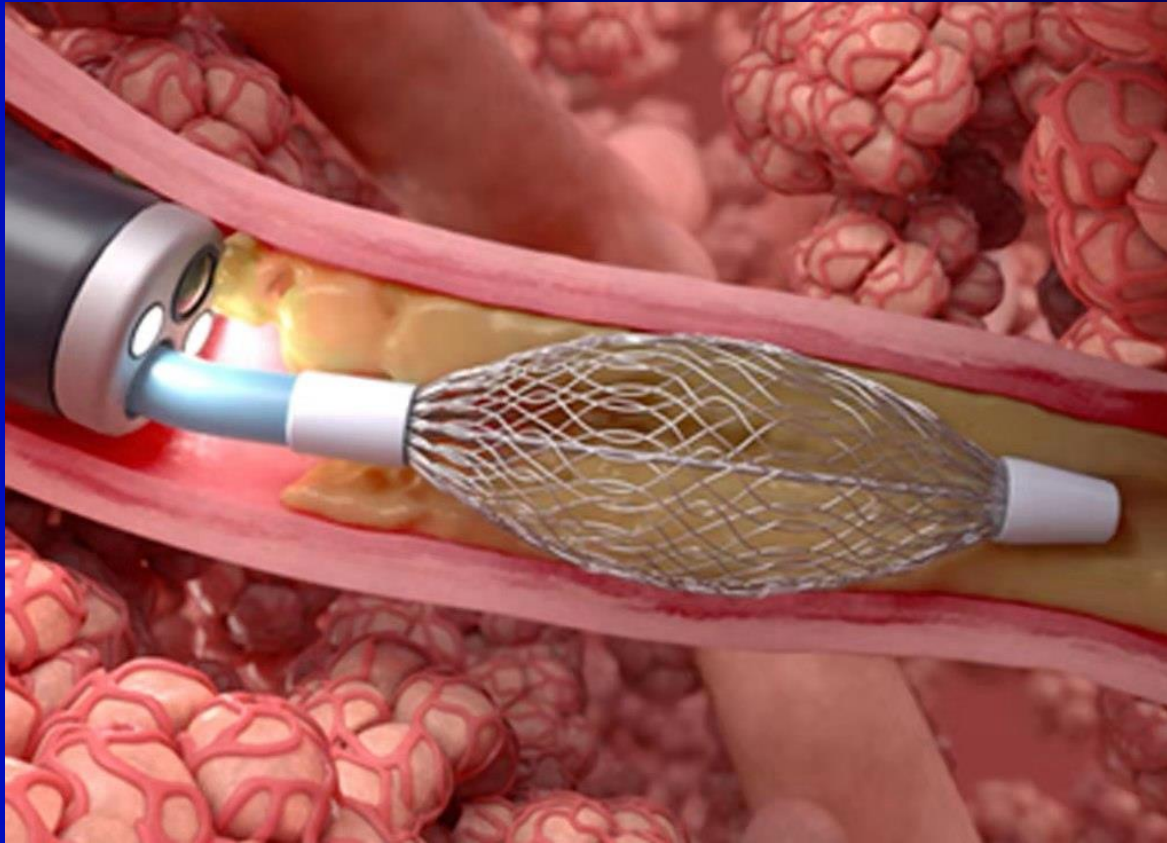
北京大学第一医院
PEKING UNIVERSITY FIRST HOSPITAL

Mulcahey TI, et al. Metered Cryospray™: a novel uniform, controlled, and consistent in vivo application of liquid nitrogen cryogenic spray. *Med Devices (Auckl)*. 2017 Feb 17;10:29-41. doi: 10.2147/MDER.S124098. eCollection 2017.

Coad, J. E., & Bischof, J. C. (2003). Histologic differences between cryothermic and hyperthermic therapies. *Vol. 4954*. (pp. 27-36), 27-36.

Godwin, B. L., & Coad, J. E. (2009). Healing responses following cryothermic and hyperthermic tissue ablation. *Vol. 7181*. (pp. 718103-718109), 718103-718109.

Bronchial Rheoplasty

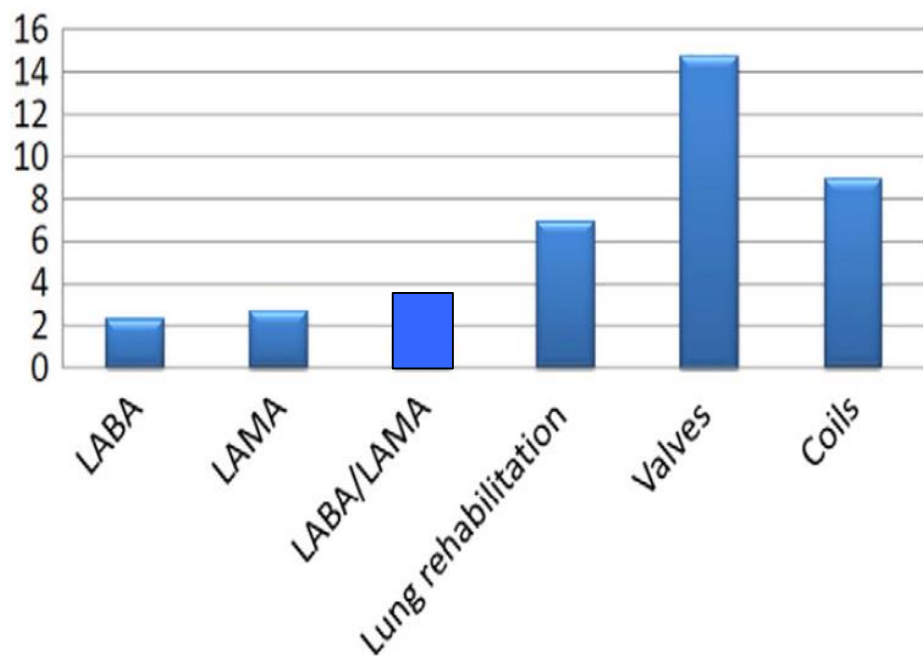


北京大学第一医院
PEKING UNIVERSITY FIRST HOSPITAL

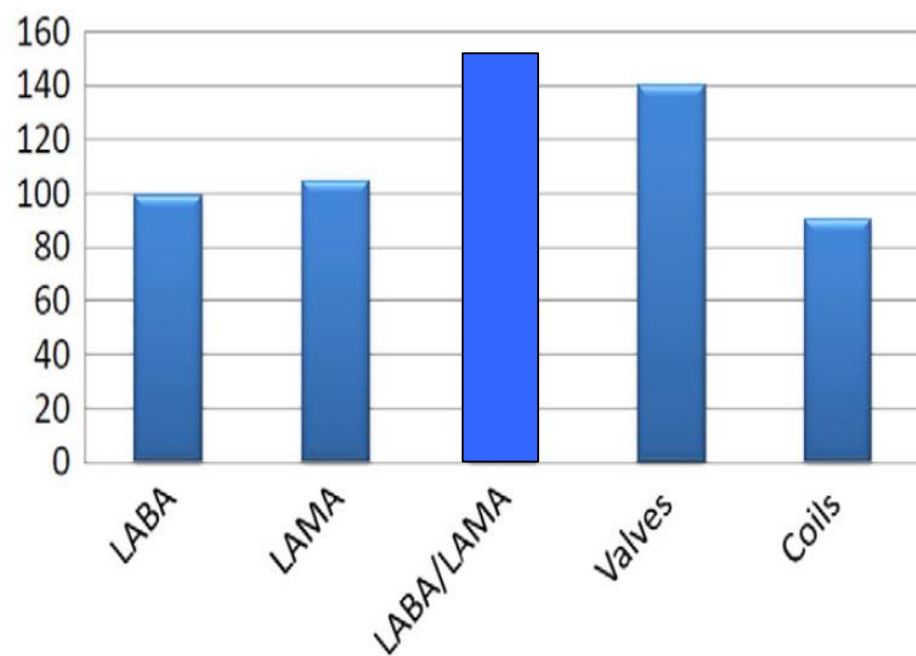
Valipour, Arschang & Ing, Alvin & Williamson, Jonathan & Saghale, Tajalli & Steinfort, Daniel & Irving, Lou & Snell, Gregory & Dabscheck, Eli & Krinsky, William & Waldstreicher, Jon & Fernandez-Bussy, Sebastian. (2018). Late Breaking Abstract - First-in-Human Results of Bronchial Rheoplasty: An Endobronchial Treatment For Chronic Bronchitis (CB). OA2162. 35
10.1183/13993003.congress-2018.OA2162.

支气管镜治疗与药物治疗的比较

Improvement in SGRQ



Improvement in FEV₁

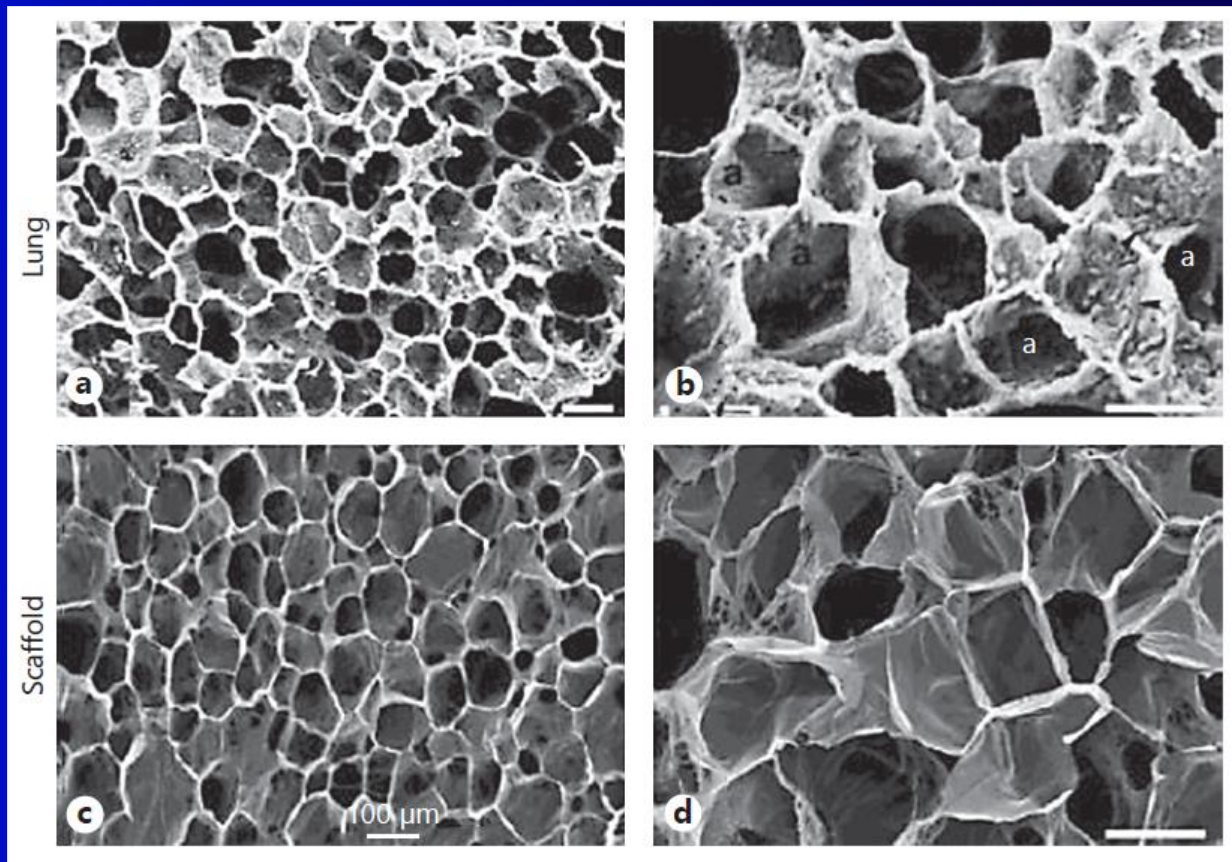


Precision patient selection is crucial

- Scientific and theory rationality
- COPD phenotype and different modalities
- Long term follow-up and large size RCTs
- Big Data studies
-



Organ regeneration or in situ repair



Thermoplasmy on the Treatment of Asthma in Mainland (by 2019.6.30)

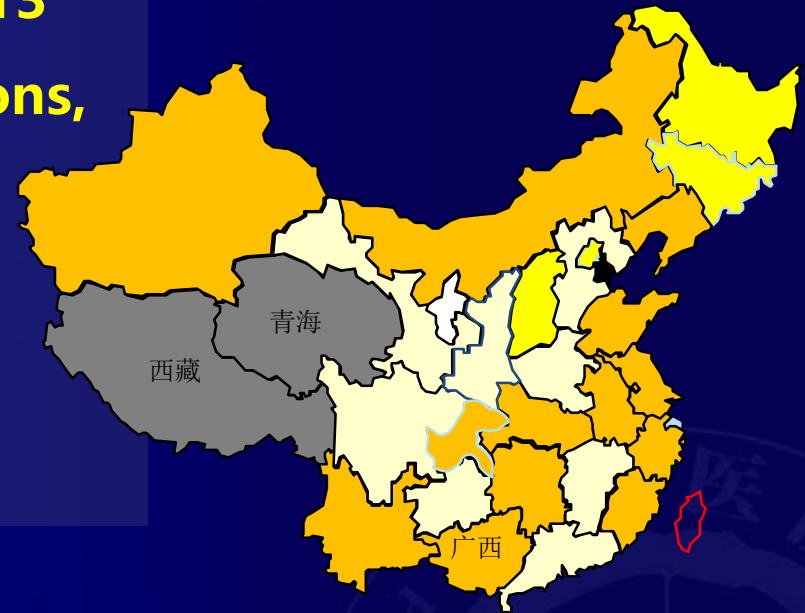
Approved by CSFDA on Sept, 2013

-27 provinces, autonomous regions,
and municipal cities.

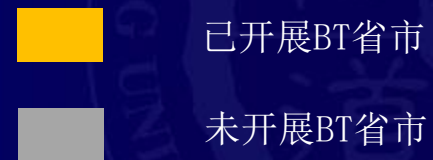95 hospitals

687 cases

1557 procedures



*截止2019年6月30日尚未开展BT手术的省份为：海南，青海，西藏



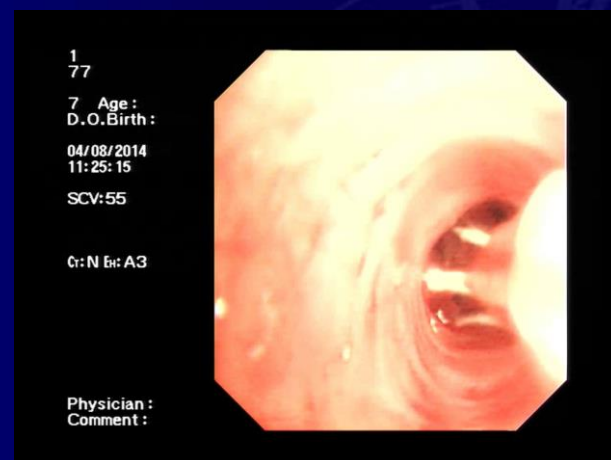
Courtesy of Dr. Lin Jiangtao



北京大学第一医院
PEKING UNIVERSITY FIRST HOSPITAL

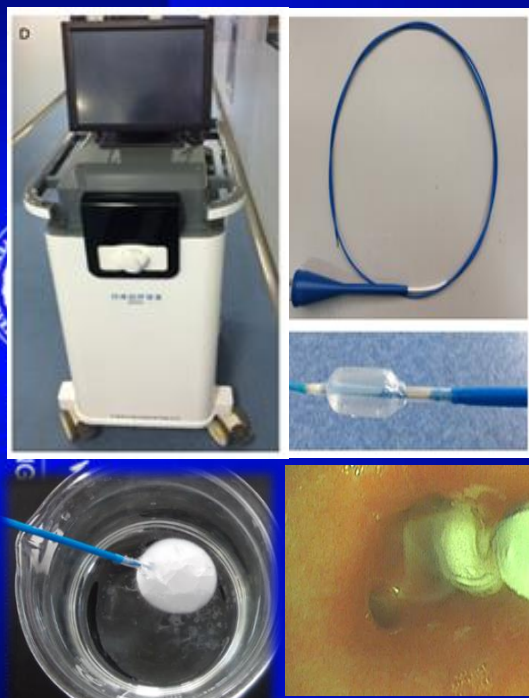
Bronchial Thermoplasty

- From the concept of precision medicine:
 - Who would benefit from the therapy?
 - The details of techniques should be modified?
 - Mild asthma?
 - Life persistent effect?
 - Mechanism?

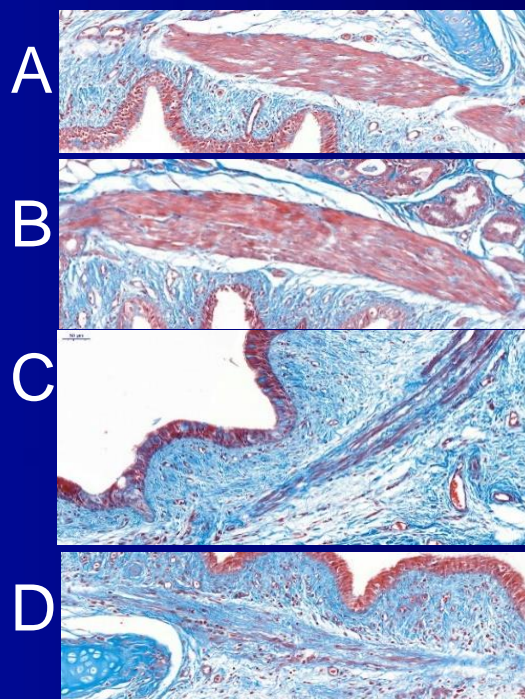


冷成形治疗可以治疗支气管哮喘？

Cryo-plasty

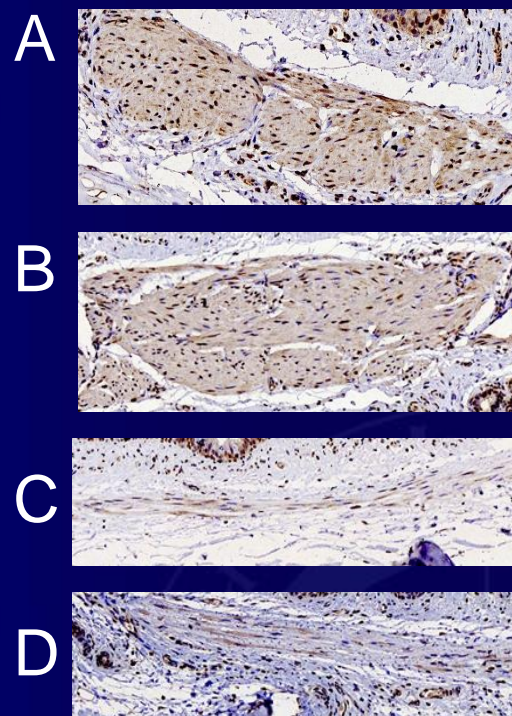


Masson
($\times 200$)



A: 对照组, B: BT术后1个月, C:
: 冷冻7秒治疗后1个月组,
D: 冷冻30秒治疗后1个月组

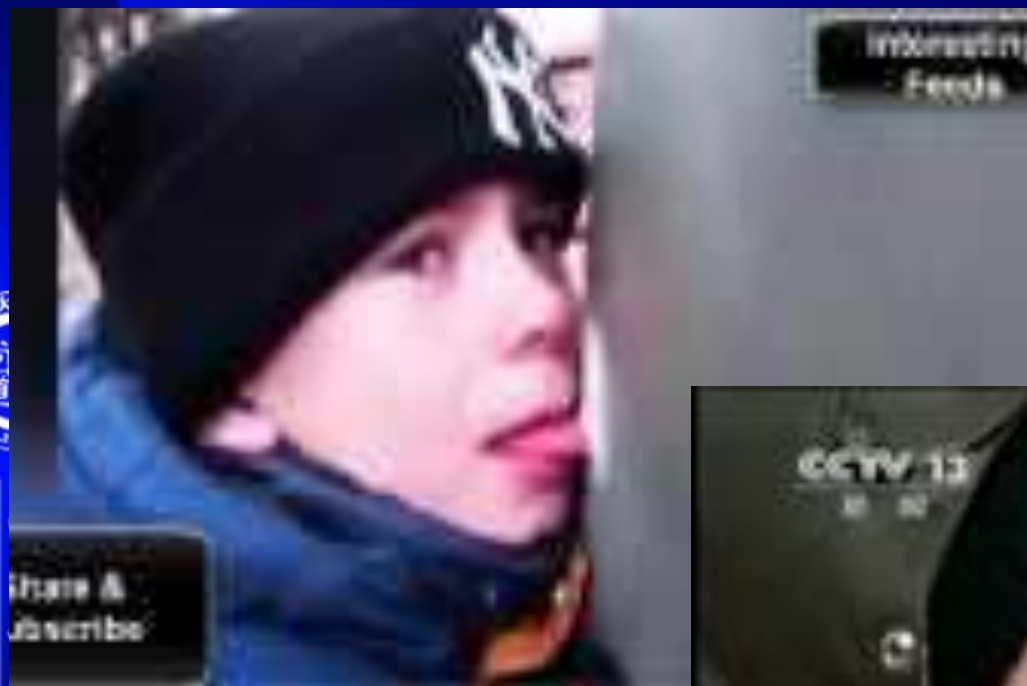免疫组化M3受体
($\times 200$)



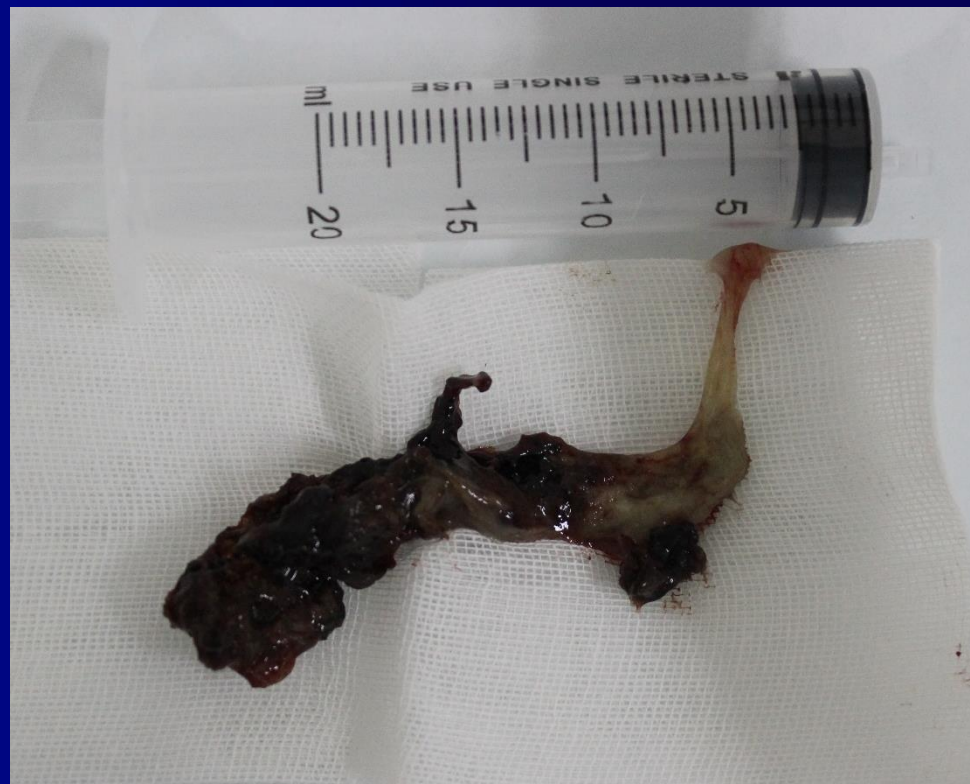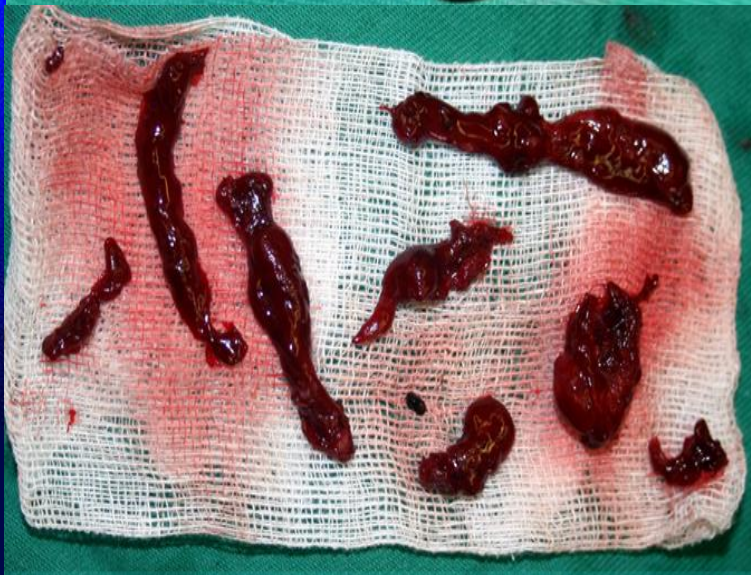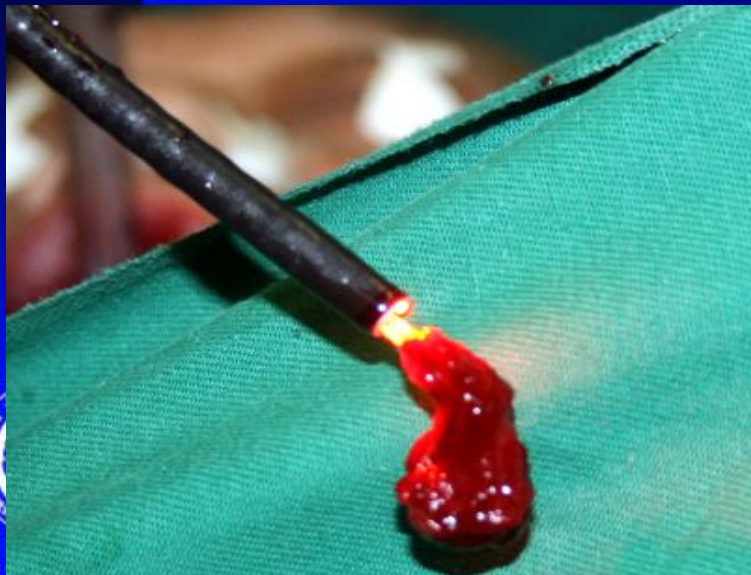
A: 对照组, B: BT术后1个月
C: 冷冻7秒治疗后1个月组,
D: 冷冻30秒治疗后1个月组

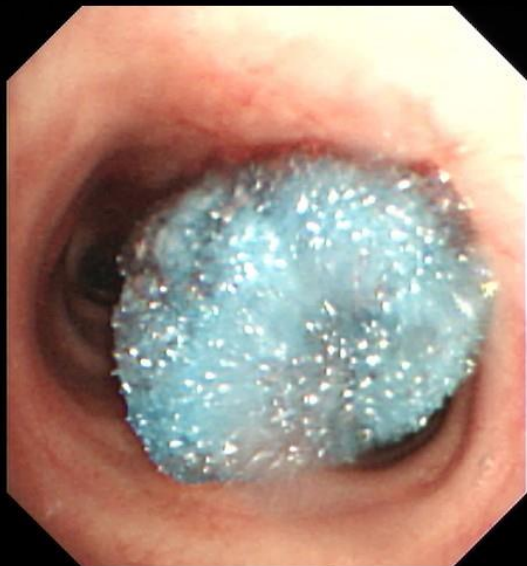
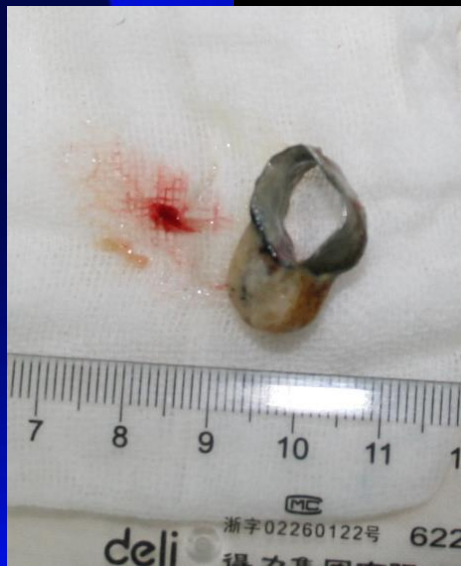王昌惠团队

介入呼吸病学领域内的转化—冷冻机械粘附效应

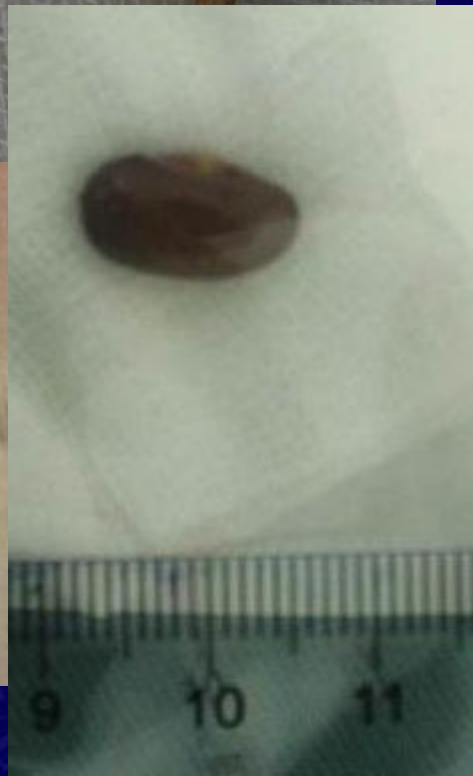
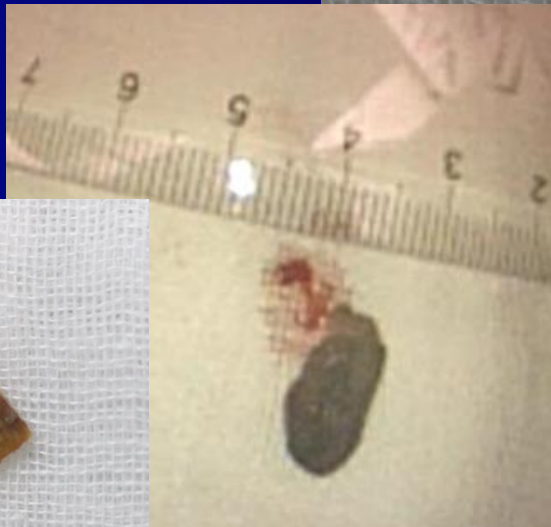
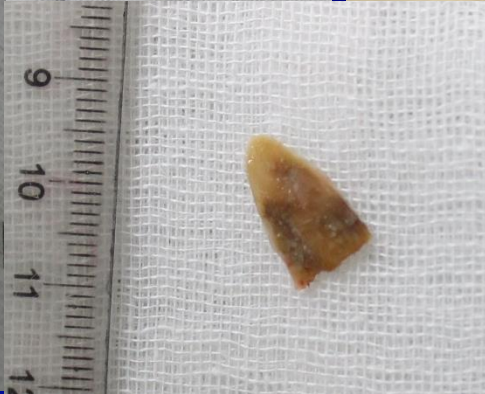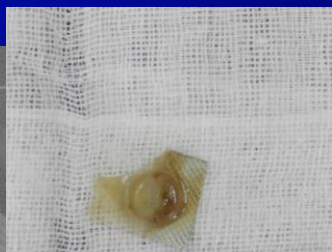冻切及冷冻提取





07



Transbronchial Cryobiopsy: A New Tool For Lung Biopsies

- 41例弥漫性肺疾病患者
- 可弯曲支气管镜，先活检钳活检再冷冻活检
- 活检钳标本平均面积5.82 mm² (0.58-20.88)
- 冷冻探头标本平均面积15.11 mm² (2.15-54.15)
($p < 0.01$)
- 2例气胸需插管引流
- 无需要处理的活检相关出血

Respiration. 2009;78(2):203-8.



北京大學第一醫院的研究

- 共37例DPLD患者
 - 男性21例，女性16例，中位年齡60岁（29-81岁）
- 每例患者均行TBLB和TBCB
 - 顺序——随机
 - 平均行TBLB4次（1-6），TBCB3.8次（1-6）
- 标本大小：TBCB $7.1 \pm 2.7\text{mm}$ vs TBLB $2.2 \pm 1.1\text{mm}$ ($p=0.001$)
- 标本中肺泡和细支气管结构完整、比例正常者：
 - TBCB19例（51.4%） vs TBLB11例（29.7%）



冷冻肺活检病理诊断

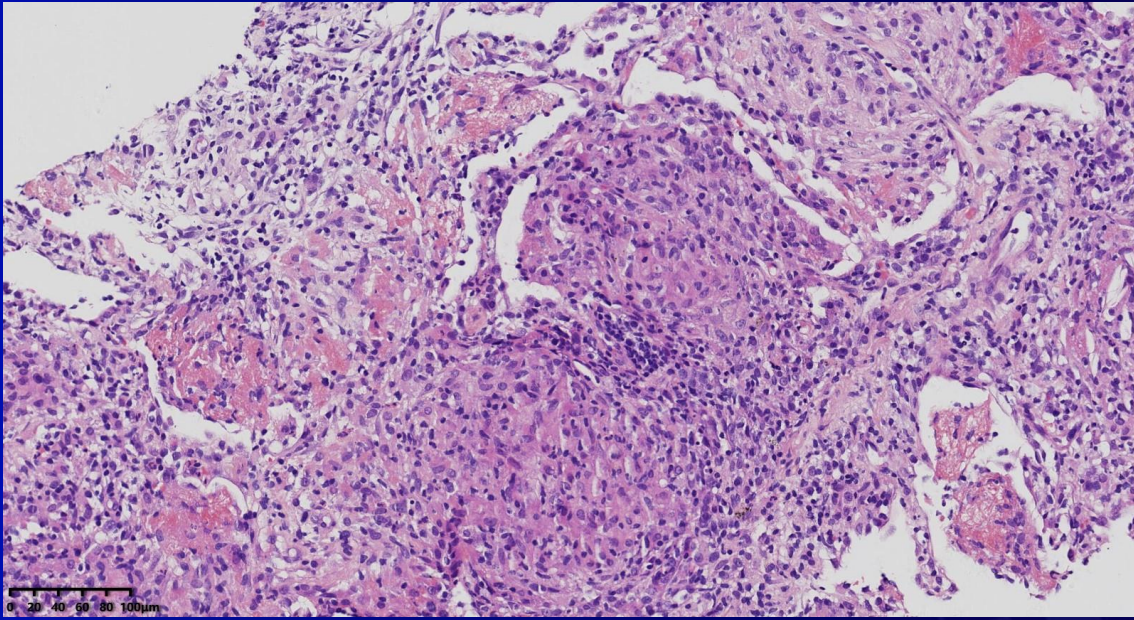
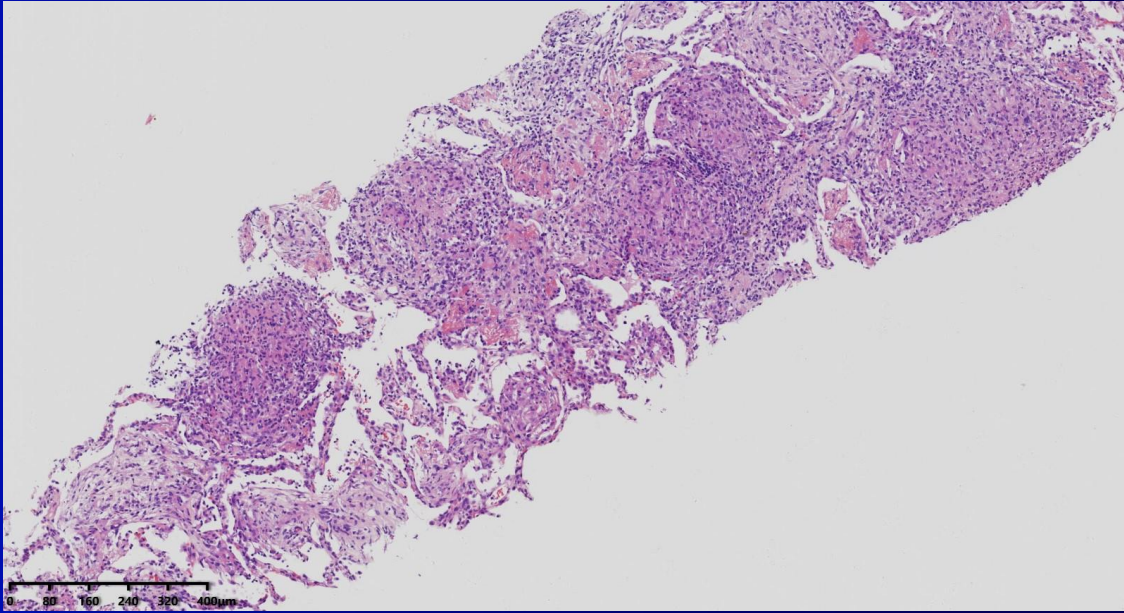
- 确定诊断：
 - UIP样改变11例
 - NSIP样改变3例
 - OP4例
 - LIP1例
 - RB-ILD 2例
 - 结节病2例
 - 肉芽肿性血管炎2例
- 确定诊断：
 - 肺泡蛋白沉着症
 - 过敏性肺炎
 - 弥漫性肺泡损伤
 - 肺泡出血
 - 结核伴纤维素性机化性肺炎及滤泡性细支气管炎
- 非特异性改变：
 - 慢支4例
 - 哮喘1例
 - 正常1例



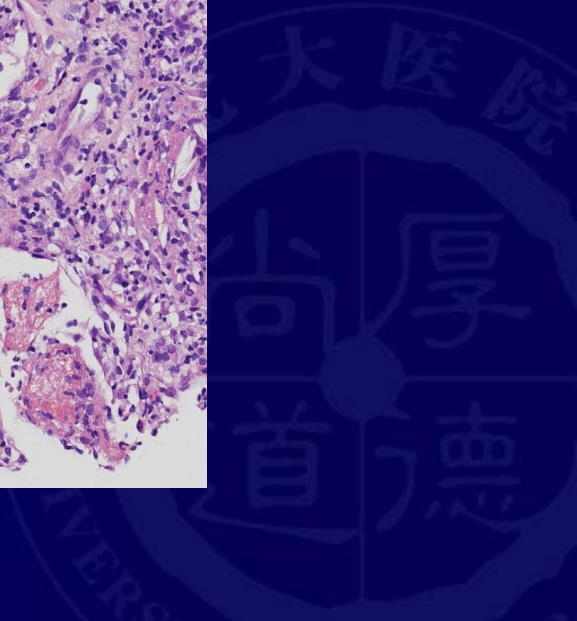
并发症

- 大于20ml的出血4例
 - 局部注入冰盐水和/或凝血酶500U后均止血
- 气胸3例
 - 1例胸腔置管引流1天后拔管
- 心律失常：
 - 中见频发室早1例
 - 术后一过性窦性心动过缓1例
 - 均未予处理自行缓解术
- 未见其他并发症





北京大学第一医院
PEKING UNIVERSITY FIRST HOSPITAL



总结

- 介入呼吸病学方兴未艾
- 是现代呼吸病病学的基础和重要组成部分
- 肿瘤早期诊治、呼吸慢病精准治疗、多种呼吸病的诊治
- 介入呼吸病学的未来发展：
 - 以精准医学为终极目标
 - 以转化医学为创新手段
 - 整合医学为临床实践
- 需要多学科协作实现自主创新
- 人工智能、干细胞、生物材料的发展将极大助推IP发展
- 规范、普及、提高仍是我国IP临床实践的主要任务



栉风沐雨 砥砺前行

New Land, New Scope

In collaboration with

21st WCBIP
SHANGHAI

International Convention Center
April 16-19, 2020

The graphic features a stylized city skyline of Shanghai in the background, including the Oriental Pearl Tower. In the foreground, the text '21st WCBIP SHANGHAI' is prominently displayed. Above the '21st' is the text 'In collaboration with' and two circular logos: one for 'WORLD MEDICAL ASSOCIATION' and another for 'CTS'. The entire graphic is set against a light blue and white background with pink cherry blossom accents.



谢谢