Tumor localization : Navigation Bronchoscopy Approach

黃才旺

三軍總醫院 胸腔外科

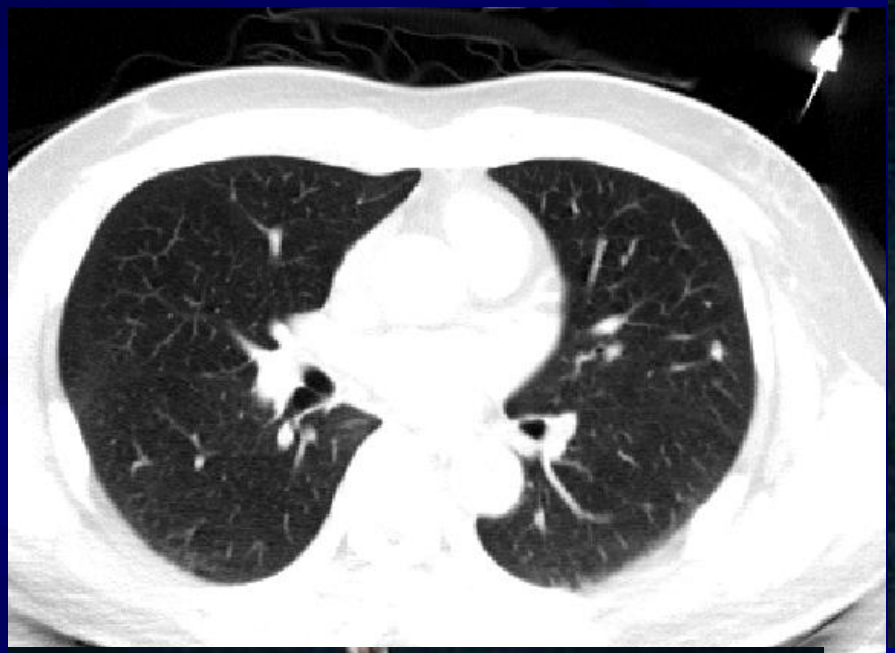

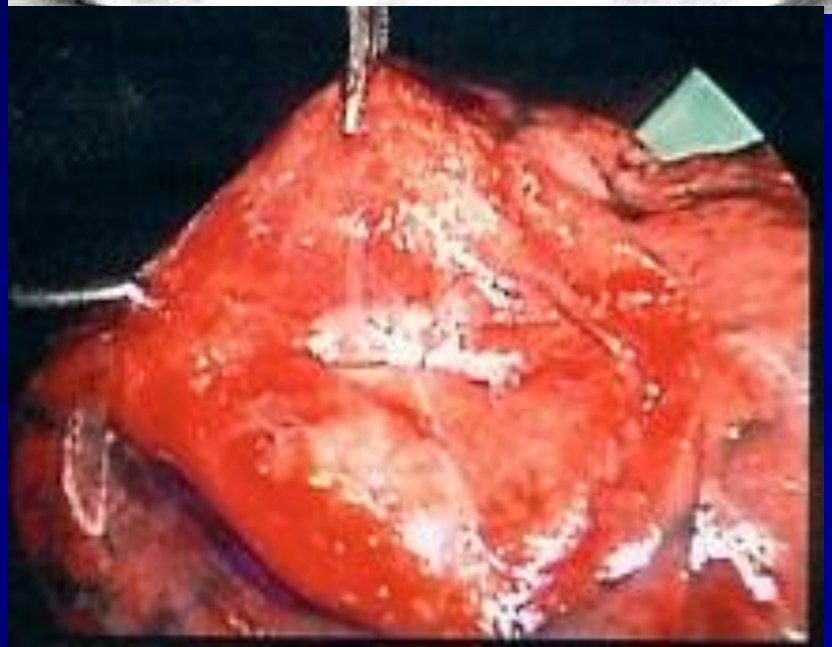

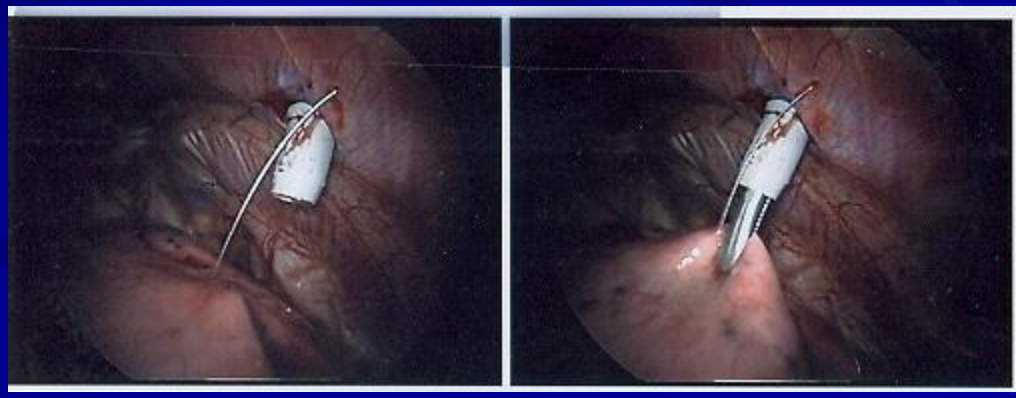

Hsu *et al. World Journal of Surgical Oncology* (2015) 13:248
DOI 10.1186/s12957-015-0664-9

WORLD JOURNAL OF SURGICAL ONCOLOGY

RESEARCH Open Access

Localization of nonpalpable pulmonary nodules using CT-guided needle puncture

Hsian-He Hsu[1], Chih-Hao Shen[2], Wen-Chuan Tsai[3], Kai-Hsiung Ko[1], Shih-Chun Lee[4], Hung Chang[4] and Tsai-Wang Huang[4,5*]

Abstract

Background: Surgical resection of small pulmonary nodule is challenging via thoracoscopic procedure. We describe our experience of computed tomography (CT)-guided needle puncture localization of indeterminate pulmonary nodules prior to video-assisted thoracoscopic surgery (VATS).

Methods: From January 2011 to July 2014, 78 consecutive patients underwent CT-guided marking for the localization of 91 small pulmonary nodules. We retrospectively reviewed the clinical data, technical details, surgical findings and pathologic results, and complications associated with CT-guided localization.

Results: Seventy-eight consecutive patients (36 men and 42 women) underwent CT-guided marking localization of 91 indeterminate pulmonary nodules (62 pure ground-glass opacity nodules, 27 part-solid nodules, and 2 solid nodules). The mean size of the nodules was 8.6 mm (3.0–23.0 mm). The mean pleural distance between the nodule and lung surface was 11.5 mm (3.0–31.3 mm). The mean procedure time of CT-guided localization was 15.2 min (8–42 min). All patients stood the procedures well without requiring conversion to open thoracotomy. Twenty-four patients (30.77 %) developed pneumothorax after the procedures. Only one patient required retention of the puncture needle introducer for air drainage. The mean visual assessment pain score was 1.7 (0–3). Fifty-seven nodules (62.63 %) were confirmed as malignances, including 45 primary lung cancer, and 34 nodules (37.37 %) were confirmed as benign lesions.

Conclusions: CT-guided needle puncture can be an effective and safe procedure prior to VATS, enabling accurate resection and diagnosis of small pulmonary nodules.

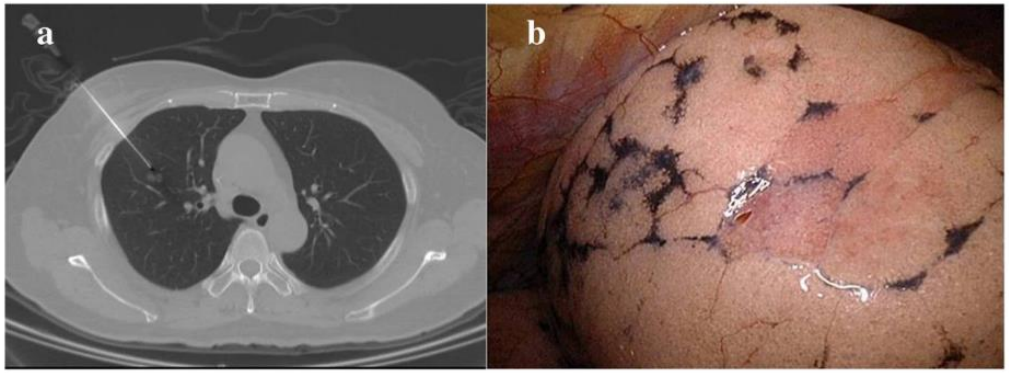

Fig. 1 a The puncture needle (Temno Coaxial Introducer Needle, Care Fusion, PP1910) was inserted under the CT-guided imaging. **b** Intraoperative identification of the puncture holes at lung surface after one lung ventilation

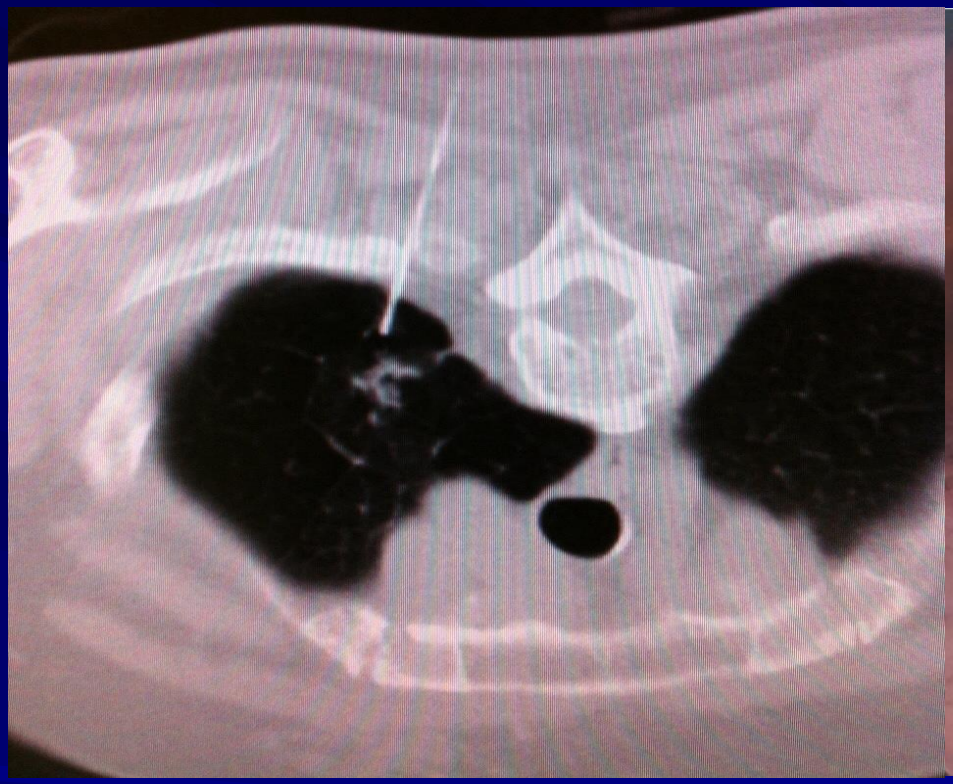

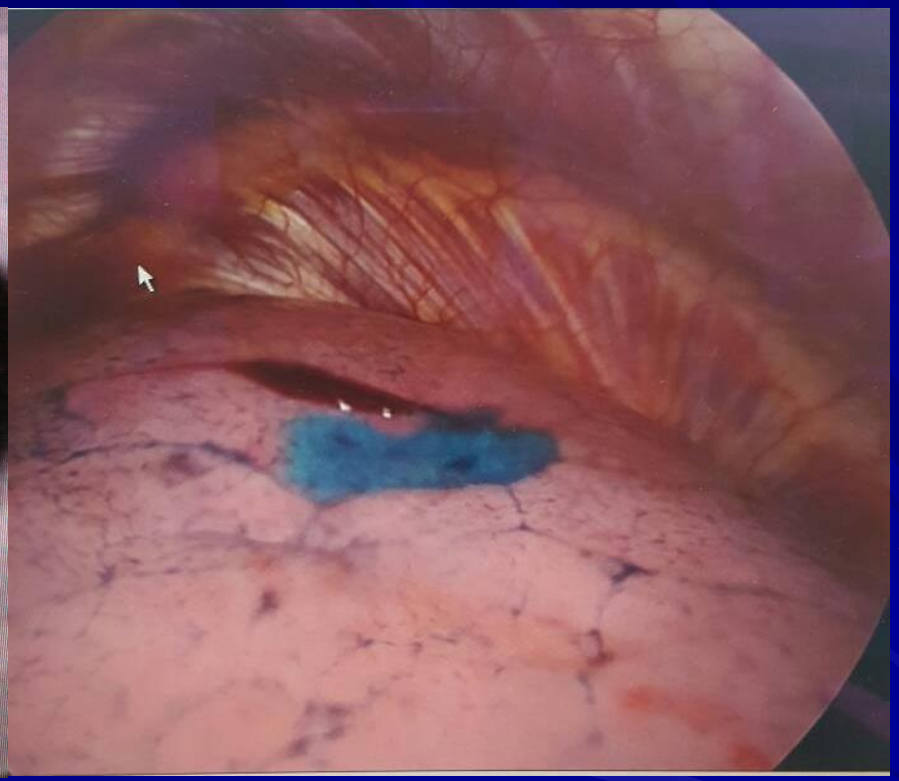

Contents lists available at ScienceDirect

Clinical Imaging

journal homepage: www.elsevier.com/locate/clinimag

Cardiothoracic Imaging

A simple and efficient method to perform preoperative pulmonary nodule localization: CT-guided patent blue dye injection

Kai-Hsiung Ko[a], Tsai-Wang Huang[b], Shih-Chun Lee[b], Wei-Chou Chang[a], Hong-Wei Gao[c], Hsian-He Hsu[a,*]

[a] Department of Radiology, Tri-Service General Hospital and National Defense Medical Center, Taipei, Taiwan, Republic of China
[b] Department of Thoracic Surgery, Tri-Service General Hospital and National Defense Medical Center, Taipei, Taiwan, Republic of China
[c] Department of Pathology, Tri-Service General Hospital and National Defense Medical Center, Taipei, Taiwan, Republic of China

ARTICLE INFO ABSTRACT

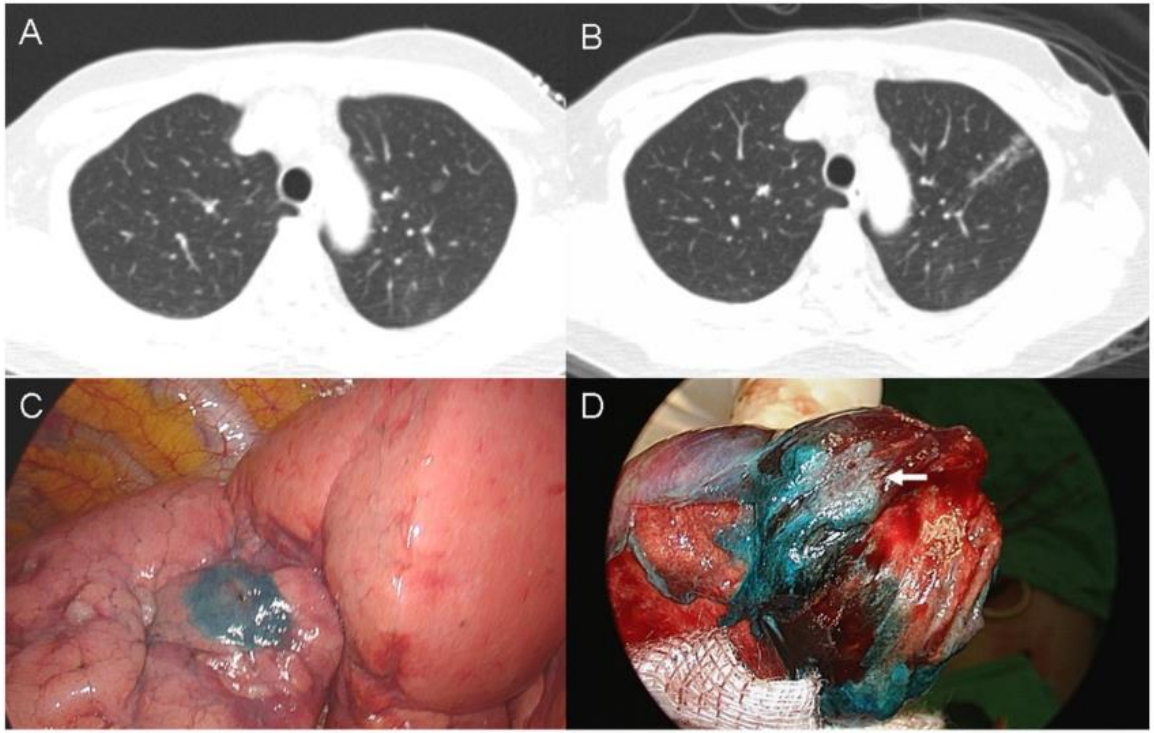

Air embolism complicating computed tomography-guided core needle biopsy of the lung

Yueh-Feng Wu[a], Tsai-Wang Huang[b], Chung-Cheng Kao[a] and Shih-Chun Lee[b,*]

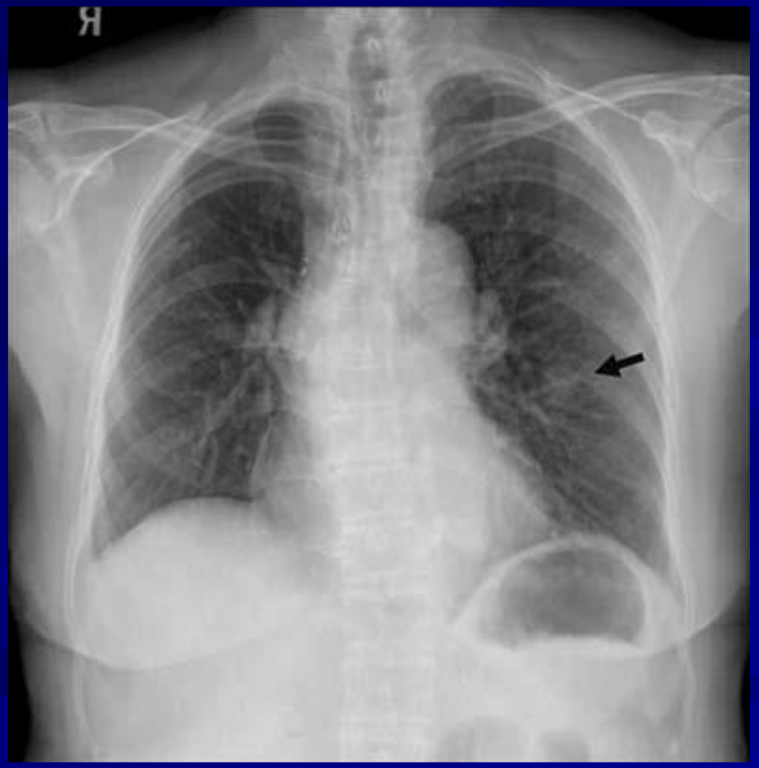

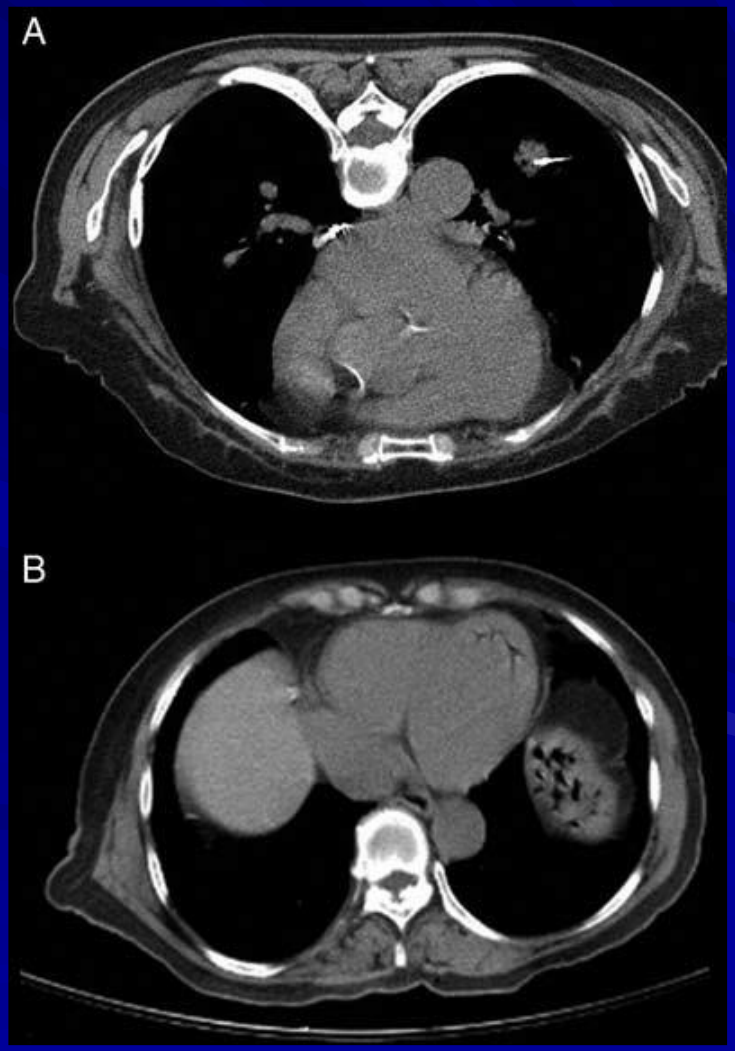

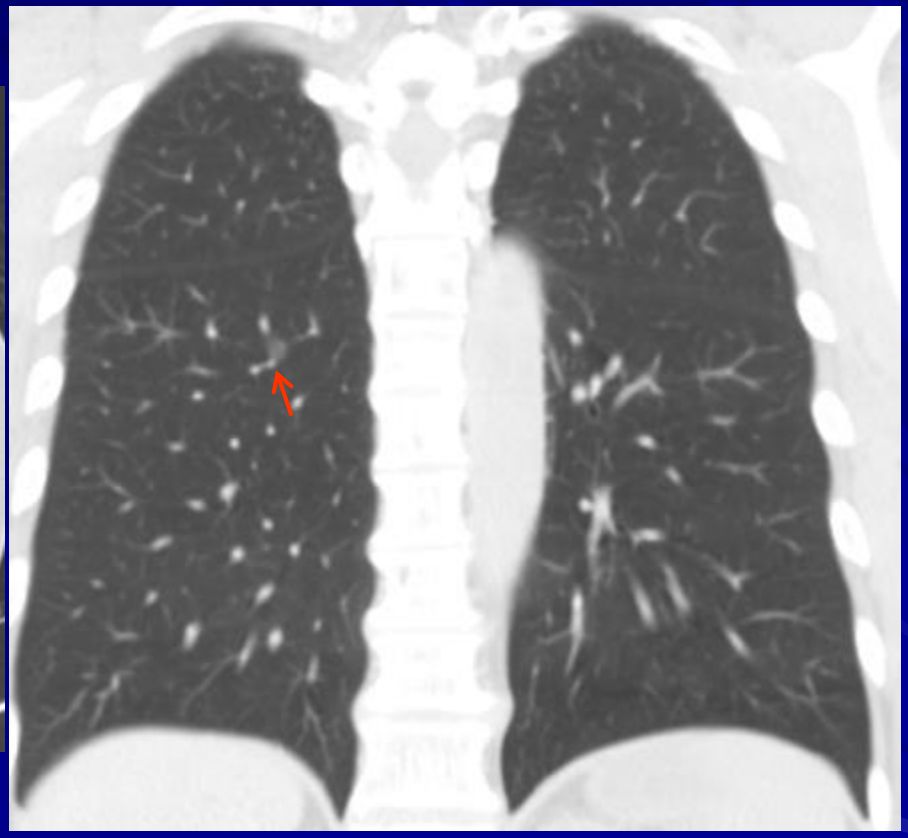

A focal ground-glass nodule (7 mm) in the superior segment of RLL lung with increase in size

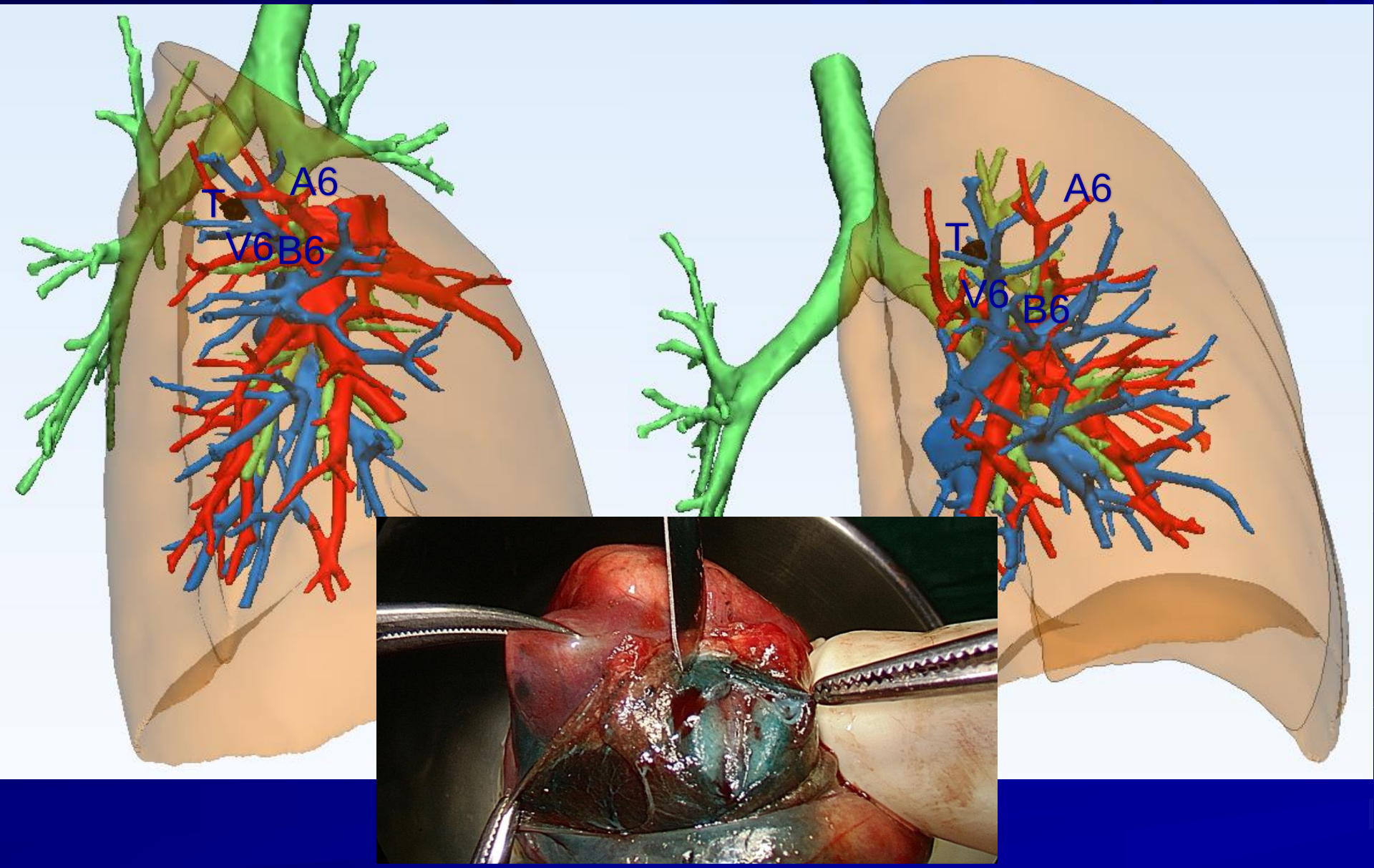
T
A6
V6
B6
A6
T
V6
B6

53/F

pure GGO of LS3, 0.8 cm

Size: 0.85 x 0.7 x 0.7 cm^3

Tumor Volume: 0.4 mL

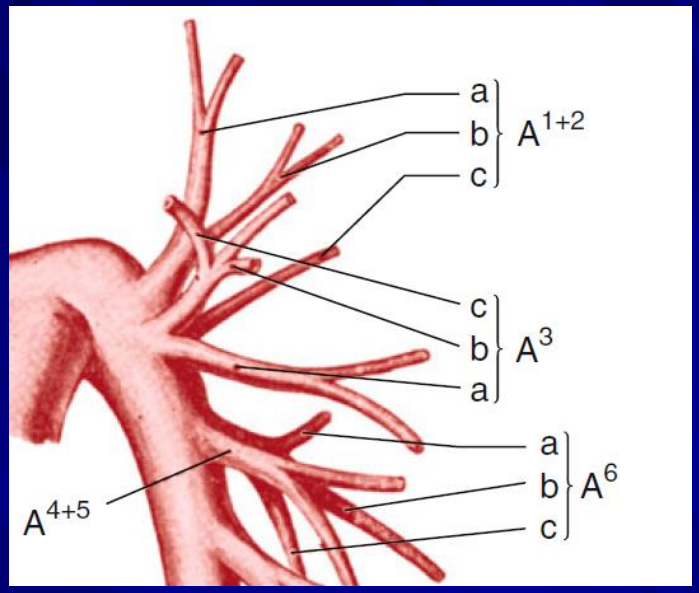

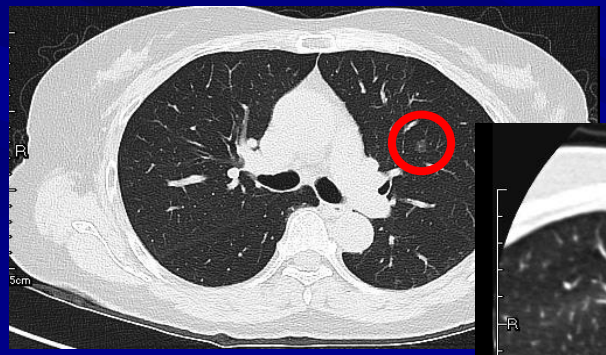

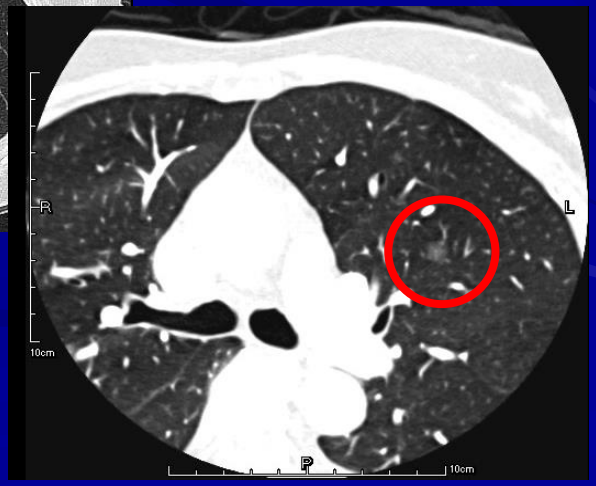

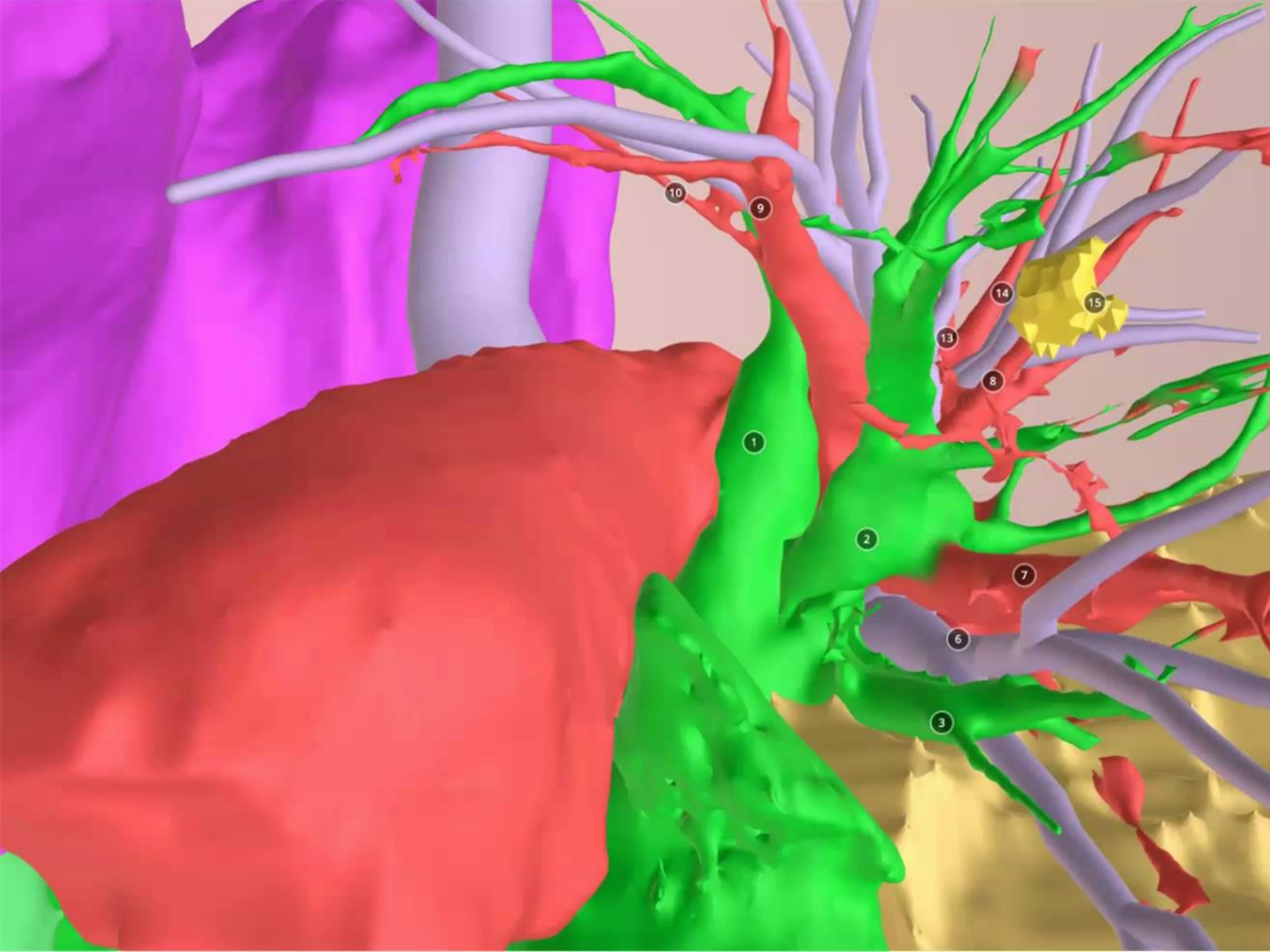
10
9
14
15
13
8
1
2
7
6
3

EBUS-TBNA

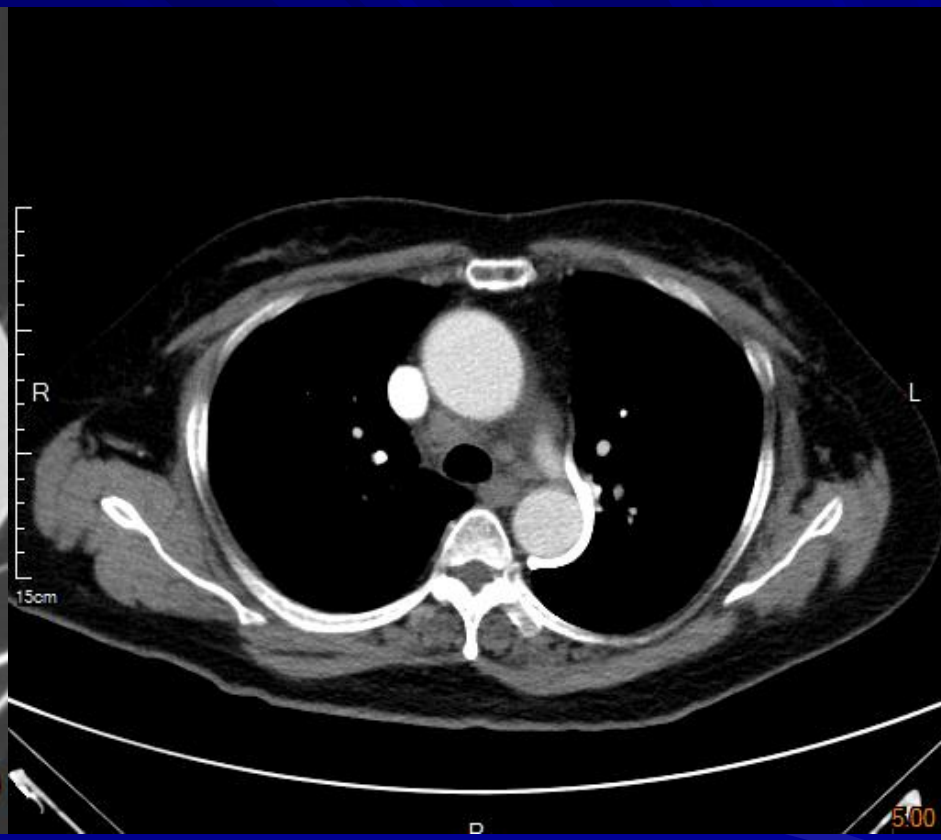

1Q11
09/10/2019
14:00:03
10MHz 4cm
G:15/19 I:N
C:5/8 FC:3
L.DEN:x2.0
TX:100%
OLYMPU

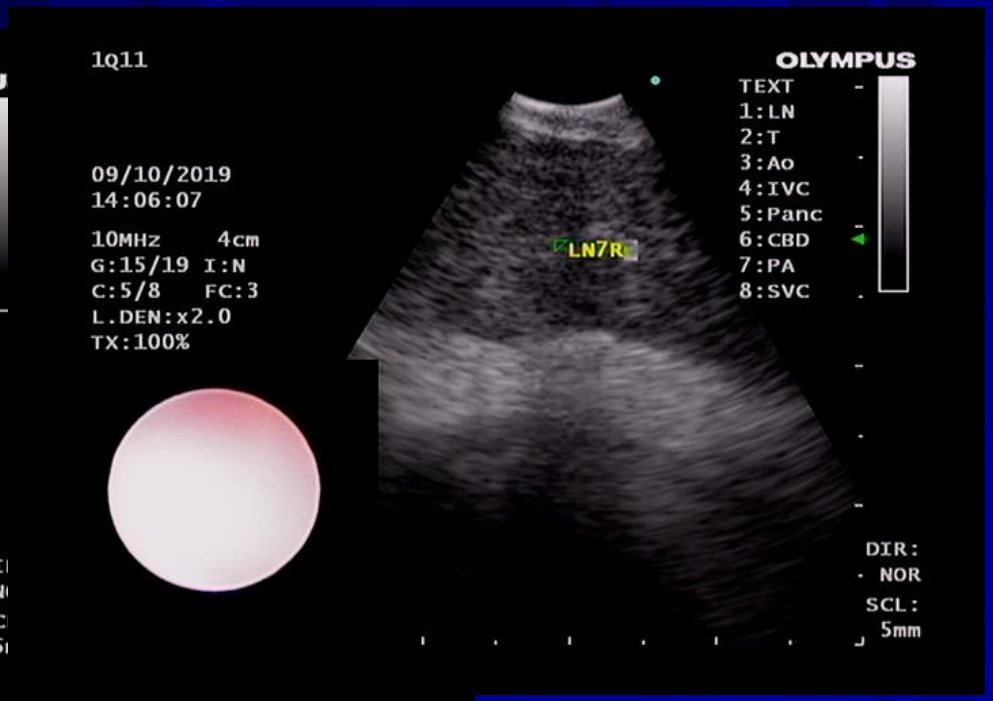
1Q11
09/10/2019
14:06:07
10MHz 4cm
G:15/19 I:N
C:5/8 FC:3
L.DEN:x2.0
TX:100%
OLYMPUS
TEXT
1:LN
2:T
3:Ao
4:IVC
5:Panc
6:CBD
7:PA
8:SVC
LN7R
DIR:
NOR
SCL:
5mm

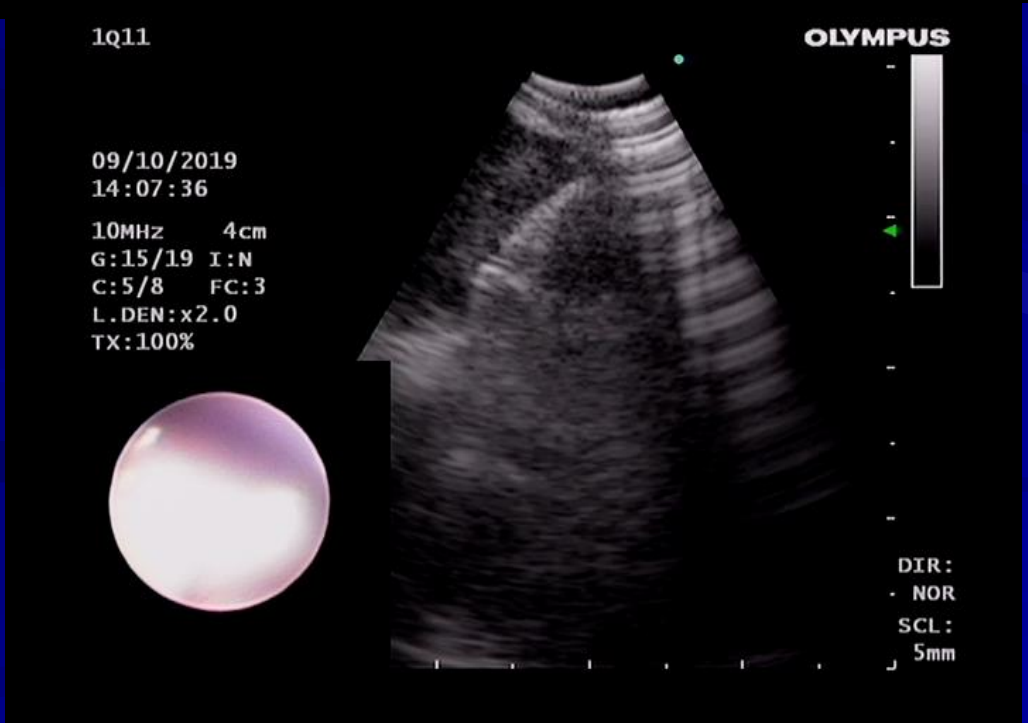
1Q11
09/10/2019
14:07:36
10MHz 4cm
G:15/19 I:N
C:5/8 FC:3
L.DEN:x2.0
TX:100%
OLYMPUS
DIR:
NOR
SCL:
5mm

09/18/2018
18:17:29
20MHz 4cm
G: 9/19 I:N
C:4/8
MEDIA
T/B:IMG ROT
CNCT:1 R
OLYMPUS
SONY
COVIDIEN
superDimension™ Navigation System
Options
Navigate to: Target_1 Pathway_1
Central Navigation
Peripheral Navigation
Target Alignment
3D Map Dynamic
Local
Bronchoscope
Mark Position
Sagittal CT
MIP
Axial CT
Coronal CT
Virtual Bronchoscopy
3D Map
Help: My Pathway does not end in the trachea
Discard Pathway and Start Over
Undo Auto Complete

- 72 Y/F , Smoker
- Biopsy : ?
- FEV1: 1.54 (90.9%)
  DLCO:11.10 (79.5%)
- PET-CT: T2N1M0, stage 2B

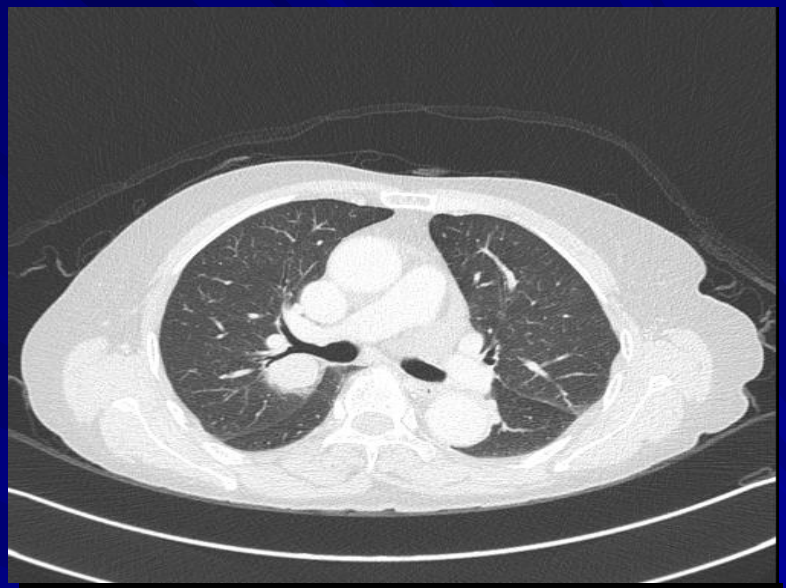

Confirm navigation accuracy by visualizing carinas
Main Carina Check
Main Carina Refinement
Main Carina Check
Back
Verify
Registration
SPIN Drive

- 64 Y/M
- CT scan GGO:1.6 cm
- Staging work up : M0

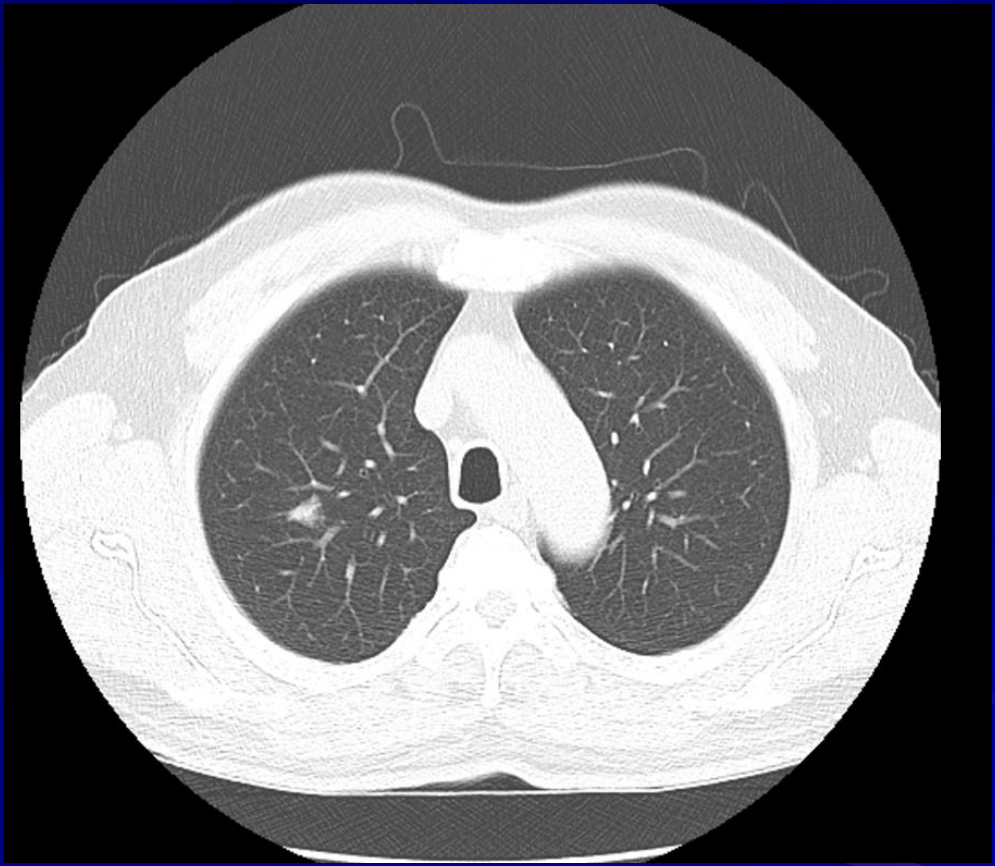

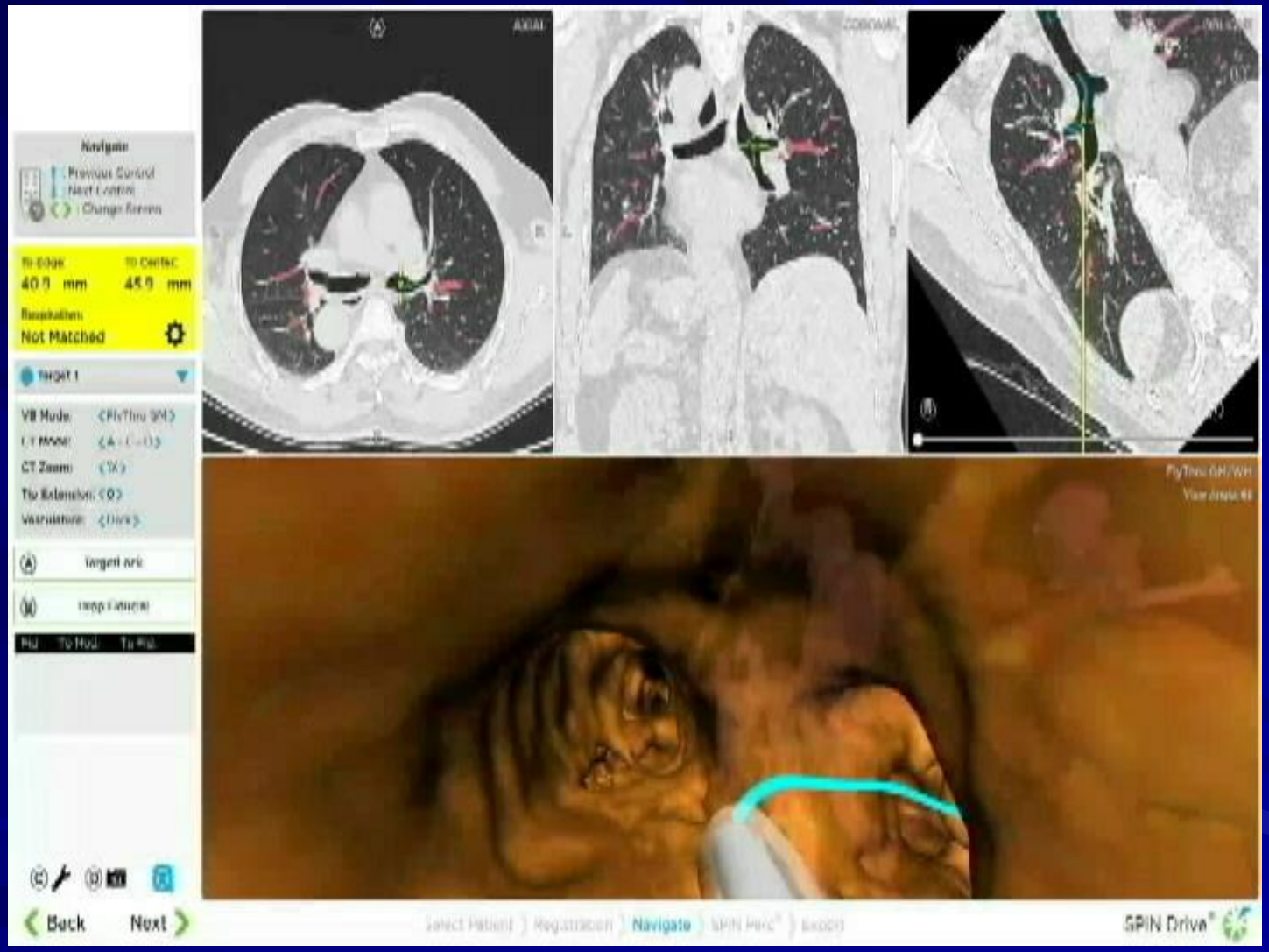
AXIAL
Navigate
Not Matched
Target 1
Back
Next
Navigate
SPIN Drive

NOVADAQ

NOVADAQ

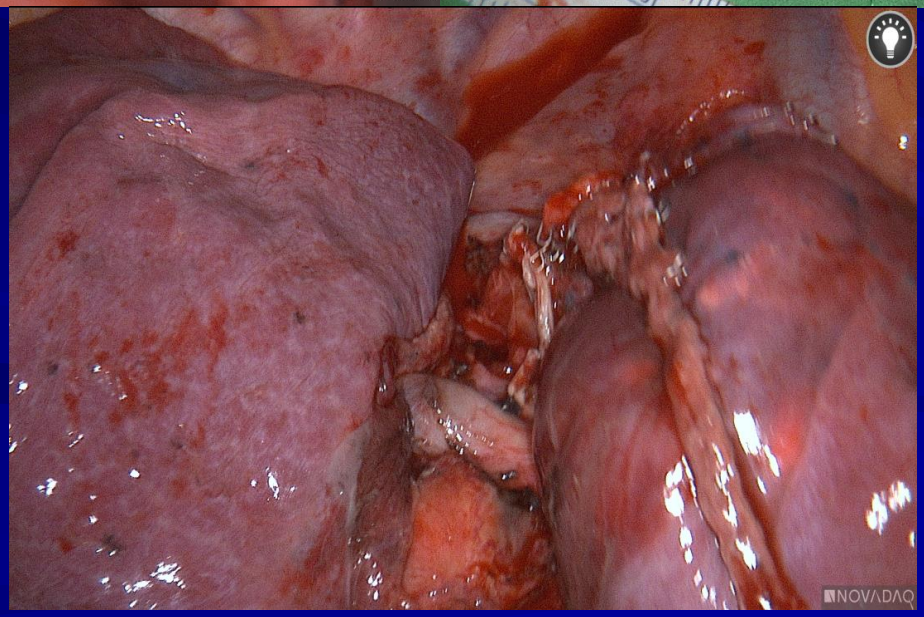
NOVADAQ

- 59 Y/M , Smoker
- Adeno Ca of colon
- LUL 1.6 cm SPN
- RLL GGO 1.0 cm

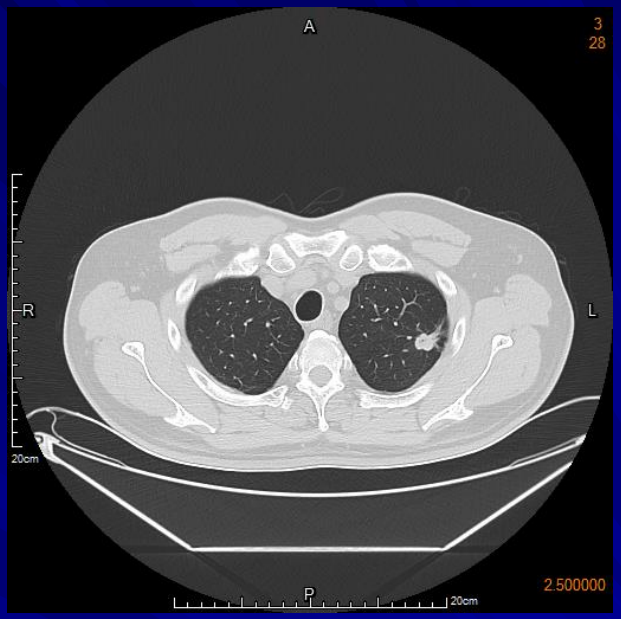

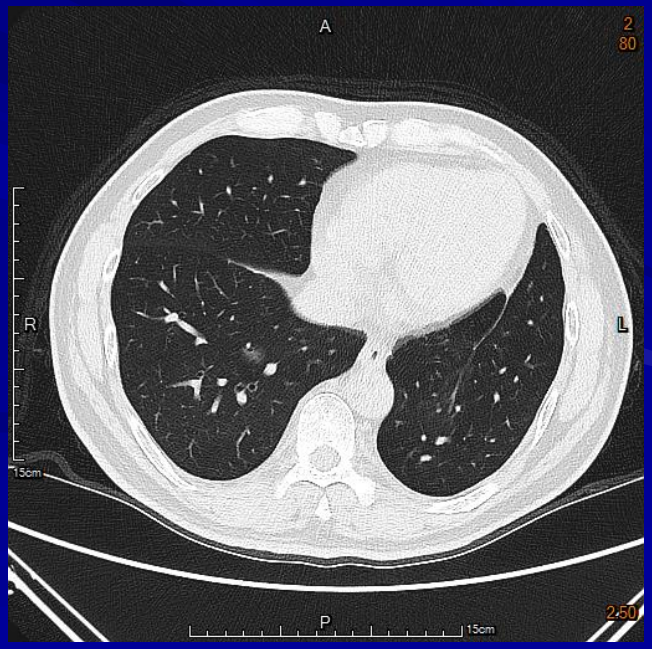

AXIAL
Navigate
To Edge
To Center
Registration
Not Matched
Target 1
VB Mode
CT Zoom
Tip Extension
Inspiration
Expiration
FlyThru GM/WM
Back
Next
Navigate
SPIN Drive

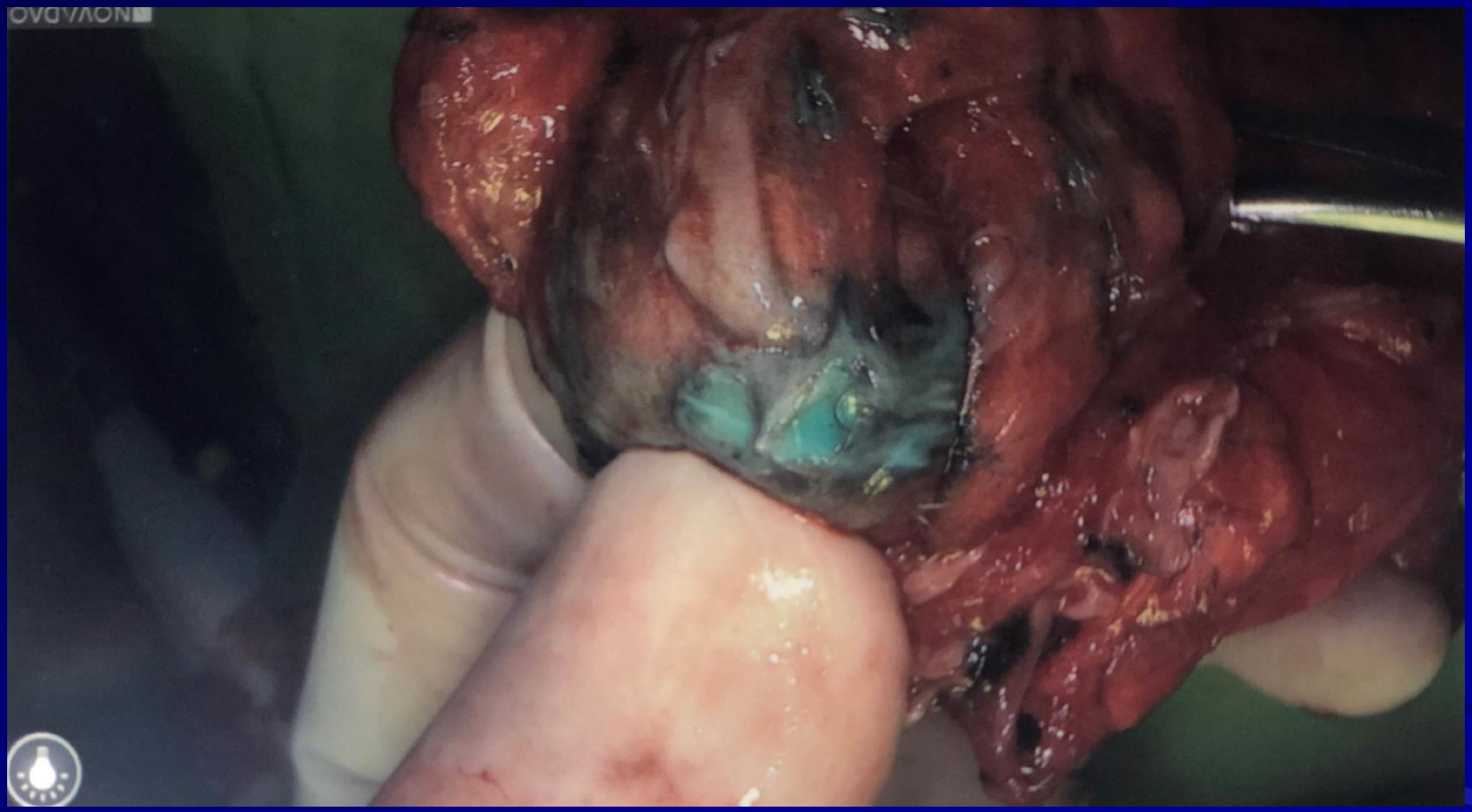

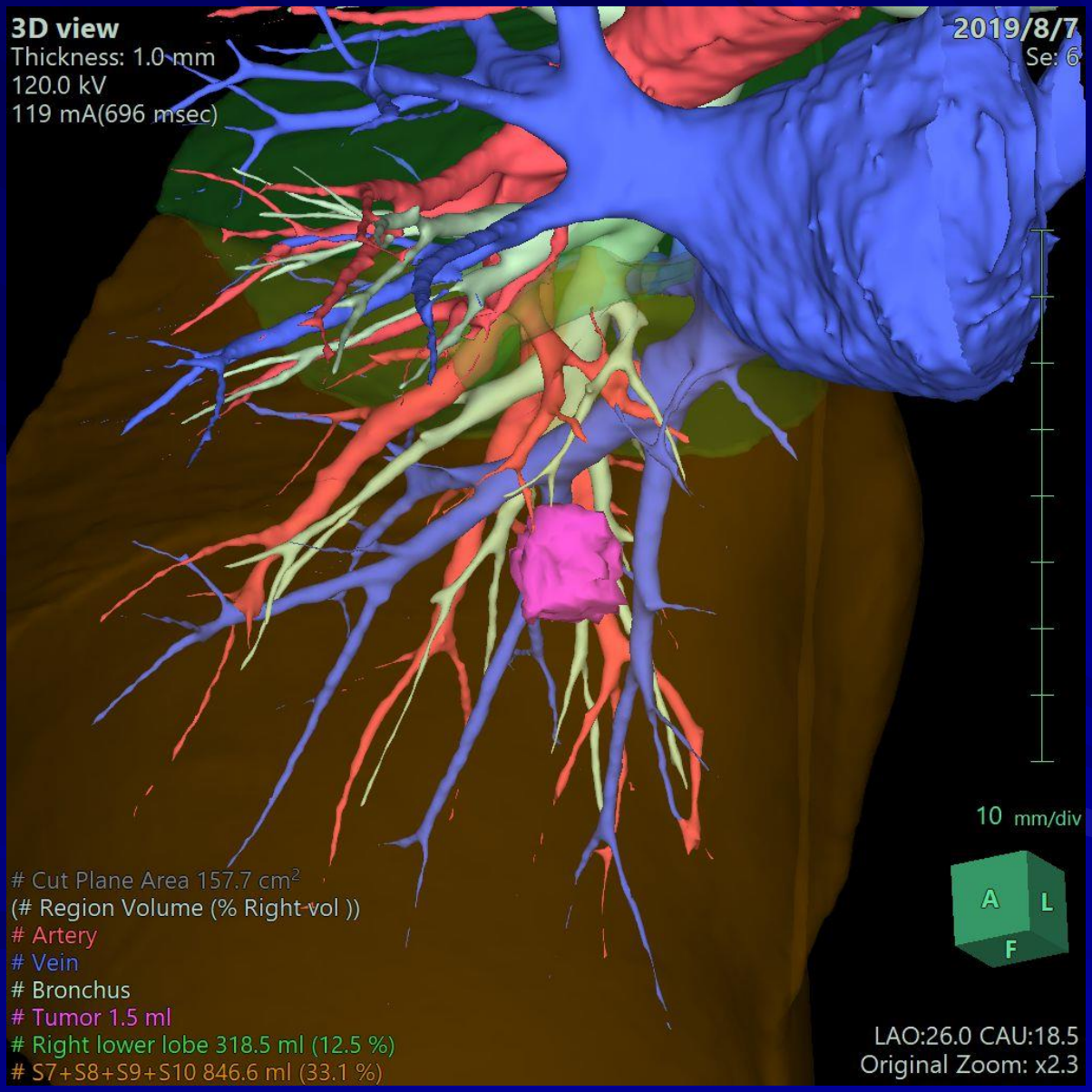
3D view
Thickness: 1.0 mm
120.0 kV
119 mA(696 msec)
2019/8/7
Se: 6
10 mm/div
A
L
F
Cut Plane Area 157.7 cm2
(# Region Volume (% Right vol))
Artery
Vein
Bronchus
Tumor 1.5 ml
Right lower lobe 318.5 ml (12.5 %)
S7+S8+S9+S10 846.6 ml (33.1 %)
LAO:26.0 CAU:18.5
Original Zoom: x2.3

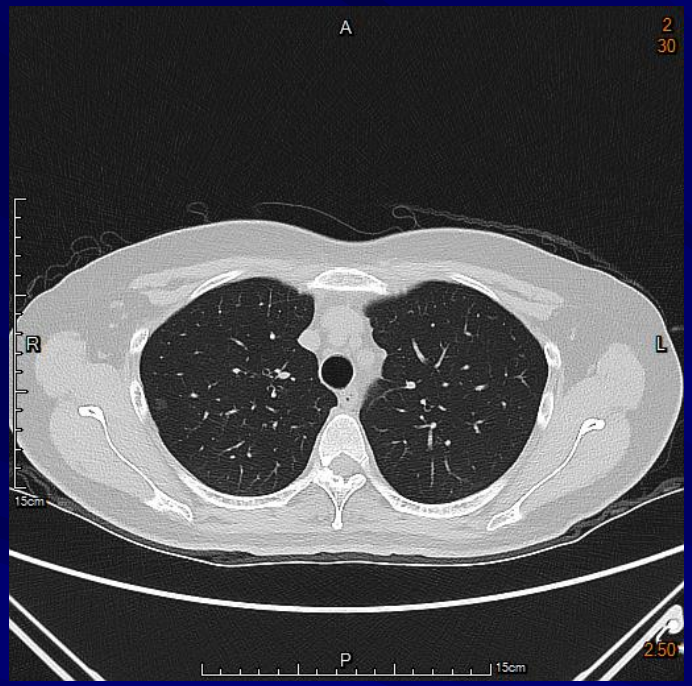
A
2
30
R
L
15cm
P
15cm
2.50

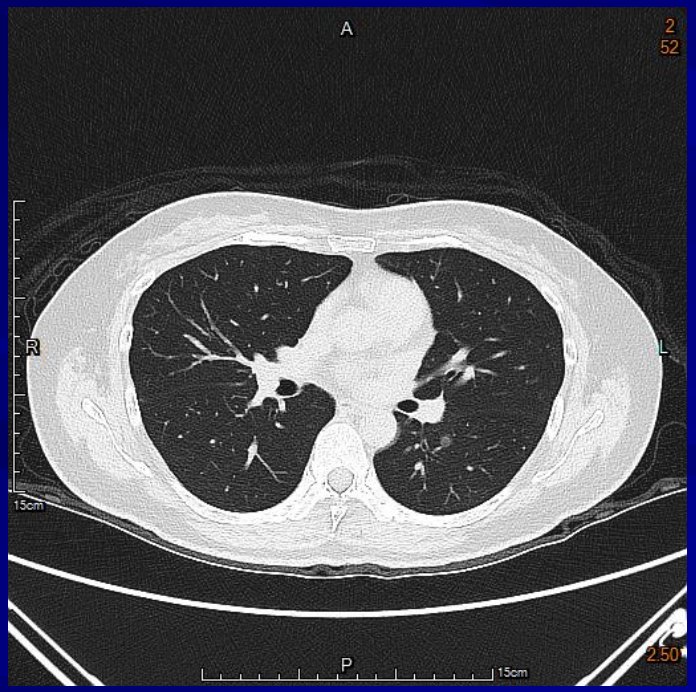
A
2
52
R
L
15cm
P
15cm
2.50

H
80464
28
R
L
15cm
F
15cm
5

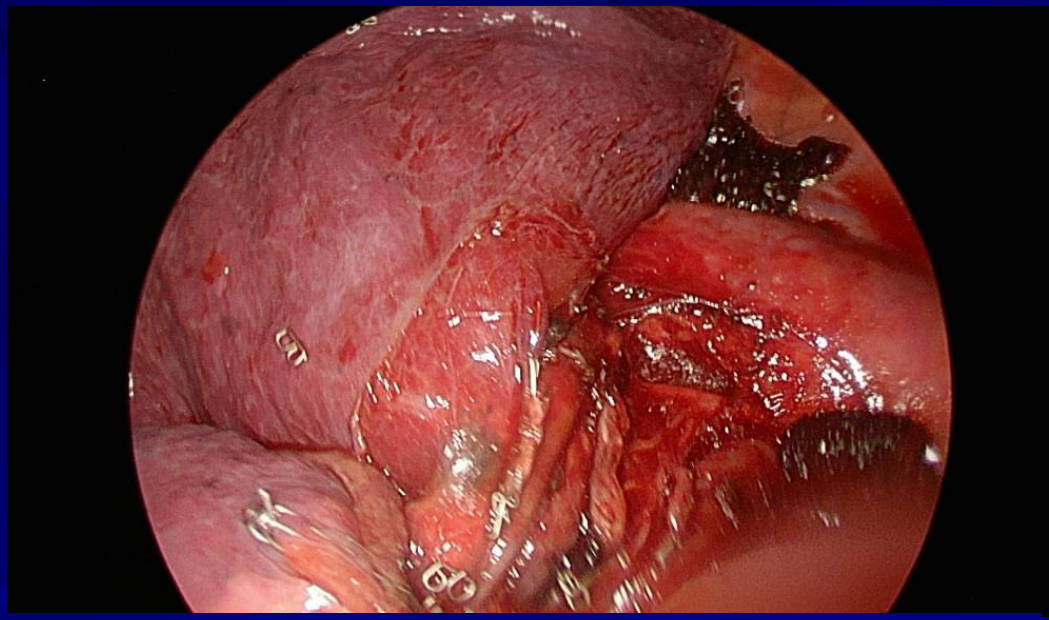

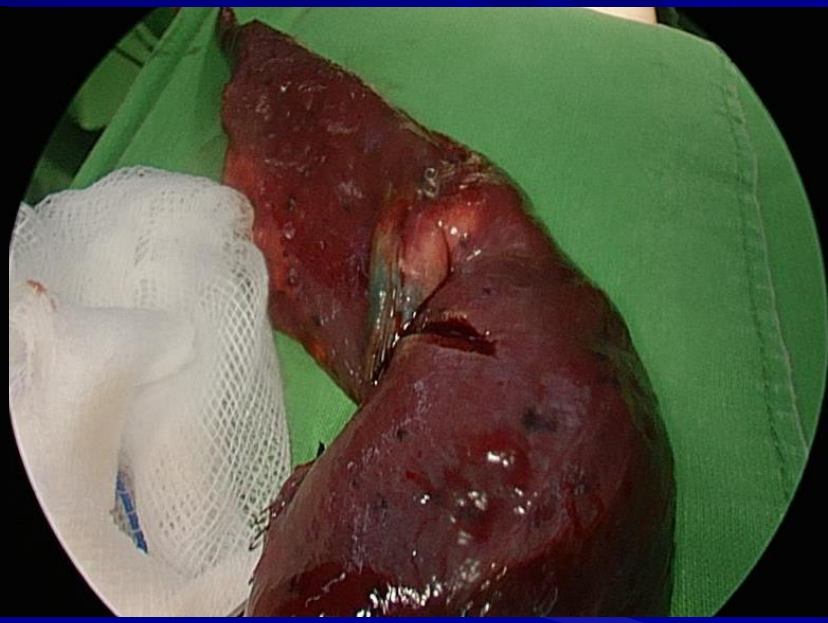

TSGH (2019.10-)

- Localization : 5 cases (RUL, RLL, LLL)
- Biopsy : 3 cases
- Procedure time : 10 minutes
- CT scan : OP date
- Dye injection : 0.5 cc

Thank you for your attention