



中國醫藥大學  
China Medical University



中國醫藥大學附設醫院  
China Medical University Hospital



2019年支氣管內視鏡超音波推廣及實體操作課程  
Taiwan Society of Pulmonary and Critical Care Medicine  
Hand-on Seminar of Endobronchial Ultrasonography

# EBUS-TBNA操作介紹

中國醫藥大學附設醫院 胸腔暨重症系 陳家弘

Chen, Chia-Hung, MD-PhD

Assistant Professor, China Medical University

Department of Pulmonary and Critical Care Medicine

China Medical University Hospital

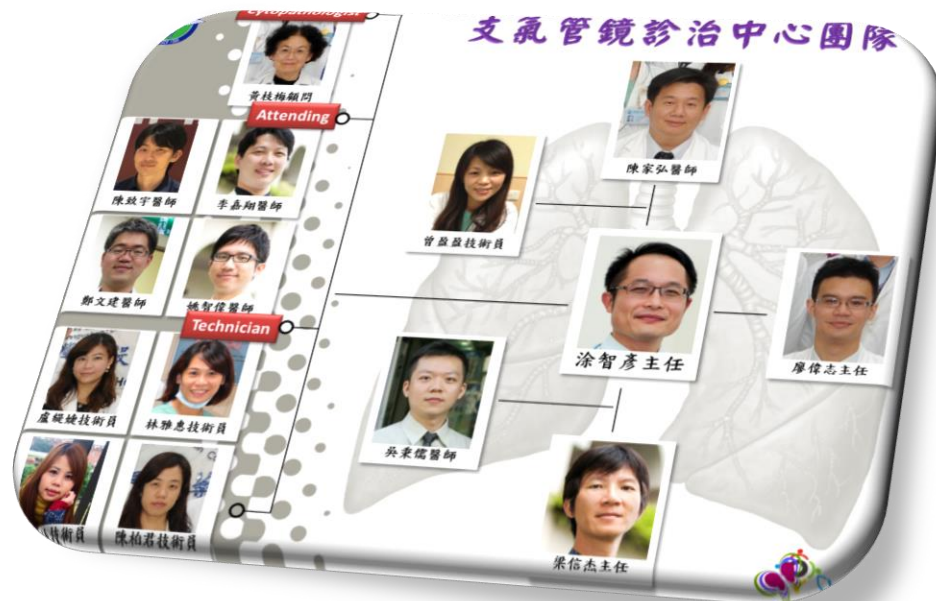


2019-05-26



## EBUS-TBNA操作介紹

# INTERVENTIONAL PULMONOLOGY CENTER



# 中國附醫支氣管鏡診治中心



## Cytopathologist



黃枝梅顧問

## Attending




沈宜成醫師



陳致宇醫師



李嘉翔醫師



曾盈盈技術員



陳家弘醫師



陳偉峻醫師




鄭文建醫師



陳韋成醫師



涂智彥主任



廖偉志主任

## Technician



洪如怜技術員



林雅惠技術員



吳秉儒醫師



曾湘純技術員



陳柏君技術員



梁信杰主任



# 支氣管鏡診治中心特色

全面且深入的發展介入性支氣管鏡的診治功能

## 診斷性氣管鏡

- 內視鏡超音波
- 支氣管內視鏡超音波導引細針穿刺抽吸術
- 自體螢光內視鏡

Pleuroscopy  
肋膜腔鏡



## 治療性支氣管鏡

- 電燒
- 氣管支架置放
- 氣管氣球擴張
- 氣管異物夾取
- 支氣管鏡輔助經皮擴張氣管切開術

Cryotherapy  
冷凍治療

2016

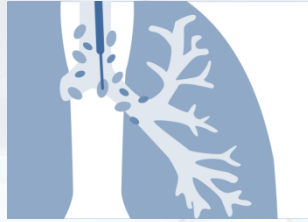
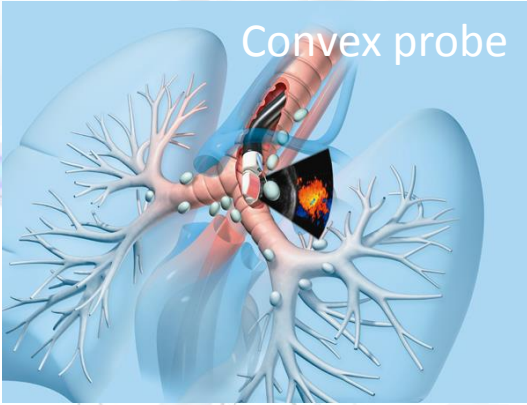
APC  
氬氣電漿凝固術



Radial probe



Convex probe



2007-12



中國醫藥大學附設醫院  
China Medical University Hospital

2008-  
UM-S20-17R radial  
balloon probe


2004-  
UM-S20-20R radial  
balloon probe

2002-  
Real-time of (TBNA)

1999-  
20 MHz radial balloon  
probe

1992-  
12 MHz radial probe

1988-  
7.5 MHz radial probe



Dr. Hürter TH



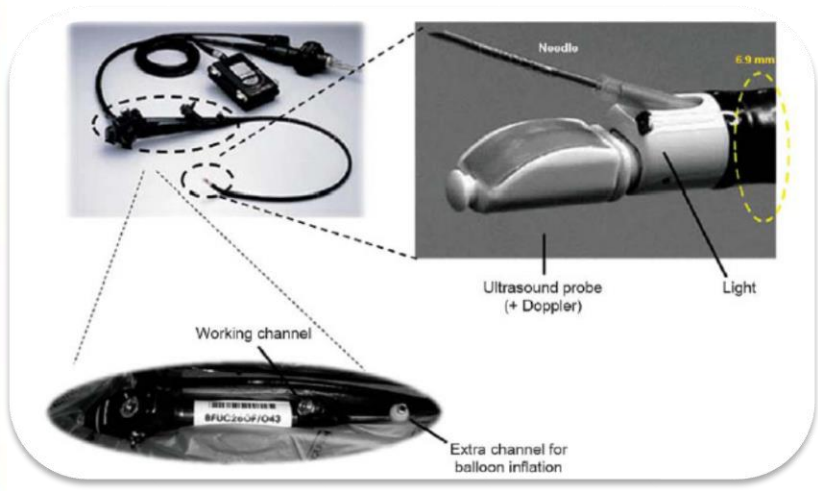
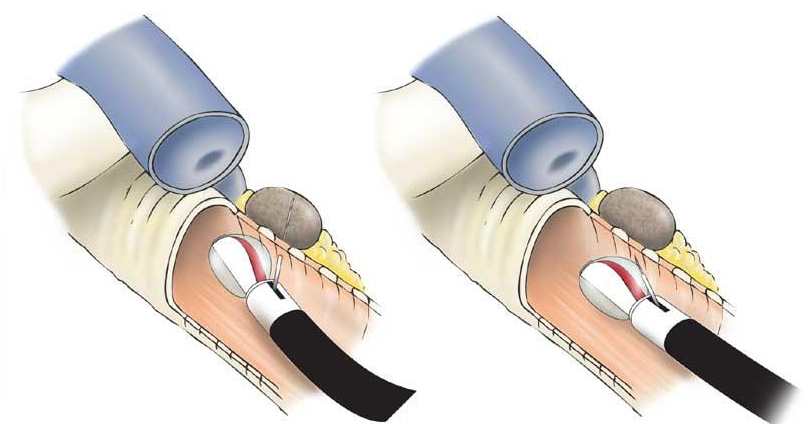
Dr. N. Kurimoto

## EBUS-TBNA操作介紹

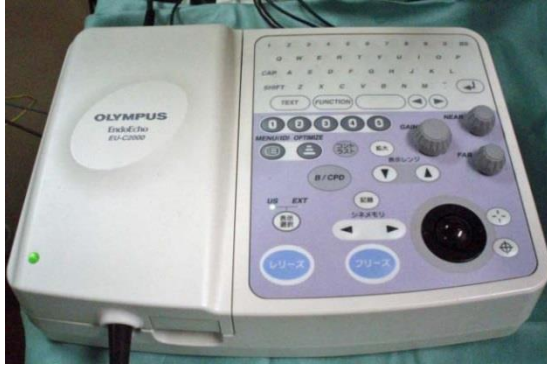
# EBUS SCOPE



# EBUS BF-UC180F



# Ultrasound processor



EU-C60  
2001

- 1<sup>st</sup> generation
- With color Doppler mode



EU-ME1  
2009

- With EBUS and EBUS-TBNA
- With Doppler, THI, power mode



EU-ME2  
2013

- With elastography
- Pulse Wave Doppler B mode



# EBUS - EB1970UK

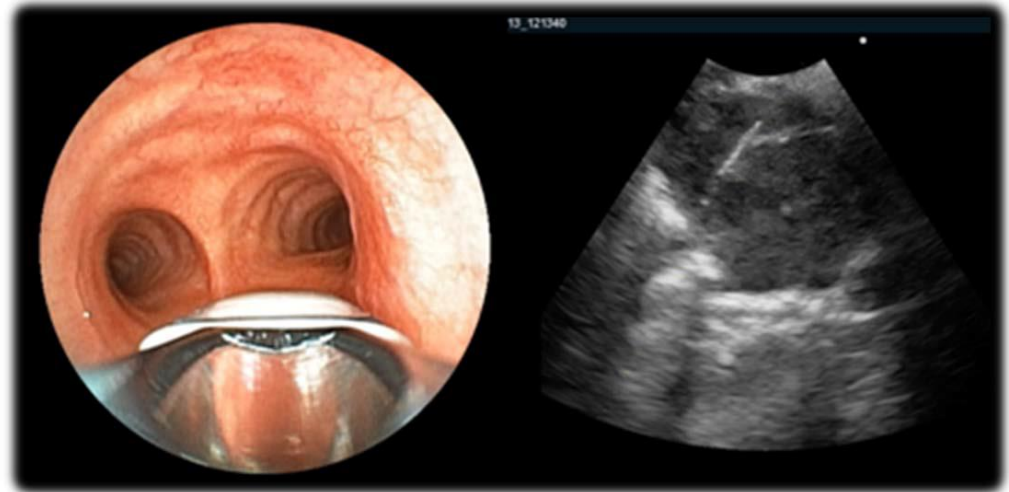
---

- 6.3mm Insertion Tube
- 2mm working channel
- Color CCD video images
  - 45° Forward Oblique
- Hitachi 5500 scanner
  - 75° Forward Oblique
- 5, 6.5, 7.5, 9, 10 MHz options



# EBUS scope – EB-530US

- 10° forward oblique view
- Wide Field of View: 120°



廠牌	OLYMPUS	PENTAX	FUJIFILM
視野	80°	100°	120°
視野方向	35° 向前斜視	45° 向前斜視	10° 向前斜視
先端部外徑	Φ 6.9 mm	Φ 7.4 mm	Φ 6.7 mm
插入部外徑	Φ 6.3 mm	Φ 6.2 mm	Φ 6.3 mm
有效長度	600 mm	600 mm	610 mm
管道內徑	Φ 2.2 mm	Φ 2.0 mm	Φ 2.0 mm
角度範圍	向上：120° 向下：90°	向上：120° 向下：90°	向上：130° 向下：90°
掃瞄頻率	5MHz, 6MHz, 7.5MHz, 10MHz, 12MHz	5MHz, 6.5 MHz, 7.5MHz, 9MHz, 10MHz, 12MHz	5MHz, 7.5MHz, 10MHz, 12MHz

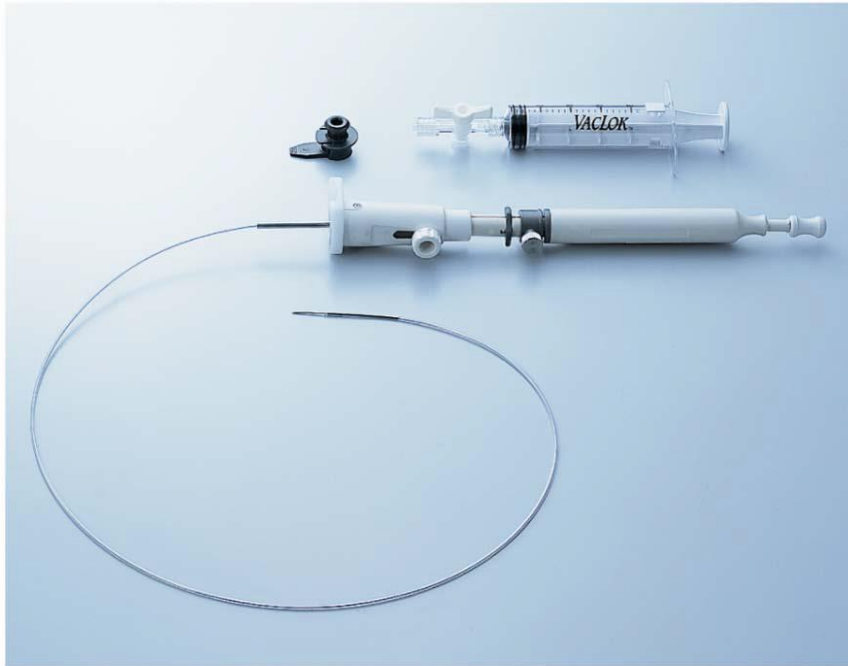
## EBUS-TBNA操作介紹

# EBUS-TBNA NEEDLE

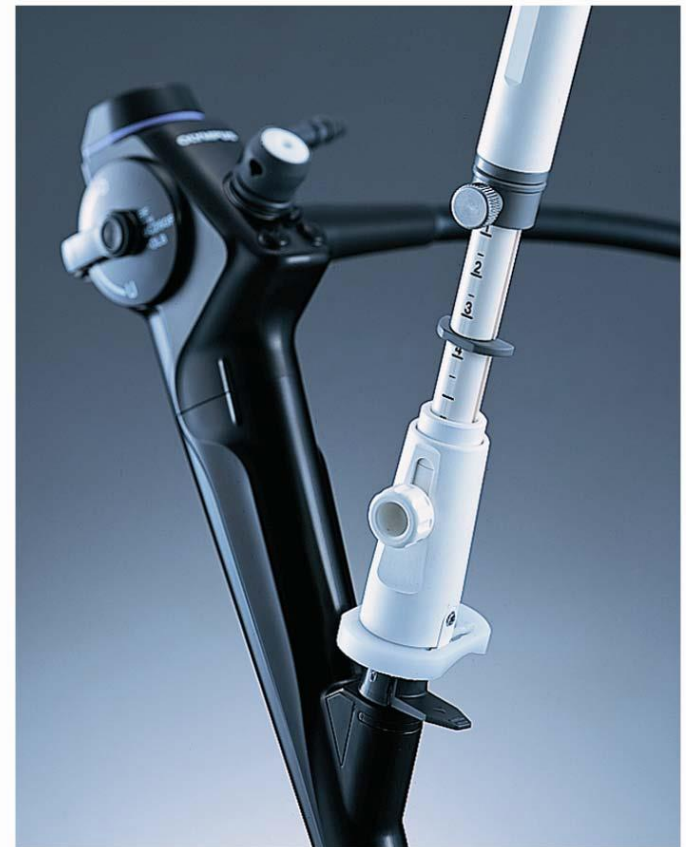



# NA-201SX-4022, 4021



**19G, 21G, 22G**



# SonoTip EBUS Pro Flex

## SonoTip® EBUS Pro

- Dimensionally Stable Nitinol Needle  
*Eliminates needle deformation ("Banana-Effect") after initial puncture for precise needle positioning in repeated passes*
- Twist-Lock Technology for Sheath & Needle Length Adjustment  
*Single hand operation*  
*Needle length adjustment (0 - 4 cm)*
- Blue Colored Plastic Sheath  
*Creates a high contrast image under endoscopic visualization providing clear identification of the outer sheath and the respiratory tract for precise needle guidance*
- Luer-locking Needle and Stylet  
*Provides exact needle and stylet tip positioning*

SonoTip® EBUS Pro Flex  
Endobronchial Ultrasound-Guided TBNA System – Single Use

 SonoTip®  
EBUS Pro

- Dimensionally Stable Nitinol Needle  
*Eliminates needle deformation ("Banana-Effect") after initial puncture for precise needle positioning in repeated passes*
- Twist-Lock Technology for Sheath & Needle Length Adjustment  
*Single hand operation*  
*Needle length adjustment (0 - 4 cm)*
- Blue Colored Plastic Sheath  
*Creates a high contrast image under endoscopic visualization providing clear identification of the outer sheath and the respiratory tract for precise needle guidance*
- Luer-locking Needle and Stylet  
*Provides exact needle and stylet tip positioning*

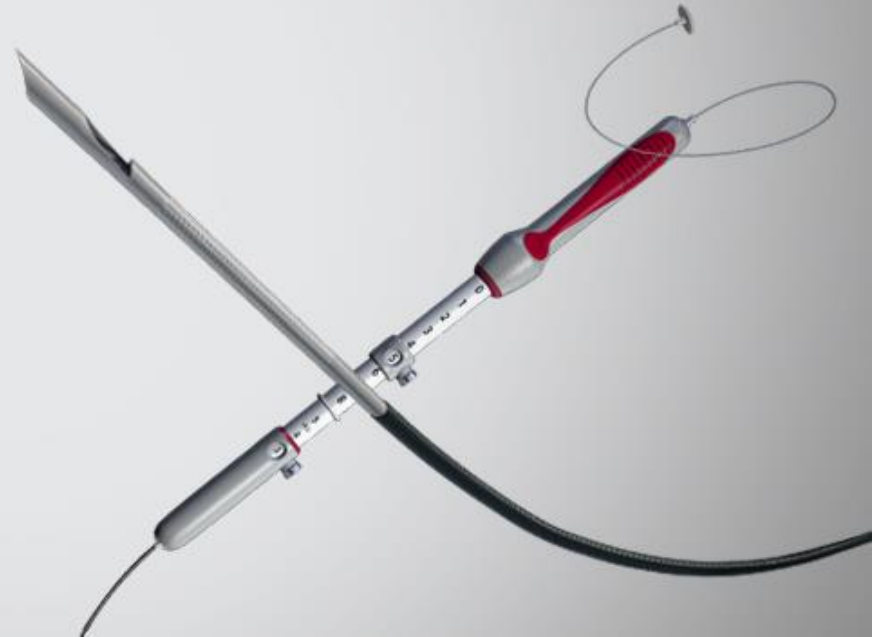


SonoTip® EBUS Pro Flex  
Eliminates Needle Deformation ("Banana-Effect")

 Medi-Globe®  
The Spirit of Care.™

# EchoTip ProCore EBUS Needles

- Core trap design to obtain tissue
- 22G and 25G



# EBUS: 21g vs 22g needle

**TABLE 2.** Classification of Histologic Specimens Obtained by EBUS-TBNA

Category of Histologic Specimens	Needle Size for EBUS-TBNA	
	21-gauge	22-gauge
I. Diagnostic	35 (58)	34 (57)
II. Nondiagnostic, adequate	8 (13)	13 (22)
III. Nondiagnostic, inadequate	15 (25)	7 (12)
IV. No specimens	2 (3)	6 (10)

Data are presented as n (%). Using the  $\chi^2$  test,  $P = 0.40$  across the sampling yield of adequate histologic specimens (I and II) in the needle sizes.

EBUS-TBNA indicates endobronchial ultrasound-guided transbronchial needle aspiration.

使用21號針，  
拿到specimen  
的機會比較高，  
但會出現blood  
contamination機  
會也會增加許  
多

**Table 1** Results of evaluated factors of each needle

Evaluated factors ( $n = 45$ )	22G > 21G	22G = 21G	22G < 21G	P-value
Cytology				
Number of tumour cells ( $n =$ )	11	12	22	$P = 0.0256$
Blood contamination ( $n =$ )	3	9	33	$P < 0.0001$
Histology				
Quantity of tissue ( $n =$ )	14	16	15	$P = 0.9661$

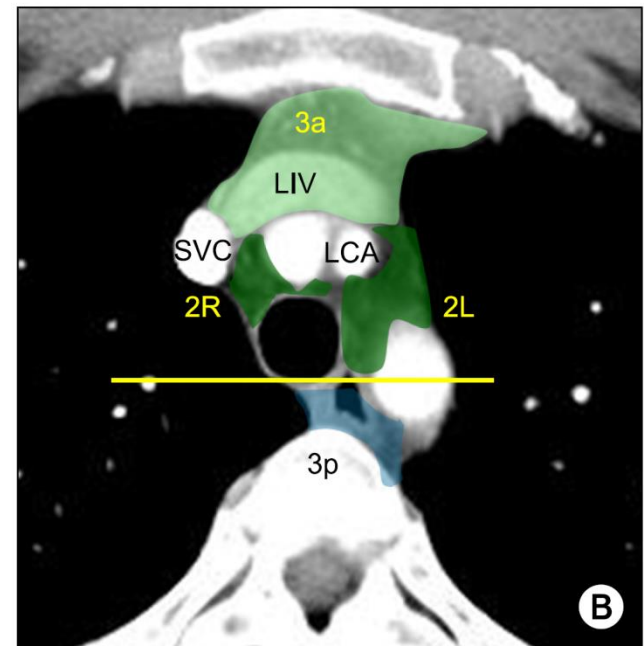
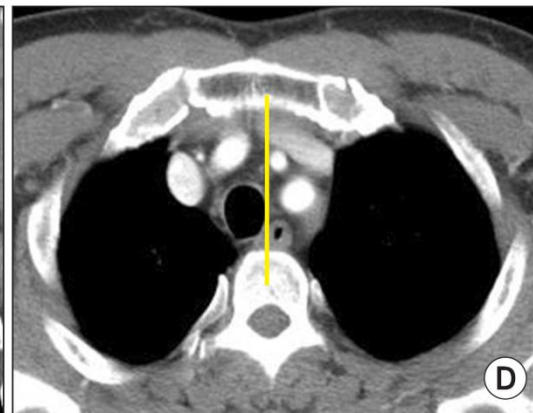
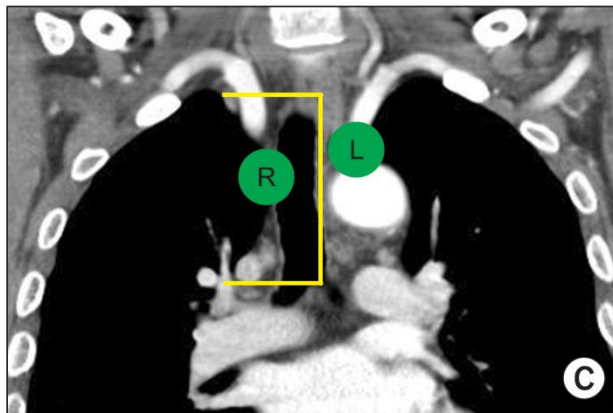
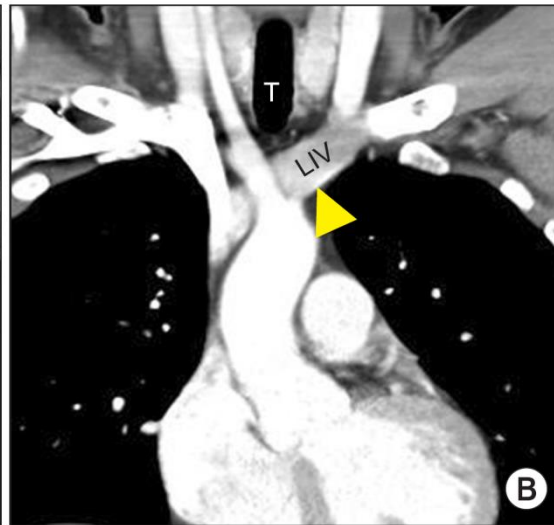
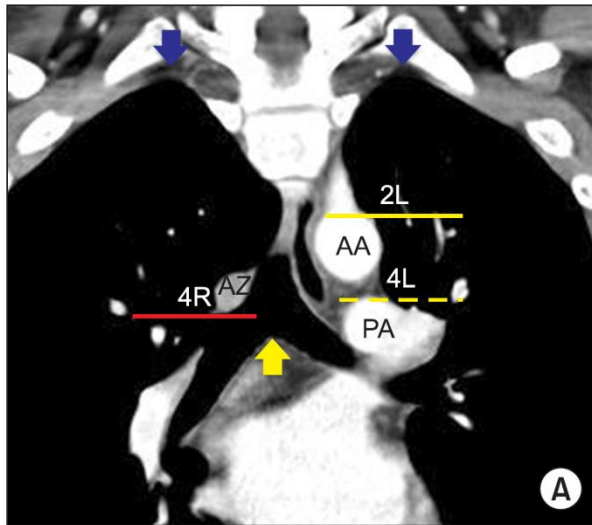


## EBUS-TBNA操作介紹

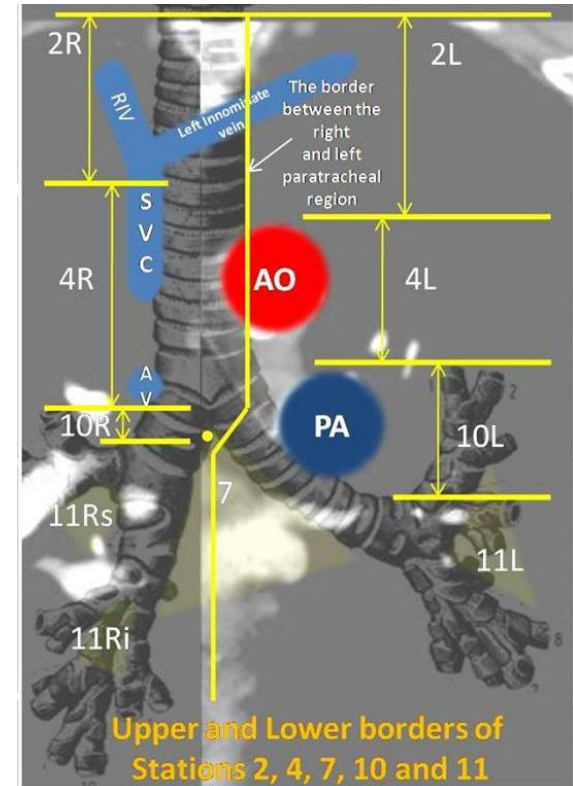
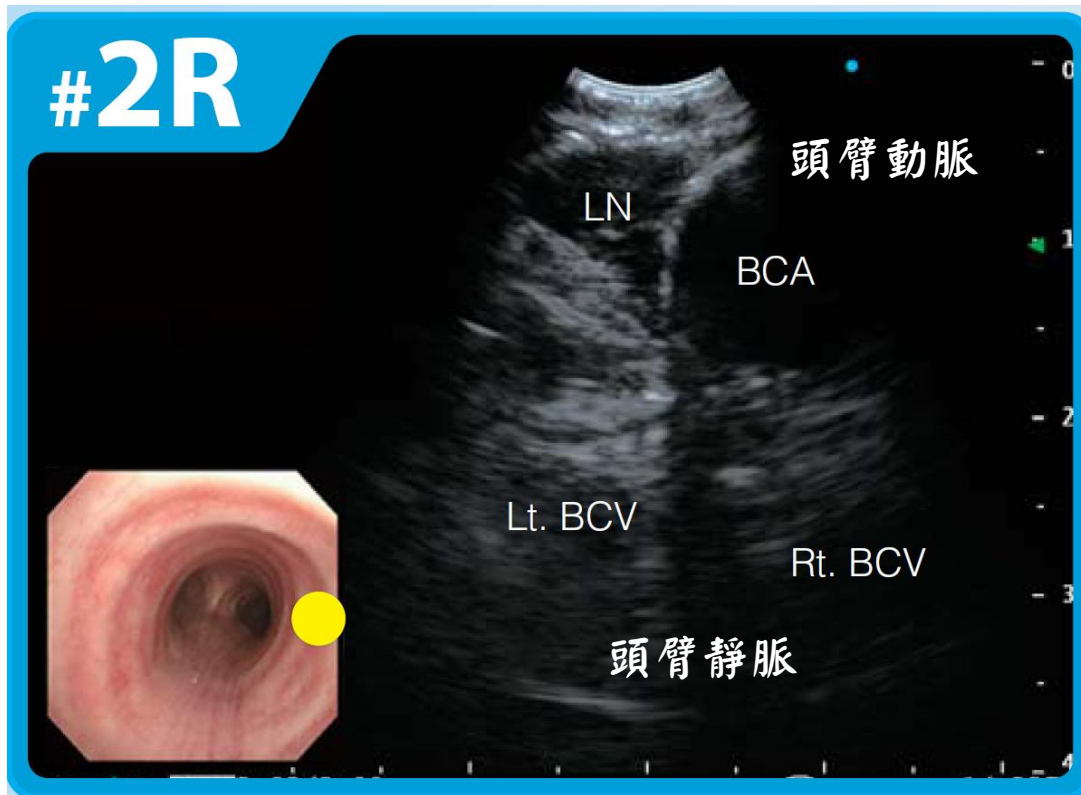
# LYMPH NODE



# Group 2 Upper Paratrachea

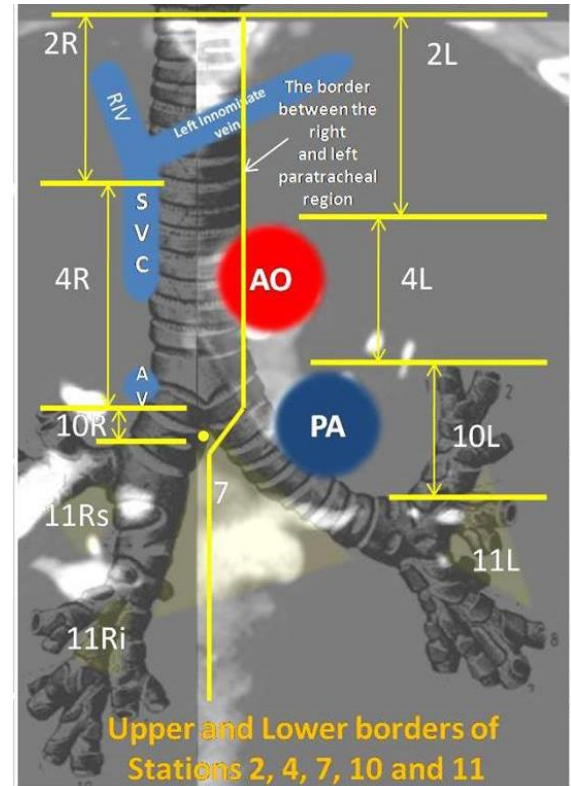
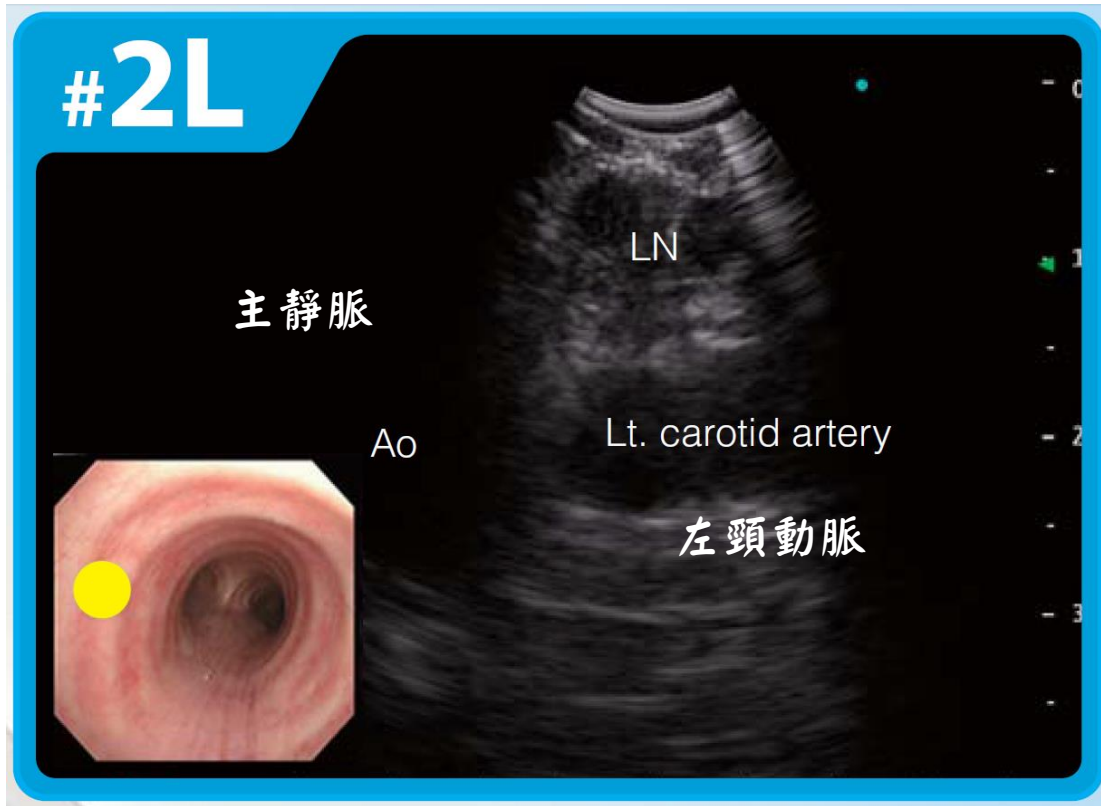


# Group 2R



While visualizing the SVC on the ultrasound image, withdraw the bronchoscope maintaining contact with the trachea at the two to three o'clock position. The SVC will bifurcate to the left and right brachiocephalic veins. Any lymph node distal to the bifurcation along the right side of the trachea is station #2R.

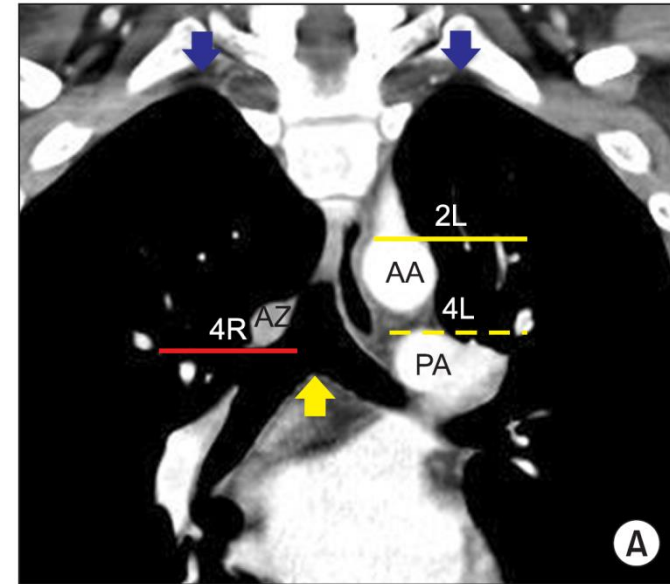
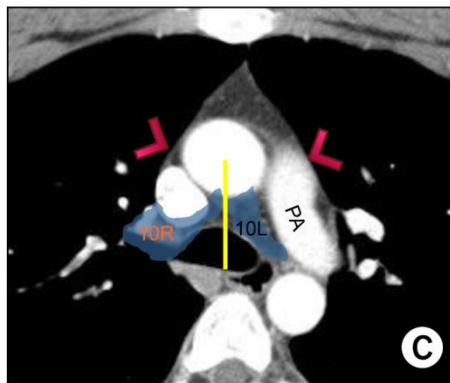
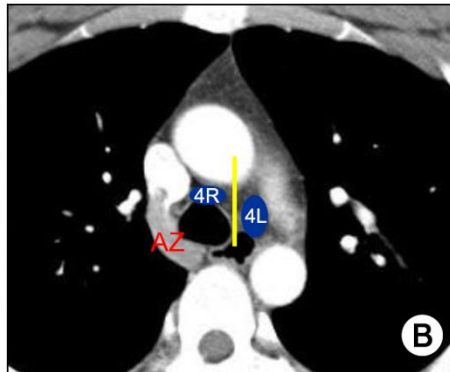
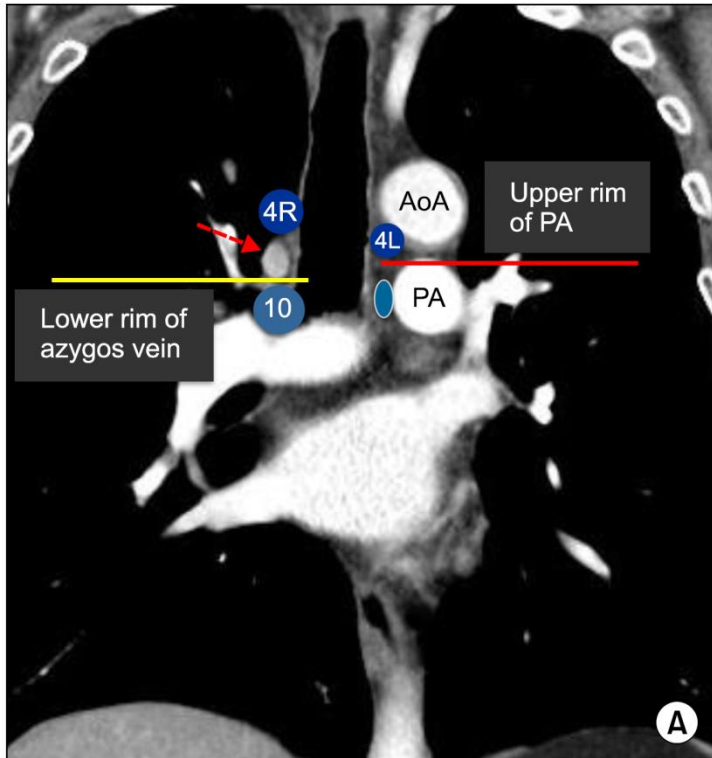
# Group 2L



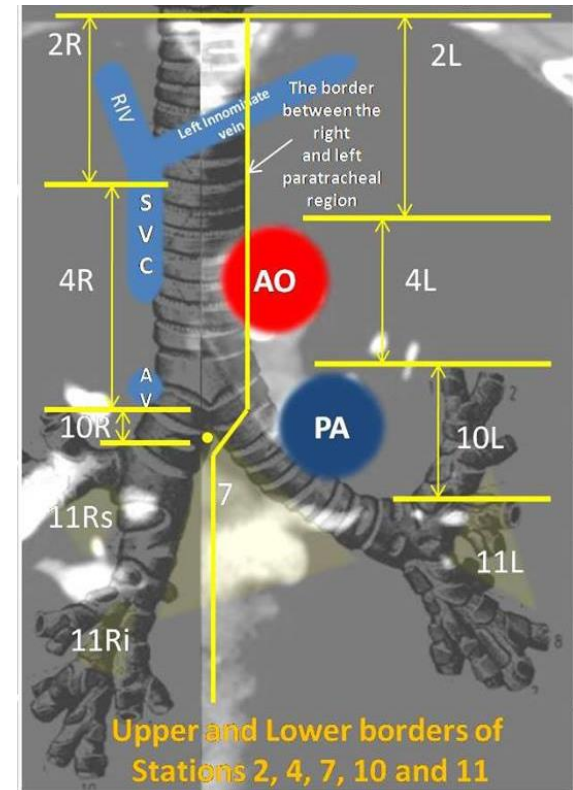
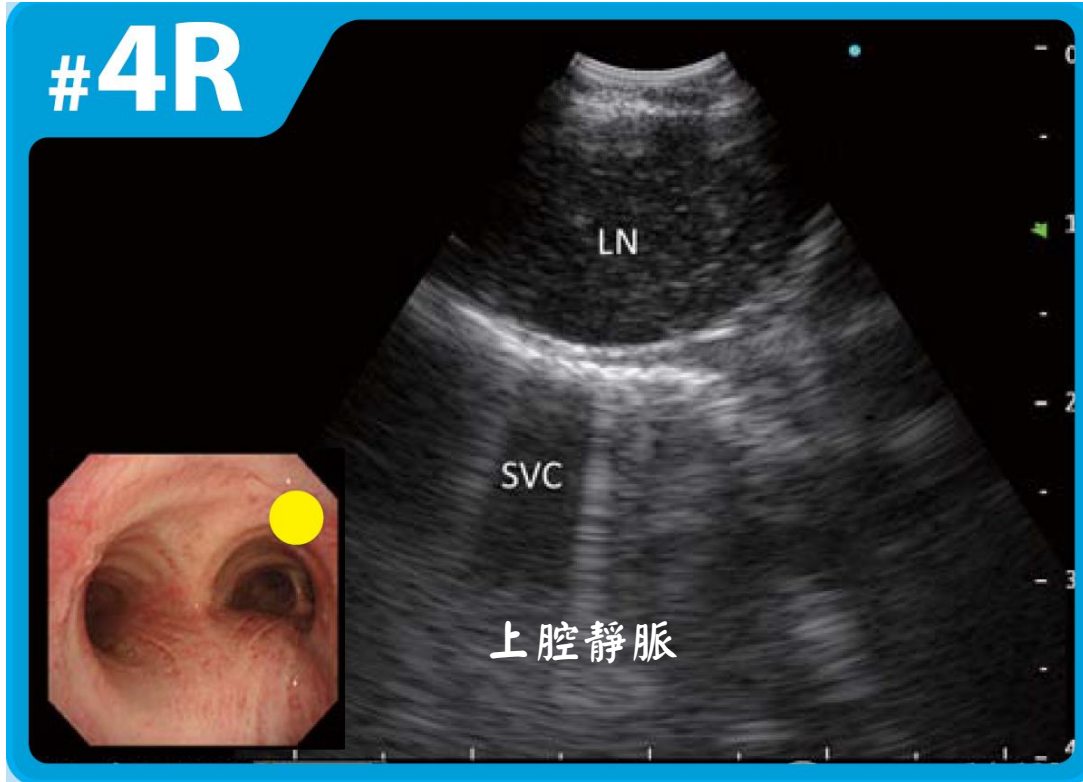
The aortic arch is the vascular landmark for differentiating station #2L and #4L. Lymph node present on the left side of the trachea above the aortic arch is station #2L.



# Group 4 Lower Paratrachea

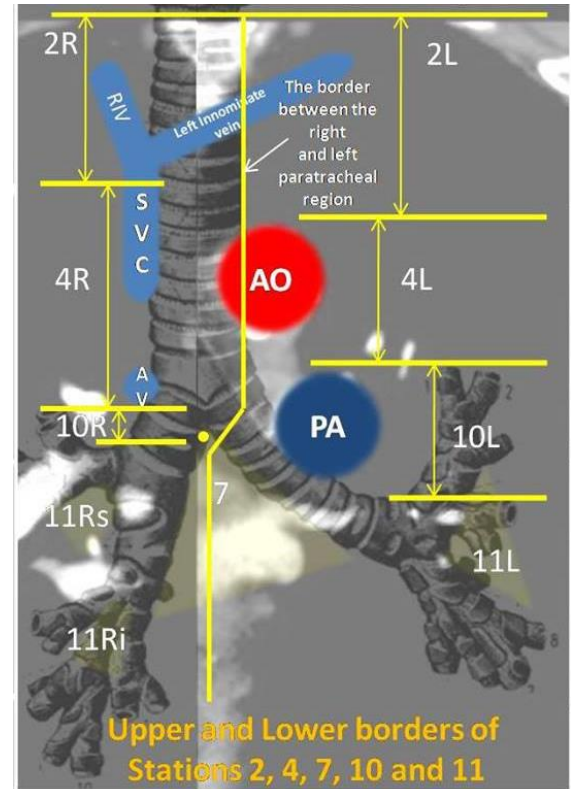
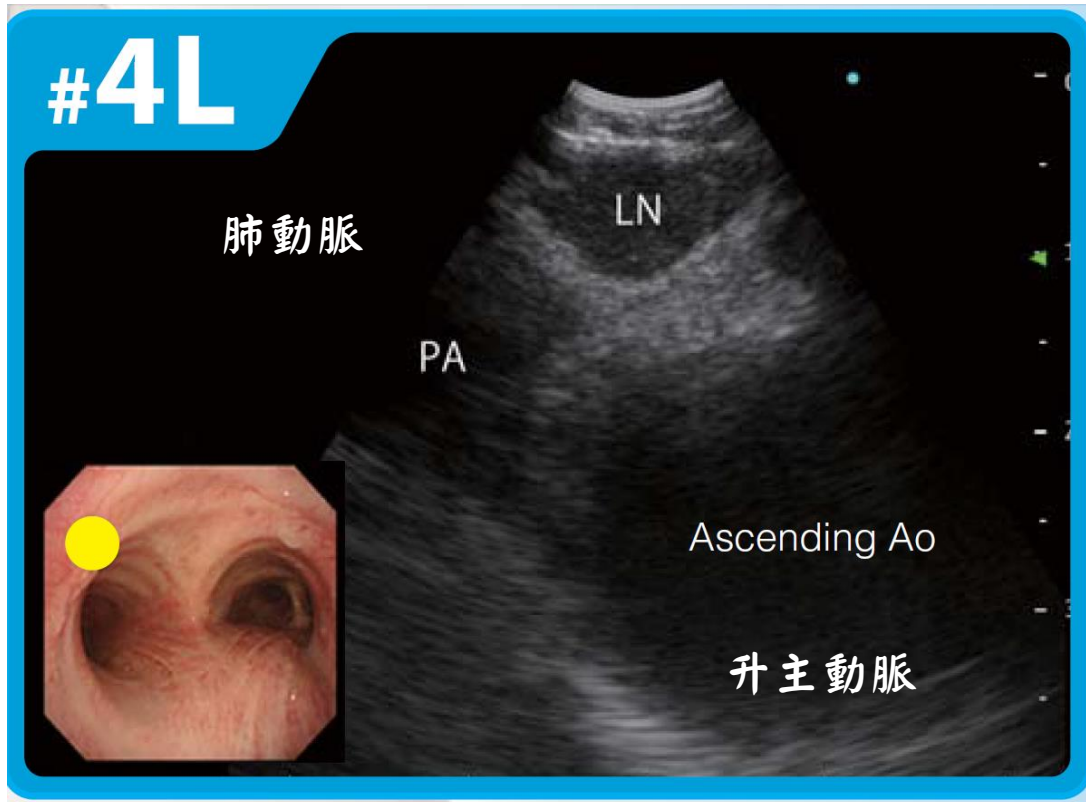


# Group 4R



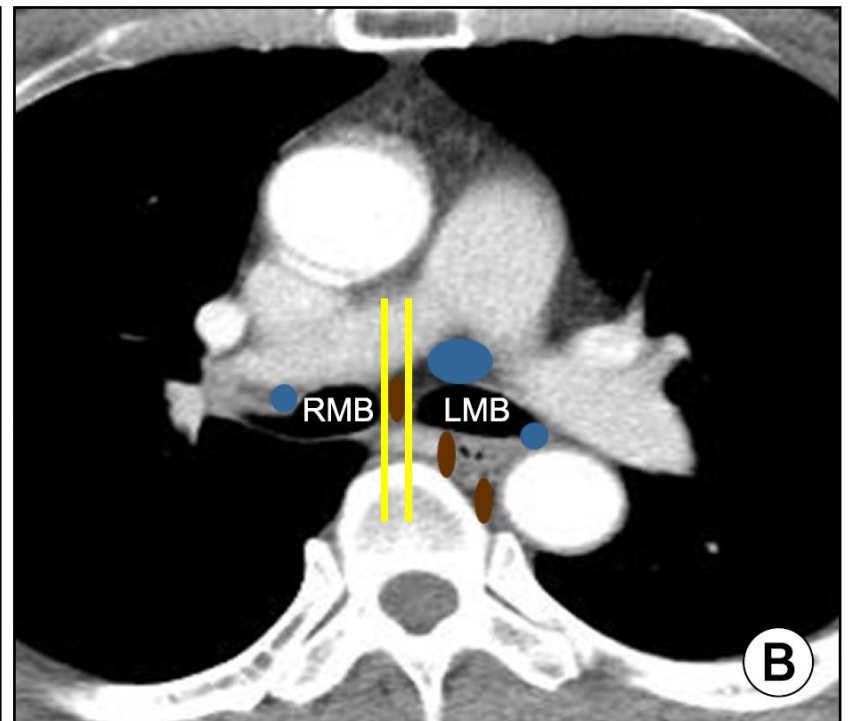
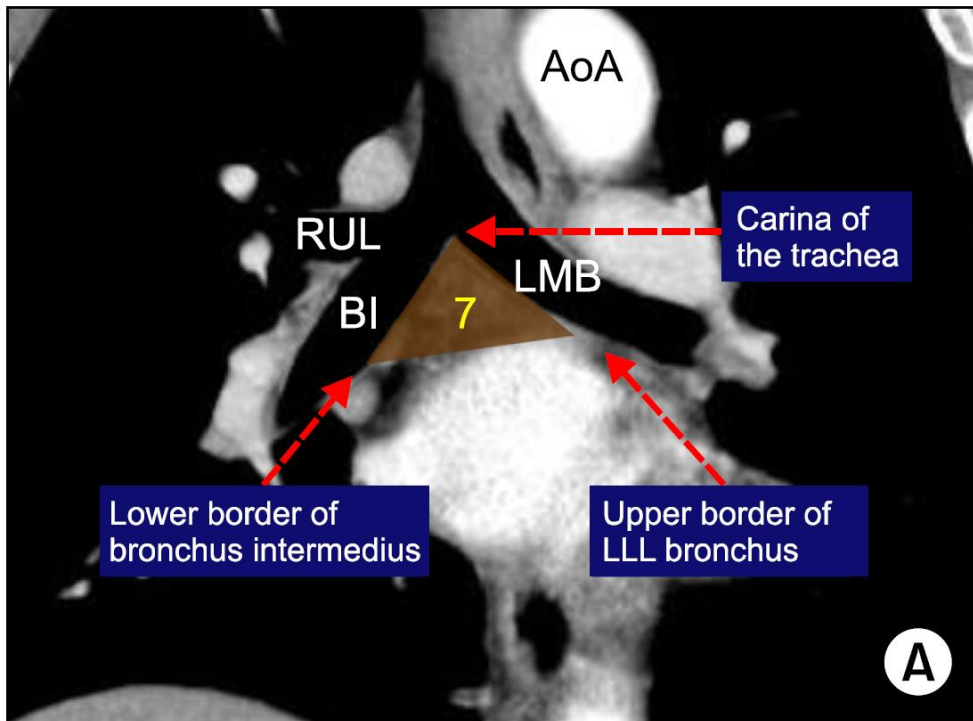
Withdraw the bronchoscope to the trachea looking straight towards the main carina. Turn to the two o'clock position and press the tip just proximal to the main carina. Look for the SVC and the azygos vein branching from the SVC. Station #4R is close to the SVC and the azygos vein.

# Group 4L



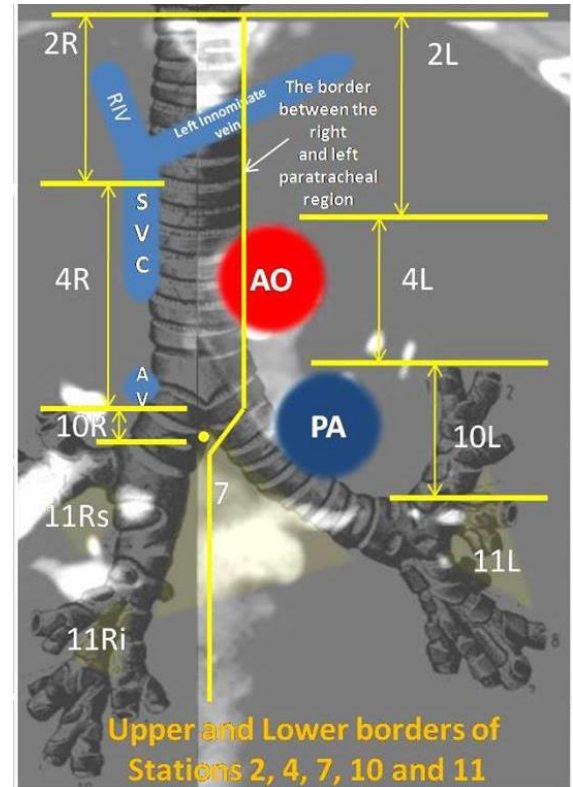
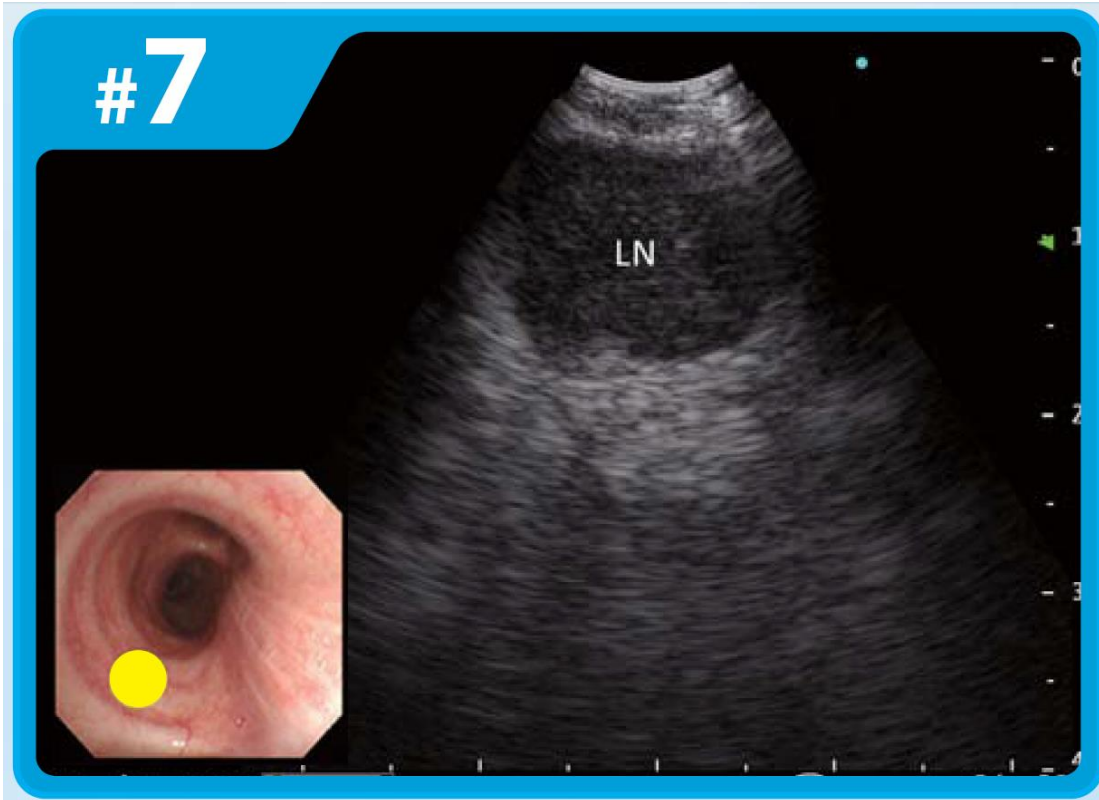
Facing the main carina, turn the bronchoscope to the 10 o'clock position and press the tip just proximal to the main carina and scan the area for station #4L. The aortic arch can be followed to the aorto-pulmonary window. The aortic arch is proximal and the left main pulmonary artery is distal.

# Group 7 Subcarina





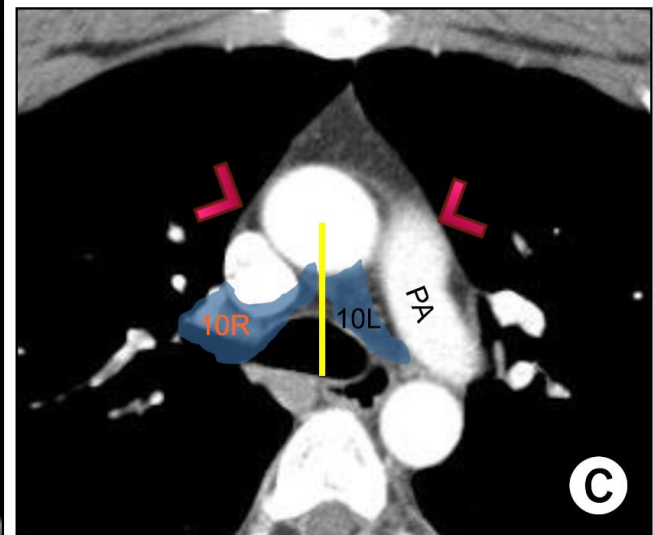
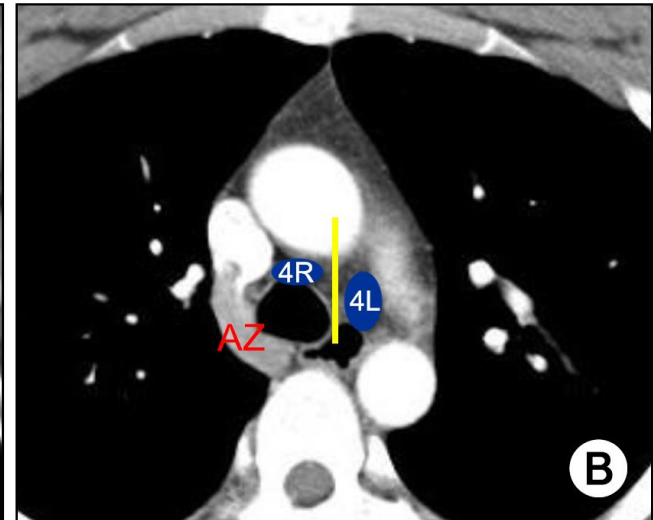
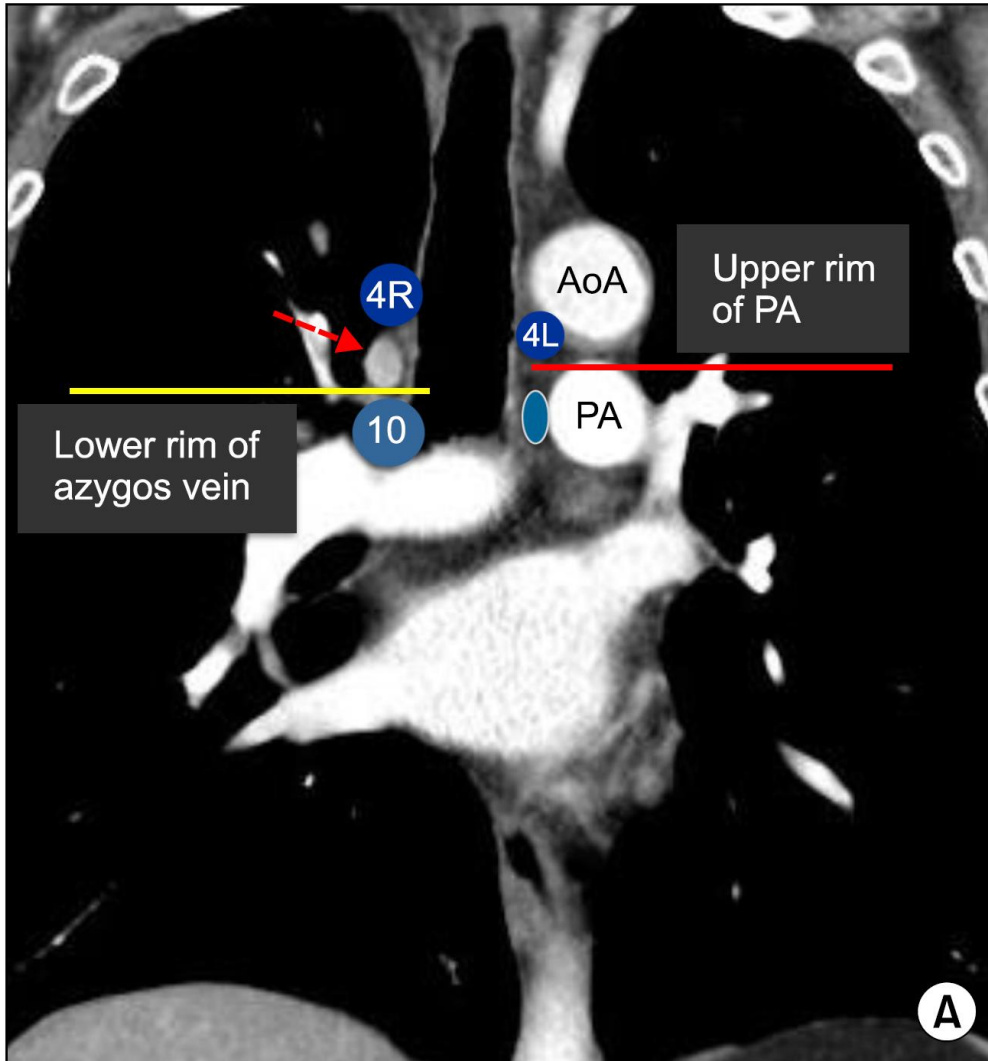
# Group 7



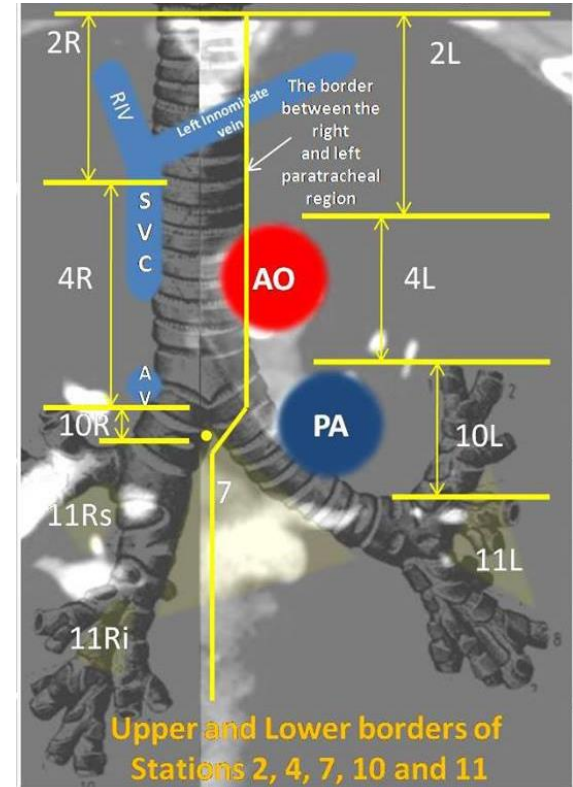
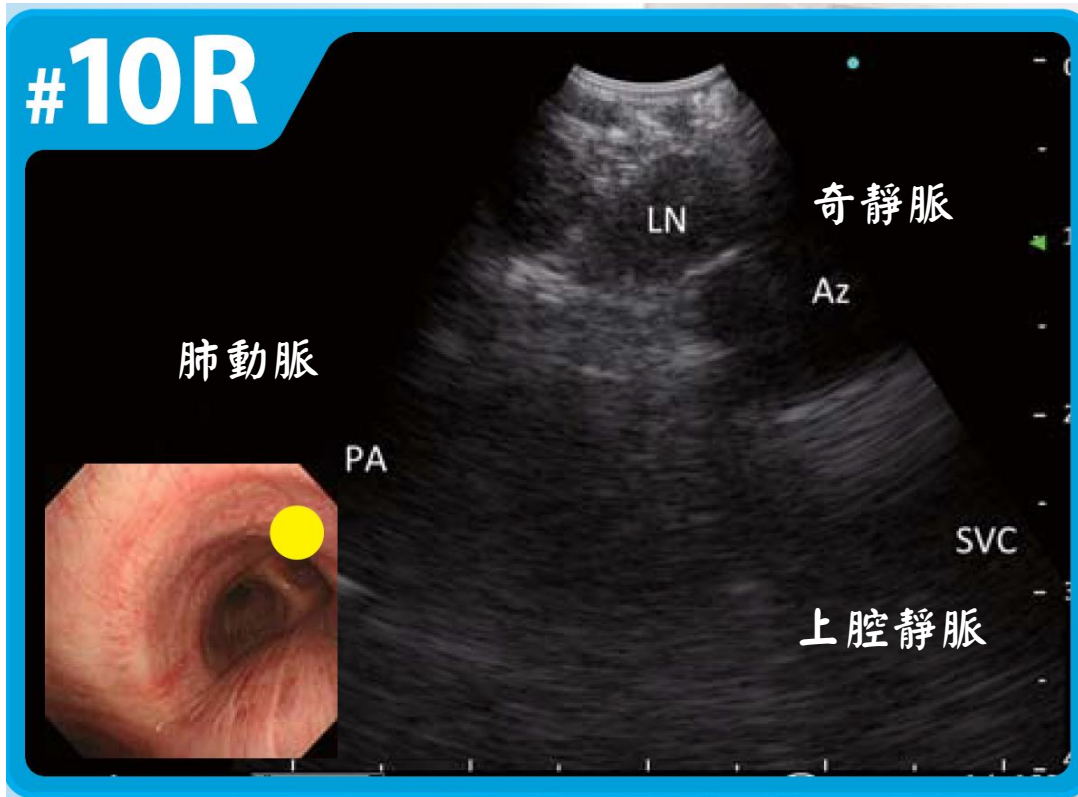
Station #7 can be visualized from either the right or the left main bronchus. On the right side, turn to the 12 o'clock position and press the tip against the right main bronchus where the main stem of the pulmonary artery is visualized. After confirmation with the Doppler mode, turn the tip to the nine o'clock position to visualize station #7. Lymph node distal to station #7 along the main bronchus is station #10R.



# Group 10 Hilar nodes

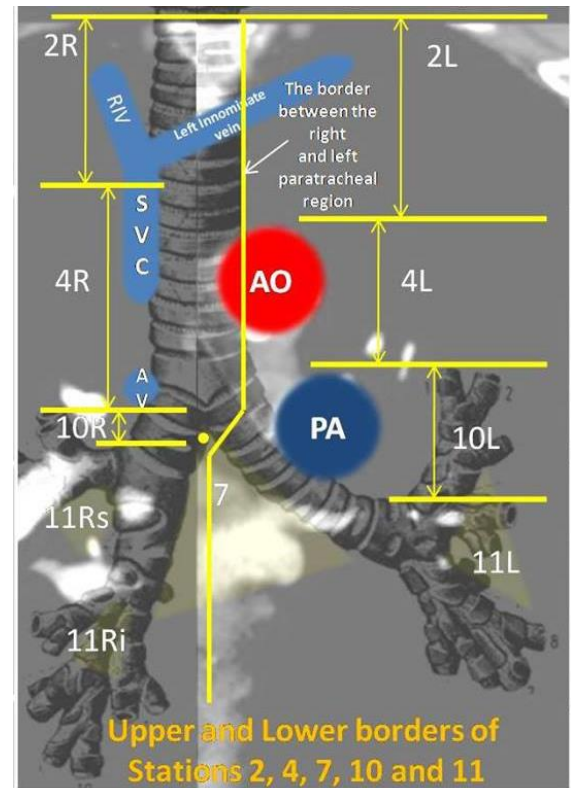
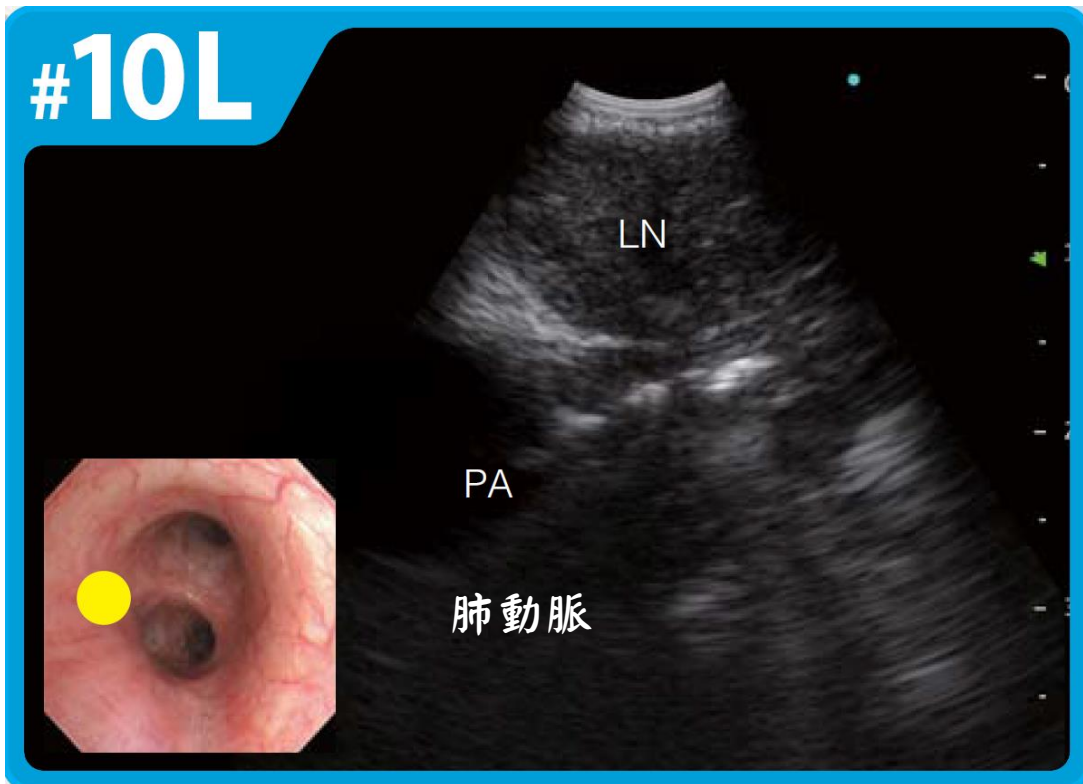


# Group 10R



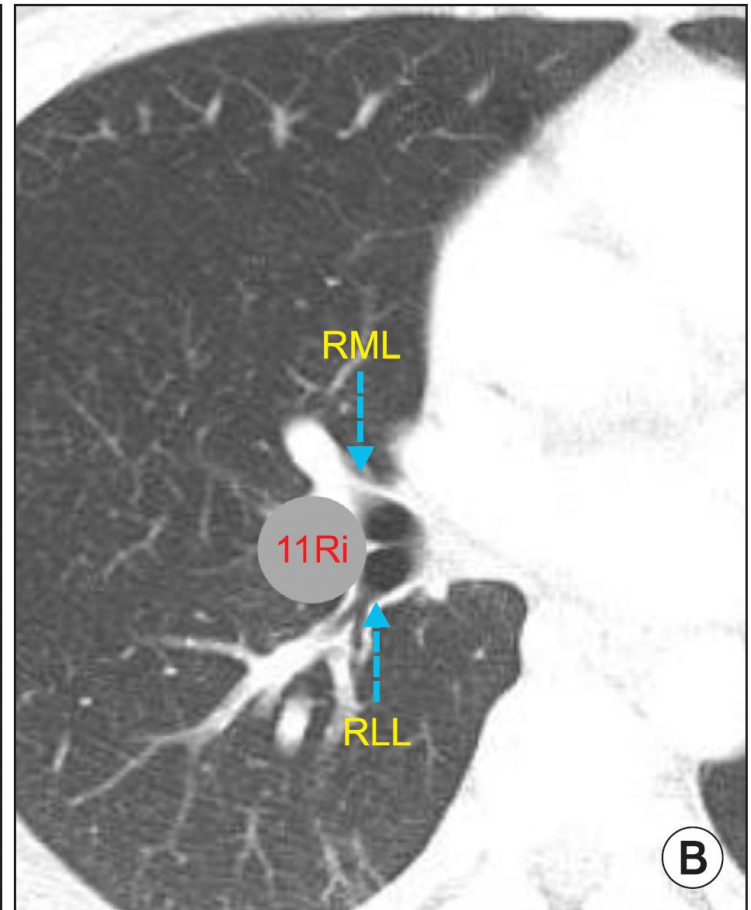
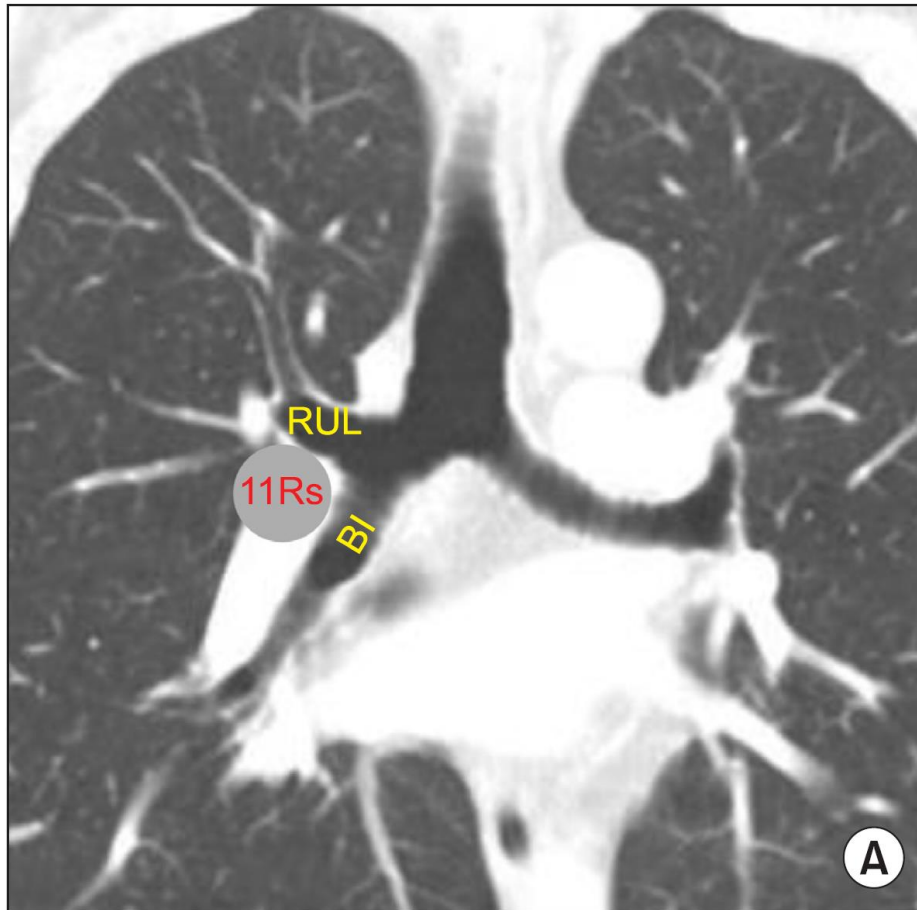
Withdraw the bronchoscope to the right main bronchus. Turn the tip to the three o'clock position and press the tip to visualize station #10R. Station #10R also lies just distal to station #7 along the right main bronchus. This part is visualized after identifying station #7 at the nine o'clock position at the right main bronchus.

# Group 10L



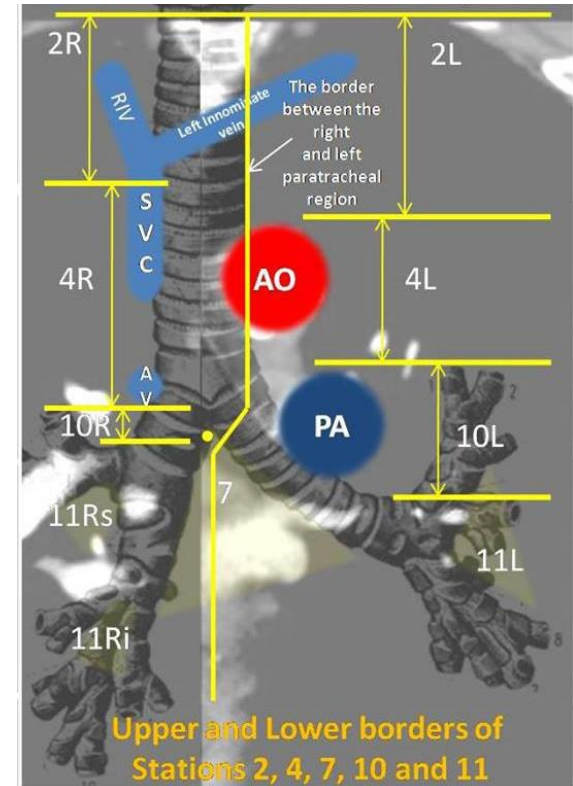
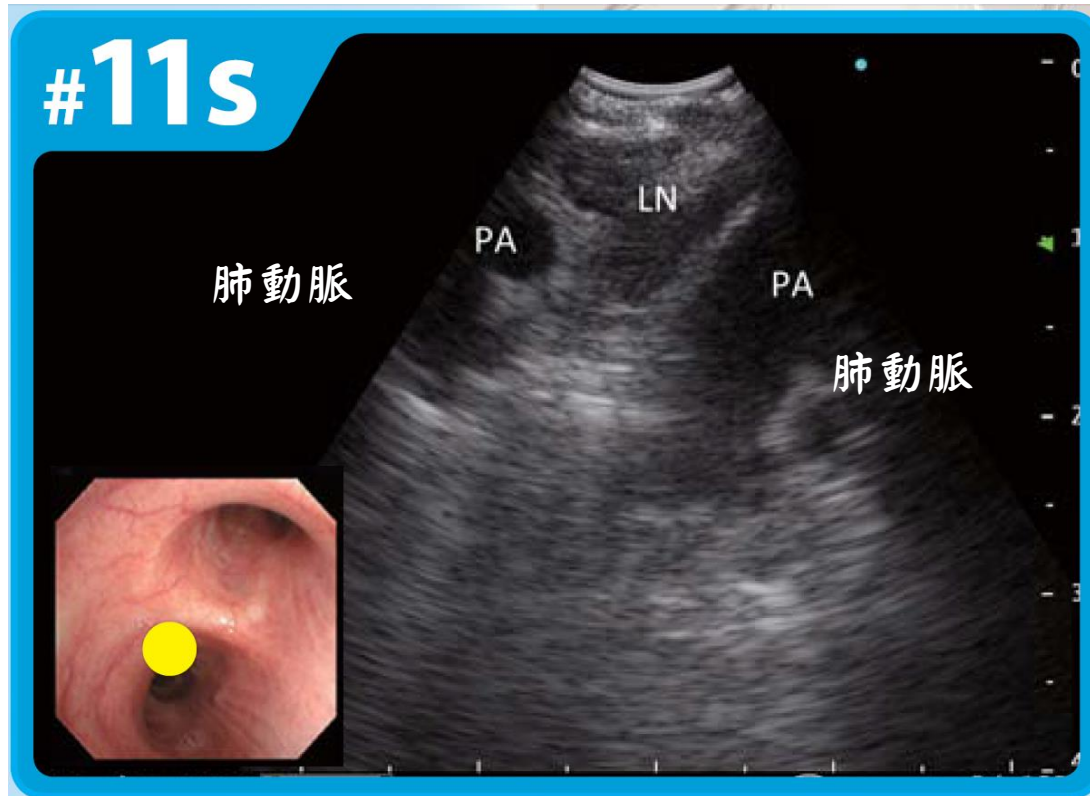
Advance the bronchoscope into the left main bronchus at the 10 o'clock position by following the left pulmonary artery on ultrasound image. This is the area of station #10L. Similar to station #10R, #10L can be visualized distal to station #7 at the three o'clock position on the left main bronchus.

# Group 11 Interlobar node





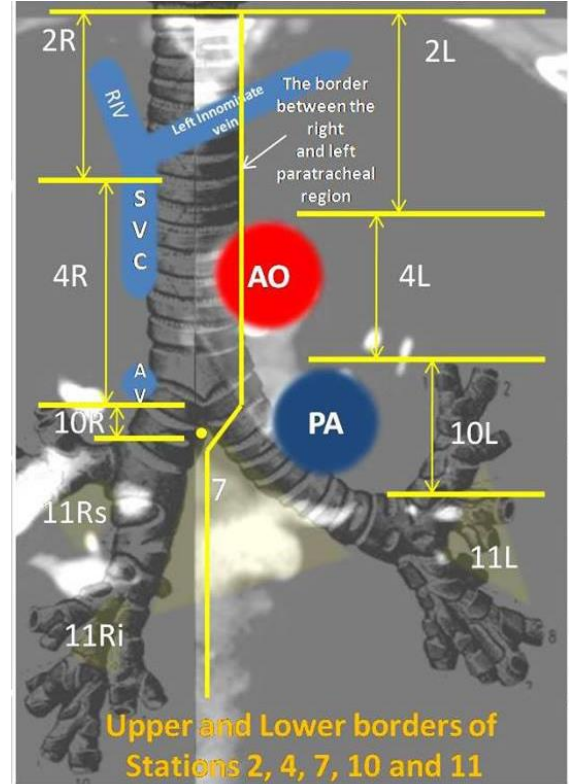
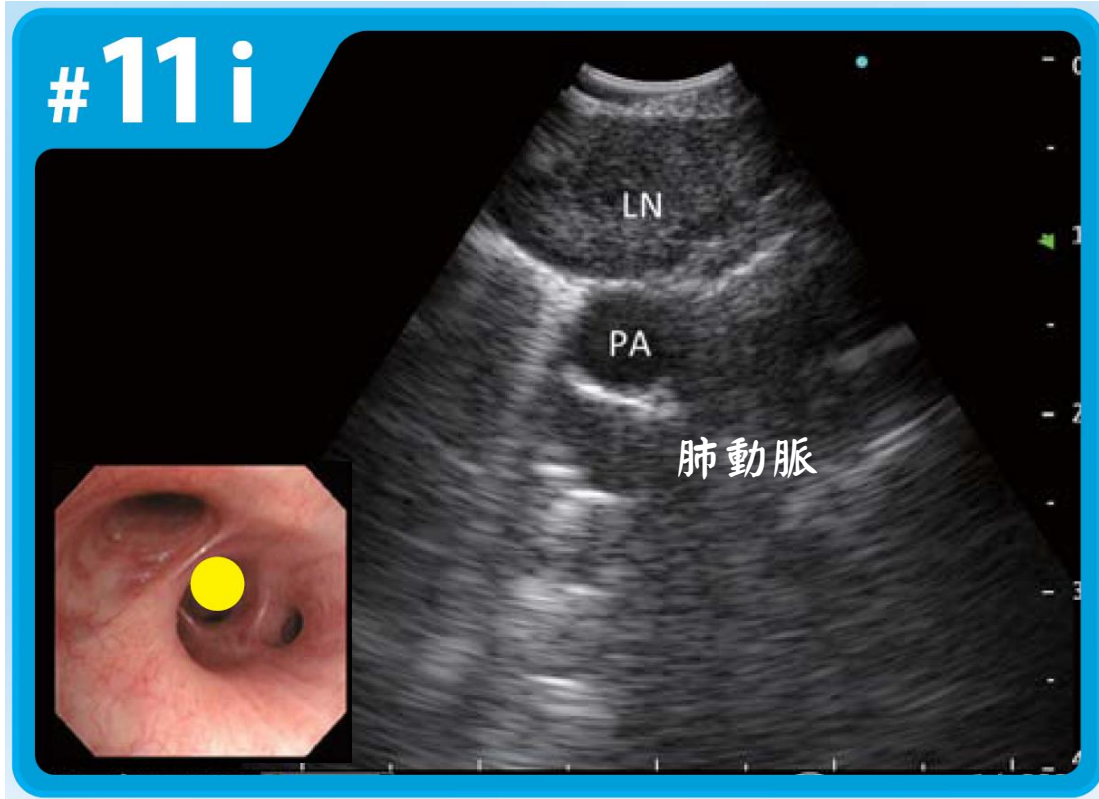
# Group 11Rs



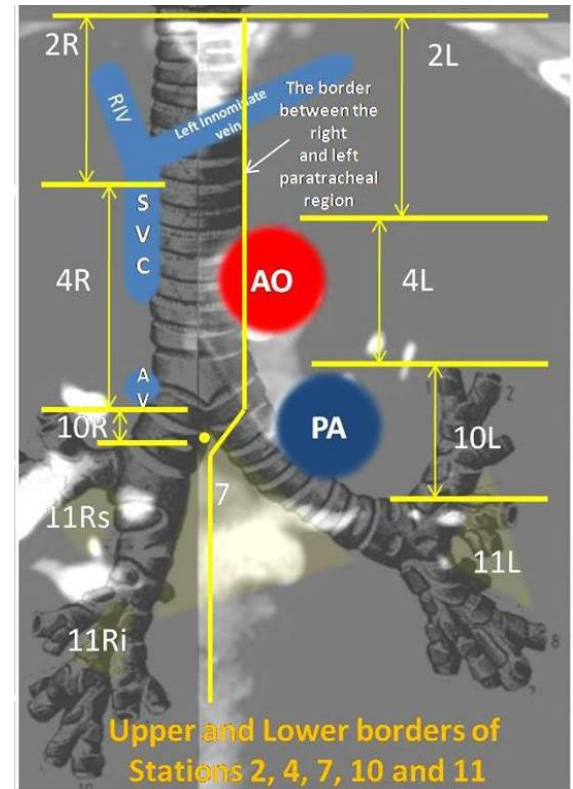
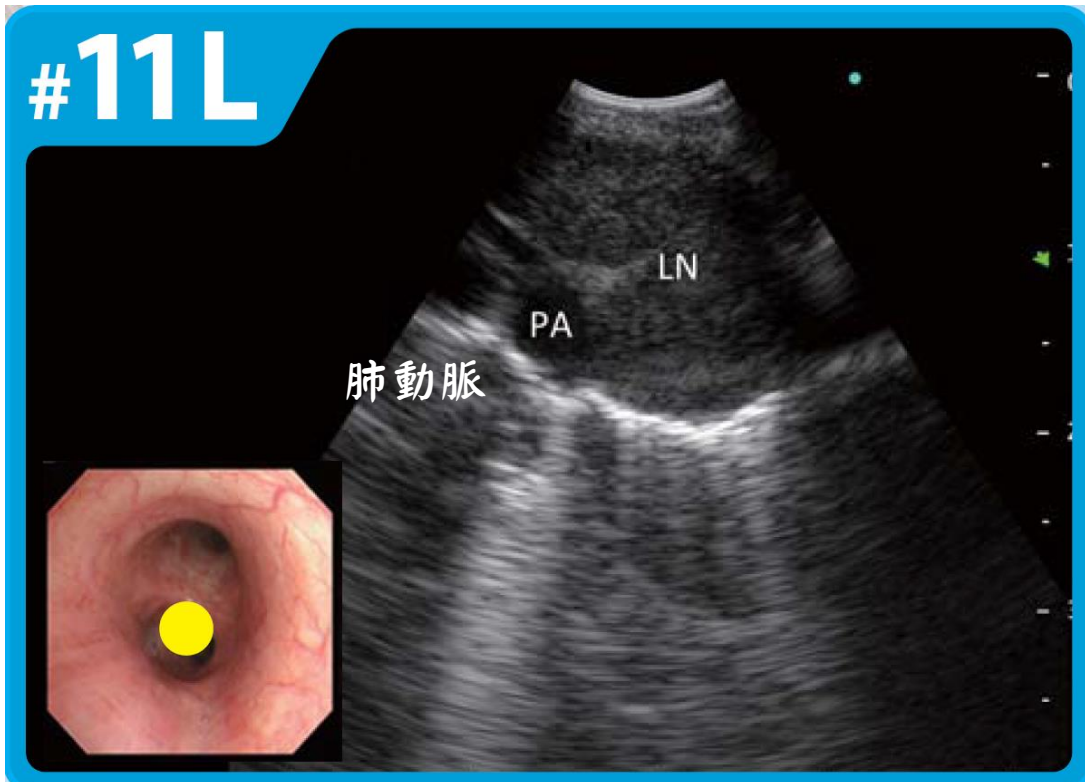
Straighten and withdraw the bronchoscope to the intermediate bronchus. Turn to the two o'clock position and press the tip just distal the entrance of the right upper lobe bronchus. Station #11R can be visualized with the interlobar pulmonary artery running distal to the lymph node.



# Group 11Ri

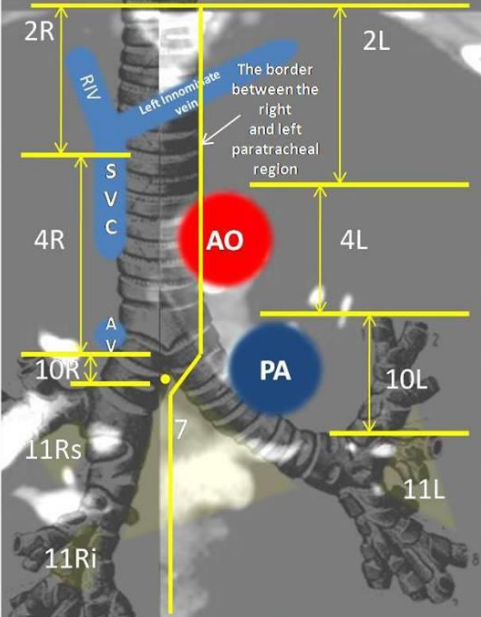


# Group 11L



Further advancing the bronchoscope into the left lower lobe bronchus, press the tip at the two o'clock position in the carina of the upper and lower lobe bronchus. Station #11L is visualized adjacent to the interlobar pulmonary artery.

**CT-WLB-EBUS correlations for regional lymph nodes by IASLC system**

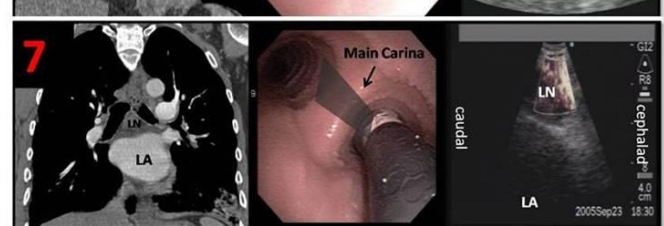
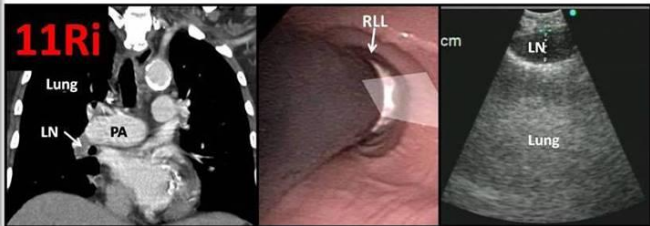
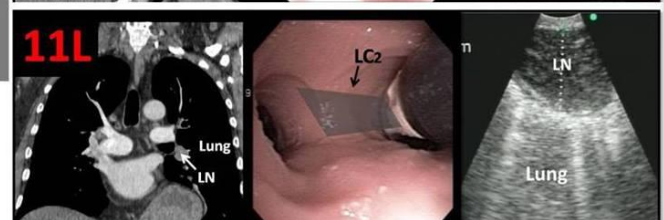
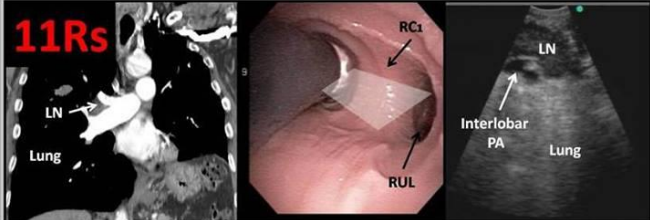
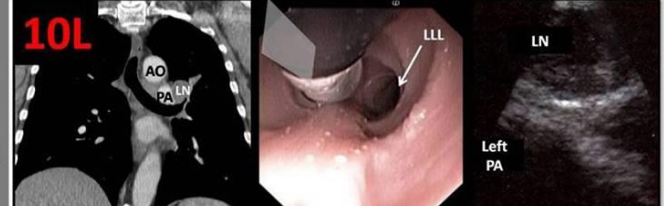
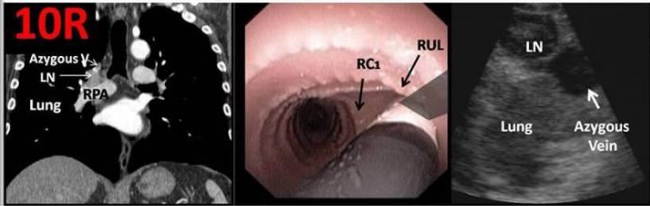
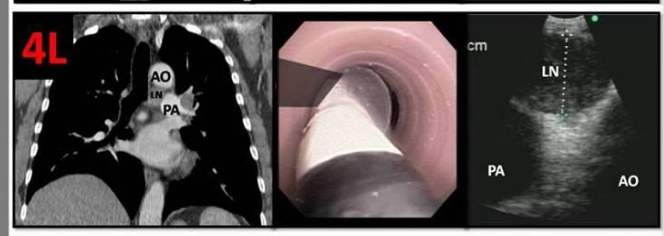
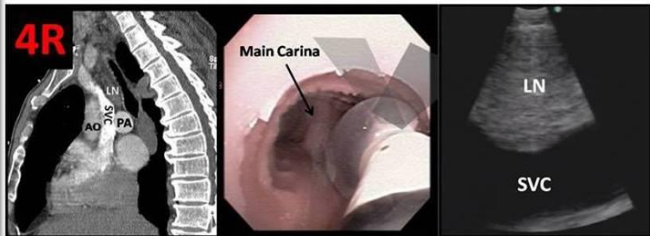
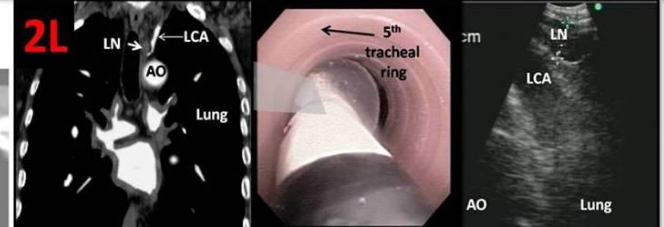
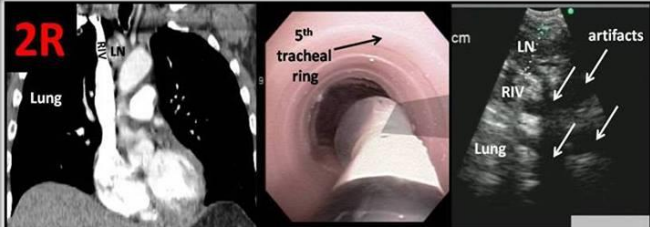


**Upper and Lower borders of Stations 2, 4, 7, 10 and 11**

- AV: azygos vein
- AO: aorta
- LN: lymph node
- PA: pulmonary artery
- SVC: superior vena cava
- RC1: primary right carina
- RUL: right upper lobe
- RLL: right lower lobe
- LCA: left carotid artery
- LC2: secondary left carina
- LUL: left upper lobe

© Bronchoscopy International 2010

Septimiu Murgu, MD & Henri Colt, MD



CEPHALAD CAUDAL  
LA  
2005Sep23 18:30

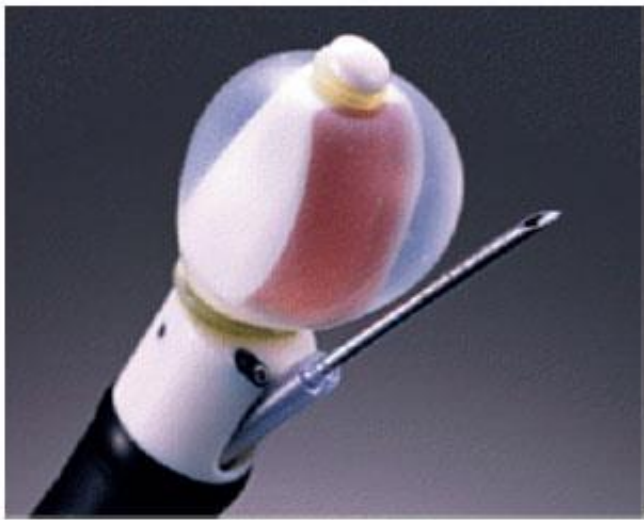


## EBUS-TBNA操作介紹

# BALLOON

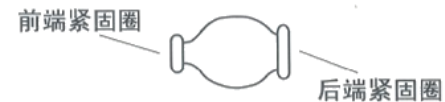


# Balloon

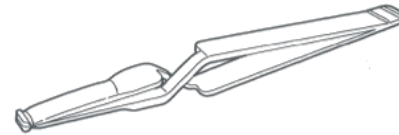


< 术语 >

- 水囊 (MAJ-1351)

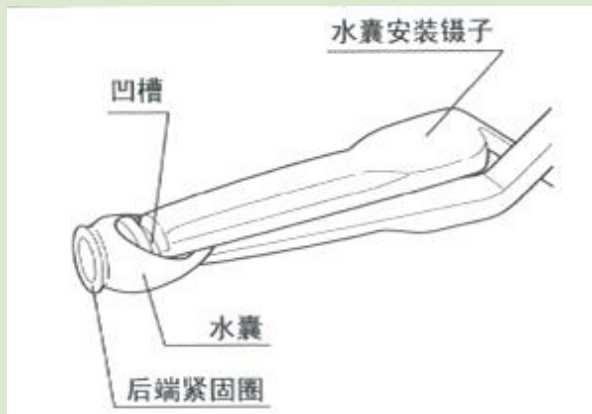

- 水囊安装镊子 (MAJ-1352)

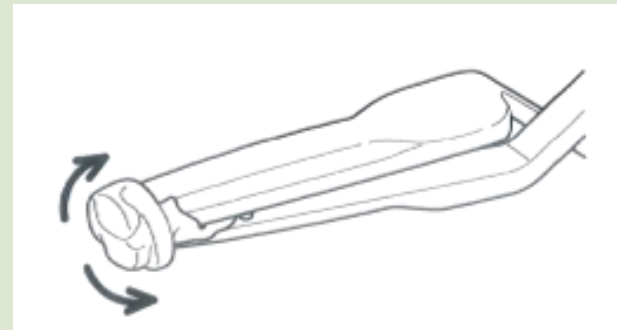


- 超音波探頭與呼吸道之間如果存在空氣，將不能獲得良好的超音波圖像，因此需要靠水來當作介質。
- 為防止形成假影，應移除水囊內所有氣泡，也必須預防水自水囊內漏出。

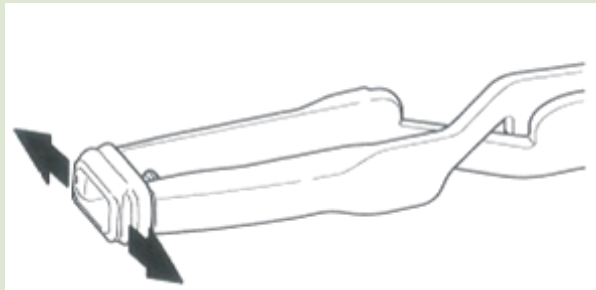




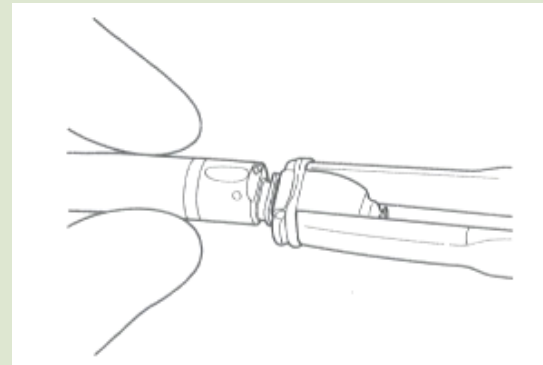
水囊安裝鑷子夾住水囊遠端



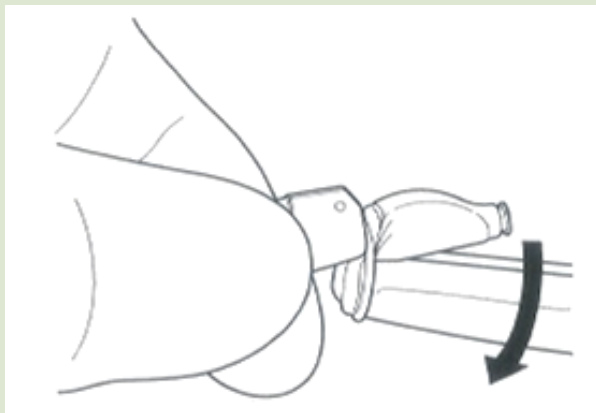
水囊近端向後反摺，將其放入水囊安裝鑷子的凹槽



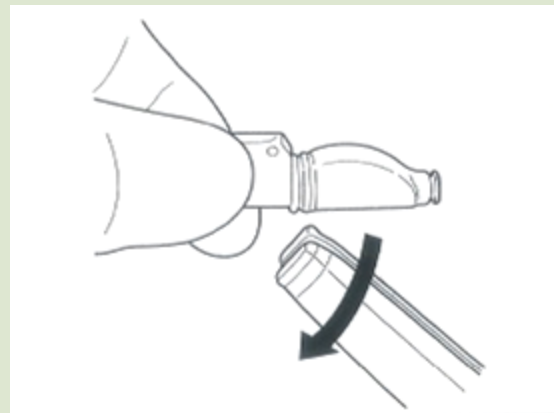
打開水囊安裝鑷子直至其擴展至內視鏡探頭的寬度



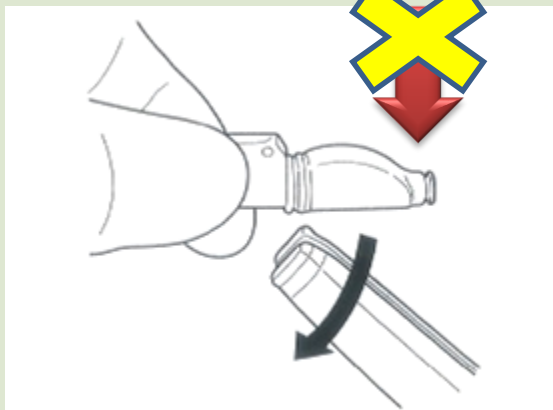
將水囊放置在超音波探頭上



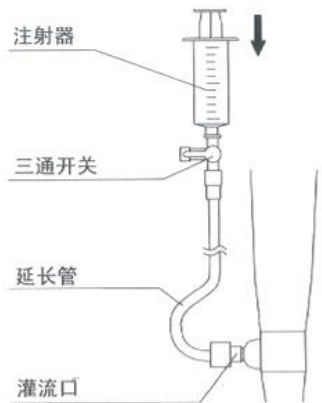
將近端反摺部分裝入內視鏡近端的凹槽內，將水囊安裝鑷子移向探頭的後端



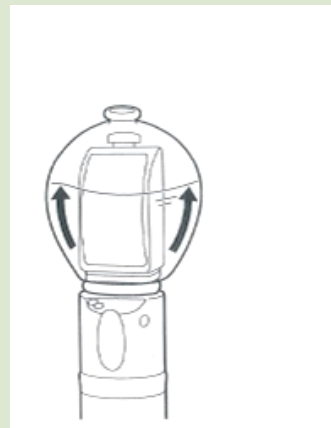
持續向下移動水囊安裝鑷子至水囊近端的反摺部分完全裝入內視鏡近端的水囊凹槽內



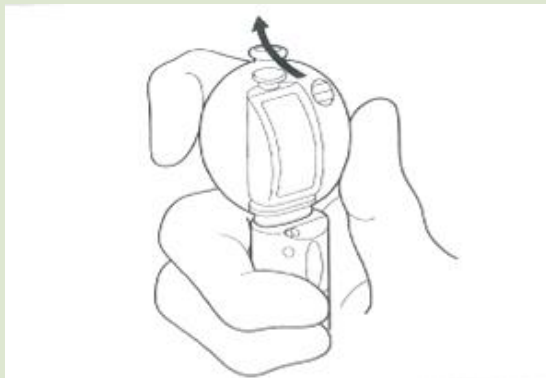不要嘗試放置水囊遠端的緊固部分，因之後需自該處將通道內的氣體完全移除



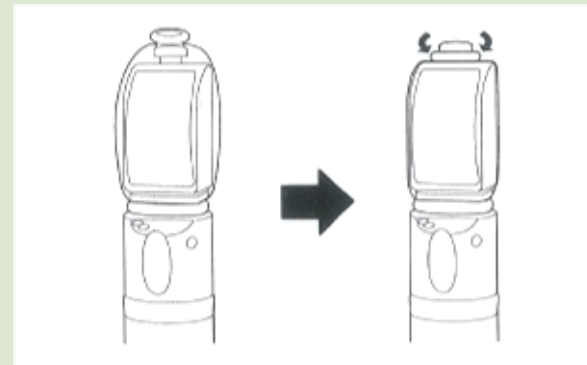
將針筒連接至活塞上，輕推針筒  
以使無菌水分布在水囊內



使水囊略膨脹後，此時將內視鏡  
遠端向上



用拇指及食指輕輕擠壓水囊，將  
水囊內空氣及無菌水自遠端推出



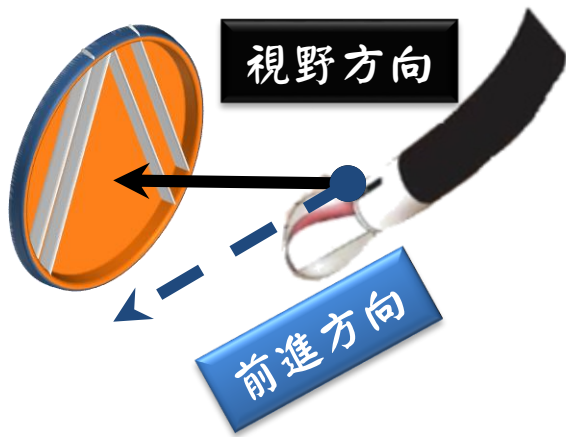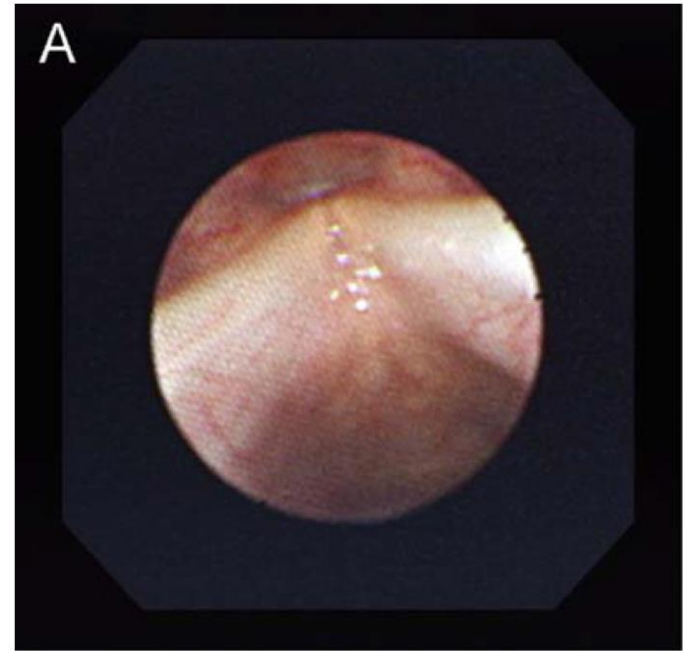
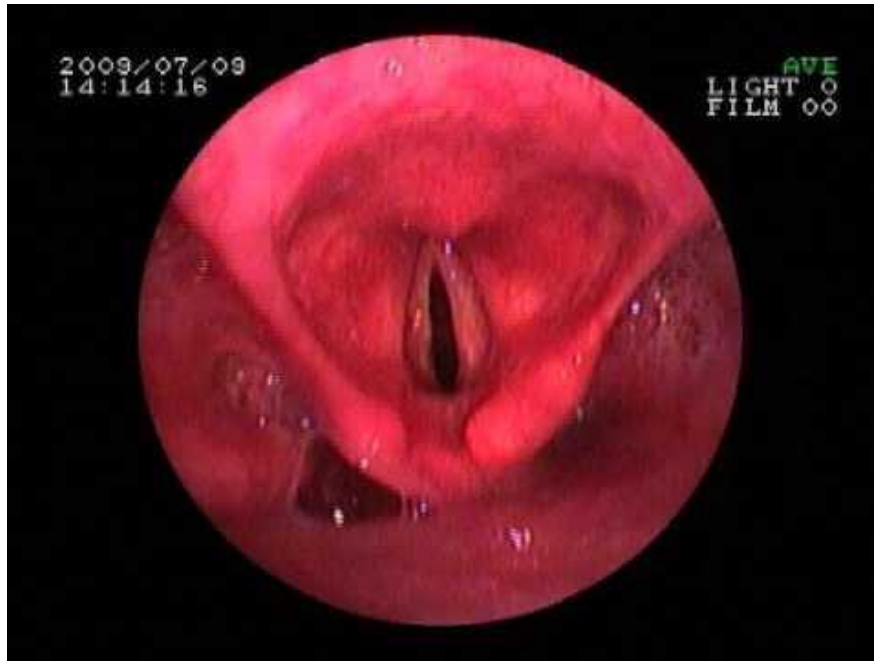一旦水囊內氣泡消失，回抽針筒，  
然後再將水囊遠端的緊固部分放  
置入探頭遠端的水囊凹槽內

## EBUS-TBNA操作介紹

# START TO VOCAL CORD



# Insert the bronchoscope





## EBUS-TBNA操作介紹

# CONNECT TO NEEDLE



# Connect to needle

探針帽

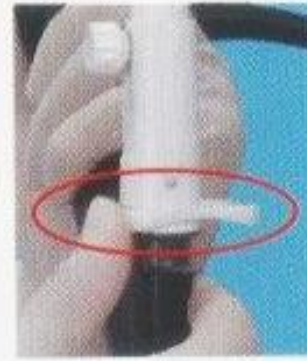採檢針滑  
動把手

連接卡  
榫

抽吸口

出針調  
節器

鞘管調  
節旋鈕



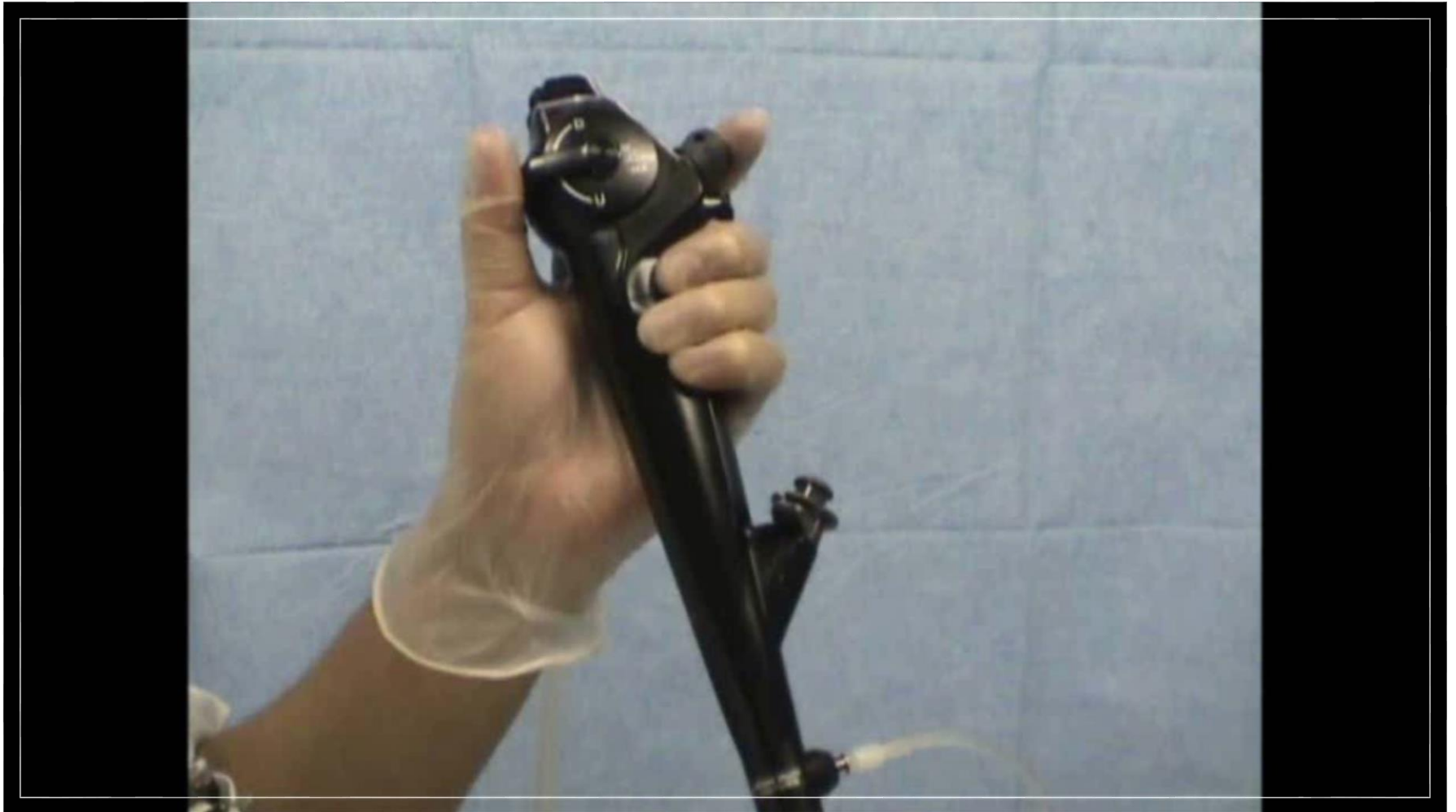连接卡锁停靠到专  
用活检阀上。

朝箭头所指方向滑  
动连接卡锁以固定  
穿刺针。



# Connect to needle

---



固定鞘管的  
位置



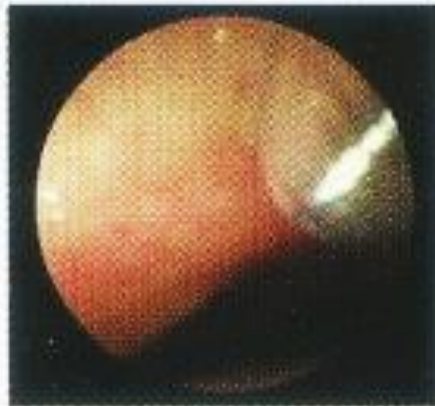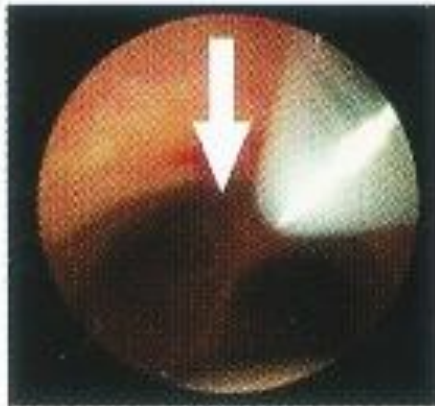
決定穿刺路  
徑



進行穿刺和  
細針活檢



移除穿刺針



將鞘管向前推進，直至  
在支氣管圖像中可見後，  
將穿刺針向前推進至鞘  
管內，當針與鞘管同時  
向下掉時，即不再前進，  
之後再回拉鞘管至初始  
位置



固定鞘管的  
位置



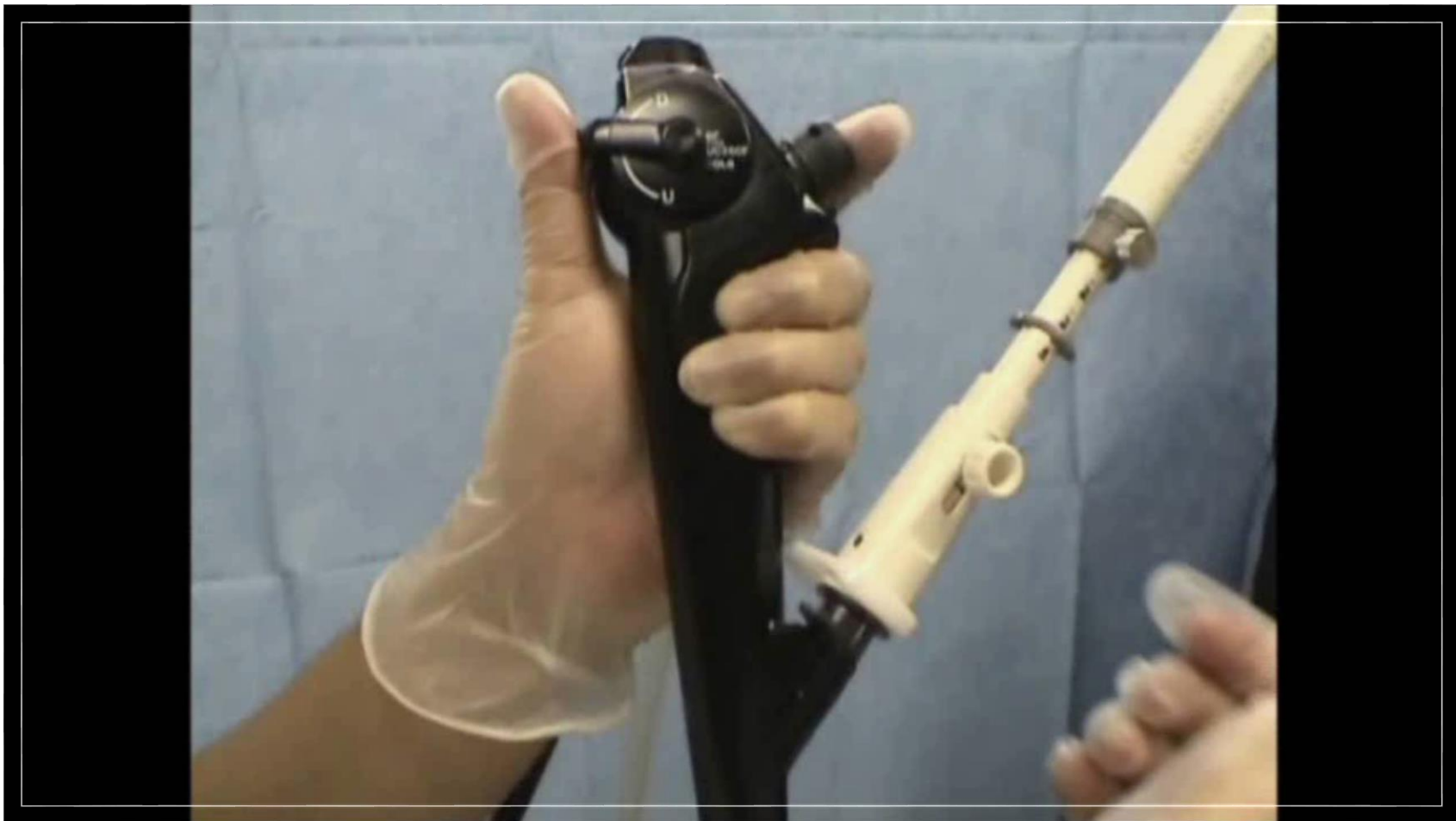決定穿刺路  
徑



進行穿刺和  
細針活檢



移除穿刺針



固定鞘管的位置



決定穿刺路徑



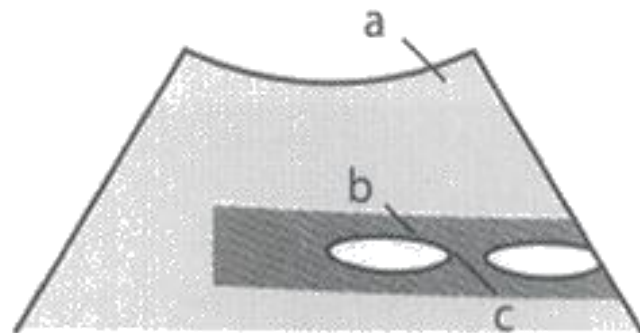
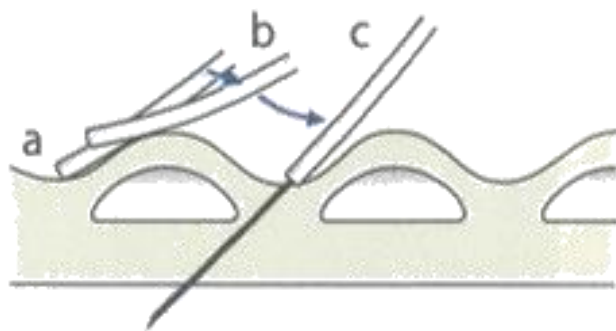
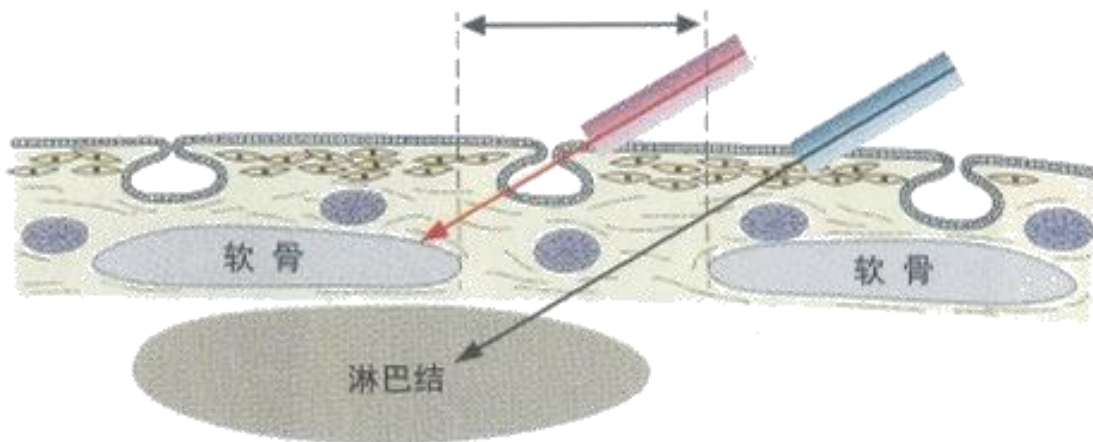
進行穿刺和細針活檢



移除穿刺針

<图8>

虽然穿刺针希望通过软骨间区域，但穿刺针实际将碰到软骨。



固定鞘管的  
位置



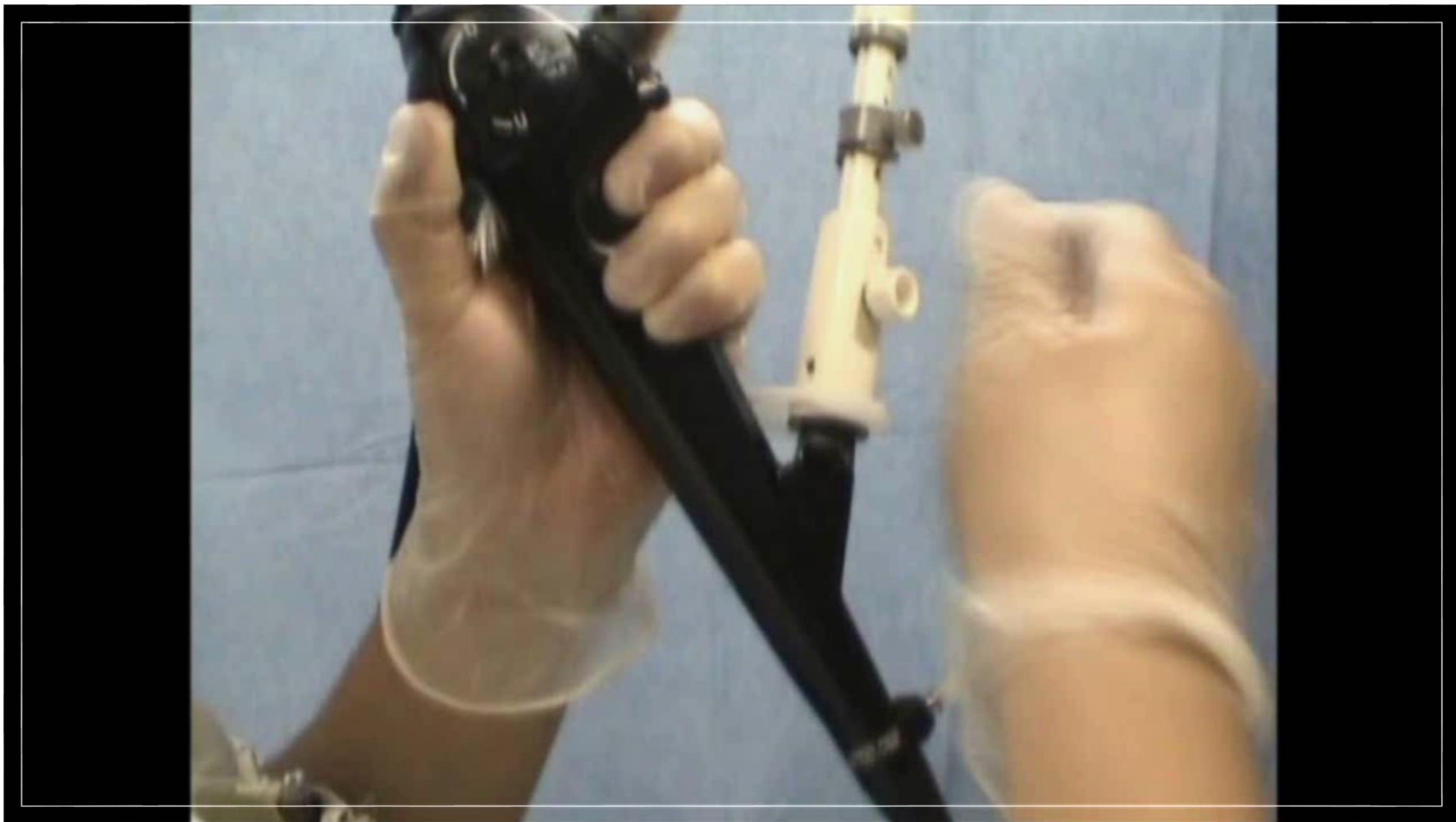決定穿刺路  
徑



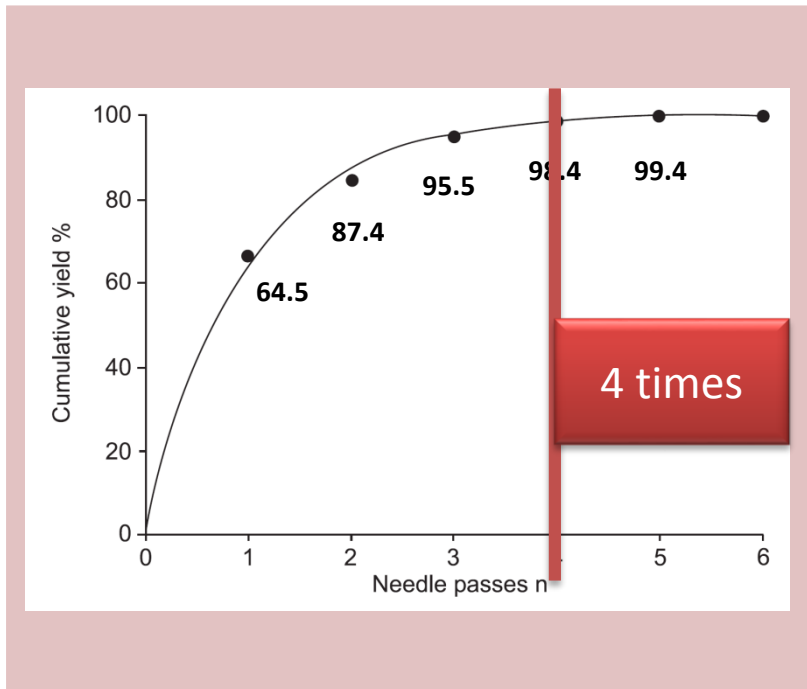
進行穿刺和  
細針活檢



移除穿刺針

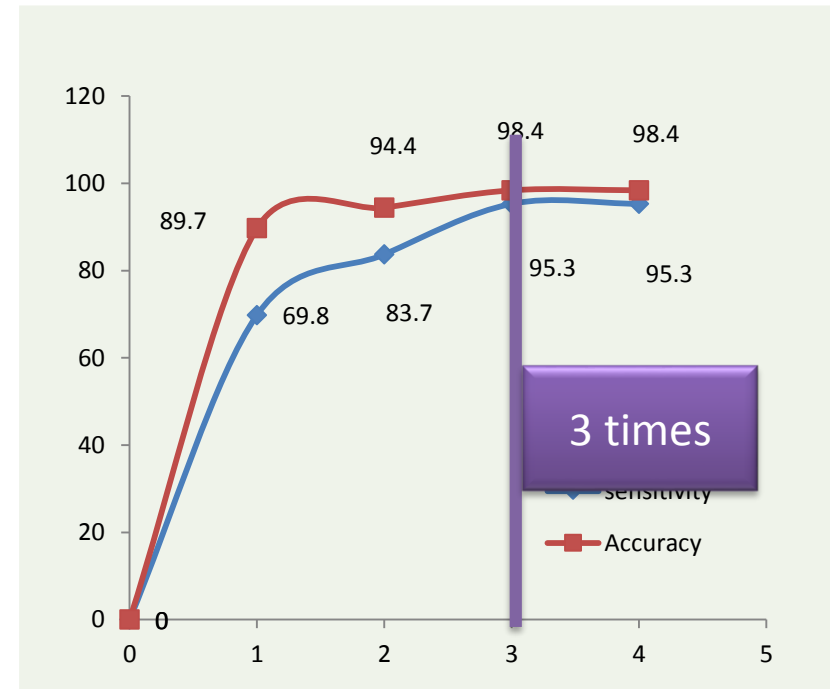


# TBNA: How many passes per target site?



Eur Respir J 2007; 29: 112–116

Transbronchial needle aspirates: how many passes per target site?

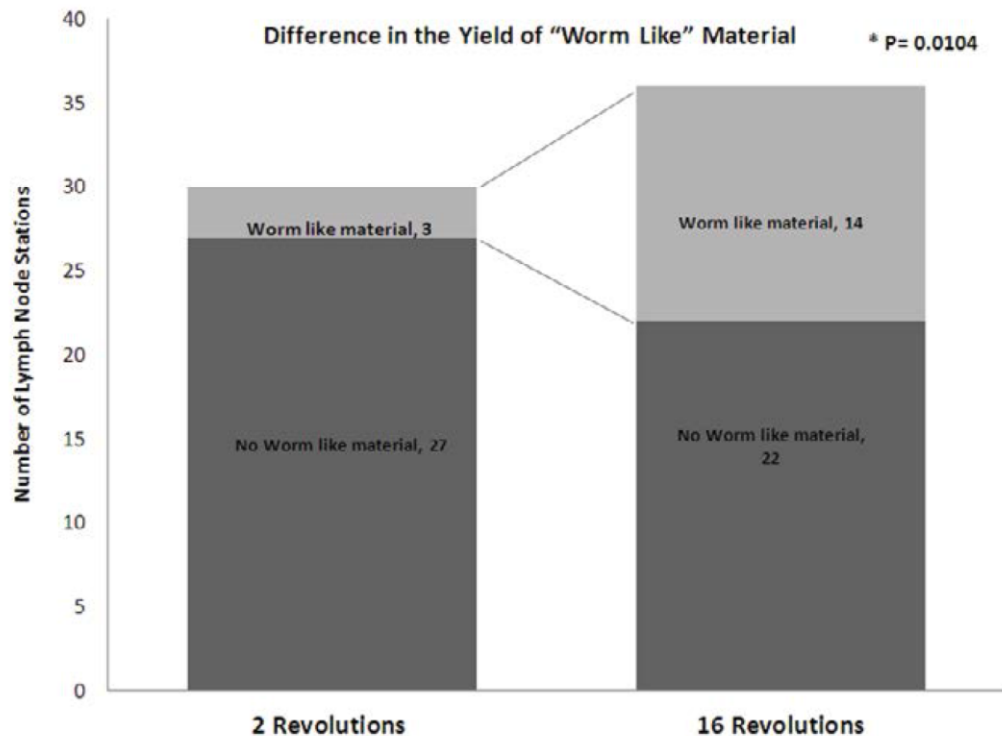


**CHEST 2008; 134:368–374**

**Real-time Endobronchial  
Ultrasound-Guided Transbronchial  
Needle Aspiration in Mediastinal Staging  
of Non-Small Cell Lung Cancer\***  
How Many Aspirations Per Target Lymph Node  
Station?

# How many back and forth movement of the needle passes per lymph node?

EBUS-TBNA: Are Two Needle Revolutions (Back and Forth Movement of the Needle Inside the Lymph Node) Adequate for Diagnosis of Lung Cancer?



**Figure 4:** Although the worm like string of core tissue was obtained significantly more frequently with 16 revolutions ( $P=0.0104$ ) as compared to two, this did not influence the diagnosis detection rate in case of malignancy.

- **Standard procedure : 建議插10-20次**
- 當進針至Lymph node時，插2次與插16次，診斷率相近
- 插16次可以取得worm-like specimen的機會比較高
- 需要比較多的組織，或是benign的病灶，建議插15-20次
- 只要staging的病人，可以插2次



# TBNA: with and without aspiration?

## Randomized Clinical Trial of Endobronchial Ultrasound Needle Biopsy With and Without Aspiration

**Conclusions:** Regardless of LN size, no differences in adequacy, diagnosis, or quality were found between samples obtained using EBUS-TBNA and those obtained using EBUS-TBNCS. **There is no evidence of any benefit derived from the practice of applying suction to EBUS-guided biopsies.**

- 有沒有使用negative suction對診斷沒有影響
- 有使用negative suction可能可以得到較大的組織
- 但使用negative suction可能會增加血液的contamination，使診斷困難度提高
- 血流量較高的組織，若要使用negative suction，建議negative pressure可以改為5或10ml，使得抽吸到的血液減少。

固定鞘管的  
位置



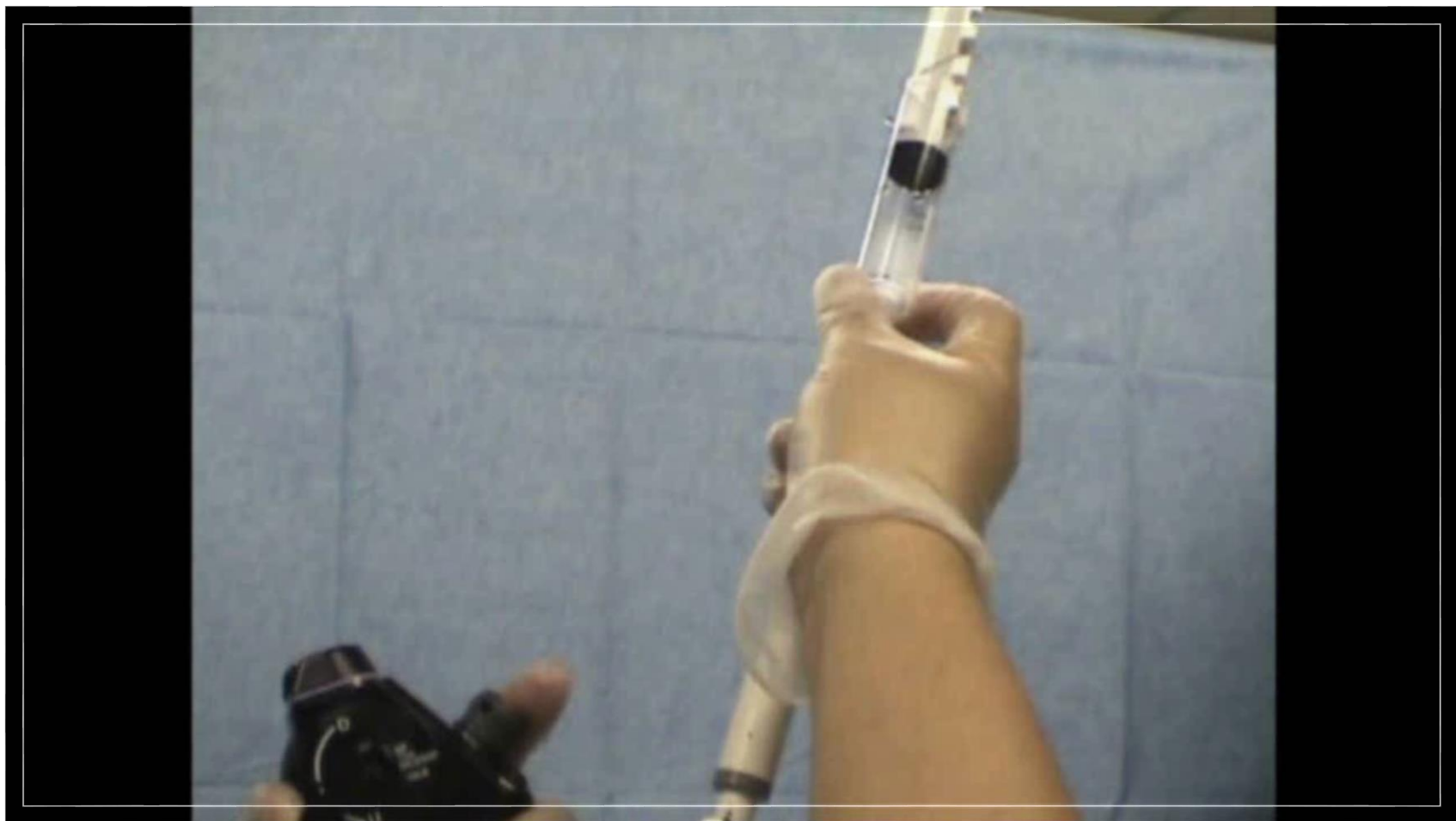決定穿刺路  
徑



進行穿刺和  
細針活檢



移除穿刺針



EBUS-TBNA操作介紹

# SPECIMEN MANAGEMENT



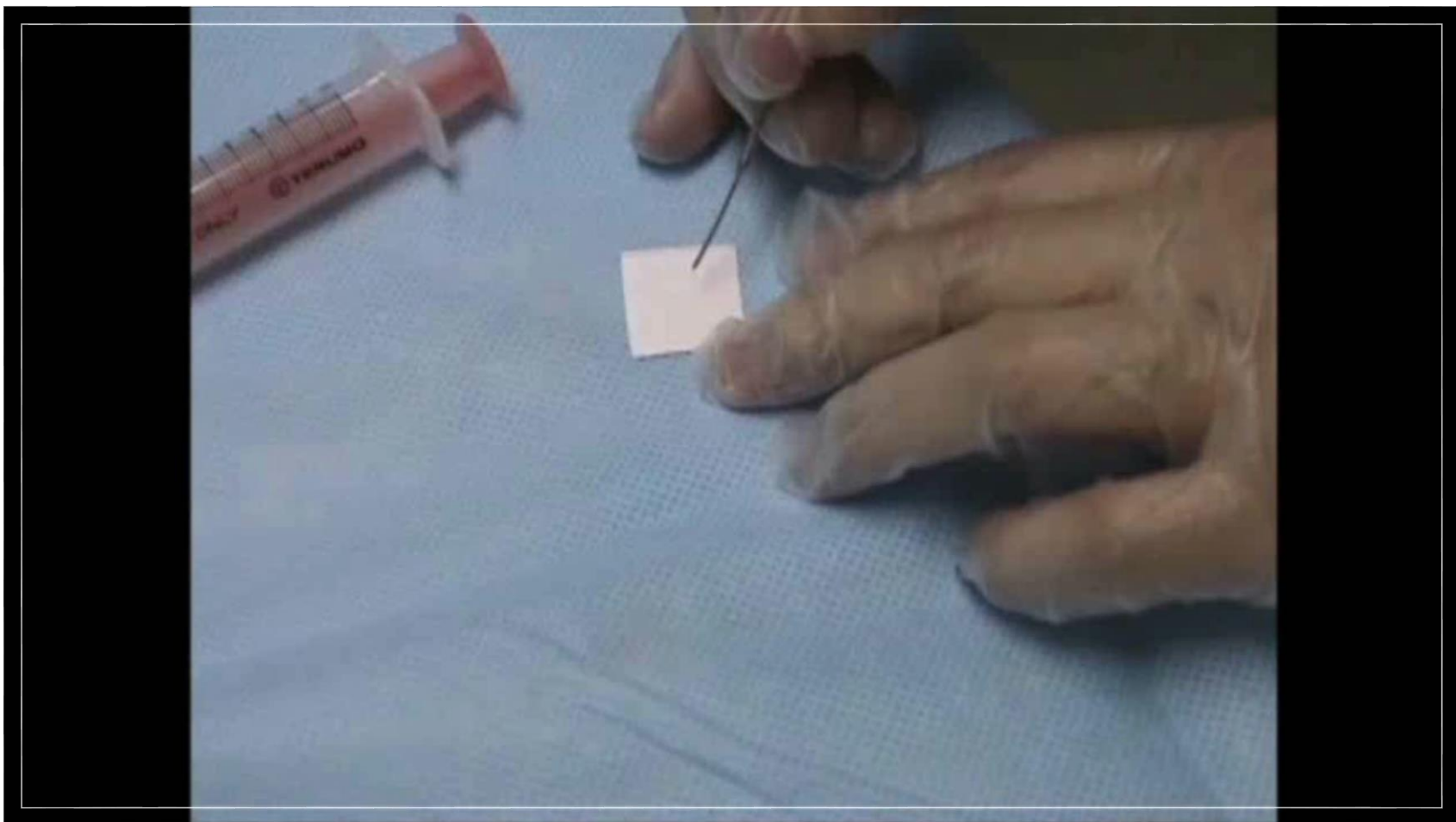檢體取出



病理學檢查



細胞學檢查



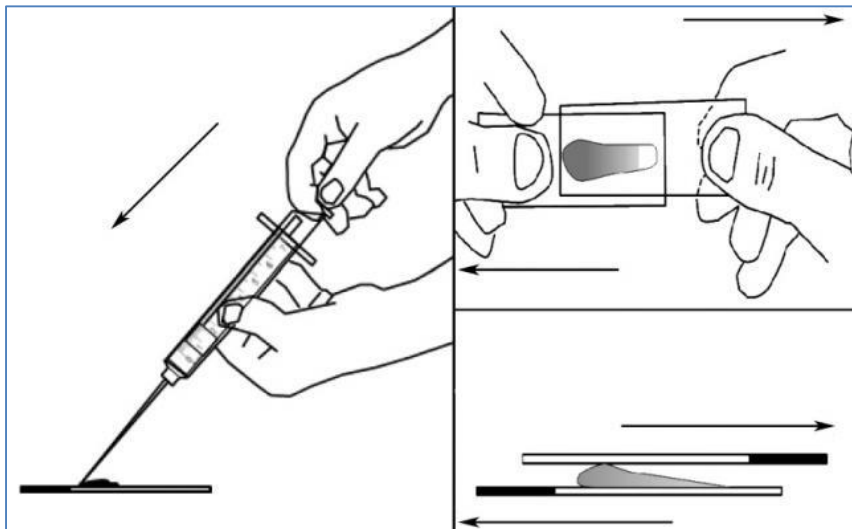
檢體取出



病理學檢查



細胞學檢查



- 在收集組織後，使用空針筒，以正壓的方式，將穿刺針內的標本打出到載玻片上，迅速固定以進行病理細胞學檢查。



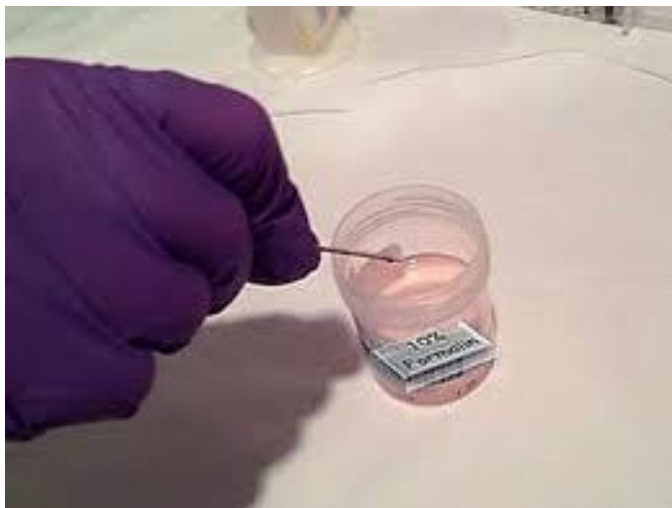檢體取出



病理學檢查



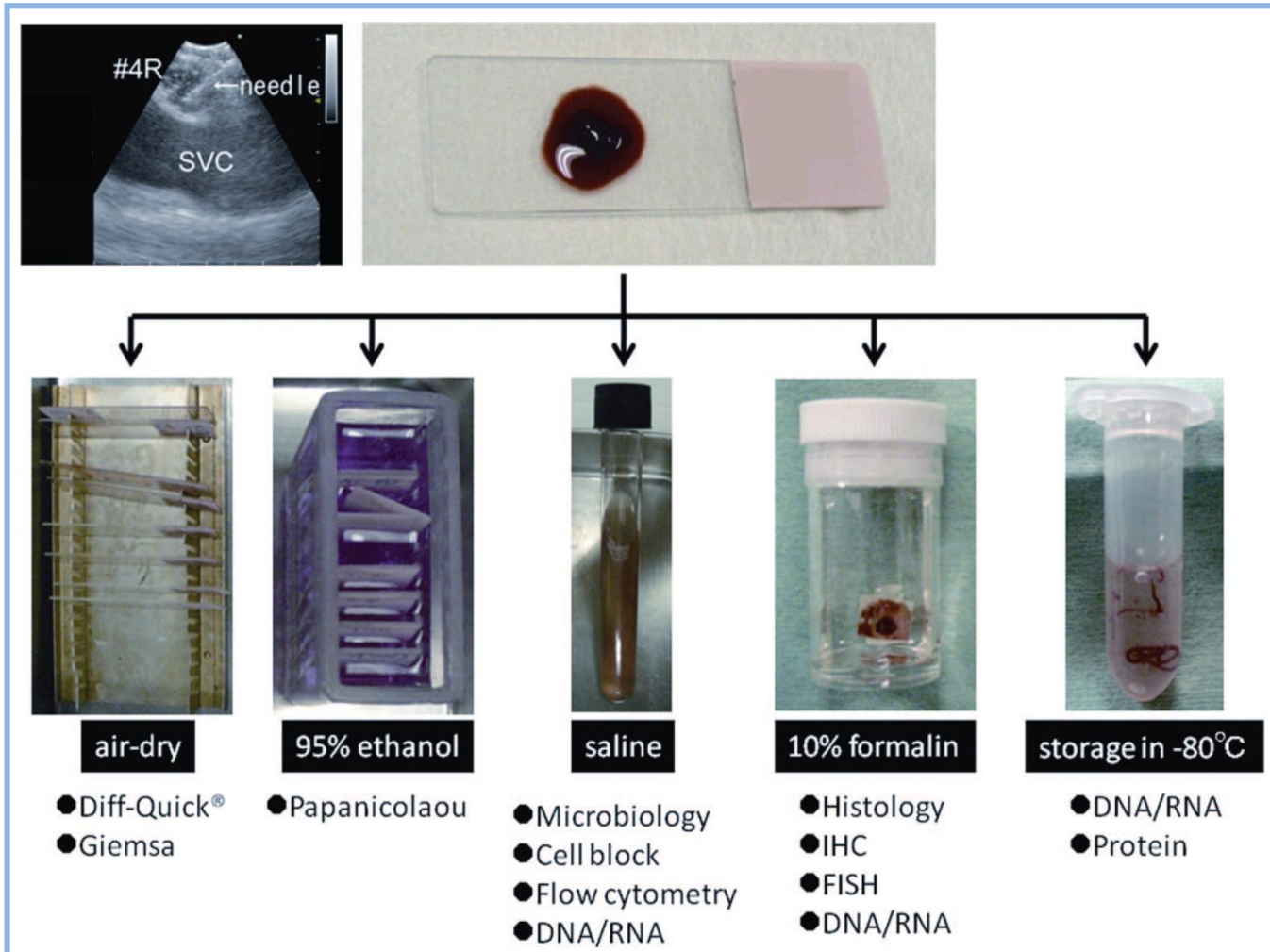
細胞學檢查



- 使用針筒打約略3ml生理食鹽水來清洗穿刺針空腔，將每次清洗的溶液一起收集好，進行細胞學檢查以及細菌學檢查。



# Specimen management



## EBUS-TBNA操作介紹

# CONVEX PROBE EBUS

WHAT'S BENEFIT FROM  
EBUS-TBNA



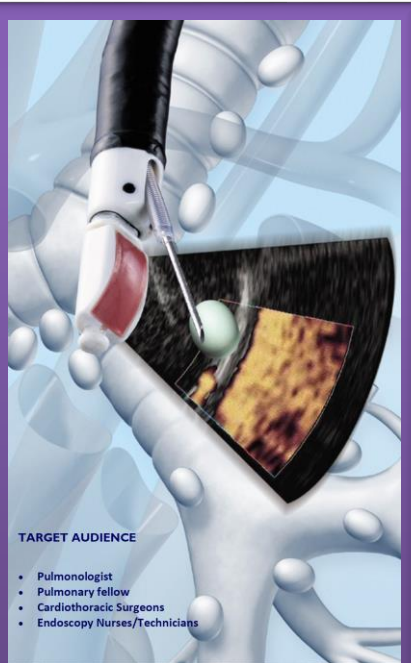
# Role of EBUS-TBNA

Lymph node staging in lung cancer patients  
(saves patients from surgery)

Diagnosis of intrapulmonary tumors

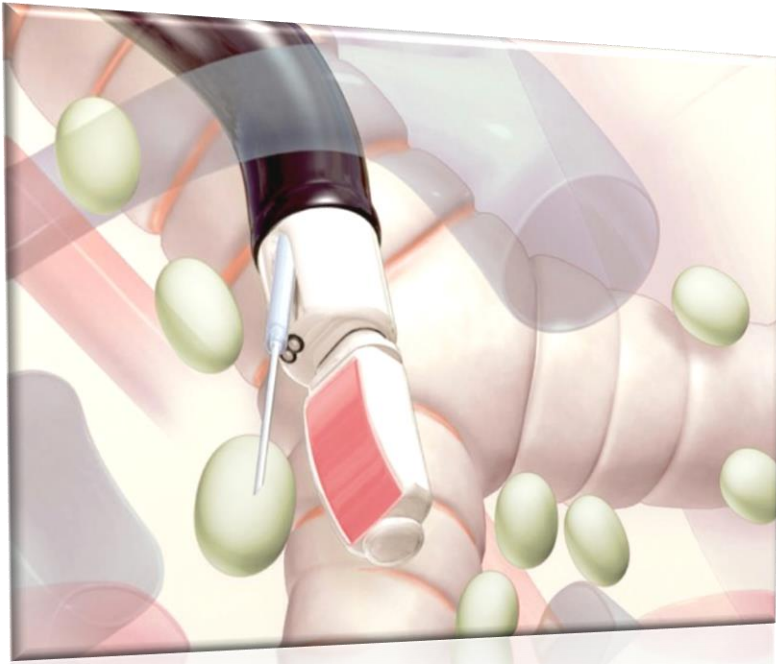
Diagnosis of unknown hilar and/or mediastinal  
lymphadenopathy

For mediastinal LAP EGFR mutation test



**TARGET AUDIENCE**

- Pulmonologist
- Pulmonary fellow
- Cardiothoracic Surgeons
- Endoscopy Nurses/Technicians



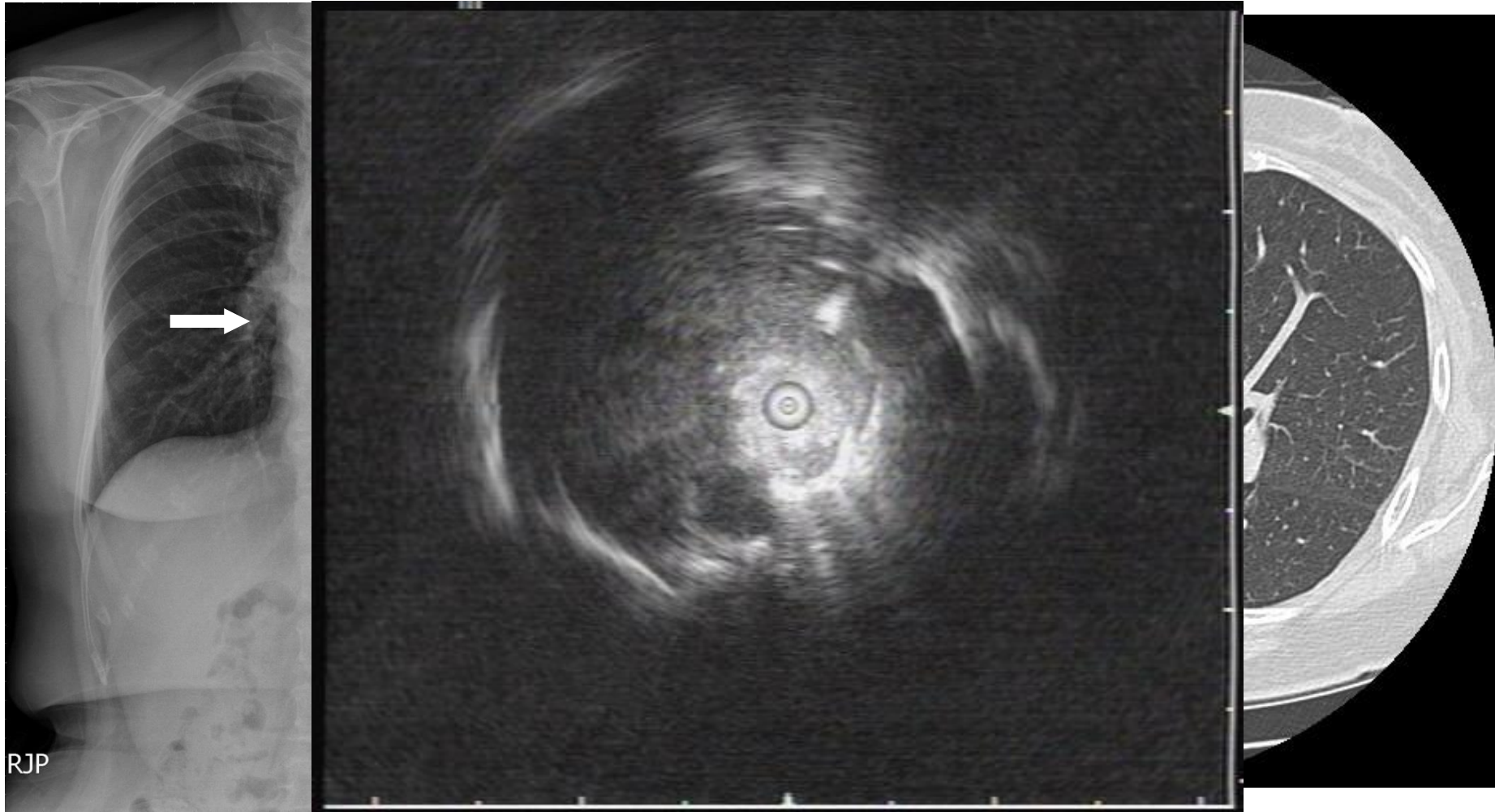
**Diagnose lung cancer who  
cannot approach in radial  
EBUS**





# Liner EBUS in diagnosing lung cancer who cannot approach in radial EBUS

---



# Liner EBUS in diagnosing lung cancer who cannot approach in radial EBUS

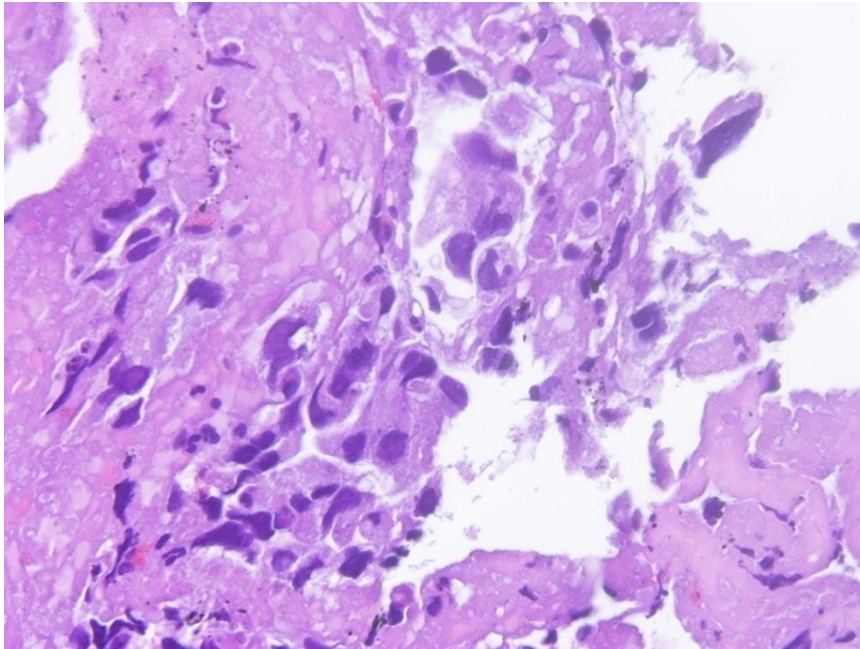


**Histology: adenoCA**

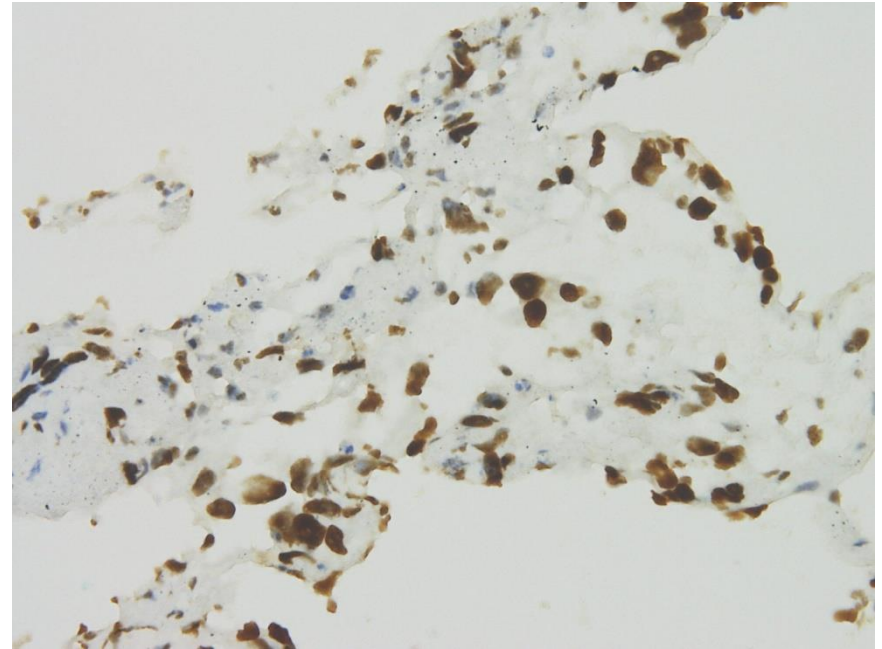


# Liner EBUS in diagnosing lung cancer who cannot approach in radial EBUS

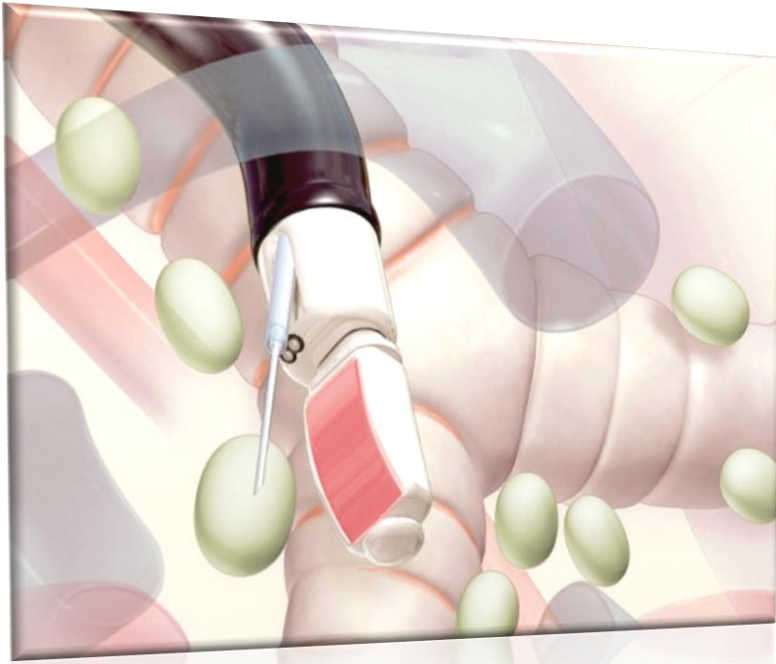
---



**Adenocarcinoma**



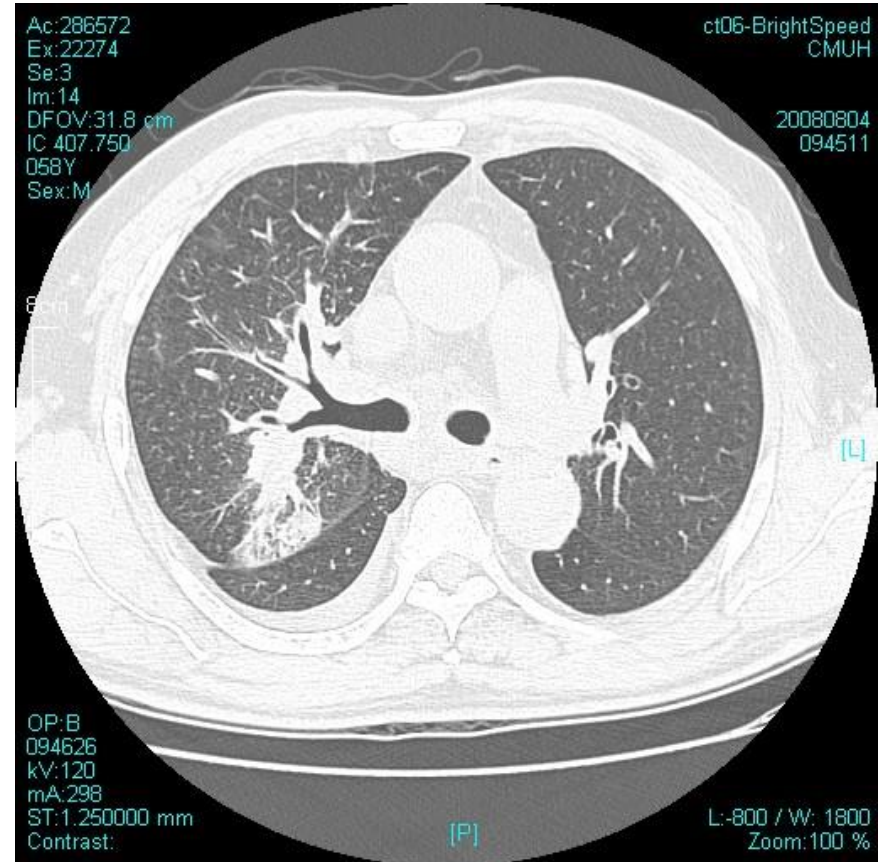
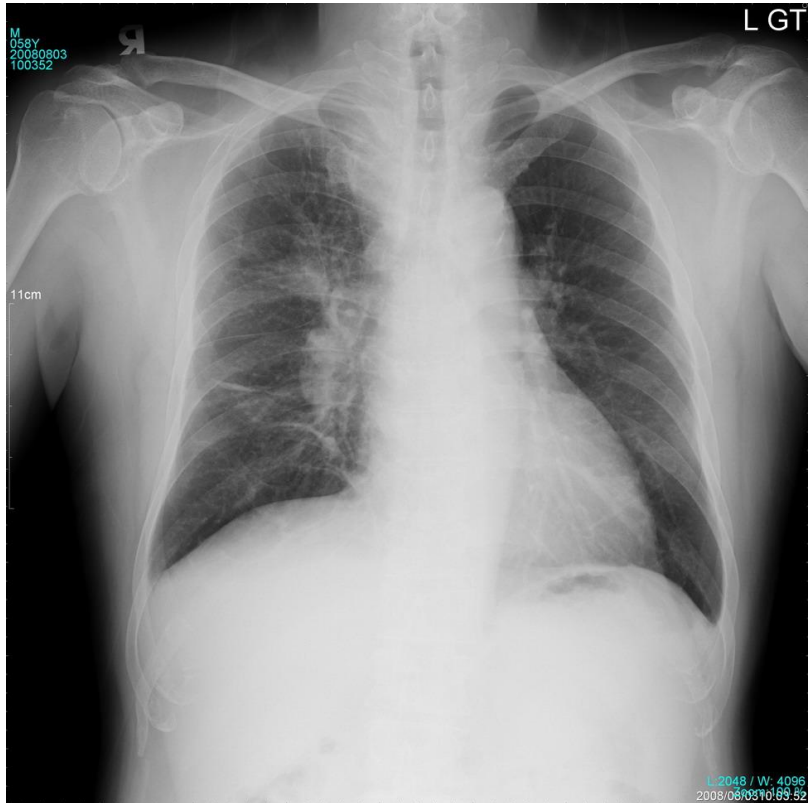
**TTF-1 stain**



## Para-airway Lesions

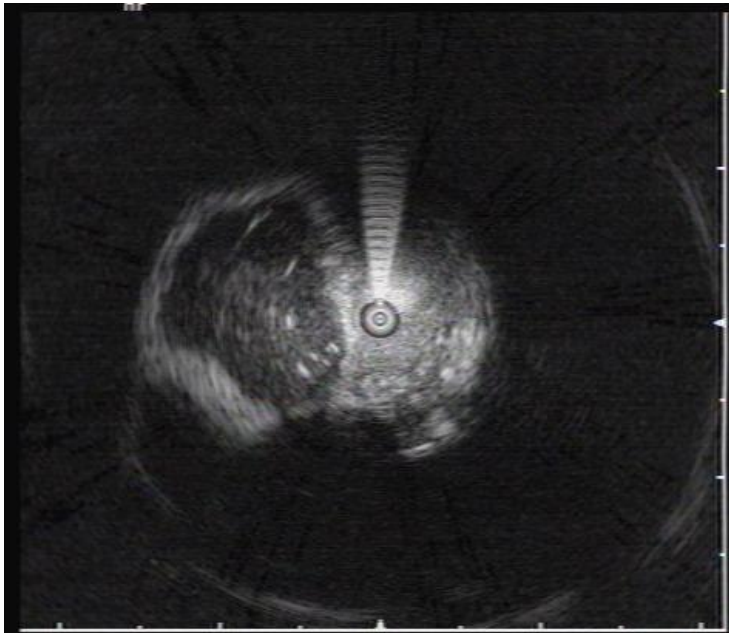


# Case Present (1)

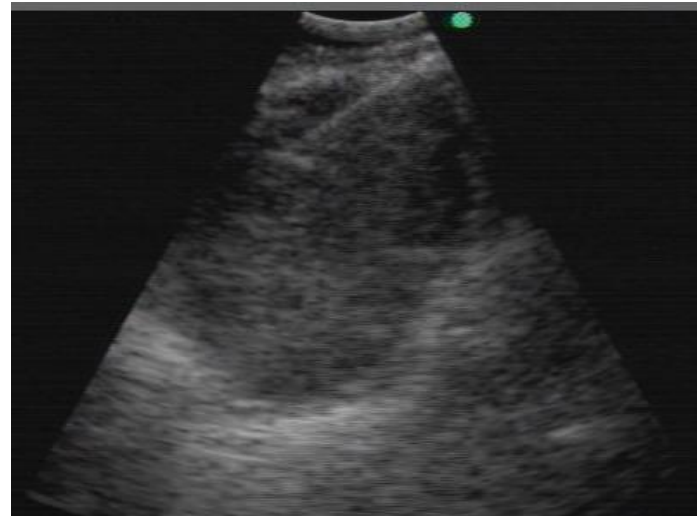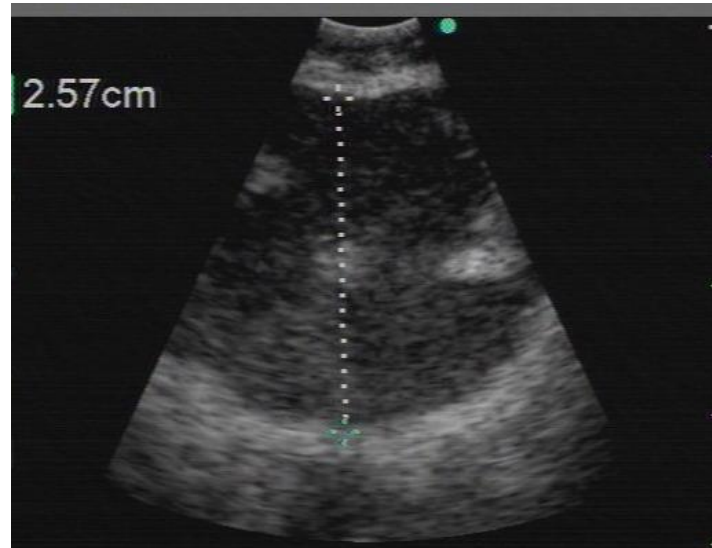




# Case Present (1)



Radial probe

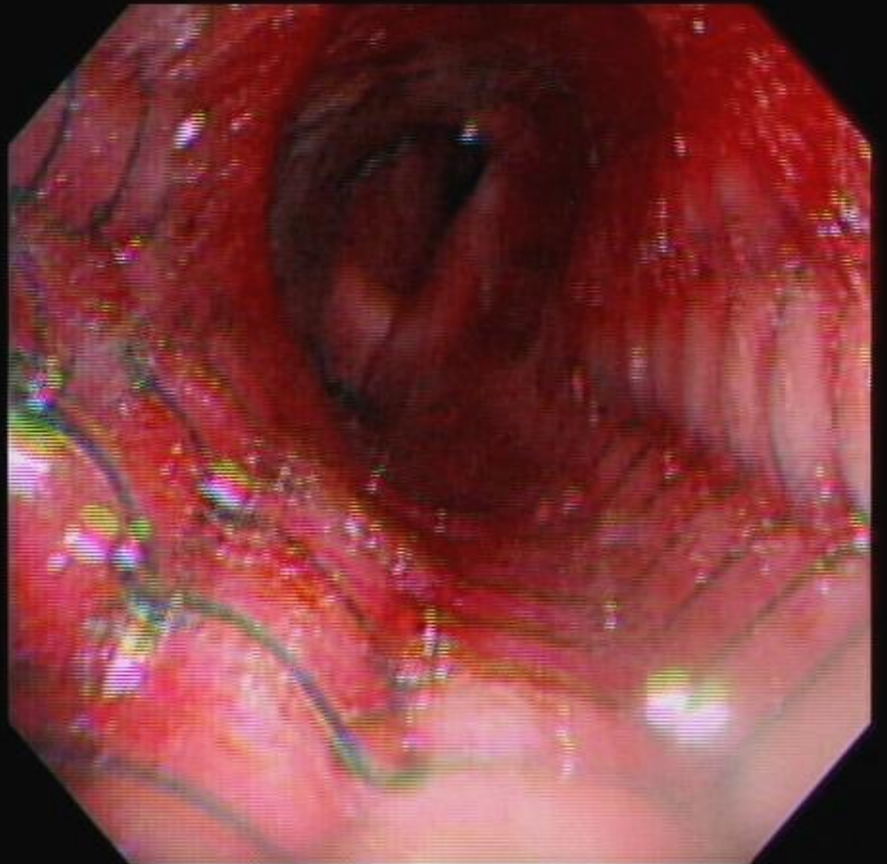
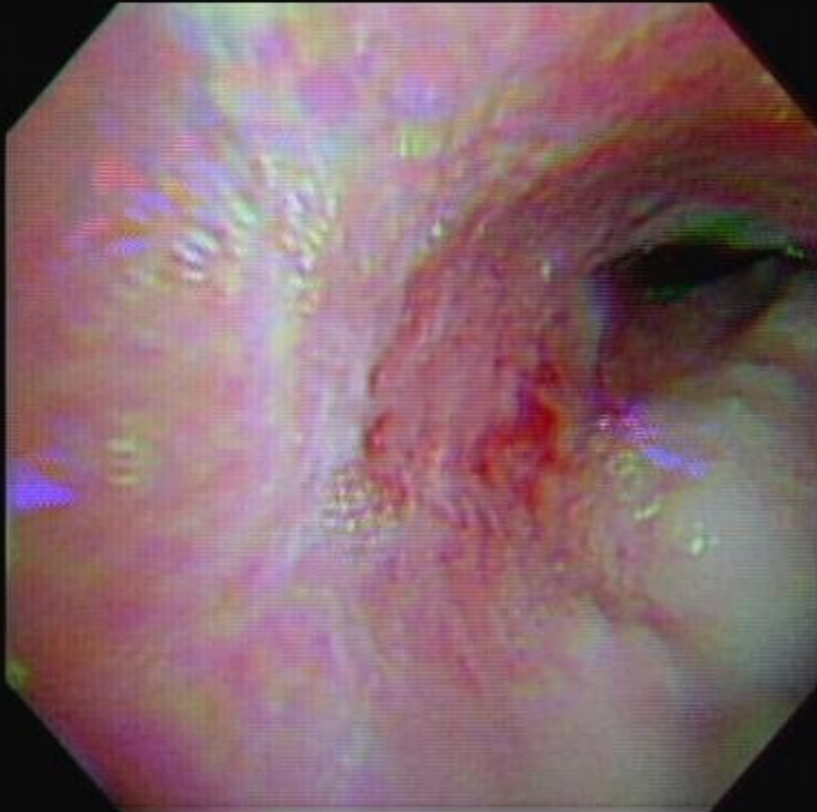


Convex  
EBUS

Endobronchial

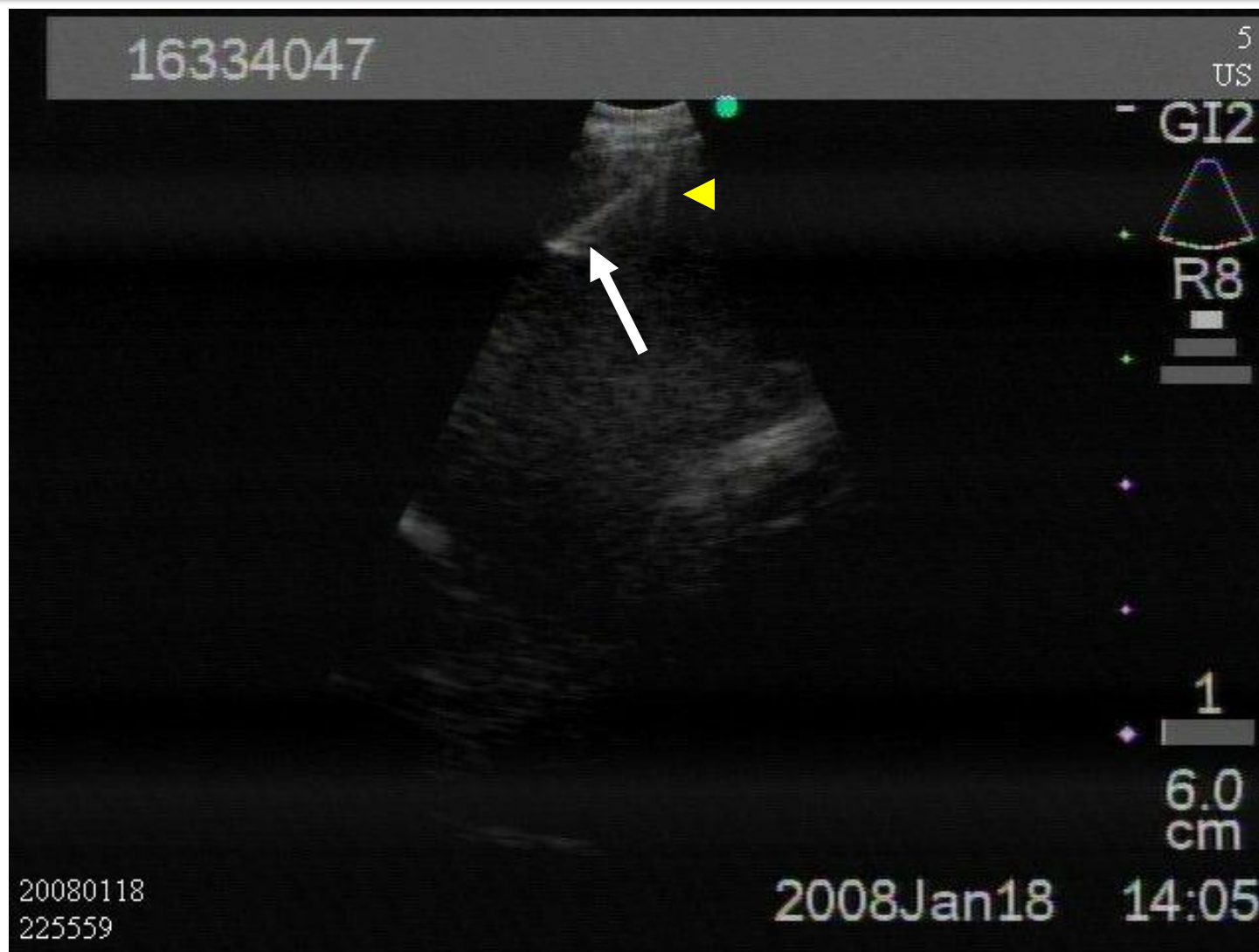
U  
T  
A  
O  
W  
A  
S

Name :

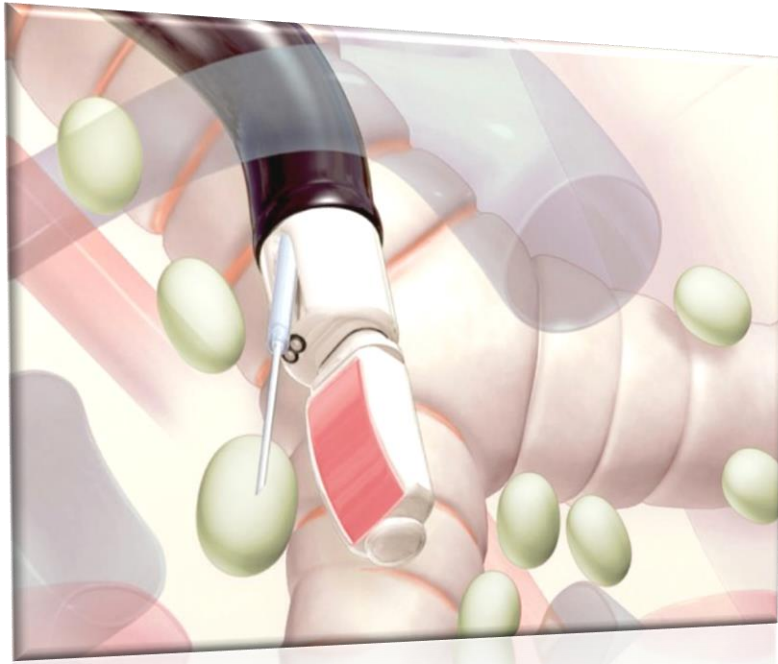


China Medical University Hospital  
Taichung, Taiwan

# Endobronchial ultrasound-guided transbronchial needle aspiration for diagnosis of a mediastinum mass with severe central airway obstruction after stenting





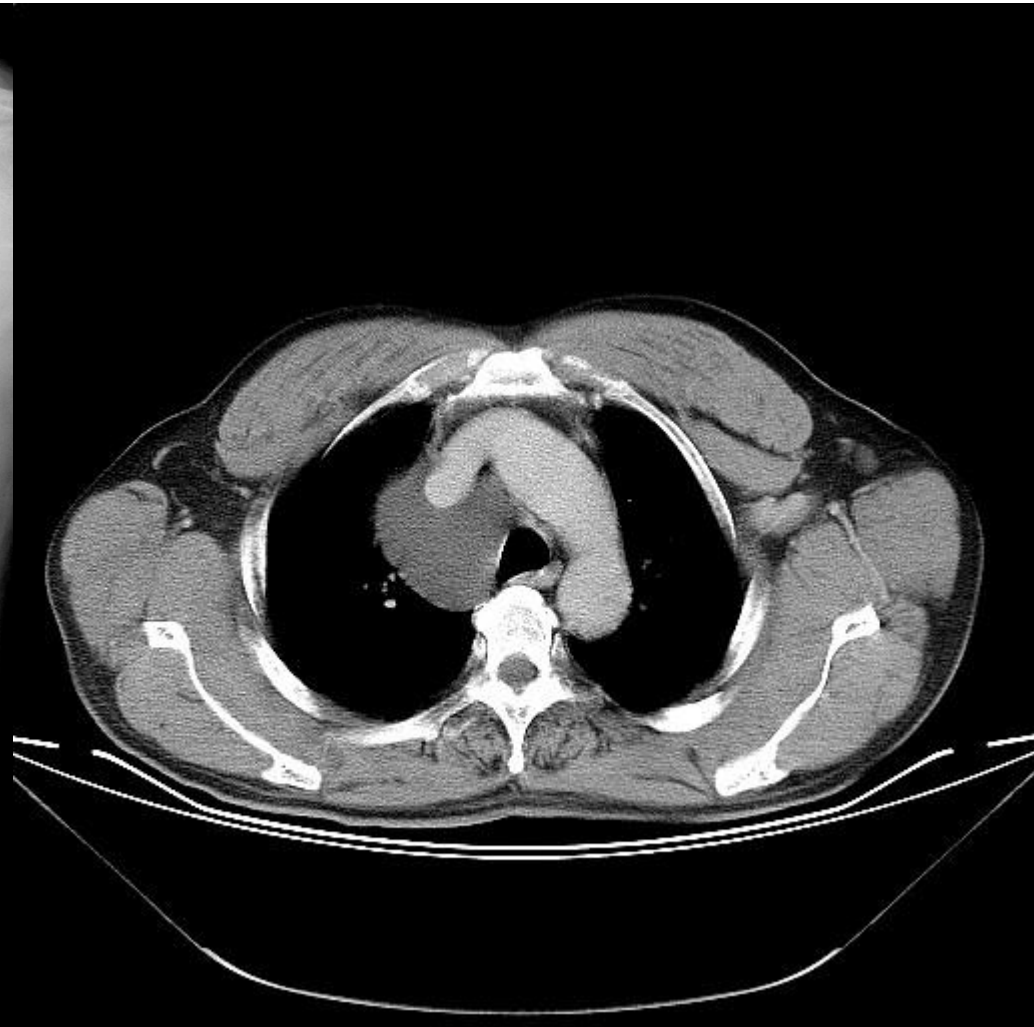
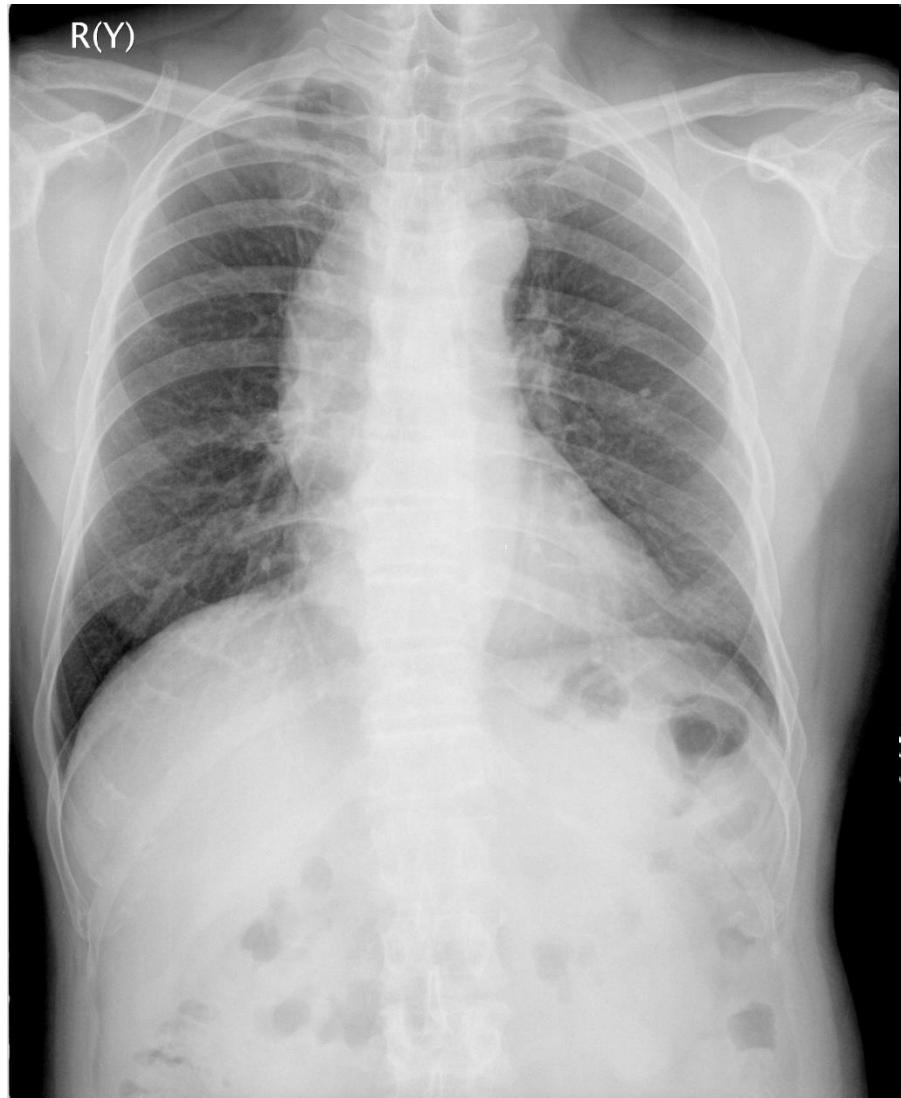


**Treat bronchogenic cyst**



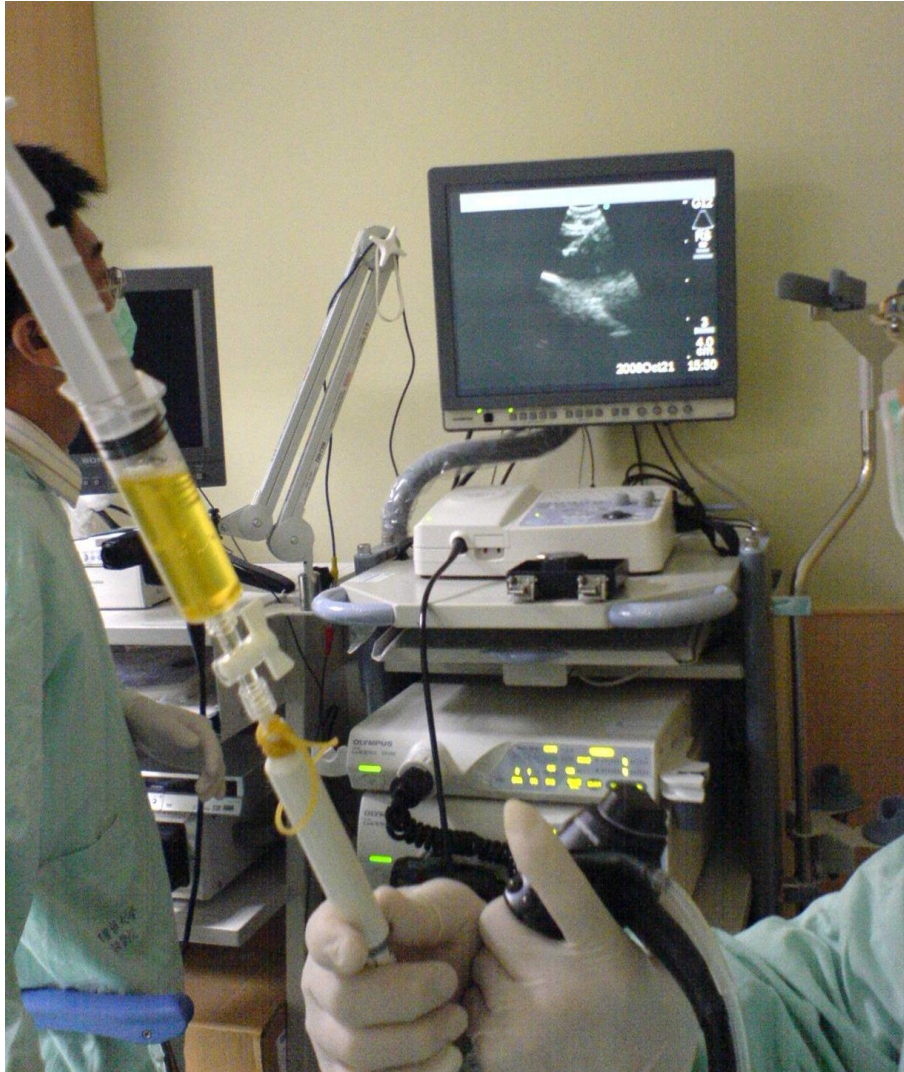# Bronchogenic cyst treated with EBUS-TBNA

---



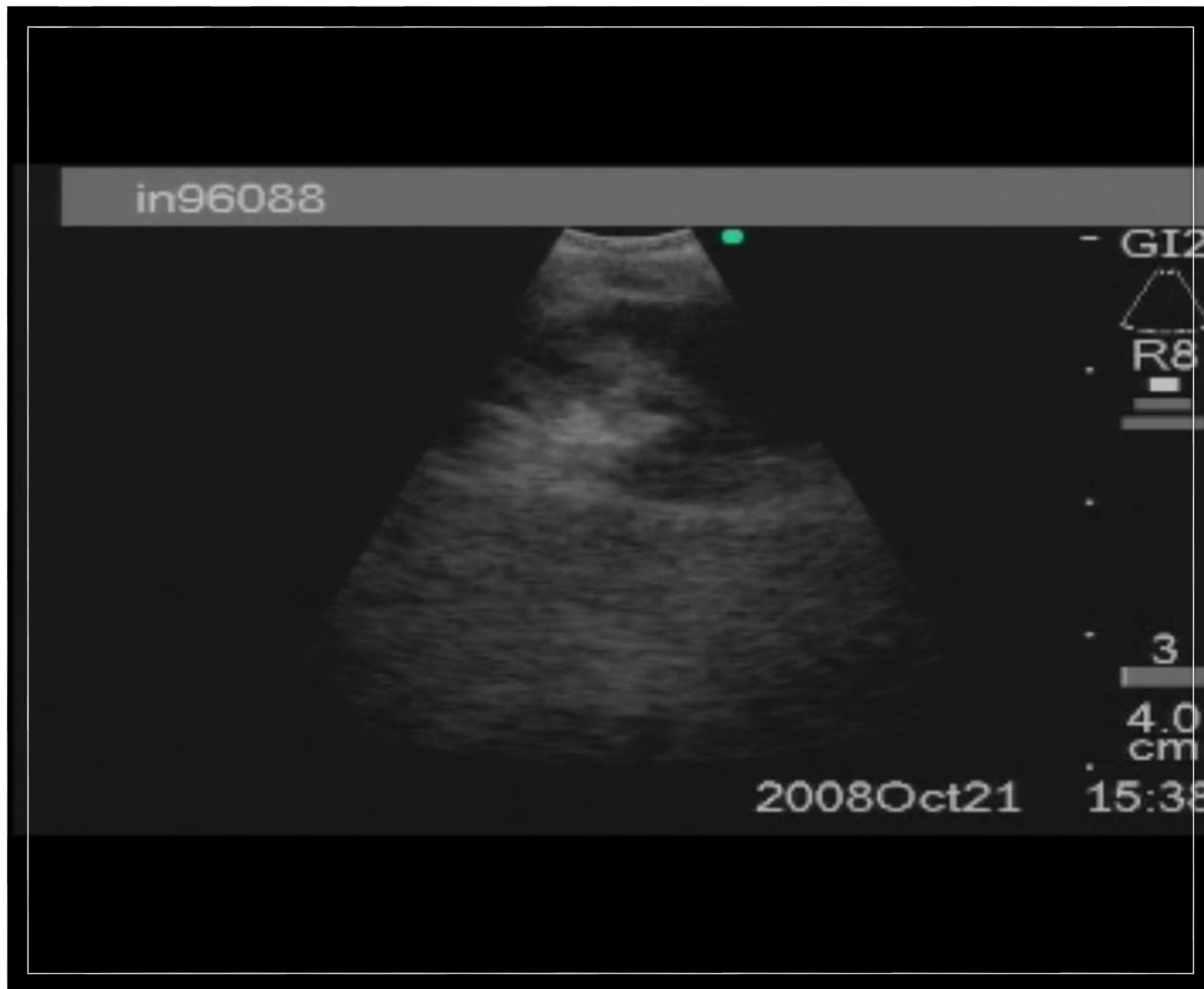


# Bronchogenic cyst treated with EBUS-TBNA



# Bronchogenic cyst treated with EBUS-TBNA

---



## EBUS and EBUS-TBNA

# CONVEX PROBE EBUS

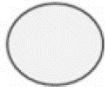
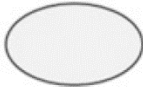
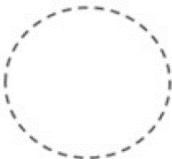

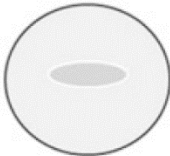
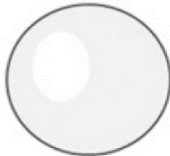






WHAT'S BENEFIT FROM  
EBUS-TBNA

IMAGE IN LUNG LESION





# The Utility of Sonographic Features During Endobronchial Ultrasound-Guided Transbronchial Needle Aspiration for Lymph Node Staging in Patients With Lung Cancer

Size	Shape	Margin	Ecogeneity	Central Hilar Structure	Coagulation Necrosis Sign
 (a) $\leq 1\text{cm}$	 (c) oval	 (e) indistinct	 (g) homogeneous	 (i) present	 (k) present
 (b) $>1\text{cm}$	 (d) round	 (f) distinct	 (h) heterogeneous	 (j) absent	 (l) absent

# The Utility of Sonographic Features During Endobronchial Ultrasound-Guided Transbronchial Needle Aspiration for Lymph Node Staging in Patients With Lung Cancer

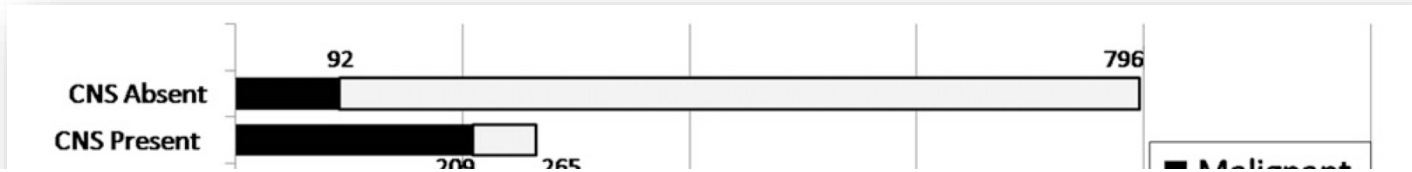
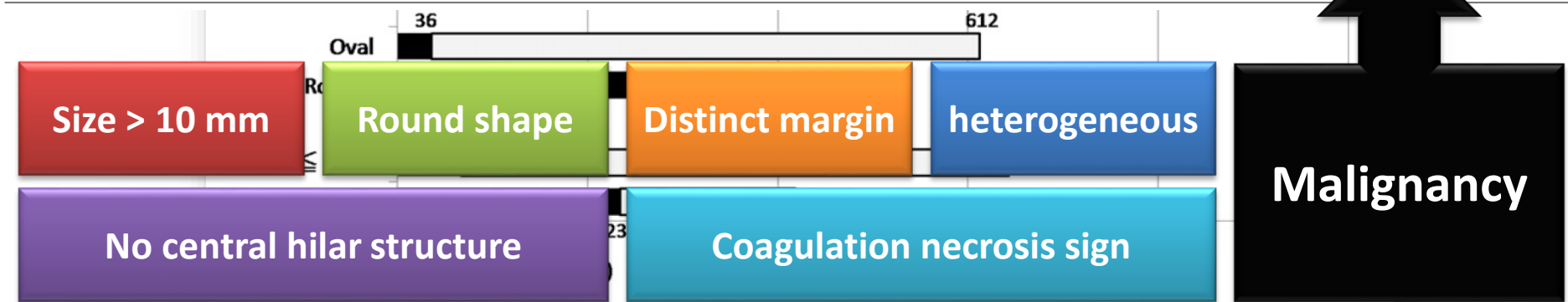


Table 3—Diagnostic Yield of Each Endobronchial Ultrasound Image Category for Metastatic Lymph Node

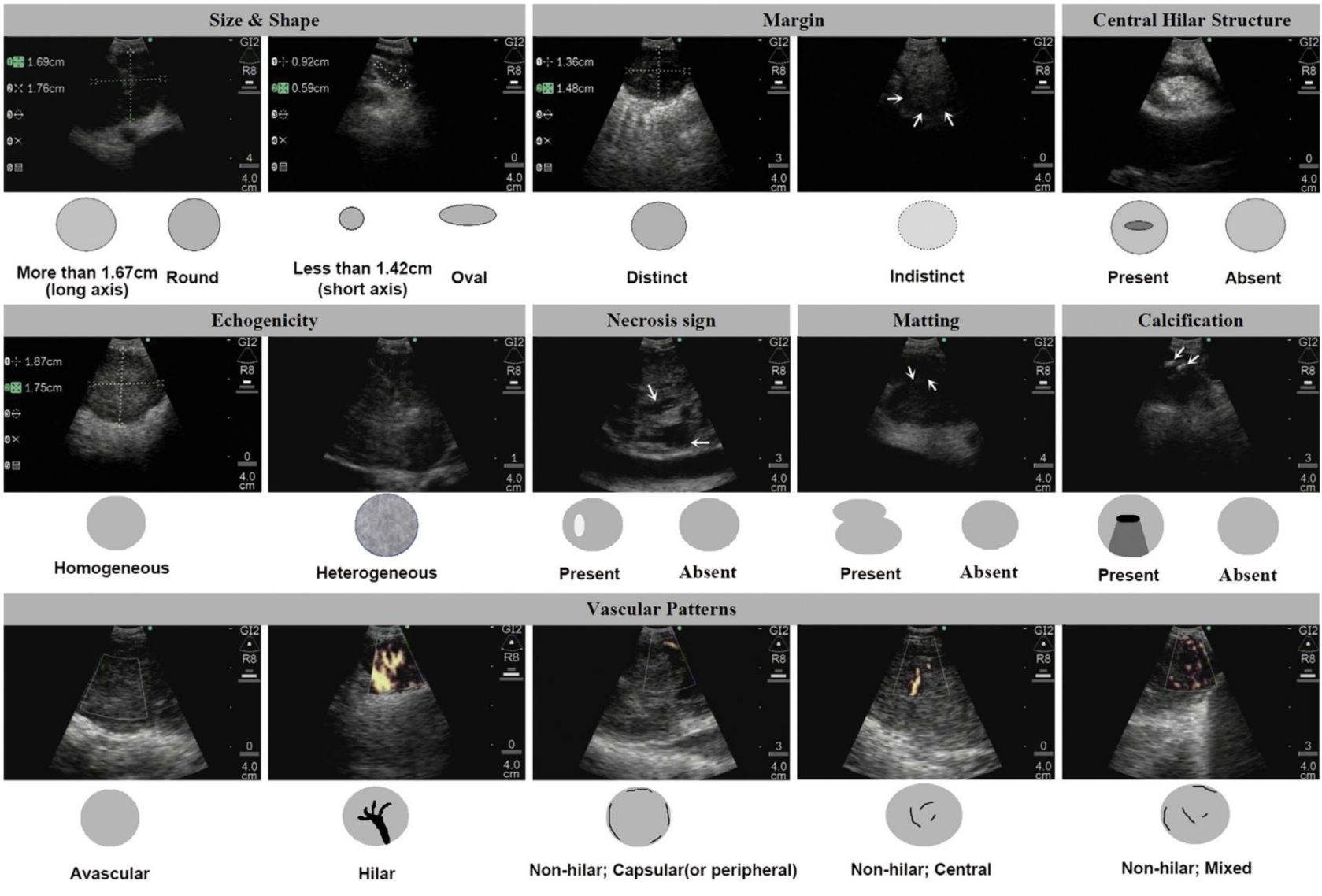
Morphologic Category	Sensitivity	Specificity	Positive Predictive Value	Negative Predictive Value	Diagnosis Accuracy
Size: > 10 mm	77.9	75.8	55.9	89.7	76.4
Shape: round	88.0	75.8	59.0	94.1	79.3
Margin: distinct	94.4	54.3	45.5	96.0	65.7
Echogenicity: heterogeneous	77.3	86.6	69.5	90.6	83.9
Central hilar structure: absence	89.7	53.5	43.3	92.9	63.8
Coagulation necrosis sign: presence	69.4	92.6	78.9	88.4	86.0



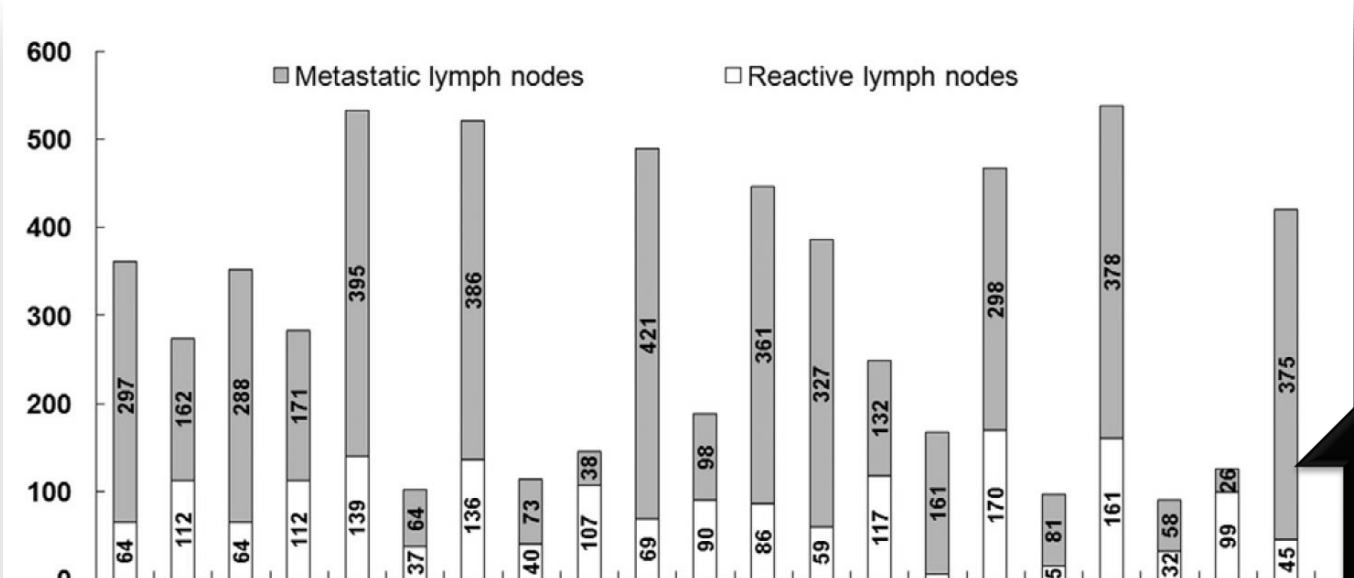


# Sonographic Features of Endobronchial Ultrasonography Predict Intrathoracic Lymph Node Metastasis in Lung Cancer Patients

Ann Thorac Surg 2015;■:■-■



# Sonographic Features of Endobronchial Ultrasonography Predict Intrathoracic Lymph Node Metastasis in Lung Cancer Patients



Size > 15 mm

Round shape

Distinct margin

heterogeneous

No central hilar structure

Coagulation necrosis sign

**Malignancy**

With matting

No calcification

No hilar vascular

# Sonographic Features of Endobronchial Ultrasonography Predict Intrathoracic Lymph Node Metastasis in Lung Cancer Patients

Lei Wang, MD, Weihua Wu, MD, Yunqian Hu, MD, Jiajun Teng, MD, Runbo Zhong, MD, Baohui Han, MD, PhD, and Jiayuan Sun, MD, PhD

Departments of Ultrasound, Pulmonary Medicine, and Endoscopy and Pulmonary Medicine, Shanghai Chest Hospital, Shanghai Jiaotong University; and Department of Respiration, Shanghai East Hospital, Shanghai Tongji University, Shanghai, China

*Table 4. Diagnostic Test Parameters and Exact 95% Confidence Intervals for Score System to Predict Lymph Node Metastasis Based on Odds Ratio*

EBUS Characteristics	Sensitivity	Specificity	PPV	NPV	Diagnostic Accuracy
Shape: round	86.06%	21.02%	73.97%	36.63%	68.03%
Matting: presence	35.08%	96.59%	96.41%	36.32%	52.13%
CHS: absence	91.72%	60.80%	85.92%	73.79%	83.15%
Nonhilar perfusion	81.70%	74.43%	89.29%	60.93%	79.69%
Sonographic features <sup>a</sup>					
0	1.53%	84.66%	20.59%	24.79%	24.57%
1+	98.47%	15.34%	75.21%	79.41%	75.43%
2+	93.03%	55.68%	84.55%	75.38%	82.68%
3+	76.69%	84.66%	92.88%	58.20%	78.90%
4	26.36%	97.16%	96.03%	33.60%	45.98%

<sup>a</sup> Sonographic features satisfy none (0) or at least one (1+), two (2+), three (3+), or four (4) of the four categories (round shape, presence of matting, absence of central hilar structure [CHS], nonhilar perfusion) based on the odds ratio.

CHS = central hilar structure; NPV = negative predictive value; PPV = positive predictive value.

## EBUS and EBUS-TBNA

# CONVEX PROBE EBUS

WHAT'S BENEFIT FROM  
EBUS-TBNA

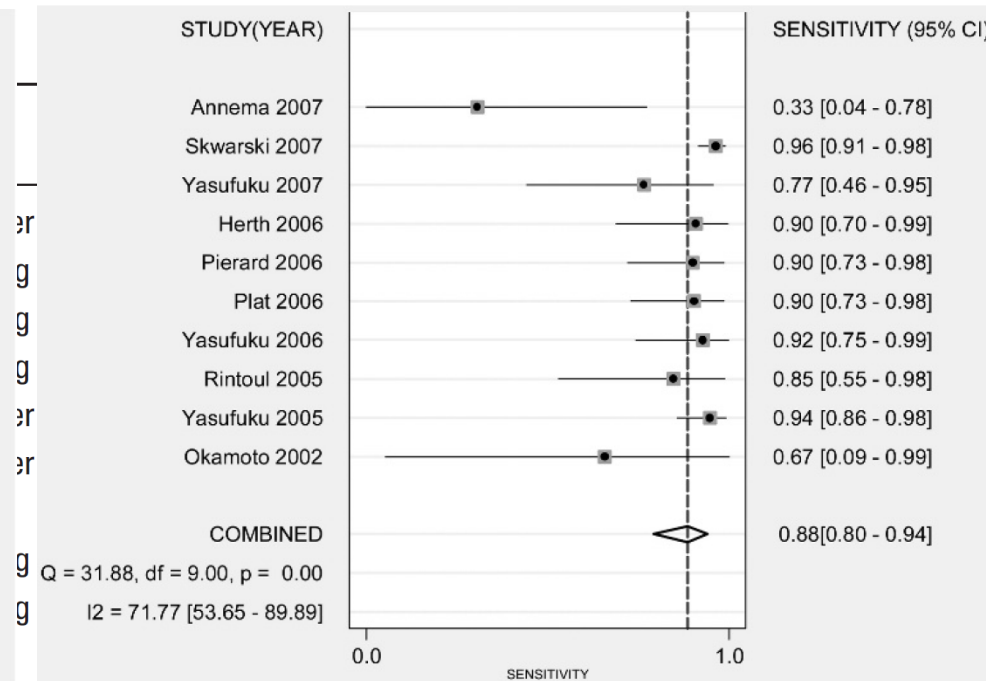
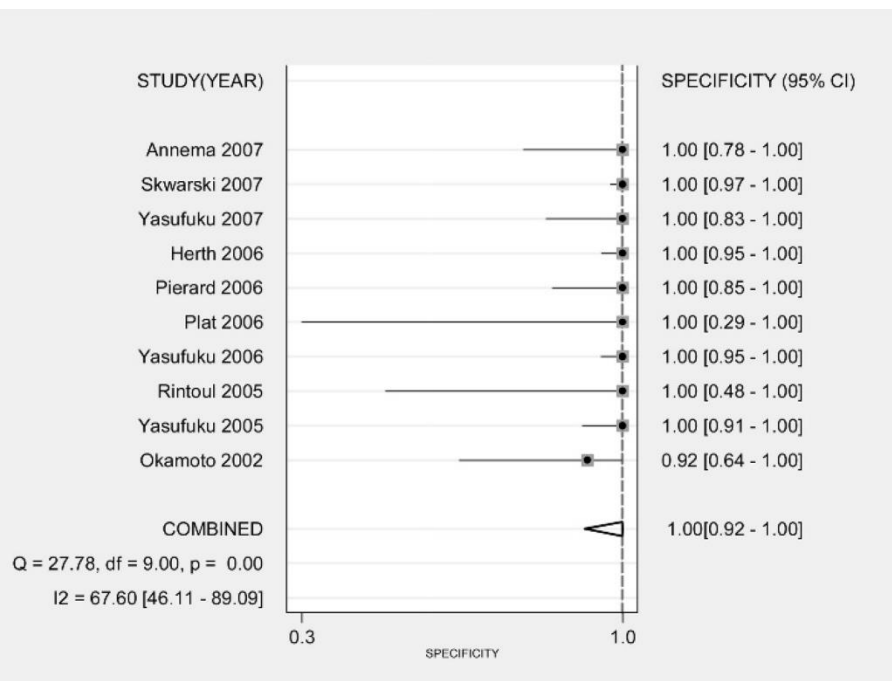
IMAGE IN LUNG LESION

DIAGNOSE LYMPH  
NODE LESION

DIAGNOSE  
YIELD



# Test performance of endobronchial ultrasound and transbronchial needle aspiration biopsy for mediastinal staging in patients with lung cancer: systematic review and meta-analysis



ND, not described; NSCLC, non-small cell lung cancer; PET, positron emission tomography.

**Specificity = 1.00**

**Sensitivity = 0.88**



# Method Detect Nodal Metastasis meta-analysis

Method	Stations sampled	Patients included	Sensitivity	Specificity
CT <sup>22</sup>	N/A	5111	0.51 (0.47–0.54)	0.86 (0.84–0.88)
PET <sup>22</sup>	N/A	2865	0.74 (0.69–0.79)	0.85 (0.82–0.88)
TBNA <sup>20</sup>	2, 4, 7, 11	1339	0.78	0.99
TTNA <sup>20</sup>	Any accessible	215	0.89	1
EUS-FNA <sup>21</sup>	5–9	1201	0.83 (0.78–0.87)	0.97 (0.96–0.98)
EBUS-TBNA <sup>20</sup>	2–4, 7, 10–12	1339	0.78	0.99
Mediastinoscopy <sup>20</sup>	1–4, 7 (cervical) 5,6 (anterior), 8,9 (thoroscopic)	6505	0.78	1



## EBUS and EBUS-TBNA

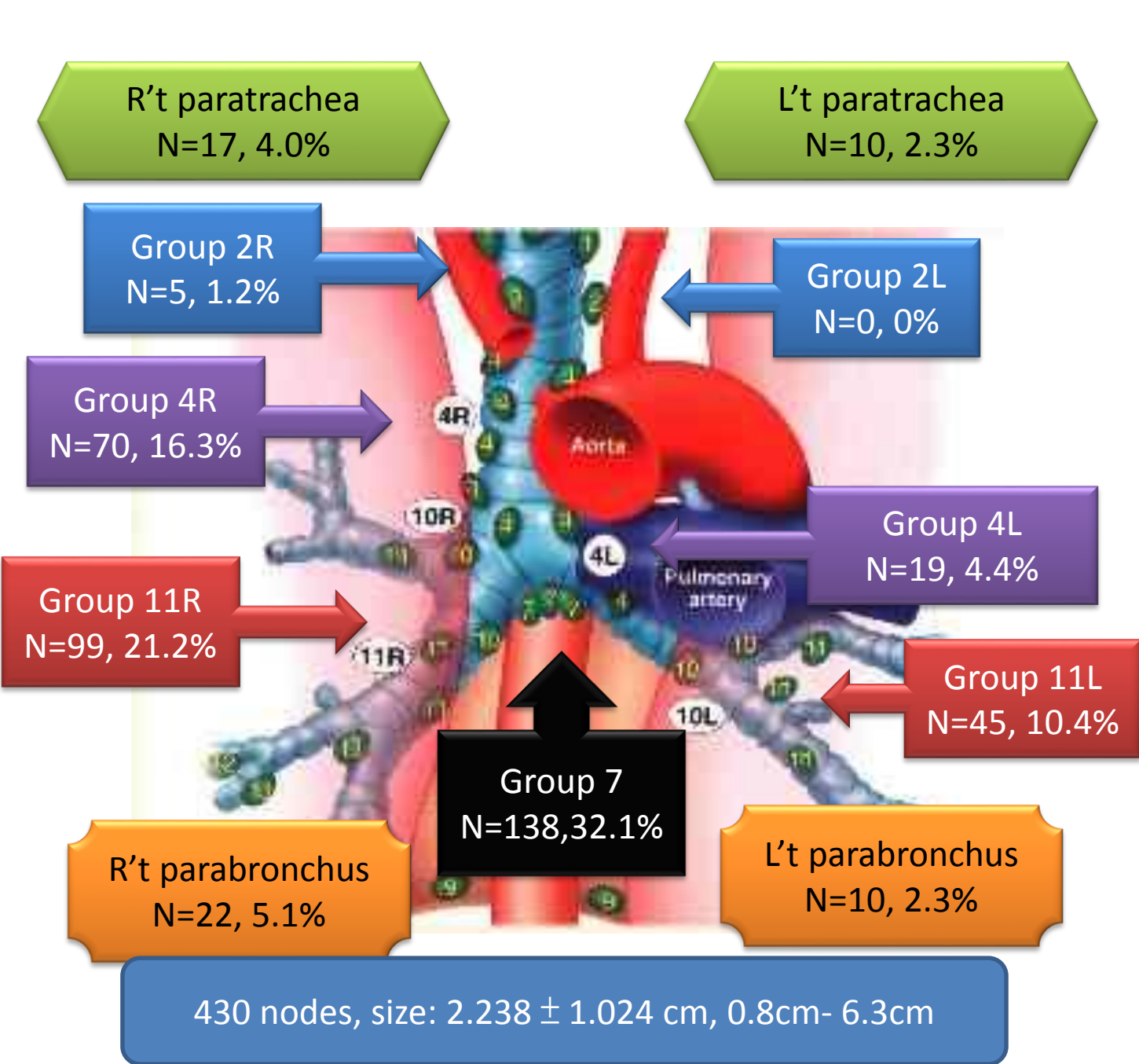
# CONVEX PROBE EBUS

IMAGE IN LUNG LESION

DIAGNOSE LYMPH  
NODE LESION

CMUH EXPERIENCE





0970101 to  
1031231

Total 317 patients,  
430 lesion

164 patients with  
one LAP

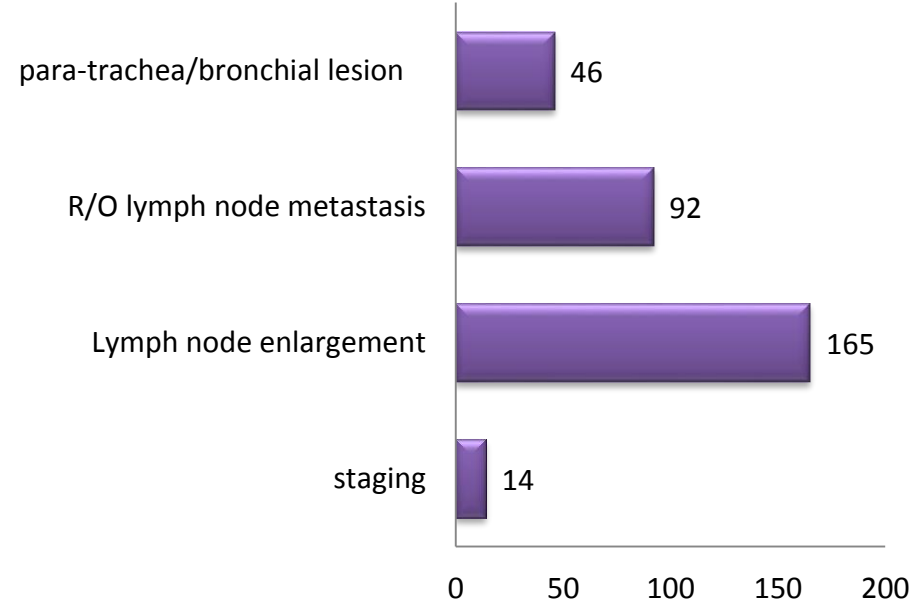
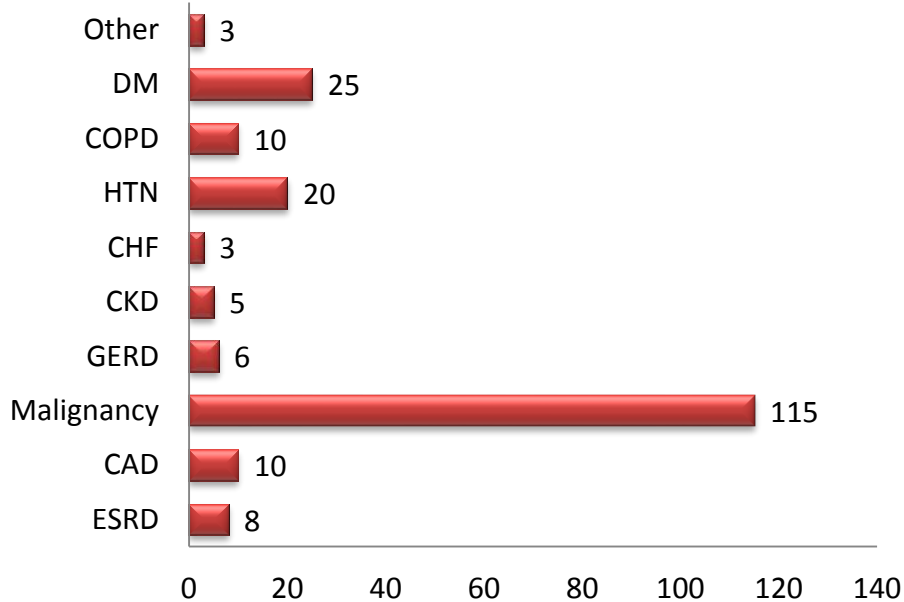
77 patients with  
>2 LAP

paratrachea  
lesion, n=27

parabronchial  
lesion, n=32

# EBUS-TBNA, n=317

EBUS-TBNA Patients, n=317	Characteristics
Age	59.40 ± 17.78 (17 y/o - 93 y/o)
<b>Sex</b>	
male	213, 67.2%
female	104, 32.8%



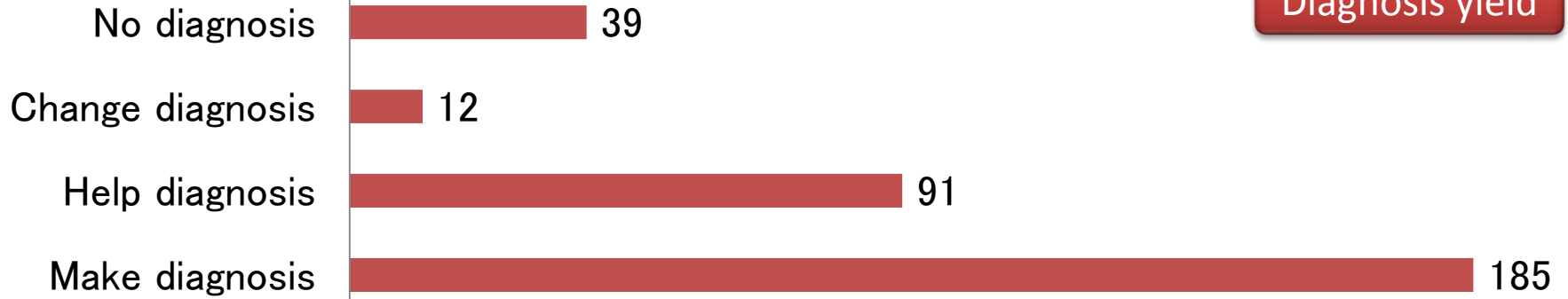
Underlying disease

Reason for EBUS-TBNA

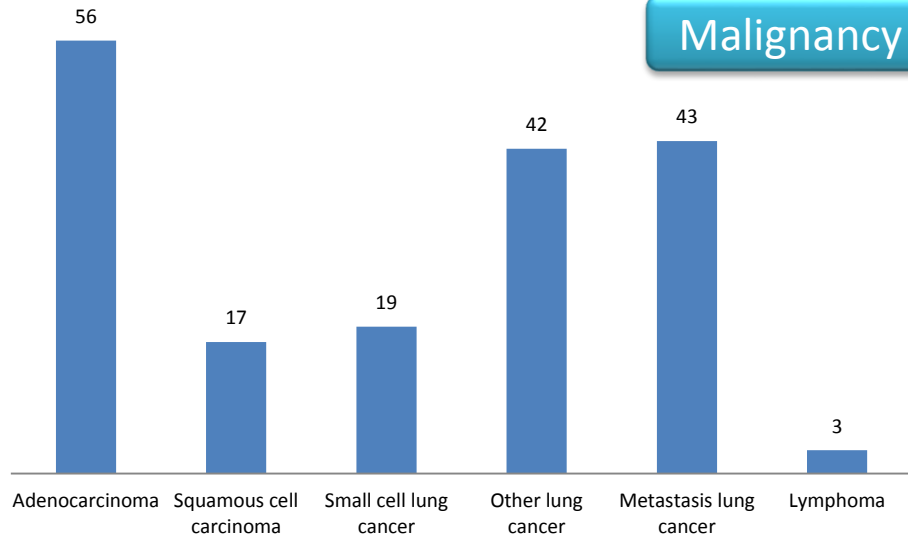


# EBUS-TBNA, n=317

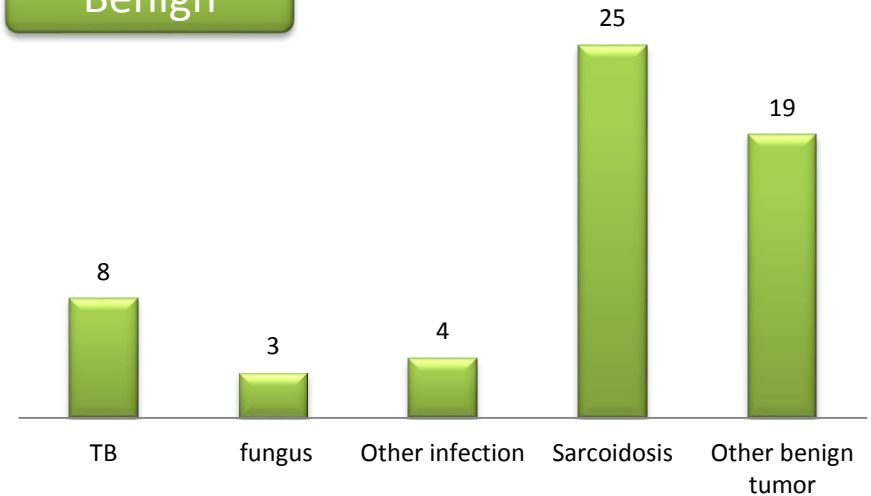
## Diagnosis yield



## Malignancy



## Benign



# Sensitivity, Specificity and Diagnostic accuracy of EBUS-TBNA for diagnosis malignancy

---

EBUS-TBNA	Final result of Lymph node	
	Diagnostic for malignancy	Not Diagnostic for Malignancy
Diagnostic for malignancy	180	0
Not diagnostic for malignancy	20	59

**Sensitivity = 90% (180/ 200 cases);**

**Specificity = 100% (59/59),**

**Diagnostic accuracy = 92.3% (239/259 cases)**

# Conclusion of EBUS-TBNA

---

## Useful staging tool

- EBUS-TBNA is useful as a staging tool in lung cancer patients, especially for bulky mediastinal disease and discrete N2 or N3 disease on CT

## Lung tumor with mediastinal LAP

- Radial and Linear EBUS can help each other in diagnosing lung tumor with mediastinal LAP

## Malignancy rather than lung cancer

- malignancy rather than lung cancer can diagnose by pulmonologist using linear EBUS-TBNA



**STRENGTH**  
**IN NUMBERS**

**#CMUH**