

ISSN 1023-9855



# 胸腔醫學

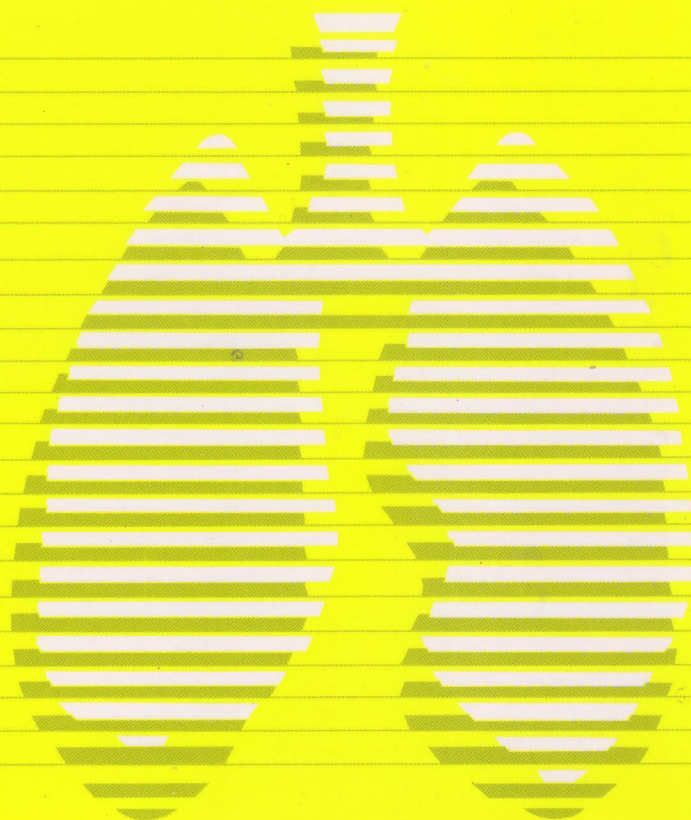
## Thoracic Medicine

The Official Journal of Taiwan Society of  
Pulmonary and Critical Care Medicine

Vol.24 No.1 Feb. 2009

第二十四卷 第一期

中華民國九十八年二月



台灣胸腔暨重症加護醫學會  
台北市中正區仁愛路一段1號

No. 1, Sec. 1, Jen Ai Rd., Taipei, Taiwan, R.O.C.



ISSN 1023-9855



Vol.24 No.1 February 2009

# 胸腔醫學

## Thoracic Medicine

The Official Journal of Taiwan Society  
of Pulmonary and Critical Care Medicine

### 原著

- 打哈欠出現在使用呼吸器的重症患者時可視為一個存活指標 .....1~10  
沈修年，杜漢祥，丁郁茹，陳美偵，沈美麗，呂瑾立，鄭高珍
- 手術證實之原因不明器質化肺炎之臨床結果 .....11~19  
蕭承愷，王鴻昌，丁耀明，朱國安，林旻希，賴瑞生

### 病例報告

- 一位瀰漫性結核併嗜血症候群及多重器官衰竭病患接受靜脈注射免疫球蛋白治療的經驗 .....20~26  
吳福平，蘇文麟，彭萬誠，陳健文
- 罕見的縱隔腔腫瘤“類上皮性血管內皮瘤”：病例報告 .....27~35  
徐培菘，謝義山，葉育雯，江俊松
- 肺及腹膜結核合併結核性脾膿瘍 .....36~41  
王志文，林慶雄，張竣期，蔡政宏，何上芸，鄧宗翰
- 同時發生的二處惡性腫瘤：肺腺癌和腦部的分化不良型寡樹突星狀膠質細胞瘤 .....42~48  
林永淵，林慶雄，葉金水，張竣期，施穎銘，何上芸，陳威良，鄧宗翰
- Boerhaave 氏症候群——病例報告 .....49~53  
黃旭志，謝致政，許文虎
- 縱隔腔脊索瘤——病例報告 .....54~59  
張蒼育，蘇建銘，楊國坤，吳子卿
- 高惡性度之肋膜黏液性紡錘細胞肉瘤 .....60~67  
趙文綺，王勝永，陳兆弘，蘇健，吳健樑
- 中心靜脈導管異位置放於主肺動脈幹內——病例報告 .....68~73  
林瑞原，郭炳宏，陳晉興



Vol.24 No.1 February 2009

# 胸腔醫學

## Thoracic Medicine

The Official Journal of Taiwan Society  
of Pulmonary and Critical Care Medicine

### Original Articles

Yawning as a Predictor of Survival in Critically Ill Mechanically Ventilated Patients ..... 1~10  
Hsiu-Nien Shen, Han-Siong Toh, Yu-Ju Ting, Mei-Chen Chen, Mei-Li Shen, Chin-Li Lu, Kuo-Chen Cheng

The Clinical Outcome of Surgically-Proved Cryptogenic Organizing Pneumonitis..... 11~19  
Cheng-Kai Shiao, Hong-Chung Wang, Yao-Min Ting, Kuo-An Chu, Min-His Lin, Ruay-Sheng Lai

### Case Reports

Intravenous Immunoglobulin Therapy in a Patient with Tuberculosis-associated  
Hemophagocytic Syndrome: A Case Report ..... 20~26  
Fu-Ping Wu, Wen-Lin Su, Wann-Cherng Perng, Chien-Wen Chen

Epithelioid Hemangioendothelioma, a Rare Tumor of the Mediastinum: Case Report and  
Review of the Literature..... 27~35  
Pei-Sung Hsu, Yei-San Hsieh, Diana Yu-Wang Yeh, Jiunn-Song Jiang

Pulmonary and Peritoneal Tuberculosis with Tubercular Splenic Abscess ..... 36~41  
Chih-Wen Wang, Ching-Hsiung Lin, Chun-Chi Chang, Cheng-Hung Tsai, Shang-Yun Ho, Thung-Han Teng

Synchronous Double Primary Malignancy: Adenocarcinoma of Lung and High-Grade Brain  
Malignancy, Anaplastic Oligoastrocytoma ..... 42~48  
Yung-Yuan Lin, Ching-Hsiung Lin, Chin-Shui Yeh, Chun-Chi Chang, Ying-Ming Shih, Shang-Yun Ho,  
Wei-Liang Chen, Tsung-Han Teng

Boerhaave's Syndrome – A Case Report ..... 49~53  
Hsu-Chih Huang, Chih-Cheng Hsieh, Wen-Hu Hsu

Mediastinum Chordoma: A Case Report ..... 54~59  
Choon-Yuk Chong, Jang-Ming Su, Kok-Khun Yong, Tzu-Chin Wu

High-Grade Myxoid Spindle Cell Sarcoma of the Pleura..... 60~67  
Wen-Chi Chao, Shen-Yung Wang, Chao-Hung Chen, Jian Su, Chien-Liang Wu

Malpositioned Central Venous Catheter in the Main Pulmonary Artery Trunk – A Case Report ..... 68~73  
Jui-Yuan Lin, Ping-Hung Kuo, Jin-Shing Chen

# Yawning as a Predictor of Survival in Critically Ill Mechanically Ventilated Patients

Hsiu-Nien Shen, Han-Siong Toh, Yu-Ju Ting\*, Mei-Chen Chen\*, Mei-Li Shen\*,  
Chin-Li Lu\*\*, Kuo-Chen Cheng

**Objectives:** Yawning can be used as a functioning index for the central dopaminergic system and is part of a neural network involved in empathy. The presence of yawning indicates intact functioning in these brain areas. Since encephalopathy occurs frequently in critically ill patients and is associated with patient outcome, we hypothesized that the presence of yawning, as a measure of brain function, might be associated with mortality in critically ill patients.

**Material and Methods:** A total of 99 consecutive patients who were admitted to a medical intensive care unit (ICU) at a tertiary-care hospital between July 1 and November 30, 2006 were prospectively investigated. The occurrence and frequency of yawning were recorded by ICU nursing staff. Multivariate logistic regression was used to determine the independent relationship between yawning and clinical outcomes.

**Results:** About 50% of patients, whether they received invasive mechanical ventilation (MV) or not, had yawned during their ICU stay. Patients who never yawned in the ICU tended to have non-neurological diagnoses ( $p=0.035$ ) or shock ( $p=0.045$ ), or used vasopressors ( $p=0.035$ ), and were more seriously ill as measured by the APACHE II score ( $p=0.004$ ), compared to those who had yawned during their ICU stay. In the logistic regression model, we found that only the presence of yawning (adjusted odds ratio [OR] 0.24, 95% CI 0.06-0.94,  $p=0.04$ ) and use of vasopressors (adjusted OR 9.9, 95% CI 2.55-38.45,  $p=0.001$ ) were independently associated with ICU mortality among MV patients.

**Conclusions:** Yawning is a relatively uncommon behavior in the medical ICU, and its occurrence in MV patients predicts a better survival. (*Thorac Med* 2009; 24: 1-10)

Key words: yawning, mechanical ventilation, critical illness, prognosis

# 打哈欠出現在使用呼吸器的重症患者時可視為一個存活指標

沈修年 杜漢祥 丁郁茹\* 陳美偵\* 沈美麗\* 呂瑾立\*\* 鄭高珍

**背景：**打哈欠的行為可用來當作中樞dopaminergic system的功能性指標，而其神經控制路徑也屬於與同理心有關的神經網絡活動的一部分。打哈欠的產生也就是此神經功能區運作的表現。因為重症患者常有腦病變的併發症，其發生也會影響預後。此研究即假設以打哈欠做為一種中樞神經功能的表現，來探討打哈欠的出現與否和重症患者的預後是否有關。

**方法：**從2006年7月到11月，我們前瞻性地研究了99位陸續住到在南部某醫學中心內科加護病房的患者。其打哈欠的發生與頻率由加護病房的照護護士記錄之。然後再以多變數邏輯分析來測定打哈欠與臨床預後的獨立相關性。

**結果：**不管是否有使用機械通氣，約有一半的患者在加護病房中至少有一次被觀察到有打哈欠的行為。和曾出現打哈欠者比較，未曾出現打哈欠的患者較常有非神經性疾病診斷（ $p=0.035$ ）、休克（ $p=0.045$ ）或使用血壓升壓劑（ $p=0.035$ ），而且疾病嚴重度較高（ $p=0.004$ ）。在多變數邏輯分析模型中，我們發現在使用機械通氣的重症患者中，與加護病房死亡率有獨立相關的因素只有兩個：曾出現打哈欠（adjusted odds ratio [OR] 0.24, 95% CI 0.06-0.94,  $p=0.04$ ）與使用血壓升壓劑（adjusted OR 9.9, 95% CI 2.55-38.45,  $p=0.001$ ）。

**結論：**在內科加護病房的重症患者並不常出現打哈欠。然而，若觀察到使用呼吸器的重症患者有打哈欠的行為，將可以期待其預後會較為樂觀。（*胸腔醫學* 2009; 24: 1-10）

**關鍵詞：**打哈欠，機械通氣，重症，預後



# The Clinical Outcome of Surgically-Proved Cryptogenic Organizing Pneumonitis

Cheng-Kai Shiao\*, Hong-Chung Wang\*, \*\*, Yao-Min Ting\*, \*\*, Kuo-An Chu\*, \*\*, Min-His Lin\*, \*\*, Ruay-Sheng Lai\*, \*\*

**Background:** Cryptogenic organizing pneumonitis (COP) is a specific clinicopathological syndrome characterized by chronic inflammation and a proliferation of granulation tissue within the small airways and alveolar ducts. This report summarized the clinical features of 23 patients with surgically-proved COP and discussed the therapy as well as the outcome of different clinicoradiological patterns of COP.

**Methods:** Twenty-three patients who had surgically-proved COP, from January 1994 to June 2006 at Kaohsiung Veterans General Hospital, were retrospectively evaluated using their radiological images, pulmonary function tests, treatment and prognosis. These patients were classified into 3 groups: (1) COP with a focal pulmonary pattern, (2) COP with a pulmonary consolidation pattern and (3) COP associated with connective tissue diseases.

**Results:** All patients with COP with a focal pulmonary pattern, who received surgical resection alone, had an excellent outcome without local recurrence. Of 11 patients with COP with a pulmonary consolidation pattern who received 2 to 12 months of corticosteroid therapy, 8 (73%) showed marked improvement in both clinical symptoms and pulmonary function test results. Of the 4 patients with COP associated with connective tissue diseases, 3 who received combined corticosteroid and cytotoxic drug therapy had improvement. The remaining patient, who had initial steroid therapy alone, showed no significant improvement, but had a better response after receiving combined treatment with corticosteroid and cytotoxic drugs.

**Conclusions:** COP must be considered in the differential diagnosis of focal nodular lesions. Patients with COP with a pulmonary consolidation pattern characterized by flu-like illness, bilateral crackles and patchy infiltrates had an overall favorable prognosis with corticosteroid therapy. In patients with COP associated with connective tissue diseases, steroid therapy alone may be inadequate. In our limited series of cases, steroid in combination with cytotoxic therapy was effective. (*Thorac Med* 2009; 24: 11-19)

Key words: cryptogenic organizing pneumonia (COP), idiopathic bronchiolitis obliterans organizing pneumonia (BOOP), corticosteroid, connective tissue diseases

---

\* Division of Chest Medicine, Department of Internal Medicine, Kaohsiung Veterans General Hospital, Kaohsiung, Taiwan, R.O.C.; \*\* School of Medicine, National Yang-Ming University, Taipei, Taiwan, R.O.C.

Address reprint requests to: Dr. Yao-Min Ting, Division of Chest Medicine, Department of Internal Medicine, Kaohsiung Veterans General Hospital, 386, Ta-Chung 1st Road, Kaohsiung, 813, Taiwan, R.O.C.

## 手術證實之原因不明器質化肺炎之臨床結果

蕭承愷\* 王鴻昌\*,\*\* 丁耀明\*,\*\* 朱國安\*,\*\* 林旻希\*,\*\* 賴瑞生\*,\*\*

**背景：**原因不明器質化肺炎是一種非特異性的病理形態，常見於肺部的發炎性疾病。其病理組織的特徵為鬆散的節締組織積聚在細小支氣管及肺泡。

**方法：**自1994年1月到2006年6月共有23位病人經由外科手術切片診斷為原因不明器質化肺炎。這些病人可分為三組：局部肺病灶型、原因不明的有機化肺炎（或稱作原發性阻塞性細支氣管炎併有機化肺炎）、以及自體免疫疾病相關的原因不明器質化肺炎。

**結果：**局部肺病灶型病人在外科手術切除後不再復發，亦不需類固醇治療。原因不明器質化肺炎是一種臨床病理症候群，11位病人中有8位（73%）在為期2至12個月類固醇治療後反應良好。自體免疫疾病相關的原因不明器質化肺炎對類固醇治療反應較差。在我們有限的病例中加上細胞毒性藥物可以改善症狀。

**結論：**在局部肺病灶的鑑別診斷過程中原因不明器質化肺炎是要考慮的。原因不明器質化肺炎併有雙側聽診之濕囉音及斑塊狀浸潤使用類固醇治療有良好之預後。與結締組織疾病相關之原因不明器質化肺炎，只有類固醇治療可能是不適當的。在我們有限的病患裡，類固醇併用細胞毒性藥物治療其預後更好。(胸腔醫學 2009; 24: 11-19)

**關鍵詞：**原因不明器質化肺炎，阻塞性細支氣管炎併有機化肺炎，類固醇，結締組織疾病

---

\*高雄榮民總醫院 胸腔內科，\*\*國立陽明大學醫學院

索取抽印本請聯絡：丁耀明醫師，高雄榮民總醫院 內科部 胸腔內科，813高雄市左營區大中一路386號

# Intravenous Immunoglobulin Therapy in a Patient with Tuberculosis-associated Hemophagocytic Syndrome: A Case Report

Fu-Ping Wu, Wen-Lin Su\*, Wann-Cherng Perng\*, Chien-Wen Chen\*

Hemophagocytic syndrome is an uncommon but severe fatal condition associated with a variety of infectious agents, as well as genetic, neoplastic, and autoimmune diseases. We report a 63-year-old man presenting with severe shock, acute respiratory distress syndrome, and multi-organ failure. Hemophagocytic syndrome was suspected due to the high level of serum ferritin and cytopenia, and was confirmed by bone marrow aspiration. His hemodynamic status, cytopenia, and oxygenation improved dramatically after administration of intravenous immunoglobulin for 2 consecutive days. Tuberculosis was confirmed by positive polymerase chain reaction for tuberculosis in the sputum and blood, and later by sputum mycobacterium culture. He recovered uneventfully and was successfully weaned from the ventilator. This case highlights disseminated tuberculosis as a potential cause of HPS; immediate intravenous immunoglobulin administration may rescue the patient from the catastrophic state. (*Thorac Med* 2009; 24: 20-26)

Key words: hemophagocytic syndrome, intravenous immunoglobulin, tuberculosis

---

Department of Medicine, Jingmei Hospital, Taipei, Taiwan; \* Division of Pulmonary and Critical Care, Department of Internal Medicine, Tri-Service General Hospital, Taipei, Taiwan

Address reprint requests to: Dr. Chien-Wen Chen, Division of Chest Medicine, Department of Medicine, Tri-Service General Hospital, No. 325, Section 2, Cheng-Kung Road, Nei-Hu, Taipei, Taiwan, Republic of China



# 一位瀰漫性結核併嗜血症候群及多重器官衰竭病患接受 靜脈注射免疫球蛋白治療的經驗

吳福平 蘇文麟\* 彭萬誠\* 陳健文\*

嗜血症候群是一種罕見但可能致命的疾病。臨床上以不明熱，肝脾腫大，血球低下等方式表現。其病因與感染，遺傳，腫瘤，和自體免疫有關。嚴重嗜血症候群患者也會出現休克，急性呼吸窘迫症候群，以及多重器官衰竭等情形。

本文描述一位重症患者於臨床上診斷出嗜血症候群後，連續接受靜脈注射免疫球蛋白治療兩日而成功改善其血流動脈學與呼吸狀態。後經系列檢查後發現痰液及血液之結核菌聚合酶連鎖反應（polymerase chain reaction）為陽性，痰液之結核菌培養亦為陽性。病患在接受抗結核藥物治療三週後成功拔除氣管內管。結核感染於結核病盛行區應列入嗜血症候群的鑑別診斷，短期使用靜脈注射免疫球蛋白有助穩定此類重症病患之病況。*(胸腔醫學 2009; 24: 20-26)*

關鍵詞：嗜血症候群，靜脈注射免疫球蛋白治療，結核

# Epithelioid Hemangioendothelioma, a Rare Tumor of the Mediastinum: Case Report and Review of the Literature

Pei-Sung Hsu\*, Yei-San Hsieh\*\*, Diana Yu-Wang Yeh\*,\*\*\*, Jiunn-Song Jiang\*,\*\*\*

Epithelioid hemangioendothelioma (EHE) is a rare low-grade malignant tumor of vascular origin, rarely seen in the mediastinum. We described a 27-year-old male with the initial presentation of cough and hoarseness. A superior mediastinal tumor encasing major vessels with vocal cord and diaphragm paralysis was found on CT scan. He received a wide local resection and the pathology was EHE with malignant histopathologic characteristics. He underwent post-operative adjuvant chemoradiotherapy, but metastases to the pleura and lung developed 3 months later. He then underwent another debulking surgery and photodynamic therapy to control the pleural metastasis. No recurrence or metastasis was found up to the writing of this manuscript.

This case shows that malignant histopathologic features are a major factor determining a poor prognosis, as the tumor is more likely to behave like angiosarcoma. There is as yet no reported case of EHE treated by photodynamic therapy in the available medical literature. Short-term results seemed to be excellent in our index patient. Long-term results will require further study. (*Thorac Med* 2009; 24: 27-35)

Key words: epithelioid hemangioendothelioma

---

\* Division of Chest Medicine, Department of Internal Medicine;

\*\* Division of Thoracic Surgery, Department of Surgery, Shin Kong Wu Ho-Su Memorial Hospital;

\*\*\* School of Medicine, Fu-Jen Catholic University, Taipei, Taiwan

Address reprint requests to: Dr. Jiunn-Song Jiang, Division of Chest Medicine, Department of Internal Medicine, Shin Kong Wu Ho-Su memorial hospital, Taipei, Taiwan, No. 95, Wen Chang Road, Shih Lin District, Taipei, Taiwan

## 罕見的縱隔腔腫瘤“類上皮性血管內皮瘤”：病例報告

徐培菘\* 謝義山\*\* 葉育雯\*,\*\*\* 江俊松\*,\*\*\*

類上皮性血管內皮瘤是一種罕見的血管低惡性腫瘤，少見於縱隔腔。我們提出一位27歲男性一開始以咳嗽及聲音沙啞表現。胸部電腦斷層顯示一上縱隔腔腫瘤包圍著大血管，導致聲帶及橫膈麻痺。他接受手術切除而病理報告顯示類上皮性血管內皮瘤併有惡性病理特徵。術後並接受化學放射治療。但是3個月後發現肺部及肋膜轉移。他接著接受切除手術及光動力刀治療來控制肋膜轉移。目前沒有發現局部復發或轉移。

這個病例顯示出惡性的病理組織特徵是決定這個病預後的主要因素。有這樣的惡性的病理組織特徵會使得腫瘤表現的像惡性的血管肉瘤。光動力刀治療類上皮性血管內皮瘤併肋膜轉移的方式在文獻上尚未被報導，短期的效果良好，但長期的效果有待進一步追蹤。(胸腔醫學 2009; 24: 27-35)

關鍵詞：類上皮性血管內皮瘤

# Pulmonary and Peritoneal Tuberculosis with Tubercular Splenic Abscess

Chih-Wen Wang, Ching-Hsiung Lin, Chun-Chi Chang, Cheng-Hung Tsai,  
Shang-Yun Ho\*, Thung-Han Teng\*\*

Splenic abscess is uncommon, with an incidence of 0.14% to 0.7% in autopsy-based studies. The most common pathogen of splenic abscess in Taiwan is *Klebsiella pneumoniae*; *Mycobacterium tuberculosis* is very rare as a causative agent in an immunocompetent patient.

We report a 76-year-old woman with active pulmonary tuberculosis who presented with left upper quadrant abdominal pain associated with fever for several days. Computerized tomography scan of the abdomen revealed multiple low density wedge-shaped lesions in the upper and lower portions of the spleen. Tubercular splenic abscess was confirmed by histopathological examination of the excised spleen. Pulmonary tuberculosis was diagnosed via positive sputum acid-fast smear and culture.

Tubercular splenic abscess should be on the list of differential diagnoses of an active pulmonary TB patient who presents with left upper quadrant pain and fever. Early anti-tuberculosis treatment should be started and splenectomy reserved for those with an unsatisfactory response or complications, so as to prevent mortality. (*Thorac Med* 2009; 24: 36-41)

Key words: tubercular splenic abscess

---

Division of Chest Medicine, Department of Internal Medicine; \* Department of Medical Imaging; \*\* Department of Pathology, Changhua Christian Hospital, Changhua, Taiwan

Address reprint requests to: Dr. Ching-Hsiung Lin, Division of Chest Medicine, Department of Internal Medicine, Changhua Christian Hospital, No. 135 Nanshiao Road, Changhua City, 500, Taiwan

## 肺及腹膜結核合併結核性脾膿瘍

王志文 林慶雄 張竣期 蔡政宏 何上芸\* 鄧宗翰\*\*

脾膿瘍是種罕見的疾病，以病理解剖的研究顯示發生率約在0.14%到0.7%。在臺灣造成脾膿瘍最常見的病原菌是克雷伯氏菌，因結核菌造成脾膿瘍更為稀少，大部份發生在免疫不全的病患上。

我們報告一個76歲女性，症狀為左上腹痛及發燒數天，其腹部電腦斷層發現許多脾化膿的區域，利用脾臟切除及病理切片得到結核性脾膿瘍的診斷。同時利用痰液及腹水的耐酸性染色及培養證實患者有活動性肺結核及結核性腹膜炎。

在一位活動性肺結核的病患上，如果發現有發燒及左上腹疼痛時，結核性脾膿瘍是必需列入的診斷選項。抗結核藥必需及早給予，脾臟切除則保留在病患對藥物反應不良時施行。(胸腔醫學 2009; 24: 36-41)

關鍵詞：結核性脾膿瘍



# Synchronous Double Primary Malignancy: Adenocarcinoma of Lung and High-Grade Brain Malignancy, Anaplastic Oligoastrocytoma

Yung-Yuan Lin, Ching-Hsiung Lin, Chin-Shui Yeh, Chun-Chi Chang, Ying-Ming Shih,  
Shang-Yun Ho\*, Wei-Liang Chen\*, Tsung-Han Teng\*\*

Synchronous double primary malignancy of the lung and brain is extremely rare, as there were only 2 cases reported in the literature. If patients were found to have both lung and brain malignancy, they would be ordinarily be considered to have lung cancer with brain metastasis.

We report a 76-year-old female who came to our hospital due to slurred speech for 2 weeks. Brain magnetic resonance imaging (MRI) showed a heterogeneous mass lesion at the left parietal lobe with perifocal edema. Stereotactic biopsy confirmed anaplastic oligoastrocytoma. In the meantime, the pre-operative chest radiograph accidentally found a patch of opacity at the left hilar area during the same admission. The chest computed tomography (CT) scan showed a mass lesion at the left lingular lobe; bronchoscopic finding was unremarkable. Histology of the CT-guided biopsy specimen showed adenocarcinoma. Due to the poor performance status and the patient's family refusing operation, only palliative radiotherapy to the brain was administered. She was still living 7 months later.

This case report highlights the importance of searching for and confirming synchronous tumor in addition to lung cancer, since there is the potential of cure and long-term survival. (*Thorac Med* 2009; 24: 42-48)

Key words: synchronous double primary malignancy

---

Division of Chest Medicine, Department of Internal Medicine; \* Department of Medical Imaging; \*\* Department of Pathology, Changhua Christian Hospital, Changhua, Taiwan

Address reprint requests to: Dr. Ching-Hsiung Lin, Division of Chest Medicine, Department of Internal Medicine, Changhua Christian Hospital, 135 Nanshiao Road, Changhua, 500, Taiwan

## 同時發生的二處惡性腫瘤：肺腺癌和腦部的分化不良型寡樹突星狀膠質細胞瘤

林永淵 林慶雄 葉金水 張竣期 施穎銘 何上芸\* 陳威良\* 鄧宗翰\*\*

同時在腦部及肺部發現原發惡性腫瘤是非常少見的，文獻中只有2個病例報告。由於病例稀少，當一個病人被診斷肺癌，而腦部又發現有另一個腫瘤的話，大部分的病人會被當成肺癌併腦轉移。

我們報告一個76歲女性，她因為講話含糊不清持續二週而到我們的醫院就診。腦部核磁共振檢查發現左邊頂葉有一個腫瘤，腫瘤周圍並有水腫。接著安排病人接受立體定位切片，病理診斷為分化不良型寡樹突星狀膠質細胞瘤（anaplastic oligastrocytoma）。同一時間，手術前的例行性胸部X光片檢查意外發現在左肺門區域有一個濃度增加的病灶，胸部斷層掃描顯示是一個腫瘤在左肺舌葉。支氣管鏡檢查並無異常發現，而斷層掃描導引下切片證實了是肺腺癌。由於患者年紀較大及活動力差，家屬拒絕手術及化學治療，病人僅接受緩解症狀的腦部放射治療，病人目前已存活超過7個月。

這個病例提醒我們，去尋找並診斷和肺癌同時發生的另一個惡性腫瘤是很重要的；因為這二個腫瘤都有可能治癒，而病人可能獲得長時間的存活。(胸腔醫學 2009; 24: 42-48)

關鍵詞：同時發生的二處原發惡性腫瘤

# Boerhaave's Syndrome – A Case Report

Hsu-Chih Huang, Chih-Cheng Hsieh, Wen-Hu Hsu

Spontaneous perforation of the thoracic esophagus, known as Boerhaave's syndrome, develops after vomiting or retching due to massive alcohol or food ingestion. An uncoordinated esophageal sphincter reflex opening results in a sudden increase of intramural esophageal pressure and complete transmural rupture in the weakest region, which is often the left lateral wall of the distal esophagus. This causes mediastinitis, empyema, sepsis and multi-organ failure, accounting for a mortality ranging from 20% to 40%. The prognosis depends on the interval from onset to management and the underlying physical status of the patient. Urgent surgical intervention within 24 hours after onset is advocated. Primary repair of the esophageal perforation and drainage of the pleural contamination should be done if conditions are feasible. Enteral nutrition should be reestablished by gastrostomy or jejunostomy.

We reported a case of Boerhaave's syndrome. Urgent surgical intervention was undertaken immediately after diagnosis, within 24 hours after onset. Primary repair of the esophageal perforation was successful. Oral feeding started on postoperative day 33 and no complications occurred after a 4-month follow-up. In such cases, an early and accurate diagnosis, timely surgical intervention, infection control and nutritional support in the postoperative period will lead to a better prognosis. (*Thorac Med* 2009; 24: 49-53)

Key words: Boerhaave's syndrome, esophageal perforation

## Boerhaave 氏症候群——病例報告

黃旭志 謝致政 許文虎

自發性食道破裂（Boerhaave氏症候群）發生於酗酒或大量進食後嘔吐病人，起因於食道括約肌不協調收縮導致食道腔內壓急遽上升，造成食道下段破裂，通常發生於左後壁，常引起嚴重之縱膈腔炎，膿胸，敗血症，甚至多重器官衰竭，死亡率可高達20-40%。此症之預後與發生至治療的時間長短，以及病患身體狀況相關，一般建議於發生後24小時內進行外科手術，在情況許可下應直接修補食道破裂處及引流胸腔內污染物，同時以胃或小腸造瘻作為腸道營養之途徑。

我們報告一位68歲病例，於發生24小時內實行食道修補，胸腔內引流，減壓性胃造瘻及灌食性小腸造瘻，病患術後恢復良好，於術後第33日開始經口進食，至今追蹤四個月亦無併發症發生。針對此症病患，及時且正確之診斷，於發生24小時內進行手術修補破裂處，術後持續感染控制及給予腸道營養補充，將有較佳之預後。*(胸腔醫學 2009; 24: 49-53)*

關鍵詞：食道破裂，Boerhaave氏症候群

# Mediastinum Chordoma: A Case Report

Choon-Yuk Chong, Jang-Ming Su\*, Kok-Khun Yong, Tzu-Chin Wu

Chordoma is a slow-growing yet locally aggressive malignant neoplasm of the bone derived from remnants of the embryonic notochord. Thoracic chordoma is even rarer. It may occur at the skull base (35%), at the cervical, thoracic and lumbar spine (2.3-15%), and at the sacral regions (50%). We present a 21 year-old girl who had a slow-growing left-side mediastinal tumor for 14 years. The chest X-ray film showed a benign-looking, small-sized, well-circumscribed tumor with calcification; the benign appearance on the chest X-ray delayed her prompt diagnosis and treatment.

The patient began to experience left hand dryness 2 years previously, and a recent onset of back pain. Echo-guided aspiration revealed cords and lobules of large tumor cells in the chondroid stroma. Immunohistochemical staining was positive for S-100 protein, cytokeratin and vimentin. These observations indicated a malignant chordoma. She received a total surgical resection of the tumor, together with a partial osteotomy of C7 and T1-T3. The area of bone substance loss was filled with cement. Adjuvant stereotatic radiotherapy with 50 Gy was given. No local recurrence was seen after 5 months. (*Thorac Med* 2009; 24: 54-59)

Key words: mediastinum chordoma

---

Division of Pulmonary Medicine, Department of Internal Medicine, Chung-Shan Medical and Dental University Hospital, Taichung, Taiwan; \* Chest Surgery Division, Kuang Tien Hospital  
Address reprint requests to: Dr. Tzu-Chin Wu, Division of Pulmonary Medicine, Department of Internal Medicine, Chung-Shan Medical and Dental University Hospital, Taichung, Taiwan



## 縱隔腔脊索瘤——病例報告

張蒼育 蘇建銘\* 楊國坤 吳子卿

脊索瘤是一種緩慢生長，起源於殘餘胚性背索的腫瘤，但是對局部組織破壞性很強，可發生於顱骨底（35%），頸，胸，腰脊椎（2.3-15%），和薦椎（50%）。胸廓的脊索瘤同樣罕見。在此一病例報告中，我們報告一個21歲女性病患，有一個緩慢生長達14年的左側縱隔腔腫瘤。其X光表現像良性的腫瘤，即邊緣清楚，鈣化及生長緩慢，而延遲病患的及時診斷和治療。

她兩年前開始出現左手乾燥的症狀。最近出現胸後背部痛。超音波指引抽吸術病理檢查報告為小葉和圓狀的大腫瘤細胞於軟骨樣基質。特殊免疫染色呈現對S-100蛋白，細胞角蛋白（cytokeratin），波形蛋白（vimentin）陽性。這些檢查證實為惡性脊索瘤，病患隨後接受此縱隔腔腫瘤的完全切除，同時進行C7, T1-T3的局部切骨術及填充骨泥。病患術後接受50Gy局部立體放射線治療，至今5個月也沒有局部復發。  
(胸腔醫學 2009; 24: 54-59)

關鍵詞：縱隔腔脊索瘤

# High-Grade Myxoid Spindle Cell Sarcoma of the Pleura

Wen-Chi Chao, Shen-Yung Wang\*, Chao-Hung Chen\*\*, Jian Su, Chien-Liang Wu

Spindle cell sarcomas arise from primitive mesenchymal cells and have a broad spectrum of histological differentiation. They are rare but diversified in presentation, as well as outcomes. A small group of these rare malignant tumors presents spindle cells embedded in an abundant myxoid stromal matrix. The myxoid spindle cell sarcomas mostly involve the extremities, and their occurrence in the pleura is rare. The distinguishing of the various sarcomas within the group of myxoid spindle cell sarcomas is complicated. We report a case of high-grade myxoid spindle cell sarcoma arising from the pleura presenting with massive pleural effusion. Thoracoscopic inspection of the pleural cavity showed a fleshy and gelatinous formless mass. Surgical removal provided only temporary relief. The tumor regrew rapidly and did not respond to salvage radiotherapy. The histological patterns and the immunohistochemical studies suggested a high-grade myxoid spindle cell sarcoma. However, the features of the tumor presented here were distinct from those of the published differential diagnoses of myxoid spindle cell sarcoma. The literature was reviewed and the differential diagnoses of the presented case explored. (*Thorac Med* 2009; 24: 60-67)

Key words: myxosarcoma, pleural neoplasms

---

Division of Chest Medicine, Department of Medicine; \*Division of Gastroenterology, Department of Medicine;  
\*\*Division of Thoracic Surgery, Department of Surgery, Mackay Memorial Hospital, Taipei, Taiwan  
Address reprint requests to: Dr. Jian Su, Division of Chest Medicine, Department of Medicine, Mackay Memorial  
Hospital, 92, Section 2, Chungshan North Road, Taipei 10449, Taiwan

## 高惡性度之肋膜黏液性紡錘細胞肉瘤

趙文綺 王勝永\* 陳兆弘\*\* 蘇健 吳健樑

紡錘細胞肉瘤為罕見的軟組織腫瘤，由原始間質細胞產生，並有廣泛而多樣的組織細胞分形。這些肉瘤有著多元的表現與分歧的預後。在紡錘細胞肉瘤中，有一群腫瘤其紡錘細胞包埋在含有豐富黏液性的基質體中，為黏液性紡錘細胞肉瘤，大多發生在周邊四肢，而罕見原發於肋膜。要區分黏液性紡錘細胞肉瘤不同之亞型有相當之困難度。我們在此提出一個以大量肋膜積水表現的原發性肋膜高惡性度黏液性紡錘細胞肉瘤的個案。胸腔鏡下觀察發現在肋膜腔內有大量凝膠狀、肉瘤狀的無定形腫瘤。病理檢查確立為高惡性度黏液性紡錘細胞肉瘤。手術移除只能提供暫時性的緩解，放射線治療並無法遏止腫瘤在手術後的迅速惡化。綜合臨床表現與病理檢查的結果，此肉瘤與目前文獻已報告的亞型均有差異之處。為一獨特的表現。黏液性紡錘細胞肉瘤並不易診斷或分類，我們藉這個特殊的病例將可能鑑別診斷之亞型間的臨床病程、組織型態、免疫染色、預後與治療作一綜論與分析。*(胸腔醫學 2009; 24: 60-67)*

關鍵詞：黏液性紡錘細胞肉瘤，肋膜腫瘤

# Malpositioned Central Venous Catheter in the Main Pulmonary Artery Trunk – A Case Report

Jui-Yuan Lin, Ping-Hung Kuo, Jin-Shing Chen\*

Central venous catheterization may provide hemodynamic information and act as a route for the rapid infusion of fluids and therapeutic agents. The complications of central venous cannulation are numerous. Vascular injuries during central venous catheter (CVC) insertion encompass a wide spectrum of complications, with arterial puncture being the most common. We report a 67-year-old woman with profound septic shock in whom the main pulmonary artery trunk was accidentally cannulated during an attempt to establish central venous access. Mini-thoracotomy for CVC removal was performed. Minimal pneumothorax and some reddish pleural effusion were found. The postoperative hemodynamic status was stable. We also reviewed the related literature on complications and pulmonary artery injury during central venous catheterization. (*Thorac Med* 2009; 24: 68-73)

Key words: central venous catheter, malposition, pulmonary artery

---

Departments of Internal Medicine and Surgery\*, National Taiwan University Hospital, Taipei, Taiwan  
Address reprint requests to: Dr. Ping-Hung Kuo, Division of Chest and Critical Care Medicine, Department of Internal Medicine, National Taiwan University Hospital, 7, Chung-Shan South Road, Taipei 100, Taiwan

# 中心靜脈導管異位置放於主肺動脈幹內——一病例報告

林瑞原 郭炳宏 陳晉興\*

置放中心靜脈導管可以提供血液動力學的資訊與作為快速輸注液體和治療製劑的管道。有許多種中心靜脈導管置放術的併發症，包括異位、動脈穿刺、氣胸、血胸、乳糜胸、縱隔血腫、鄰近的神經受傷、輸注物外滲出血管、血栓靜脈炎和感染。中心靜脈導管置放過程中造成血管受傷包括多種併發症，其中以動脈穿刺為最常見。我們報告一個67歲女性合併深度的敗血性休克，在試圖建立中心靜脈導管過程中，將導管意外地放置在主肺動脈幹內。中心靜脈導管藉由實行微型胸廓切開術而移除。極少量氣胸與些許紅色肋膜積液被發現。術後的血液動力學狀況穩定。我們回顧了有關中心靜脈導管置放過程中造成的併發症與肺動脈受傷相關之文獻報告。(*胸腔醫學* 2009; 24: 68-73)

關鍵詞：中心靜脈導管，異位，肺動脈