

## 花蓮慈濟醫院影像診療研討會

日期：2026年02月06日  
時間：08:00 - 09:00  
地點：花蓮慈濟醫院大愛七樓 702 教室

時間	題目	主講人
08:00-09:00	個案討論	蘇恩賢

### Patient Profile

- Name: 方 o 滿
- Sex: female
- Age: 71 y/o
- Weight: 58 kg

### Chief complaint

progressed dyspnea with milky productive cough

### History of present illness

cough, milky sputum, dyspnea, BW loss 10+ kg

### Social & family history

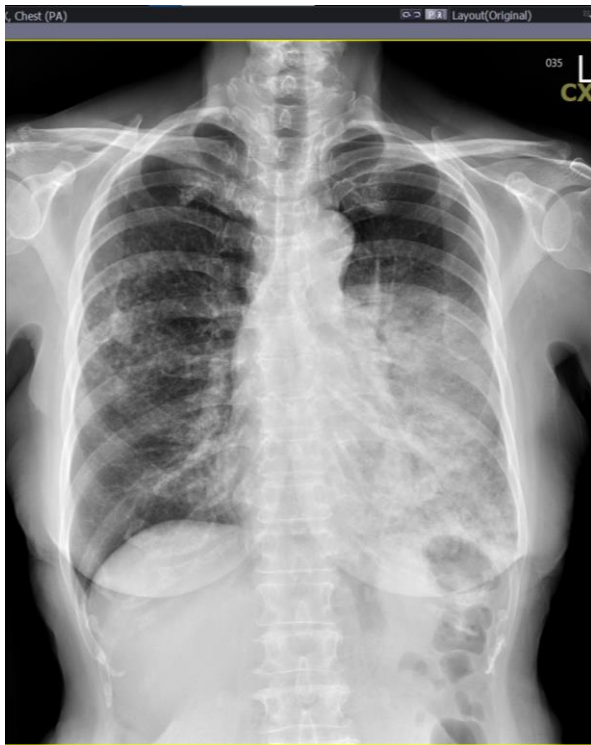- Occupation: retired farmer
- Alcohol (-), Betel nuts (+), Cigarettes (-)
- Independent ADL
- Father: HTN

### Clinical course

**cough with milky sputum since April, accompany with dyspnea, especially when she cough**

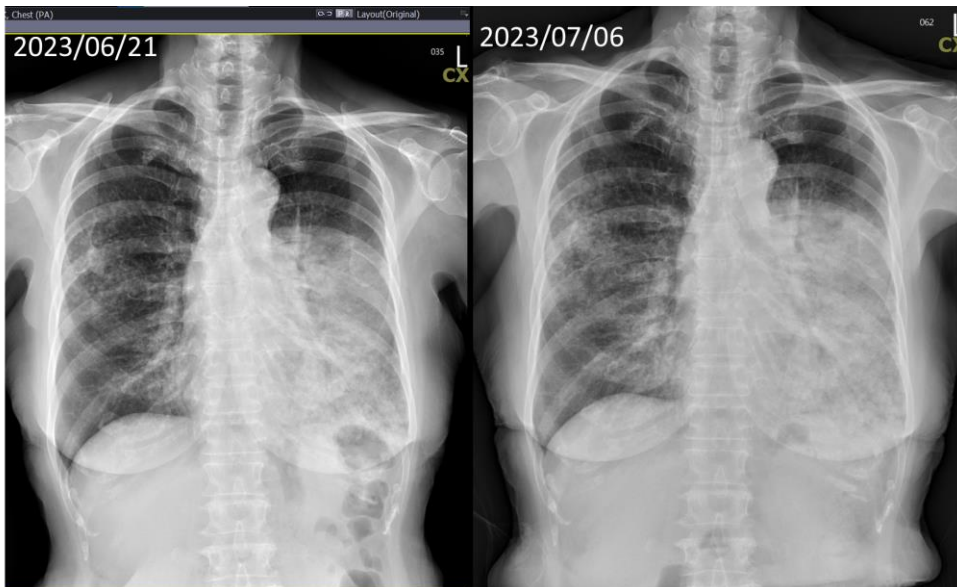
**6/20 found her body weight has loss about 10+kg, visited Taitung Christian Hospital**

**6/21 Chest CXR revealed bilateral pneumonia**

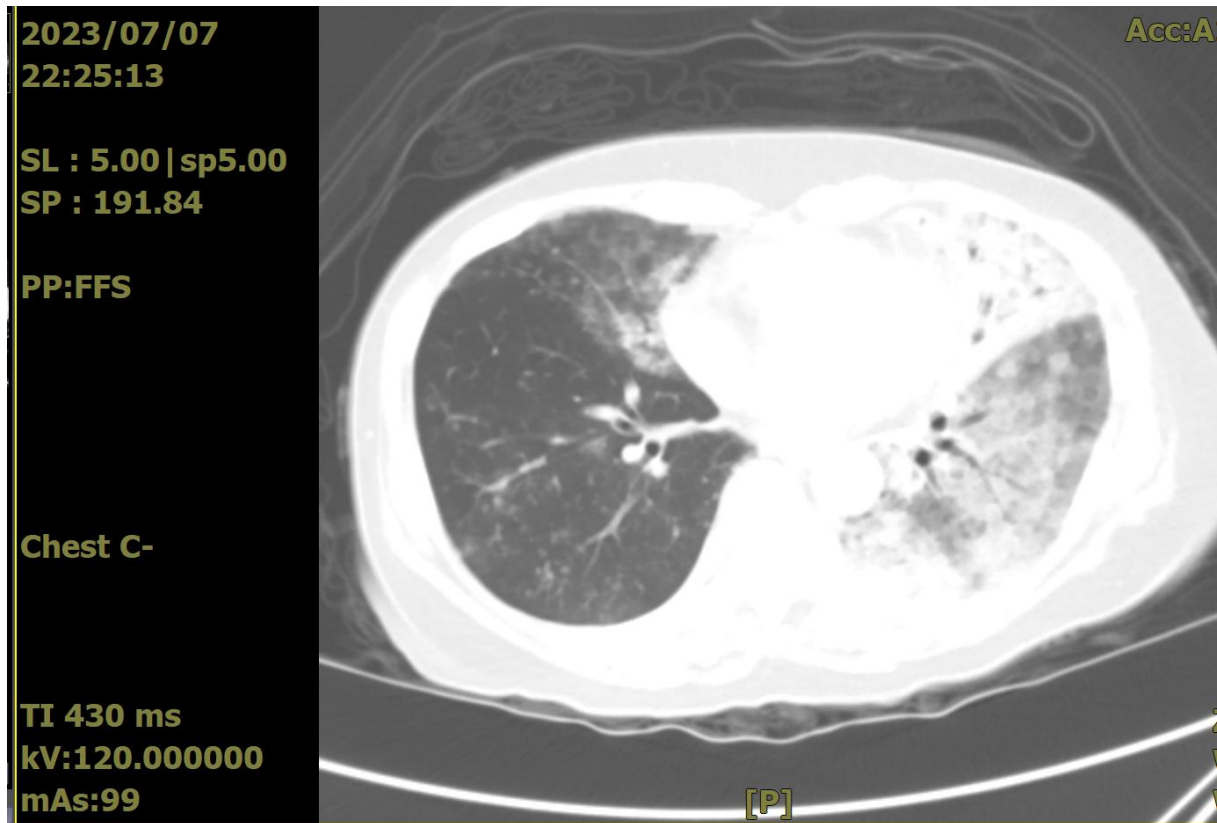


**6/30 admit to Taitung Christian Hospital due to LUL pneumonia**

**7/03 BAL: suspect ciliary parasite, suspect pulmonary alveolar proteinosis**



**7/07 refer to Hualien TCH ER**



7/08 admit to CM ward:

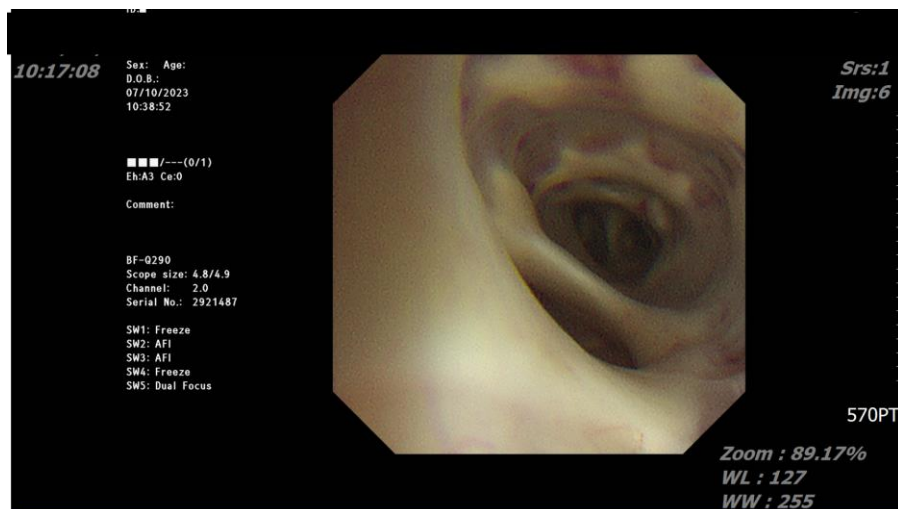
empirical brosym (Cefoperazone + Sulbactam)

7/10 bronchoscope: BAL over LB3, pinkish

⇒ cytology: atypical bronchiolar cells, PAS negative

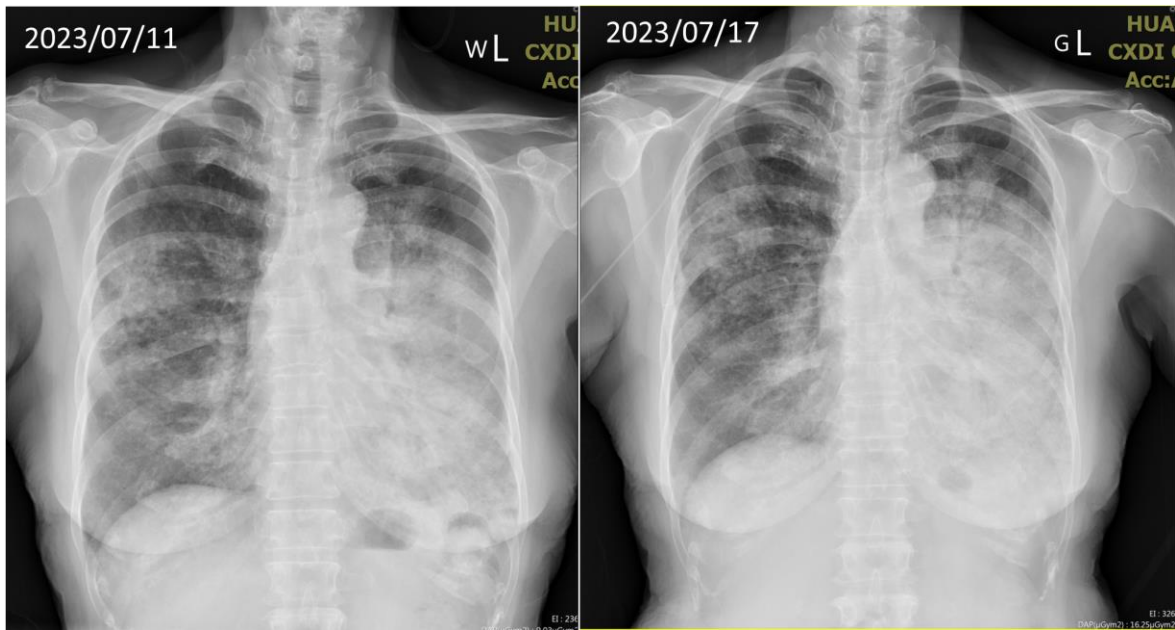
⇒ Sp/C at Taitung: NTM, Mycobacterium avium

⇒ BAL culture: Veillonella

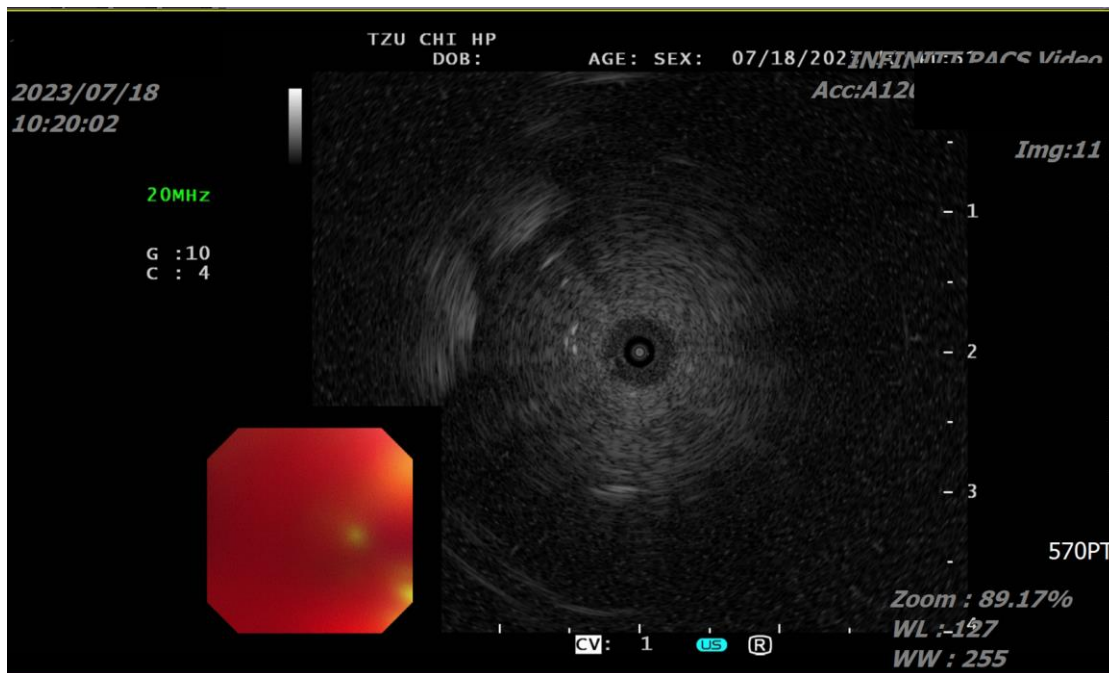


7/11 Azithromycin + Ethambutol + Rifampin

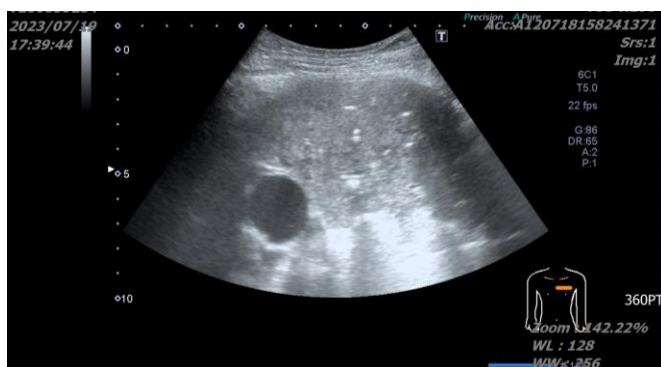7/17 CXR not improved, CEA 3.9



7/18 EBUS



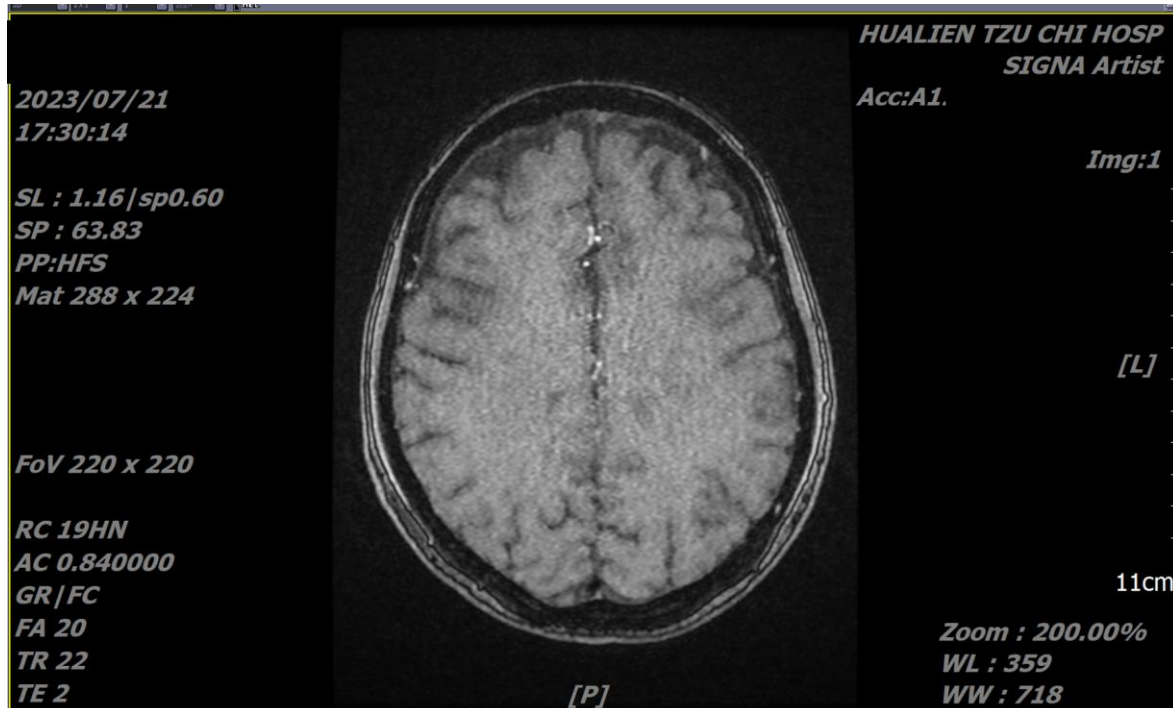
7/19 Echo guide biopsy



7/21 pathology: adenocarcinoma, TTF-1 (+), p63 (-), ROS1 (faint +, 10%), ALK (-), PD-L1 (-).

=> EGFR: exon 21 (L858R) point mutation

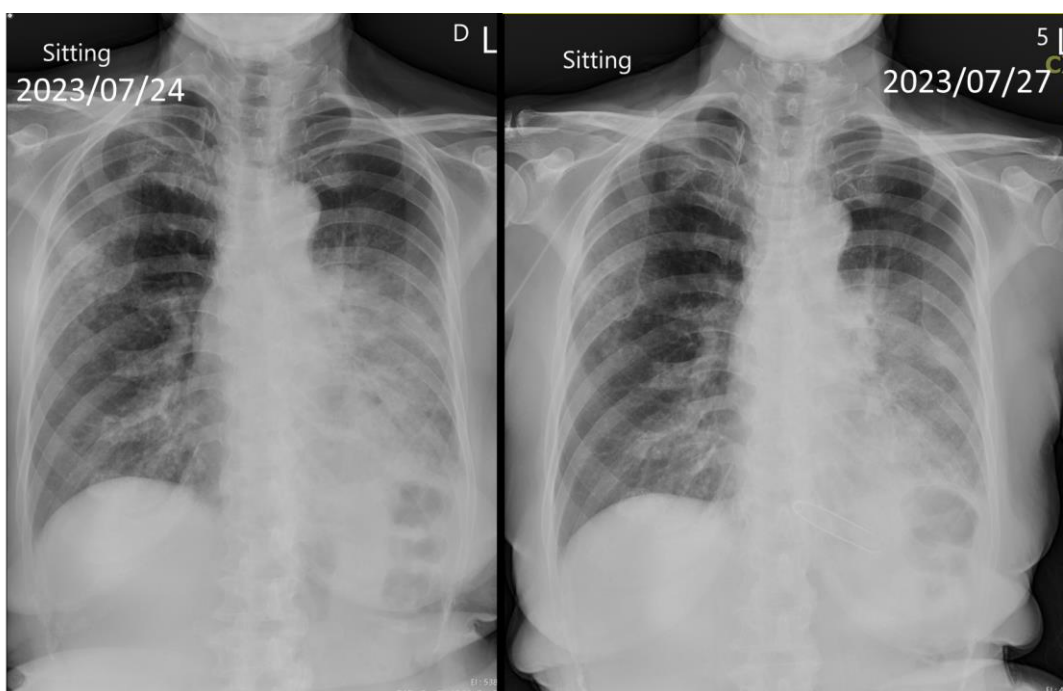
=> brain MRI: no enhancing mass



7/24 FDG-PET: LUL with lung to lung meta  
, cT4N3M1a, stage IVA

=> start oral TKI, Afatinib

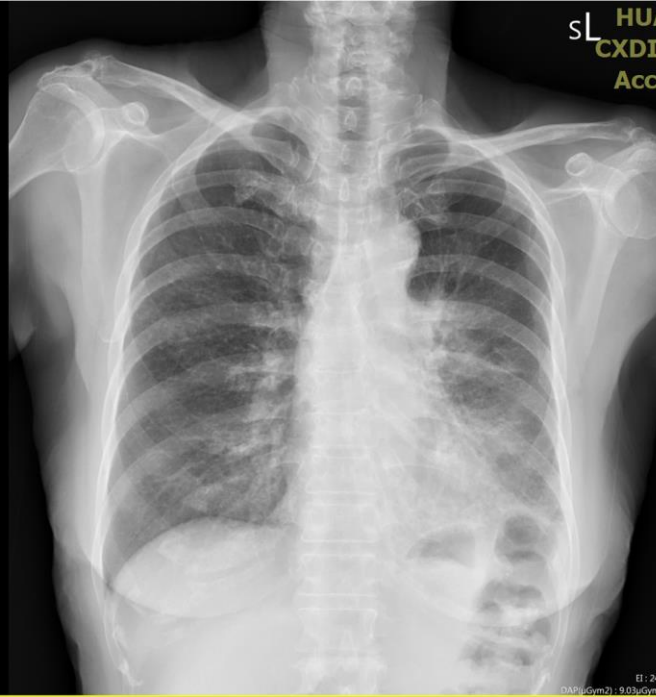
=> CM, ophth, ENT OPD follow up



7/29 Discharge

2023/08/02  
11:12:31

SL HUALIEN TZU CHI HOSP  
CXDI Control Software NE  
Acc:A12



Img:1

kV:110.000000  
mAs:3

20cm

Zoom : 31.56%  
WL : 2048  
WW : 4096

EI : 243  
DAP: 9.03 Gy/m2