

## 花蓮慈濟醫院影像診療研討會

日期：2026年05月22日  
時間：08:00 - 09:00  
地點：花蓮慈濟醫院大愛七樓 702 教室

時間	題目	主講人
08:00-09:00	個案討論	陳祐彤

### Patient Profile

- # 陳0綺, 56-year-old female, retired caregiver
- # **Chief complaint** : hemoptysis for three days
- # **Social history**: Alcohol: none, Betel nut: none, Cigarette: none
- # **TOCC**: none
- # **Family history**: Mom and Dad had hypertension

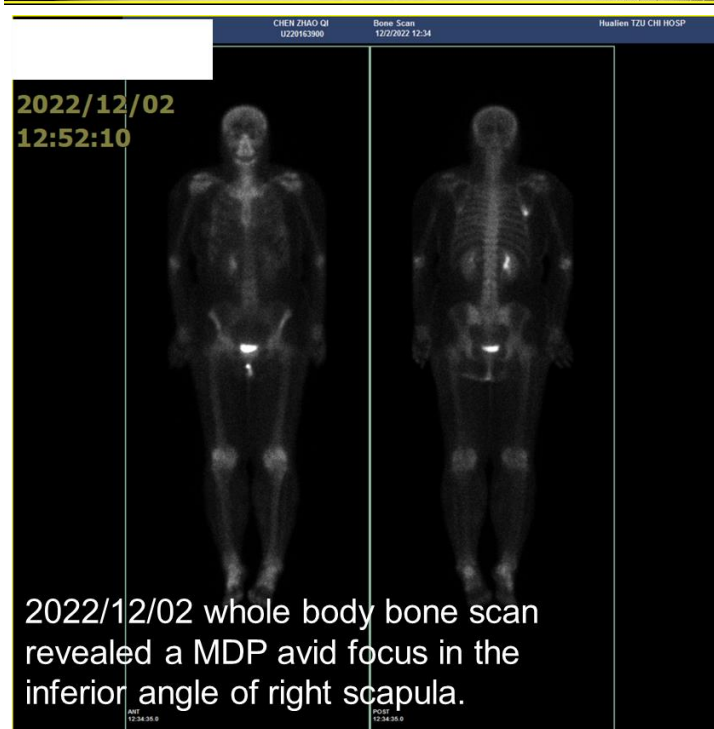
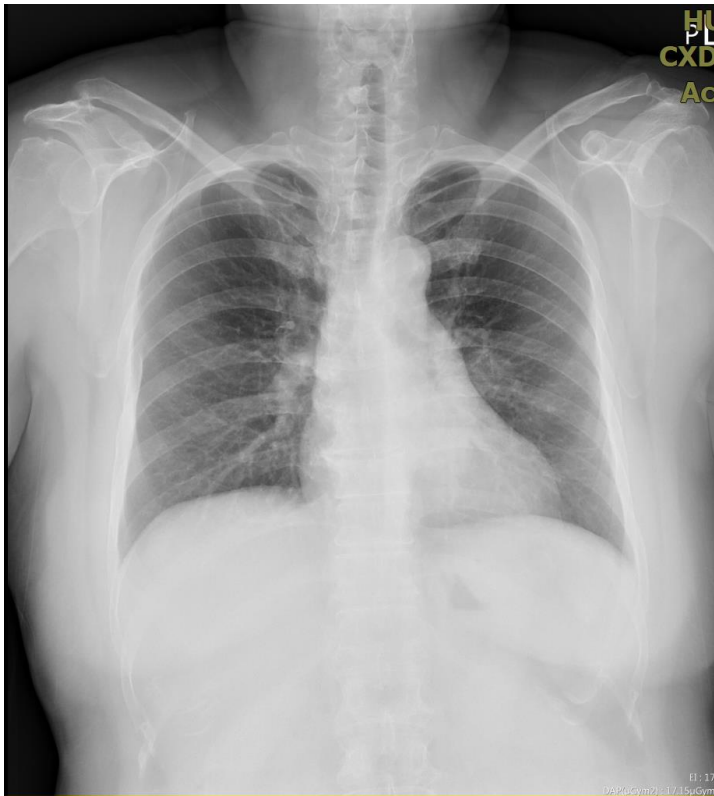
### Past history

right breast tumor, pT2N0M0, stage IIA s/p right partial mastectomy and SLNB at 2022/12/8

- ER: Positive (strong, 90%) , PR: Positive (strong, 80%), Her/neu: Negative (score 0, no membrane staining), Ki67: 15%.

leiomyoma of uterus s/p laparoscopically assisted vaginal hysterectomy (LAVH) with bilateral salpingo-oophorectomy (BSO) at 2013/08/07

hypertension, insomnia, type 2 DM



2022/12/20 Admitted to our CM ward due to hemoptysis for three days

2022/12/20

檢體名稱	報告日期	檢驗項目	檢驗報告	單位	標準(低)	標準(高)
Blood		CBC & PLT				
	1111220	WBC	6.19	*10 <sup>3</sup> /ul	3.50	11.00
		RBC	4.09	*10 <sup>6</sup> /ul	4.00	5.20
		Hb	12.0	g/dL	12.0	16.0
		Ht	36.2	%	36.0	46.0
		MCV	88.5	fL	80.0	100.0
		MCH	29.3	pg	26.0	34.0
		MCHC	33.1	%	31.0	37.0
		PLT	332	*10 <sup>3</sup> /ul	150	400
		RDW-CV	12.6	%	11.5	14.5
檢體名稱	報告日期	檢驗項目	檢驗報告	單位	標準(低)	標準(高)
Blood		PT		sec.	8.0	12.0
	1111220	PT	10.3	sec	8.0	12.0
		Control	10.4	sec.		
		INR	0.99		0.85	1.15
		APTT		sec.	23.9	35.5
	1111220	APTT	24.6	sec.	23.9	35.5
		Control	27.0	sec.		

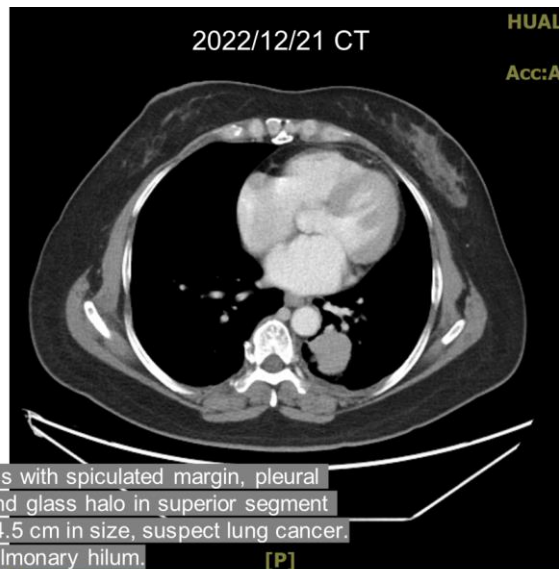
2022/12/20

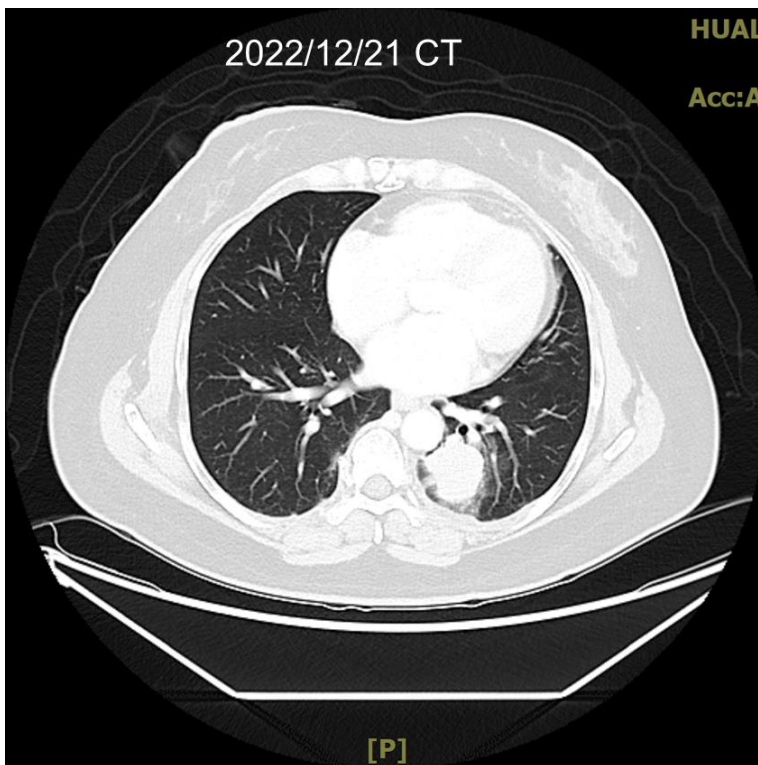
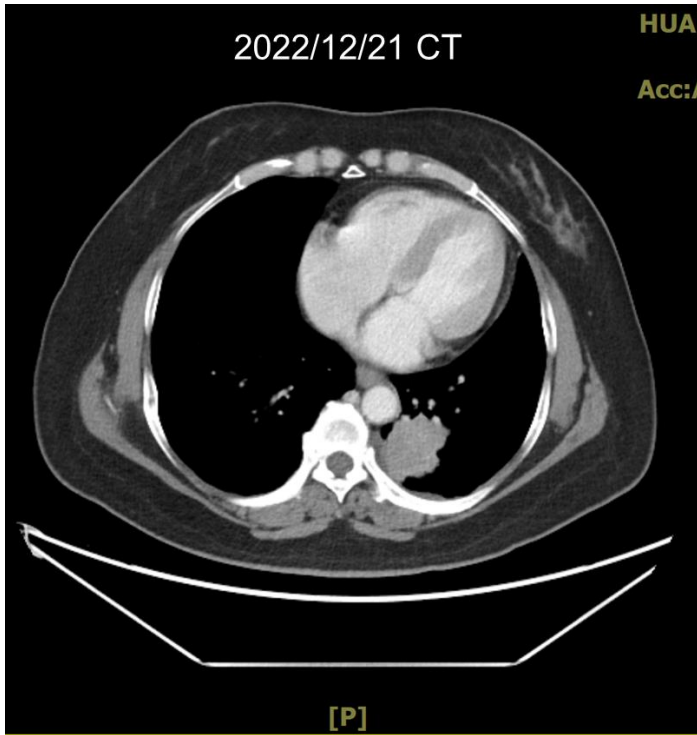
檢體名稱	報告日期	檢驗項目	檢驗報告	單位	標準(低)	標準(高)
Blood		HbA1c		%		
	1111220	HbA1c	7.2	%	4.0	6.0
		eA GLU	160	mg/dL		
	1111220	CRE	0.54	mg/dL	0.60	1.20
		eGFR	124.12	mL/min	90	
		Na	137	mmol/L	136	145
		K	4.2	mmol/L	3.5	5.1
報告日期	檢驗項目	檢驗報告	單位	標準(低)	標準(高)	
1111221	CA 125	11.2	U/mL		35.0	
	CA 19-9	5.1	U/mL		35.0	

2022/12/20 Admitted to our CM ward due to hemoptysis for three days

2022/12/21 Arranged CT

2022/12/21





**2022/12/20** Admitted to our CM ward due to hemoptysis for three days

**2022/12/21** Arranged CT

**2022/12/21** Arranged bronchoscopic ultrasonography for localization and biopsy

2022/12/21 EBUS

Left lowerlobe lung tumor, post EBUS for localization of the tumor at LB10, then biopsy.

檢驗名稱	Surgical pathology Level IV			
器官部位名稱	開立醫師	林智斌	簽收時間	12/21 15:59
	報告醫師	鄭秋璇	報告時間	01/10 08:42
檢驗前診斷名稱	Neoplasm of unspecified nature of respiratory system;			
檢驗後診斷名稱	JS biopsy, 1)adenocarcinoma, 2)chronic passive congestion or pulmonary hemorrhage			

### **Report :**

The specimen submitted consists of 3 tissue fragments measuring up to 0.3 x 0.3 x 0.2 cm in size, fixed in formalin.

Grossly, they are grayish and elastic.

All for section Jar 0

Microscopically, it shows lung tissue with heart failure cells in the alveoli. One of the tissue fragments shows the presence of adenocarcinoma cells with TTF-1 and CK7 expression. These cells are negative for GATA-3. The morphology and ICH stain results suggest primary lung adenocarcinoma.

Malignancy confirmation: Dr. CH Cheng & Dr. YC Chen

**2022/12/22** Discharged

medication: Sodicon

**2022/12/29** CM OPD, arranged lung function test and FDG-PET/CT(whole body)

FDG-PET/CT showed : increased FDG uptake

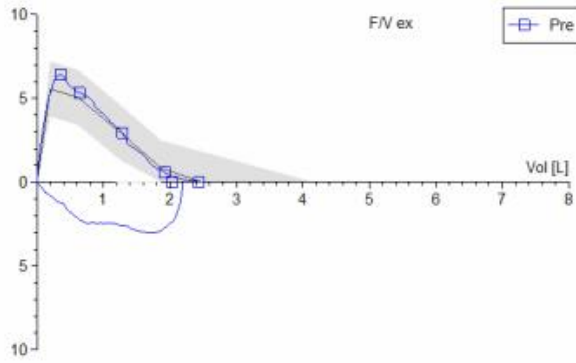
in the left lower lobe of the lung, 4.4

cm x 3.9 cm x

4.0cm and inferior angle of right scapula

2022/12/29 Lung function test

FEV1/FVC > 80%



	Pred	Best	%(Pre/Pred)
FRCpleth	1.22	2.22	182.61
RV	1.67	1.77	106.05
TLC	5.20	4.28	82.18
RV % TLC	38.00	41.50	109.20
VC MAX	2.49	2.57	103.29
FVC	2.49	2.44	97.98
FEV 1	2.07	2.03	98.01
FEV 1 % FVC		83.10	
PEF	5.55	6.41	115.42
MEF 75	5.04	5.30	105.17
MEF 50	2.98	2.93	98.45
MEF 25	0.85	0.58	68.59
MMEF 75/25	2.60	1.90	73.00
FEF 200-1200		4.81	
PIF		3.05	
FIV 1		2.07	
FIF 50		2.44	
MVV	90.13	84.27	93.50
TIME MVV		11.62	
ATS error code		0	
Measurement date		22-12-29	
Measurement time		10:05	

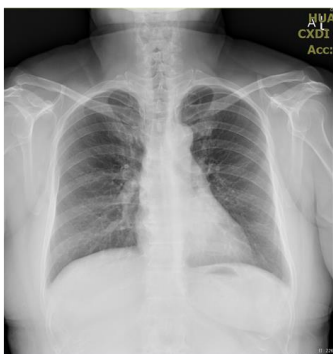2023/01/09 admitted to CS ward on 2023/1/9 for surgery

2023/01/10 Uniportal VATS LLL lobectomy and mediastinal LNs dissection

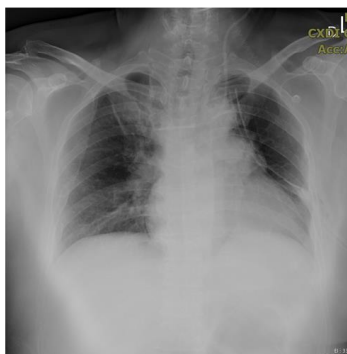2023/01/14

檢體名稱	報告日期	檢驗項目	檢驗報告	單位	標準(低)	標準(高)
Blood	1120110	CEA	16.1	ng/mL	0	3.0

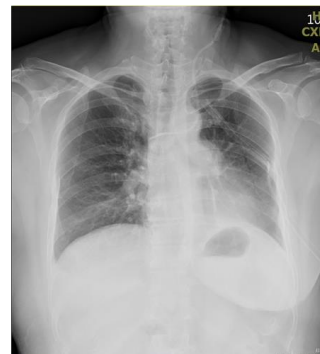2023/01/09 CXR



2023/01/10 CXR



2023/01/12 CXR



**2023/01/09** admitted to CS ward on 2023/1/9 for surgery

**2023/01/10** Uniportal VATS LLL lobectomy and mediastinal LNs dissection

**2023/01/14** Discharged on 2023/01/14 with OPD follow up.

2023/01/16 Pathology report

Pathologic Stage:

(1) Primary Tumor (pT): pT2b (> 4cm but <= 5cm)

(2) Regional Lymph Nodes (pN): pN0: No regional lymph node metastasis.

Immunohistochemical stain shows p63 (-) and TTF-1 (+).

### OPD medication

Giotrif (Afatinib) 30mg/tab start from 2023/01/30

CXR and CT follow up

檢體名稱	報告日期	檢驗項目	檢驗報告	單位	標準(低)	標準(高)
Paraffin ti	1120120	EGFR	A point mutatio			not dete

### Final diagnosis

LLL lung adenocarcinoma, pT2bN0 cM1b, stage IVA

- TTF-1 (+), p63 (-), GATA3 (-), CK7 (+), ROS1 (-), ALK/D5F3 (-) and PDL1 <1% in tumor cells
- s/p uniportal VATS LLL lobectomy and mediastinal LNs dissection

Breast cancer, pT2N0M0, stage IIA

HTN, type 2 DM, insomnia