

花蓮慈濟醫院影像診療研討會

日期：2025 年 11 月 7 日
時間：08：00 - 09：00
地點：花蓮慈濟醫院大愛七樓 702 教室

時間	題目	主講人
08:00-09:00	個案討論	吳孟謙

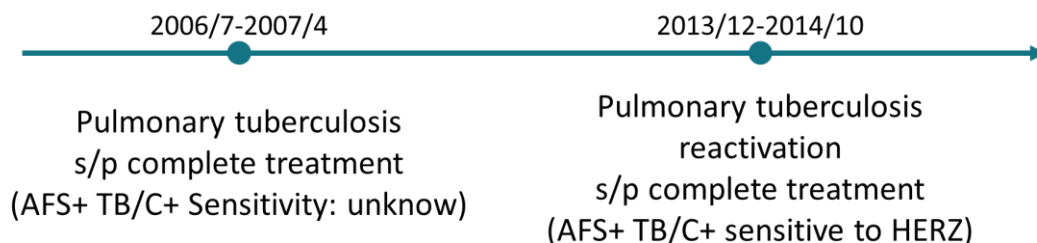
Patient's profile

- 田 O 男，U121205XXX
- 43 y/o male
- Occupation: Nil
- Admission date: 2023/03/08
- CC: cough frequency for a month

Present Illness

- History of 2 times of TB infection (2006/7-2007/4), (2013/12-2014/10)
- Cough frequency for one month with thick green sputum
- Body weight decrease 4-5 Kg and poor appetite
- No fever, chilliness or other discomfort.
- 3/7 AFS(+), MGIT(+) at 秀林鄉衛生所
- Transferred to our CM OPD -> MTBc positive(10000000), RIFR negative
- Admitted to our isolated ward

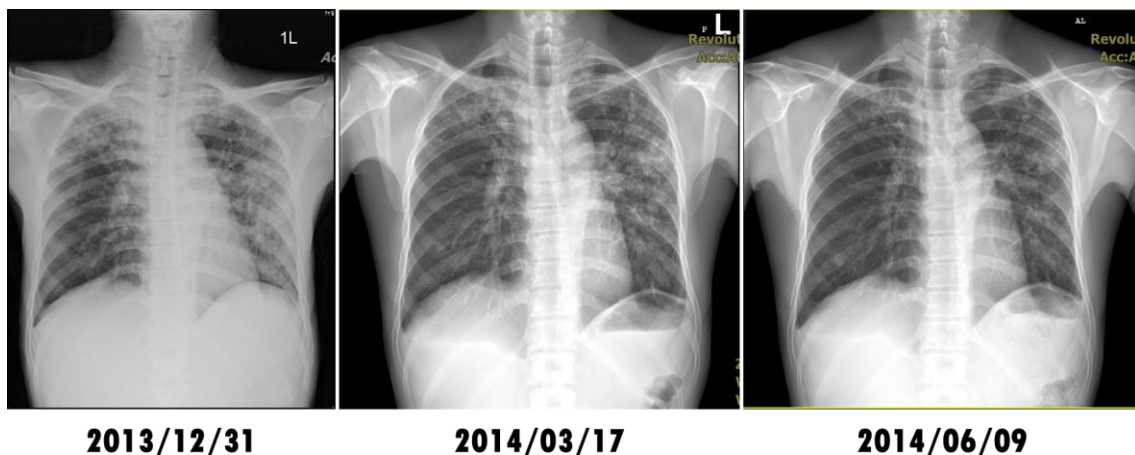
Past History



Other relative history

No Diabetes, HTN, Malignancy
No Immunocompromise
No use of Glucocorticoid
No history of organ transplantation

CXR follow up



Past History

- **Social history:**
 - Heavy smoking for 15 pack-years
 - alcohol for 30 years (quit)
 - betel nuts for 10 years
 - Live in 秀林鄉
 - Occupation: 綁鐵工人
- **Surgical history:** nil
- **Family history:**
 - Mother has history of HTN
 - No family member has history of Tuberculosis

Lab Data 0308

03/07 09:46

檢驗項目	檢驗報告	單位
AFB Stain		
AFB Stain	Was Found.4+	
WBC		/LPF
Ep.Cell		/LPF

檢驗項目	檢驗報告	單位
MTBc-RIFR		CFU/mL
MTBc	Positive(100000	CFU/mL
MTBc-RIFR	Negative	

03/08 19:18

檢驗項目	檢驗報告	單位
AFB Stain		
AFB Stain	Was Found.3+	
WBC		/LPF
Ep.Cell		/LPF

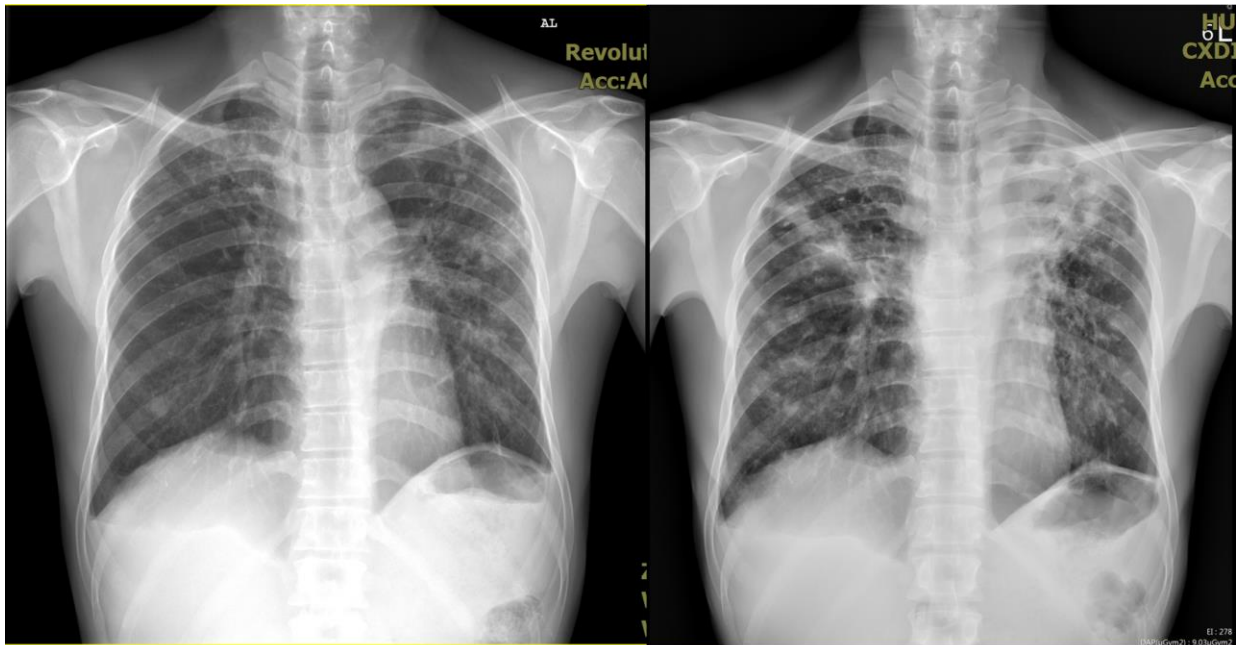
檢驗項目	檢驗報告
HBs Ag	
HBs Ag	Nonreactive
S/CO	0.36
HIV Ag/Ab	
HIV Ag/Ab	Nonreactive
S/CO	0.06
Anti HCV	
Anti HCV	Nonreactive
S/CO	0.06

CBC & PLT		
WBC	15.77	*10 ³ /ul
RBC	3.58	*10 ⁶ /ul
Hb	11.3	g/dL
Ht	34.2	%
MCV	95.5	fL
MCH	31.6	pg
MCHC	33.0	%
PLT	306	*10 ³ /ul
RDW-CV	13.6	%

WBC DC		
N. Band		%
N. Seg	74.3	%
Lym.	13.9	%
Mono.	10.8	%
Eosin.	0.5	%
Baso.	0.5	%
Aty. Lym.		%
N. RBC		/100WBC
Meta.		%
Myelo.		%
Promeylo.		%
Blast		%
Monocytoid		%

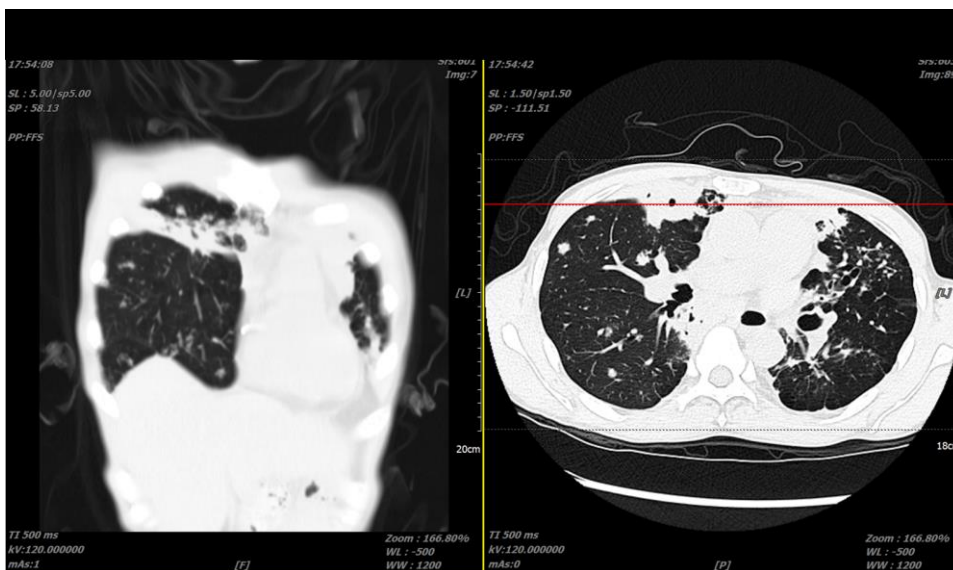Liver		
ALT	51	IU/L
AST	51	U/L
ALT	38	U/L
TBI	0.3	mg/dL
DBI	0.1	mg/dL
LDH	212	U/L
TP	6.2	g/dL
ALB-BCG	3.6	g/dL
GLO	2.6	g/dL
A/G ratio	1.4	

Kidney		
UA	4.2	mg/dL
BUN	7	mg/dL
CRE	0.62	mg/dL
eGFR	149.79	mL/min
Na	137	mmol/L
K	3.7	mmol/L
Ca	2.23	mmol/L
Mg	1.6	mg/dL
CRP	2.20	mg/dL



2014/06/09

2023/03/08



Tentative Diagnosis

- #1 Recurrence Pulmonary TB infection
- #PHx: 2 series of TB infection (2006/7-2007/4), (2023/12-2014/10)

Physical Examinations

- **General appearance: Weakness**
- **Height: 167cm, BW: 50.6, BMI: 18.143**
- **Vital signs: TRP: 36.9/119/19, BP: 132/86 mmHg, SpO2 93% under RA**
- **Consciousness: clear and oriented, E4V5M6**
- **Skin: grossly intact. no scaling.**
- **HEENT: pink conjunctiva, anicteric sclera ,Jugular vein engorgement(-), no carotid bruit, no lymphadenopathy**
- **Chest: symmetric expansion, bilateral rhonchi, without accessory muscle retraction**
- **Heart: regular heart beat without murmur.**
- **Abdomen: Grossly normal**
- **Kidney: No CV angle knocking pain**

Treatment Course

03/08-13 CM isolated ward

• Rifinah 150 (Rifampicin 150 mg & Isoniazid 100 mg)	ST	3 tab
• AkuriT- 4 (Rifampicin 150 mg, Isoniazid 75mg, Ethambutol 275mg, Pyrazinamide 400mg) /tab	QDAC	3 tab
• Acetin (粉) 1.5g/pk (Acetylcysteine 100mg/pk)	TID	1 pk
• 維他命 B6 (Pyridoxine HCl) 50mg/tab	BID	1 tab

03/08-13 CM isolated ward

AFB stain	Sputum
112/03/07	+
112/03/08	+
112/03/09	+
112/03/09	+
112/03/10	+
112/03/10	+

3 / 13 LAB follow

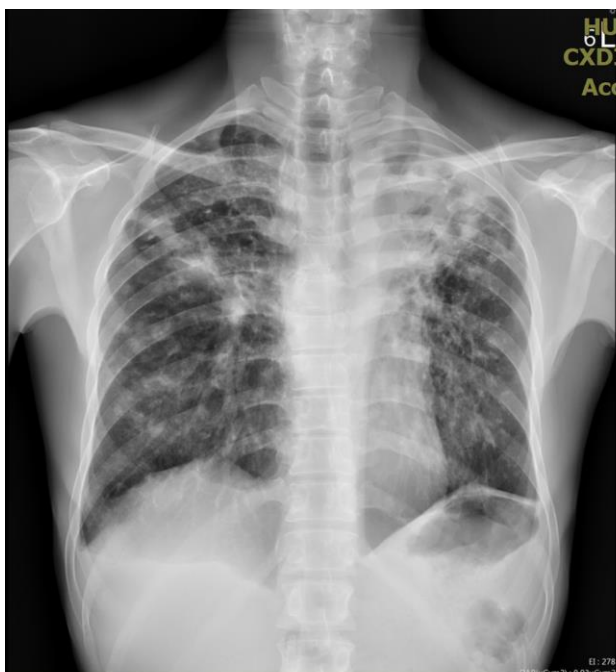CBC & PLT		
WBC	8.81	*10 ³ /ul
RBC	3.71	*10 ⁶ /ul
Hb	11.5	g/dL
Ht	35.1	%
MCV	94.6	fL
MCH	31.0	pg
MCHC	32.8	%
PLT	433	*10 ³ /ul
RDW-CV	13.1	%

Liver		
AST	21	U/L
ALT	22	U/L
TBI	0.3	mg/dL
DBI	0.1	mg/dL
TP	6.2	g/dL
ALB-BCG	3.6	g/dL
GLO	2.6	g/dL
A/G ratio	1.4	
Kidney		
UA	8.5	mg/dL
BUN	11	mg/dL
CRE	0.52	mg/dL
eGFR	183.49	mL/min
Na	135	mmol/L
K	5.1	mmol/L
Mg	1.8	mg/dL
CRP	0.62	mg/dL

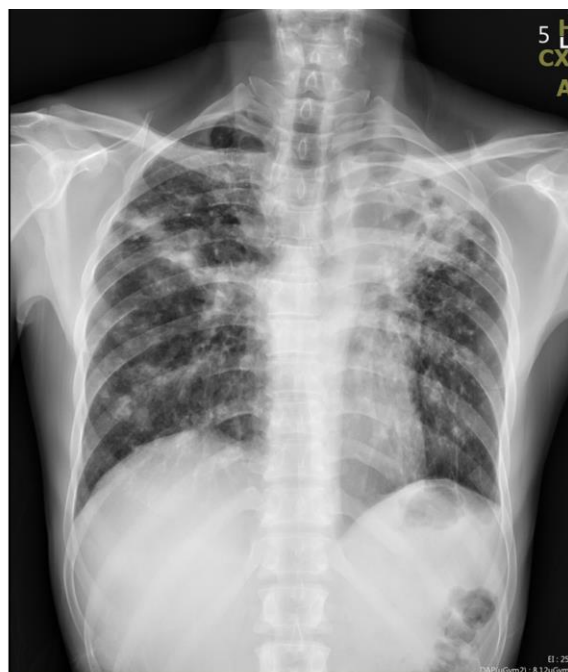03/13-20 CM isolated ward

• AkuriT- 4 (Rifampicin 150 mg, Isoniazid 75mg, Ethambutol 275mg, Pyrazinamide 400mg) /tab	QDAC	3 tab
--	------	-------

<ul style="list-style-type: none"> ● Acetin (粉) 1.5g/pk (Acetylcysteine 100mg/pk) 	TID	1 pk
<ul style="list-style-type: none"> ● 維他命 B6 (Pyridoxine HCl) 50mg/tab 	BID	1 tab
<ul style="list-style-type: none"> ● EURICON 50mg/tab (Benzbromarone) 	BID	1 tab



2023/03/08



2023/03/20

03/20 CM isolated ward

CBC & PLT		
WBC	11.50	*10 ³ /ul
RBC	3.43	*10 ⁶ /ul
Hb	10.8	g/dL
Ht	32.2	%
MCV	93.9	fL
MCH	31.5	pg
MCHC	33.5	%
PLT	438	*10 ³ /ul
RDW-CV	12.6	%

3/20 LAB follow

WBC DC		
N. Band		%
N. Seg	72.4	%
Lym.	14.5	%
Mono.	8.2	%
Eosin.	3.8	%
Baso.	1.1	%
Aty. Lym.		%
N. RBC		/100WBC
Meta.		%
Myelo.		%
Promeylo.		%
Blast		%
Monocytoid		%

Liver		
AST	20	U/L
ALT	16	U/L
TBI	0.2	mg/dL
DBI	0.1	mg/dL
Kidney		
BUN	15	mg/dL
CRE	0.62	mg/dL
eGFR	149.79	mL/min
Na	139	mmol/L
K	4.4	mmol/L
Mg	1.7	mg/dL

Medications at Discharge

- **AkuriT- 4 (Rifampicin 150 mg, Isoniazid 75mg, Ethambutol 275mg, Pyrazinamide 400mg) /tab** **QDAC** **3 tab**
- **Acetin (粉) 1.5g/pk (Acetylcysteine 100mg/pk)** **TID** **1 pk**
- **維他命B6 (Pyridoxine HCl) 50mg/tab** **BID** **1 tab**
- **EURICON 50mg/tab (Benzbromarone)** **BID** **1 tab**

Final Diagnosis

Recurrence Pulmonary TB infection s/p AkuriT- 4 therapy for 2 weeks