

# 花蓮慈濟醫院影像診療研討會

日期：2024年11月1日  
時間：08:00 - 09:00  
地點：花蓮慈濟醫院大愛七樓 702 教室

時間	題目	主講人
08:00-09:00	個案討論	曾瀨萱

## Patient Profile

- 63 y/o woman
- Admssion date: 2022/12/15
- Underlying disease: hypertension
- CC: dry cough and body weight loss in recent weeks

## Presenting Illness

- In recent weeks:
  - Dry cough without sputum
  - good appetite but weight loss of about 3-5kg
- 2022/12/14: chest OPD for help
- 2022/12/15: Admssion

## Past History

- Medical history:
  - HTN under Amlodipine 5mg & Olmesartan 20mg QD control
  - 2021/11:

Right upper ureteral stones → moderate hydronephrosis

Right renal stones, Right renal cyst

- Surgical history:
  - 2021/11/11: Right PCN, URS-SM
  - 2021/12/22: Right renal cyst aspiration
- Social history:
  - smoking: nil
  - alcohol: nil
  - betel nuts: nil
- Family history:
  - Her father: TB

**Physical Examinations**

**Height: 154cm, BW: 67.5kg , BMI: 28.461**

**Vital signs: TPR: 36.2/64/16, BP: 117/59 mmHg**

**Consciousness: clear and oriented, E4V5M6**

**HEENT: pink conjunctiva, anicteric sclera**

**Neck: no lymphadenopathy, no jugular vein engorgement**

**Chest: symmetric expansion, bilateral vesicular sounds**

**Heart: regular heart beat, no murmur**

**Abdomen: normoactive bowel sounds, no tenderness, no rebounding pain, no surgical scar, no flank pain**

**Extremities: no pitting edema**

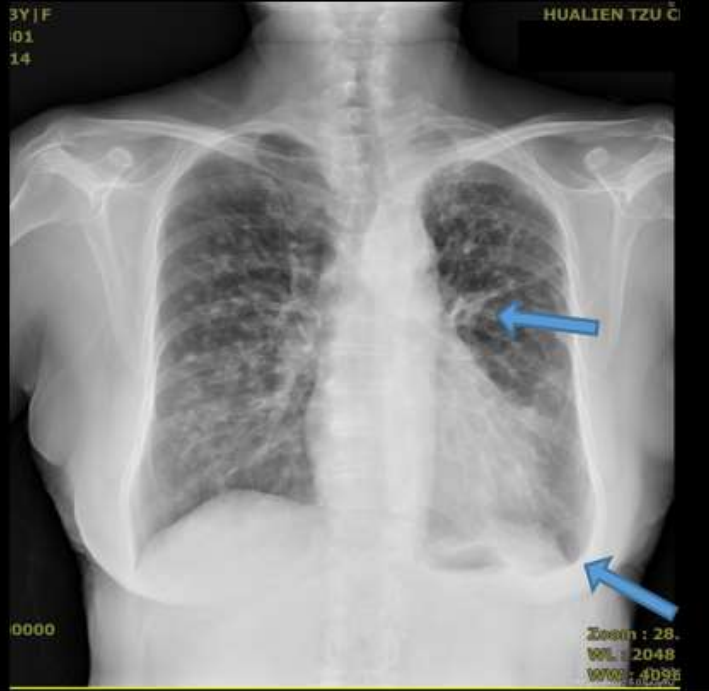
**Special finding: nil**

**Lab Data: 12/14**

檢驗項目	檢驗報告	單位	標準(低)	標準(高)
<b>CBC &amp; PLT</b>				
WBC	6.54	*10 <sup>3</sup> /ul	3.50	11.00
RBC	<b>3.88</b>	*10 <sup>6</sup> /ul	4.00	5.20
Hb	<b>11.5</b>	g/dL	12.0	16.0
Ht	<b>35.3</b>	%	36.0	46.0
MCV	91.0	fL	80.0	100.0
MCH	29.6	pg	26.0	34.0
MCHC	32.6	%	31.0	37.0
PLT	290	*10 <sup>3</sup> /ul	150	400
RDW-CV	12.6	%	11.5	14.5
<b>WBC DC</b>				
N.band		%	0.0	3.0
N.seg.	<b>76.9</b>	%	40.0	75.0
Lym.	<b>17.0</b>	%	20	45
Mono.	5.0	%	2.0	10.0
Eosin.	<b>0.5</b>	%	1.0	6.0
Baso.	0.6	%	0.0	1.0

檢驗項目	檢驗報告	單位	標準(低)	標準(高)	
AST (GOT)	<b>12</b>	U/L	13	39	
ALT (GPT)	10	U/L	7	52	
LDH	<b>134</b>	U/L	140	271	
BUN	21	ng/dL	7	25	
CRE					
CRE	0.93	ng/dL	0.60	1.20	
eGFR	<b>64.72</b>	mL/min	90		
Na	142	mmol/L	136	145	
K	4.8	mmol/L	3.5	5.1	
Ca	2.38	mmol/L	2.20	2.65	
Mg	2.1	ng/dL	1.9	2.7	
報告日期	檢驗項目	檢驗報告	單位	標準(低)	標準(高)
1111215	CEA	<b>58.3</b>	ng/mL	0	3.0
	CA 15-3	20.5	U/mL		23.5
1111214	SCC	1.0	ng/mL		1.5
1111215	CA 125	12.2	U/mL		35.0
	CA 19-9	1.6	U/mL		35.0

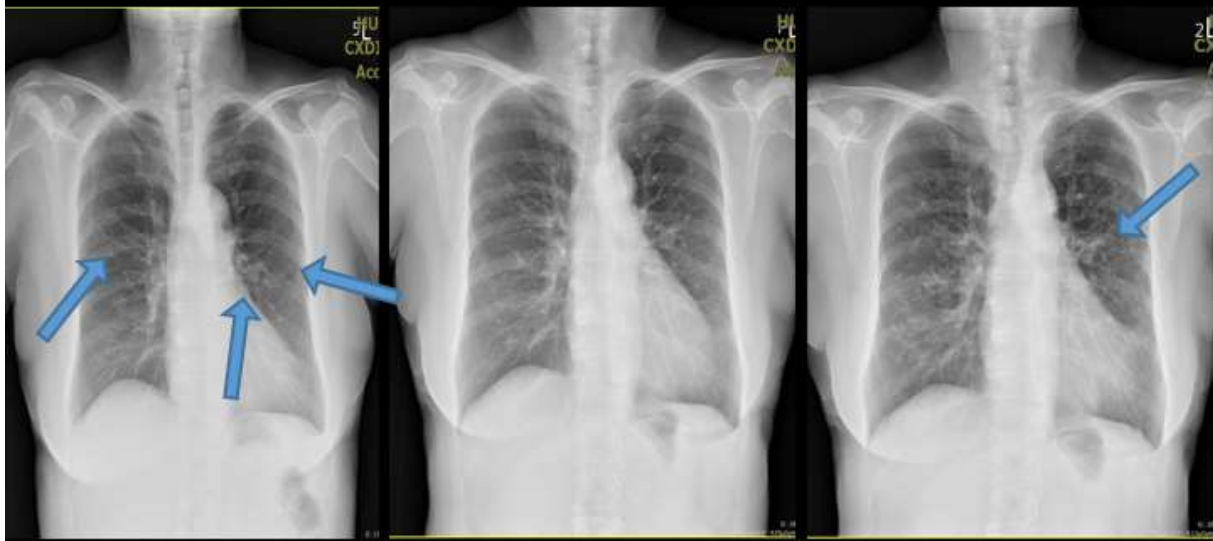2022/12/14



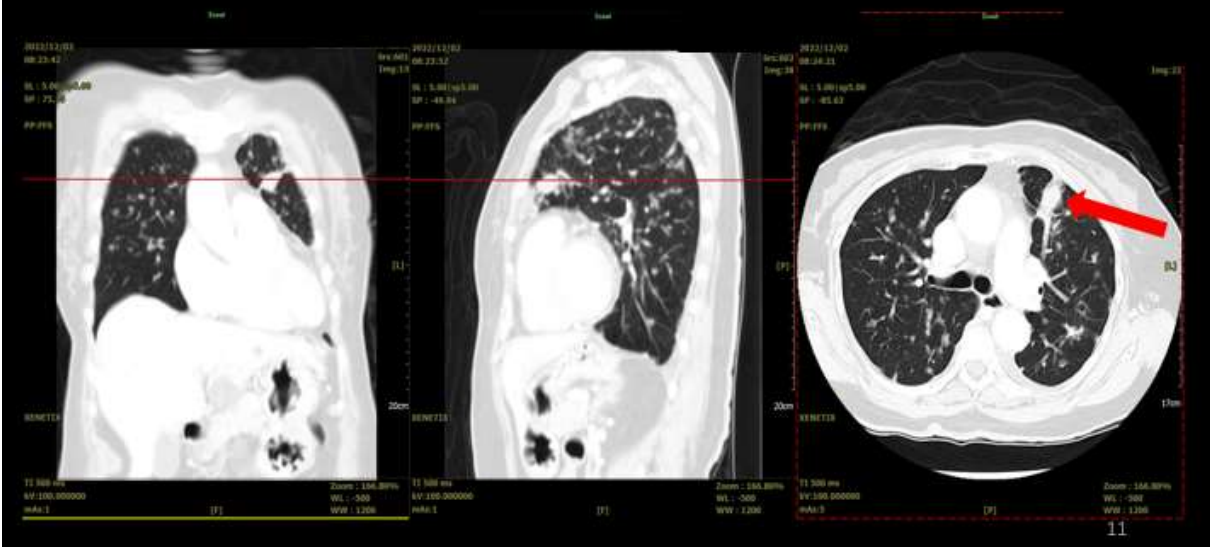
2021/11/09

2022/01/19

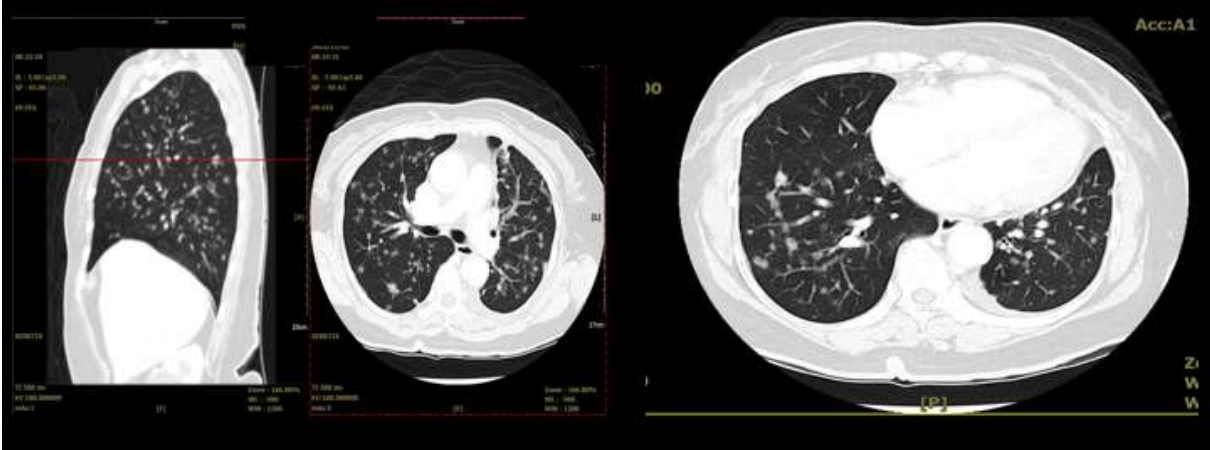2022/08/04



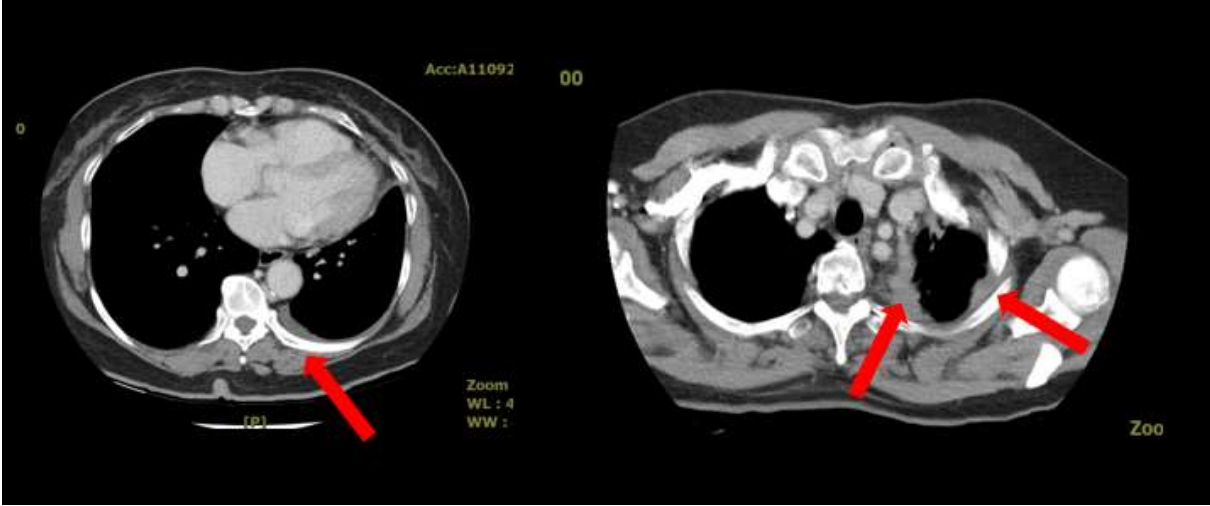
2022/12/02



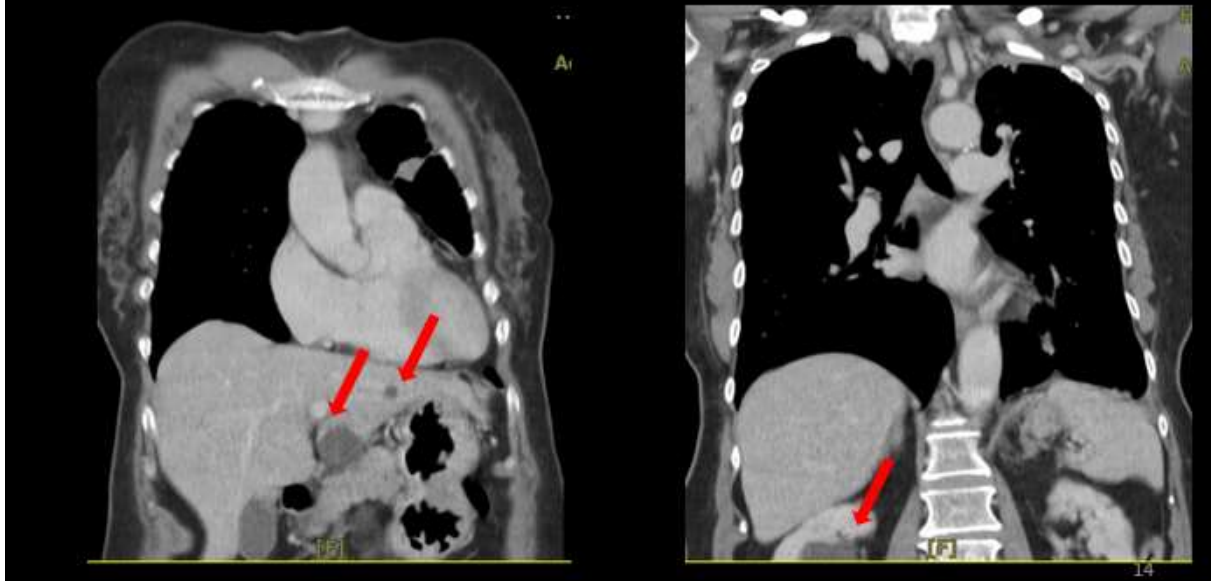
2022/12/02



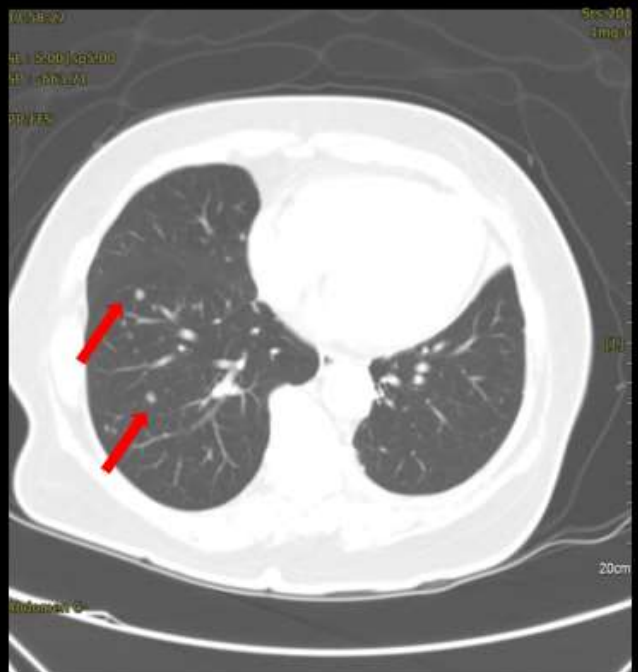
2022/12/02



2022/12/02



2021/11/09  
CT abdomen to pelvis



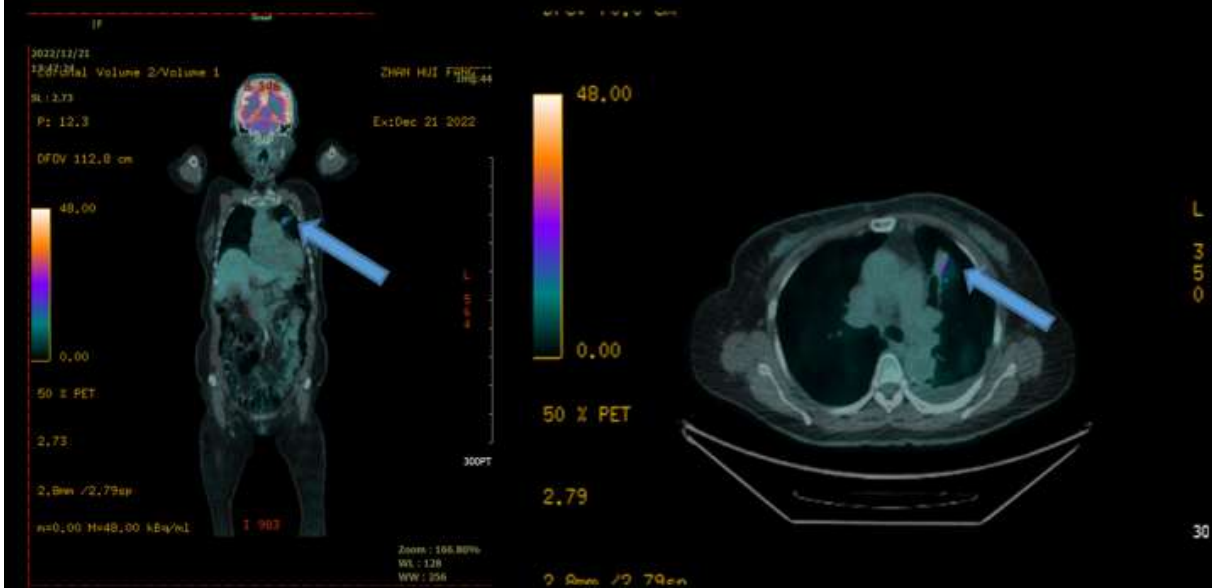
### Treatment Course

12/16 Chest Ward

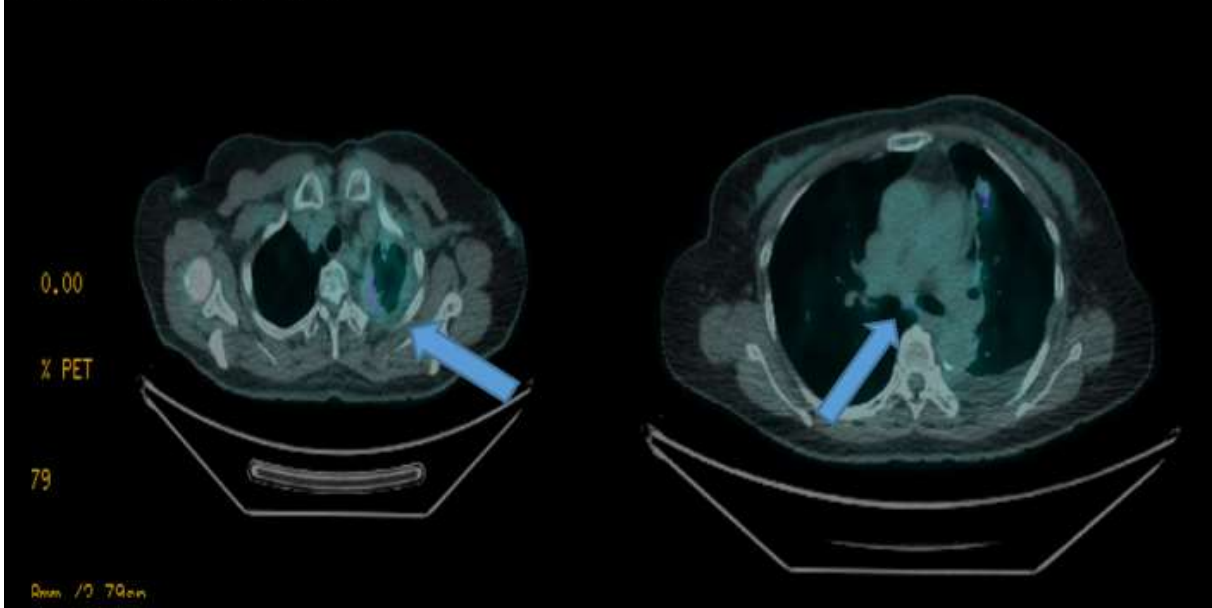
- EBUS/ Brochoscopy
  - LB3b bronchial cytology and cellblock:
    - Positive for adenocarcinoma
  - Bronchial brushing cytology:
    - Positive for adenocarcinoma
  - no endobronchial lesions over left bronchial trees



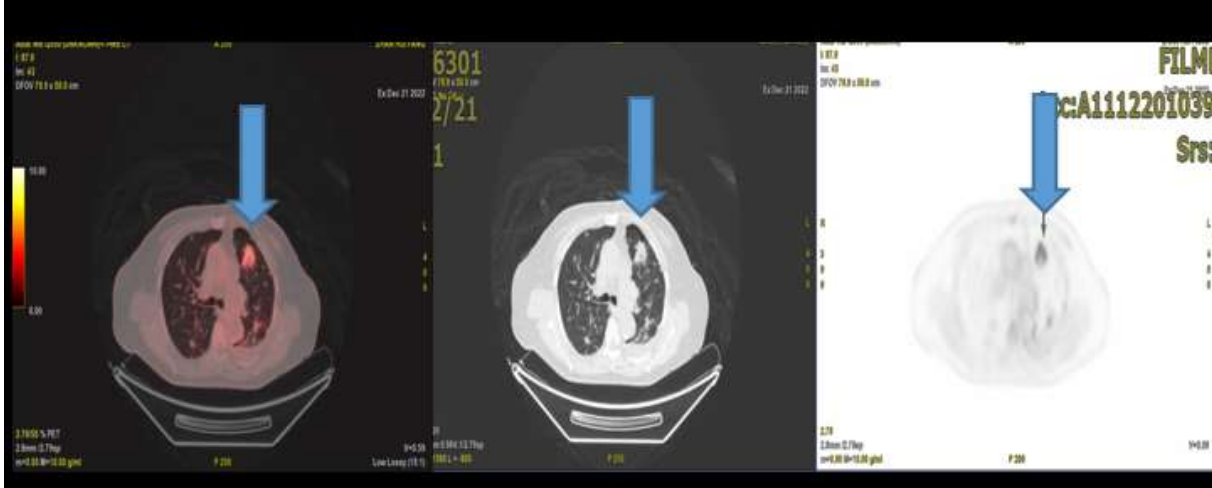
# PET 2022/12/16



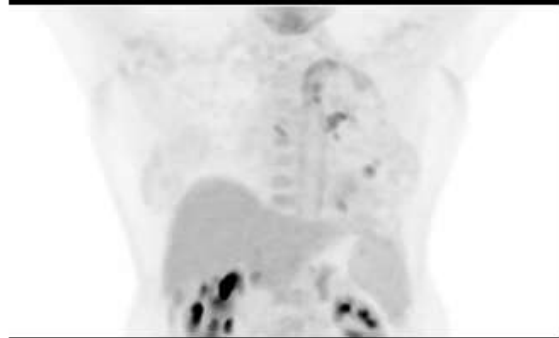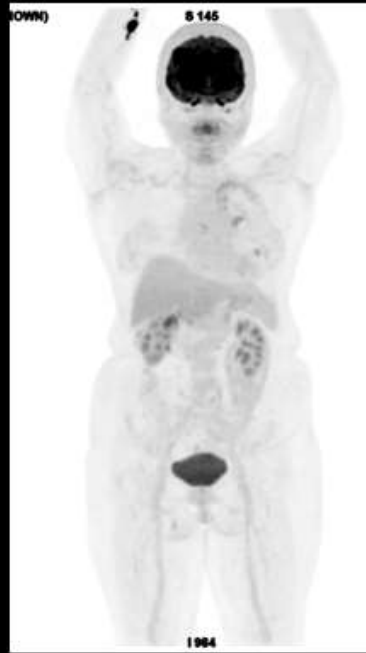
# PET 2022/12/21



# PET 2022/12/21



**PET**  
**2022/12/21**



24

### **Treatment Course**

**12/22 Discharge & OPD follow-up**

**12/23**

- **cfDNA, paraffin tissue EGFR : mutation**
  - **deletion at exon 19 of EGFR gene**

### **Medications at 12/28 OPD**

- **Afatinib 30mg/tab QDAC**

### **Final Diagnosis**

**# LUL lung adenocarcinoma, EGFR Del19, stage 4A, cT4N2M1a (with malignant pleural effusion)**