

108 年胸部影像判讀繼續教育課程(北區)

主辦單位：重症醫學專科醫師聯合甄審委員會

承辦單位：台灣胸腔暨重症加護醫學會

日期：108 年 8 月 11 日(星期日) 08:00~17:00

地點：內湖三軍總醫院 B1 第三演講廳(台北市內湖區成功路二段 325 號)

課程規劃：彭忠衍主任

學分：聯甄重症認證 8 學分

肺部感染症及呼吸道疾病 之影像判讀

唐士恩 醫師

Shih-En Tang MD PhD

三軍總醫院 胸腔內科

Aug 11 2019 15:20-16:10

2007

- 戰勝胸腔專科醫師影像考試技巧
- 1. Answers: 答案: 歷年考題答案
- 2. Locations: 位置與答案的連結
- 3. Practice: 演習! 不斷練習!

臨床胸腔醫學

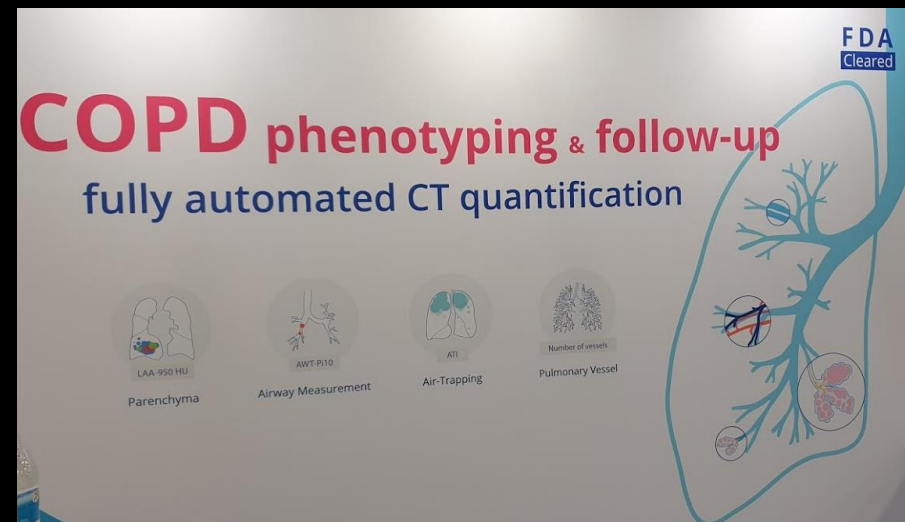
- 不是考試!
- 臨床推理!
- 鑑別診斷!
- 臨床經驗累積!
- 創新與突破!

肺癌醫學發展

- 胸腔X光片 (CXR)
- 電腦斷層檢查 (CT)
- 正子攝影檢查 (PET)
- 精準醫學發展 (Precision Medicine)

肺炎與呼吸道疾病的醫學發展

- CxR
- CT chest
- Bronchoscopy
- Lung Biopsy
- PET (Infection vs inflammation vs neoplasm)
- Culture -> PCR -> Array
- MRI (Ventilation/Perfusion)
- AI (Artificial Intelligence)



生命無價

基因療法掀起藥業大變革

文/陳苑均(鑽石生技投資分析室研究員)

發表於 2019-08-03 作者 新聞中心

- 基因療法大熱潮來臨。
- 今年5月24日，諾華（Novartis）的脊髓性肌肉萎縮症新藥 ZOLGENSMA，被美國FDA核准上市！
- 210萬美元的定價震撼市場，一舉成為史上最貴藥物。
- 三周後，另一基因治療藥企Bluebird Bio宣布，旗下治療β地中海貧血新藥-ZYNTEGLO，獲歐盟委員會的有條件上市許可，定價為180萬美元，接連驚人的高價，背後代表一場藥業變革正在展開。

2019 ATS Artificial Intelligence

■ 重要一場演講!

K7 WHAT SHOULD PULMONOLOGISTS KNOW ABOUT ARTIFICIAL INTELLIGENCE AND MACHINE LEARNING?

8:00 a.m.-8:45 a.m.

Speaker: Michael D. Howell, MD, MPH, Mountainview, CA

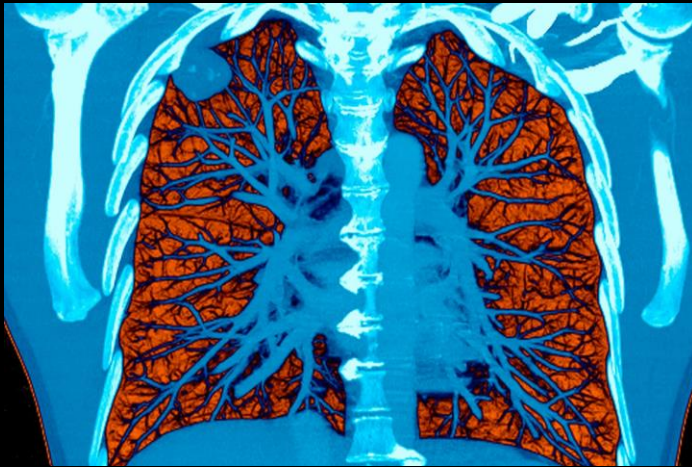WEDNESDAY • MAY 22 2019



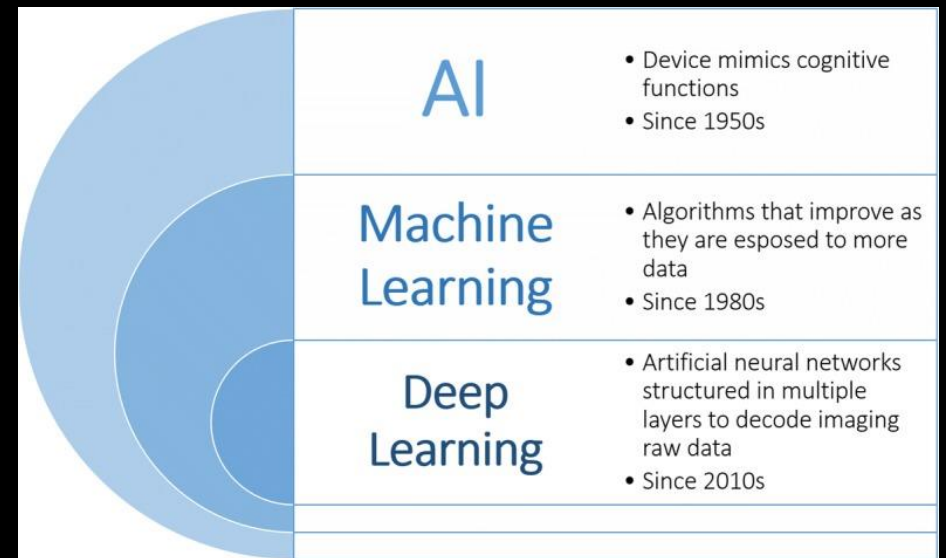
The New York Times

A.I. Took a Test to Detect Lung Cancer. It Got an A.

Artificial intelligence may help doctors make more accurate readings of CT scans used to screen for lung cancer.



Artificial intelligence in medical imaging: threat or opportunity?



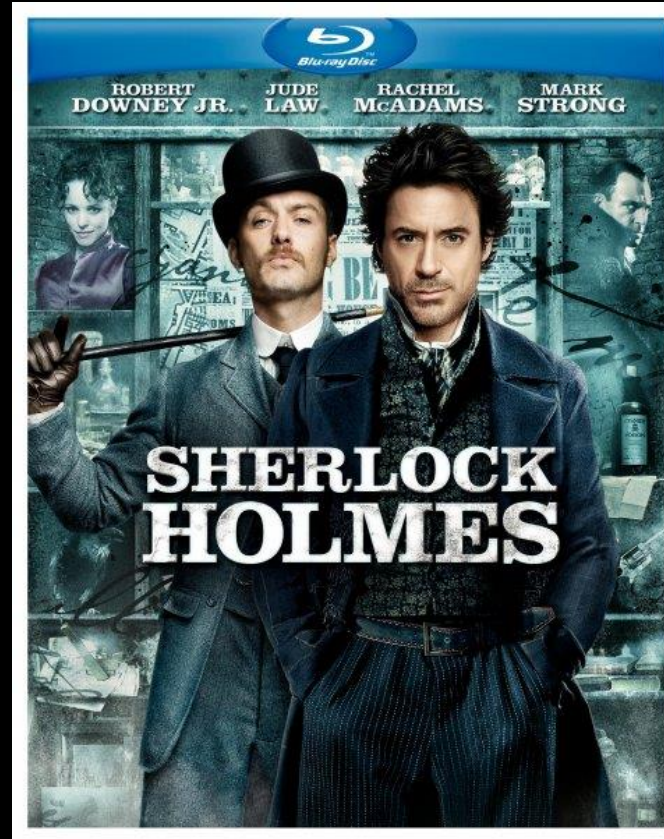
Eur Radiol Exp. 2018 Dec; 2: 35.

A version of this article appears in print on **May 21, 2019**, Section A, Page 17 of the New York edition with the headline: A.I. Took a Test to Detect Lung Cancer. It Got an A..




醫師角色

- History taking
- Physical examination
- Laboratory examination
- Radiographic examination
- Differential diagnosis
- “human” “culture” “family”!



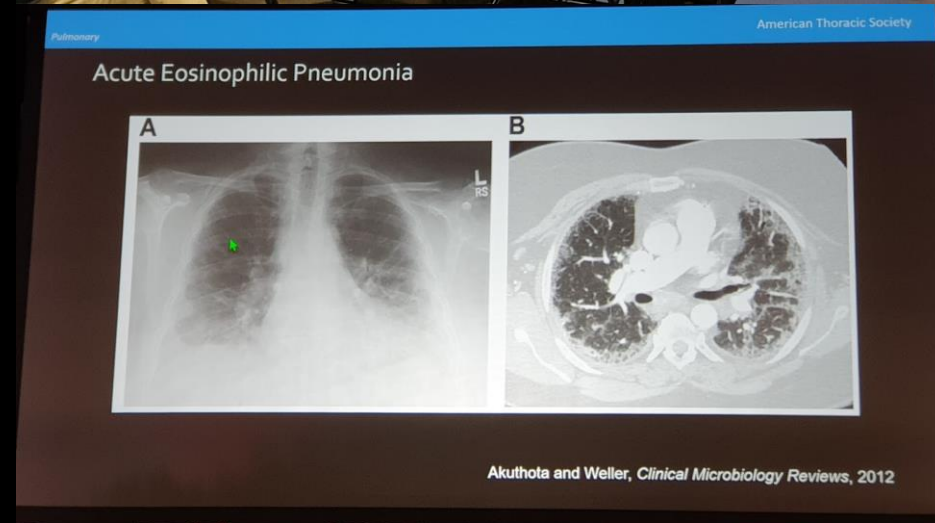
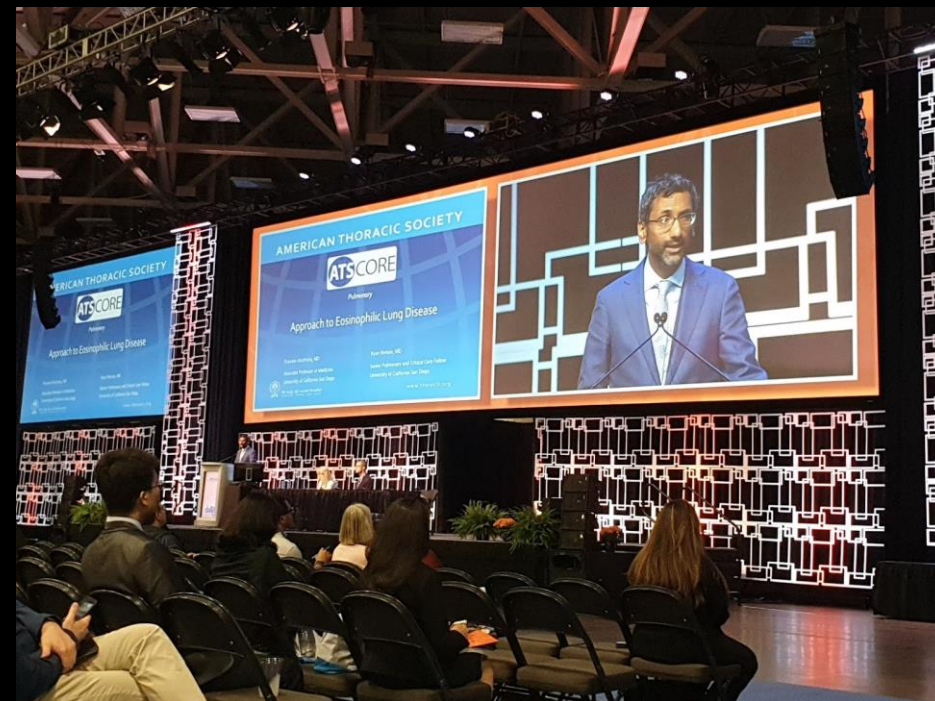三總機器人

2019 ATS



團結 & 合作

07:16:07



12

2019 ATS POSTGRADUATE COURSE

Radiologist

- PG5 THORACIC IMAGING FOR PULMONARY MEDICINE AND CRITICAL CARE PRACTITIONERS
- Pulmonary Infections (L.H. Ketai, MD, Albuquerque, NM)
- Large Airways Diseases (S. Rossi, MD, Buenos Aires, Argentina)
- Small Airways Diseases (T.S. Henry, MD, San Francisco, CA)

2019 ATS POSTGRADUATE COURSE

Radiologist

■ Pulmonary Infections
(L.H. Ketai, MD, Albuquerque, NM)

■ Large Airways Diseases
(S. Rossi, MD, Buenos Aires, Argentina)

■ Small Airways Diseases
(T.S. Henry, MD, San Francisco, CA)

Loren Ketai MD.
University of New Mexico
Department of Radiology

Santiago E Rossi MD
santirossi@cdrossi.com
Centro Rossi - Hospital Cetrángolo
Buenos Aires, Argentina

Travis S Henry, MD
Associate Professor of Clinical Radiology
Cardiac and Pulmonary Imaging Section
Director, Cardiothoracic Imaging Fellowship
University of California, San Francisco

胸部 X-ray 影像判讀原則與常用徵象	蕭逸函醫師 臺北榮民總醫院胸腔部
瀰漫性間質肺病之影像判讀	王鶴健教授 臺大醫院胸腔部
Coffee break	
肺實質化病變與肺塌陷	吳世偉醫師 三軍總醫院胸腔內科
肺結節與腫瘤判讀	賴信良主任 臺北榮民總醫院胸腔部
Lunch	
胸壁、肋膜及縱膈腔病變	張山岳醫師 三軍總醫院胸腔內科
空洞性病變與囊泡病變	湯硯翔醫師 馬偕紀念醫院胸腔內科
Coffee break	
肺部感染症及呼吸道疾病之影像判讀	唐士恩醫師 三軍總醫院胸腔內科
急重症與心血管影像判讀	郭立國主任 馬偕紀念醫院胸腔內科

■ Signs

■ DILD

■ Atelectasis

■ Pulmonary Nodule

■ Pleural

■ Cavity/Cyst

■ Infection

■ ICU/Cardiovascular disease

2019/08/10 (50 min): Summary

- Pulmonary Infections

(L.H. Ketai, MD, Albuquerque, NM)

- Large Airways Diseases

(S. Rossi, MD, Buenos Aires, Argentina)

- Small Airways Diseases

(T.S. Henry, MD, San Francisco, CA)

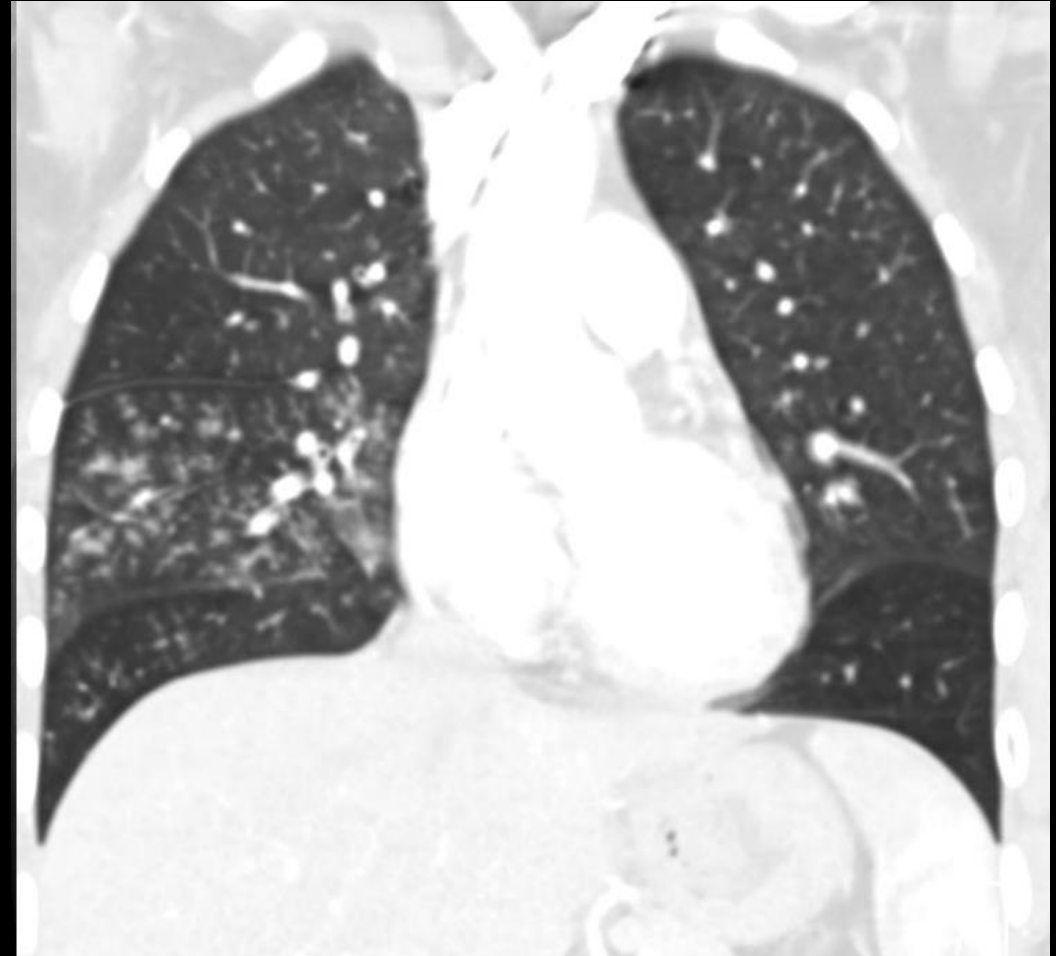
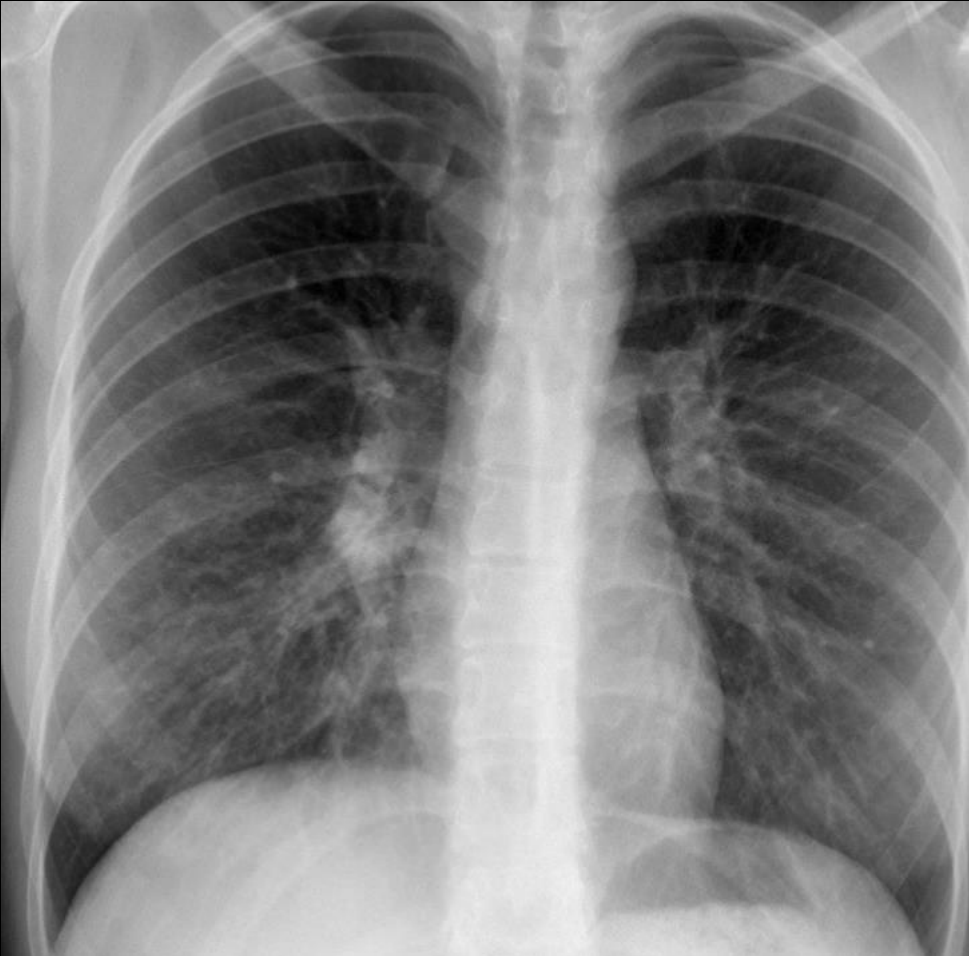
Pulmonary Infections

- (1) Detection of infection: CxR -> CT chest
- (2) Differentiation: infections? Non-infectious lung disease?
- (3) Infection: complications
- (4) Specific pathogens: Chronic fibrocavitary disease

Pulmonary Infections


- (1) Detection of infection: CxR -> CT chest
- (2) Differentiation: infections? Non-infectious lung disease?
- (3) Infection: complications
- (4) Specific pathogens: Chronic fibrocavitary disease

Occult Pneumonia

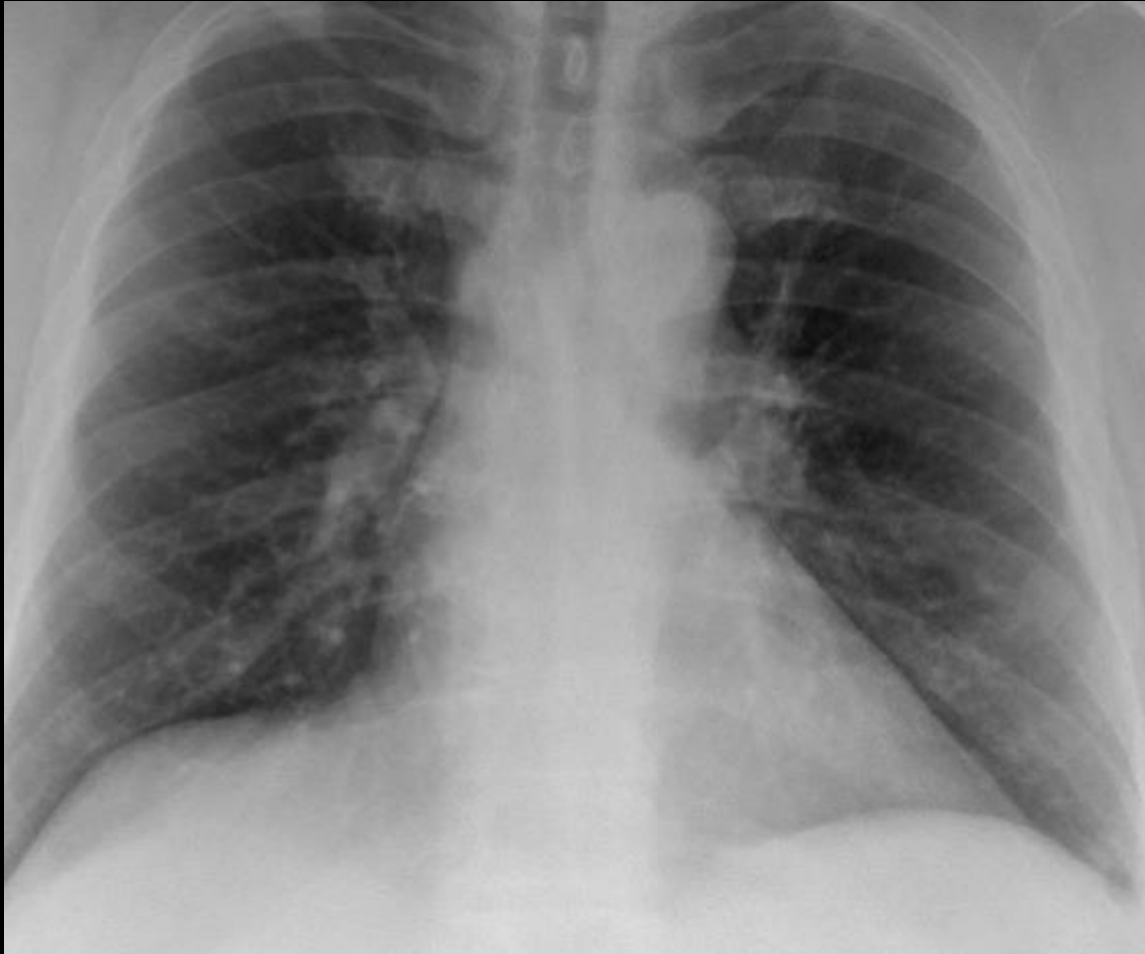


Early Chest Computed Tomography Scan to Assist Diagnosis and Guide Treatment Decision for Suspected Community-acquired Pneumonia

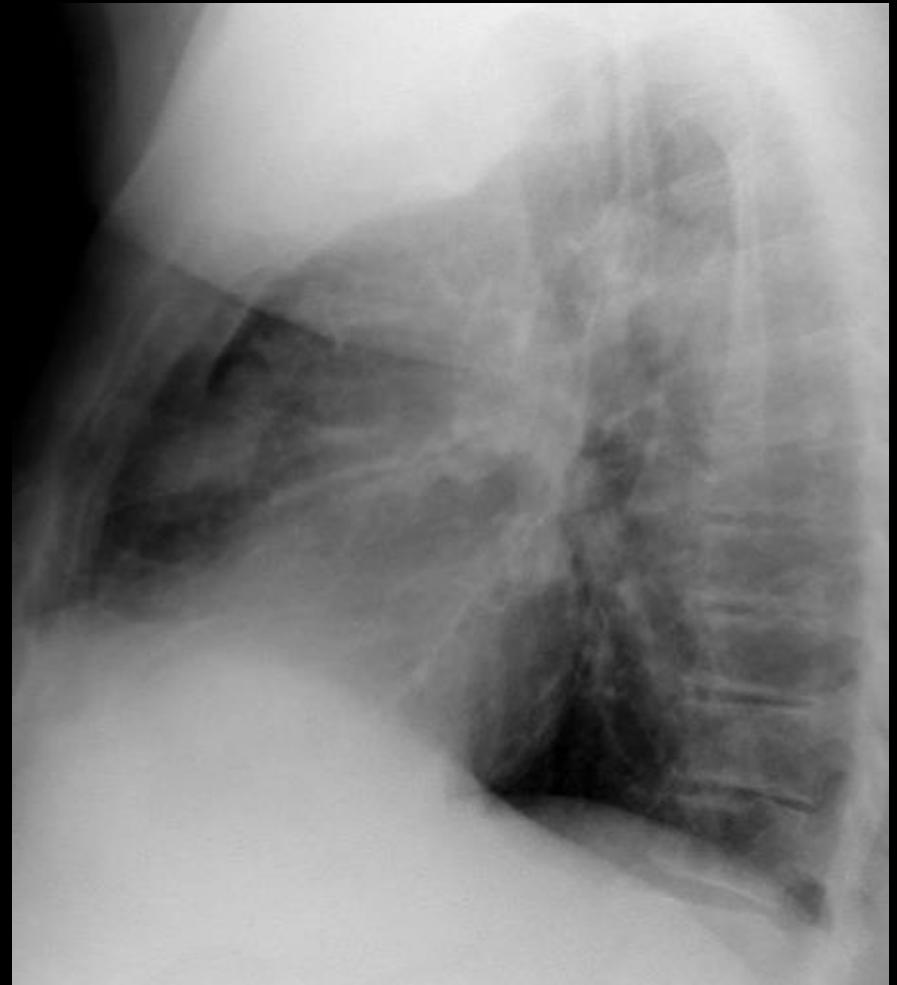
- Claessens 2015, AJRCCM
- CxR positive -> CT negative in 1/3
- CxR negative -> CT positive in 1/3



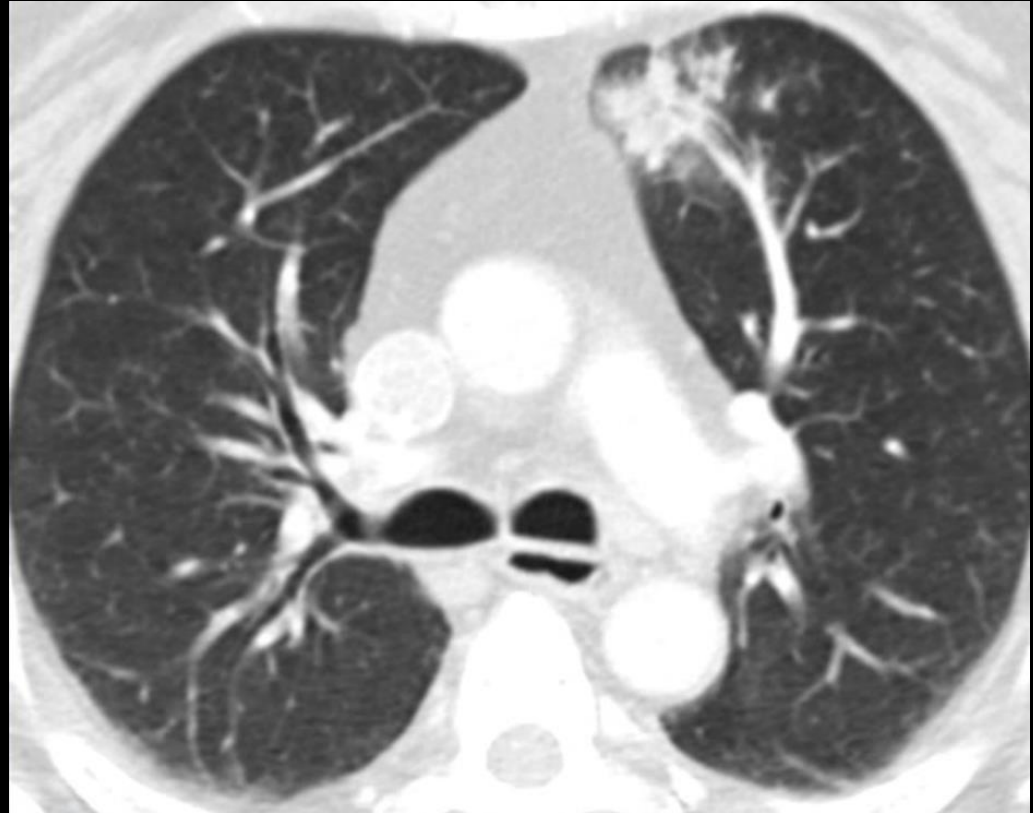
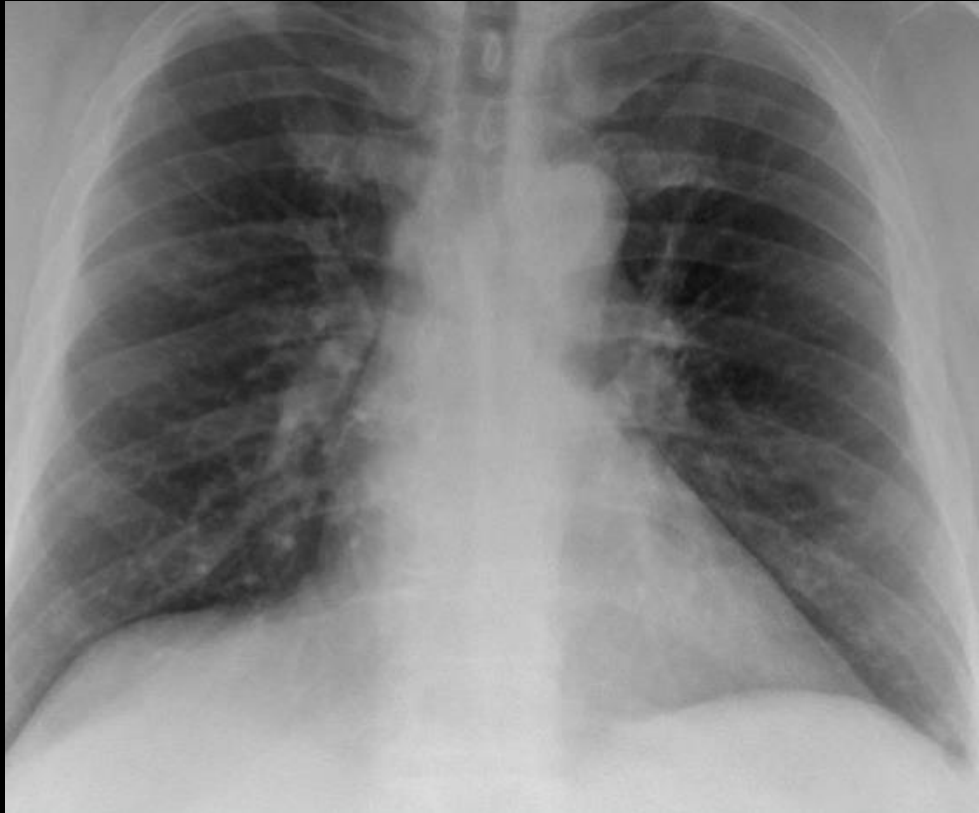
Am J Respir Crit Care Med 192, 8, 974–982, 2015



07:16:07



21



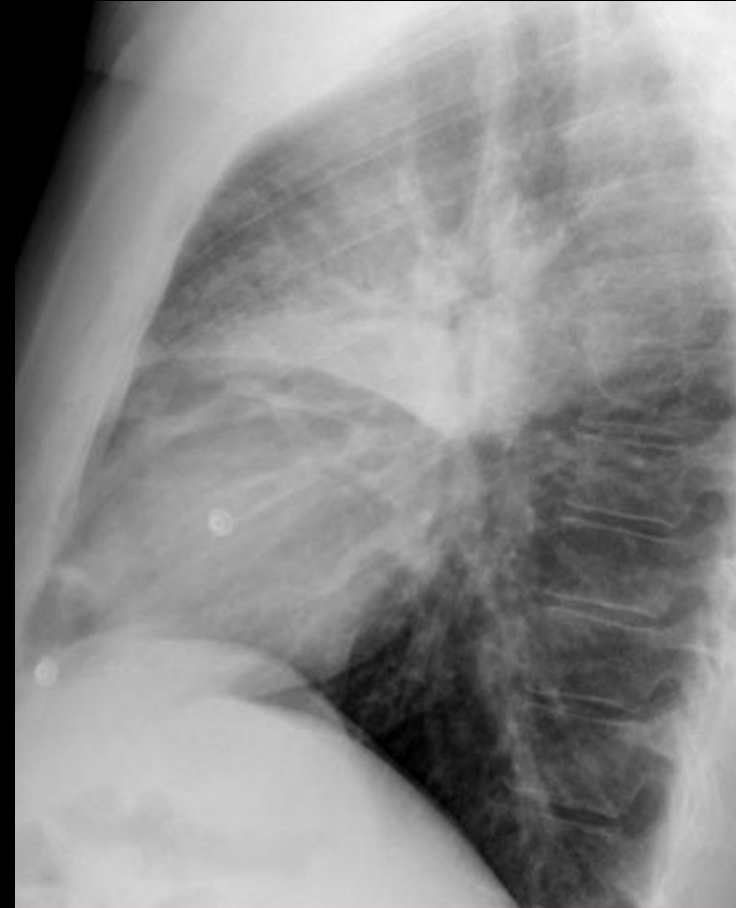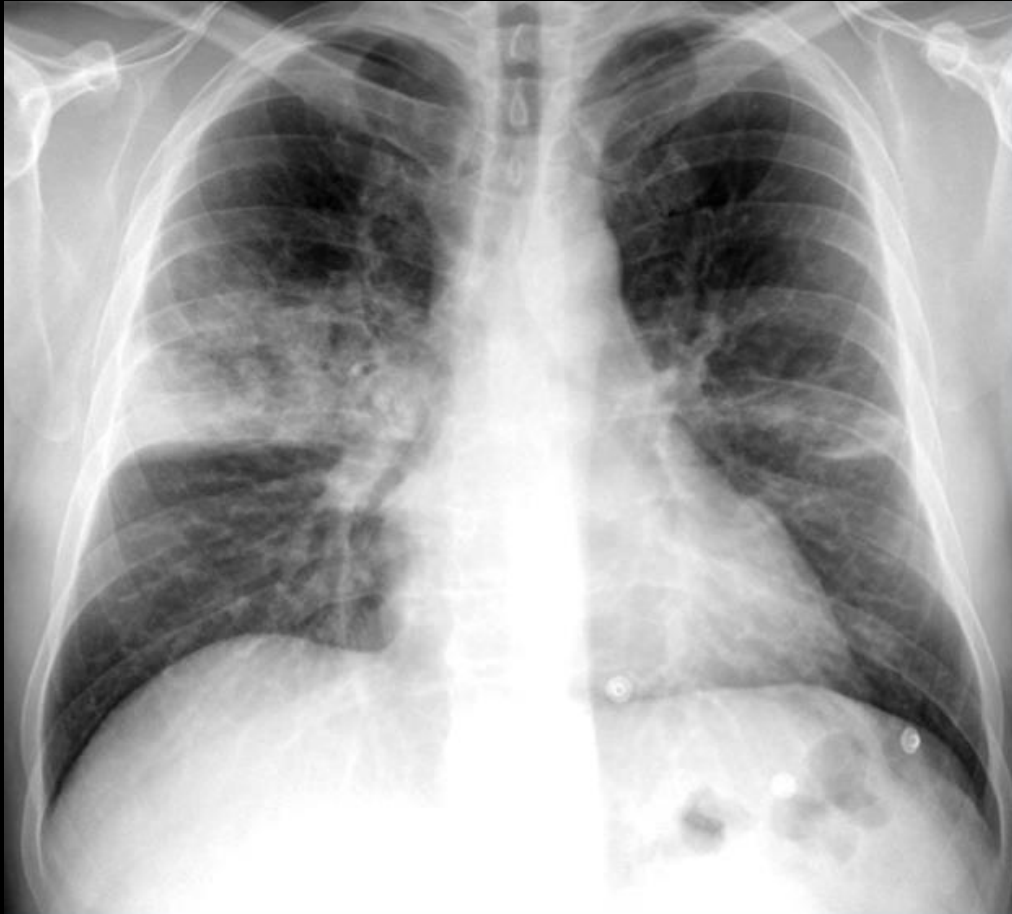- In CxR false negatives
 - ⇒ PE: Crackles: positive predictor
 - ⇒ But no crackles?

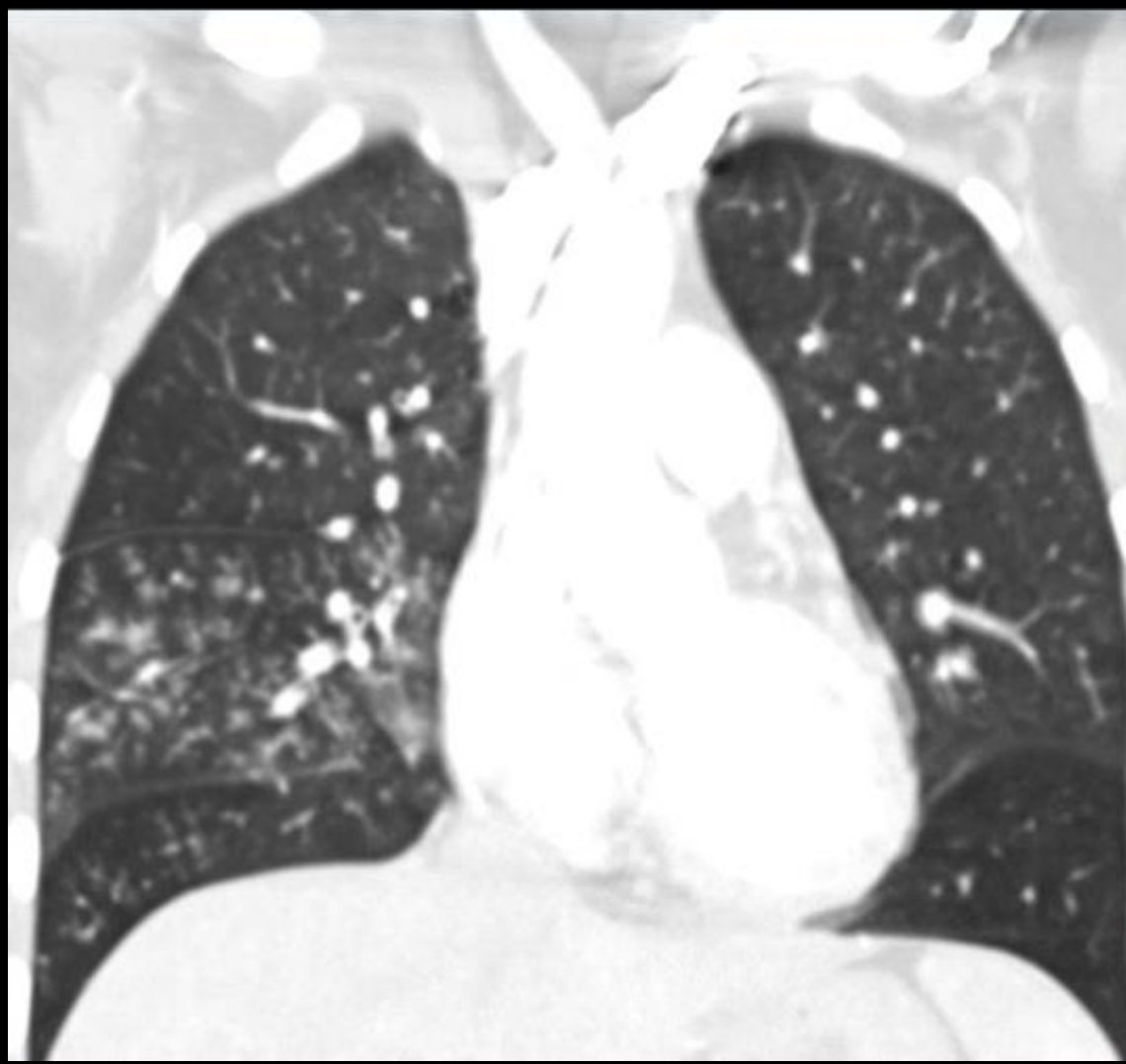
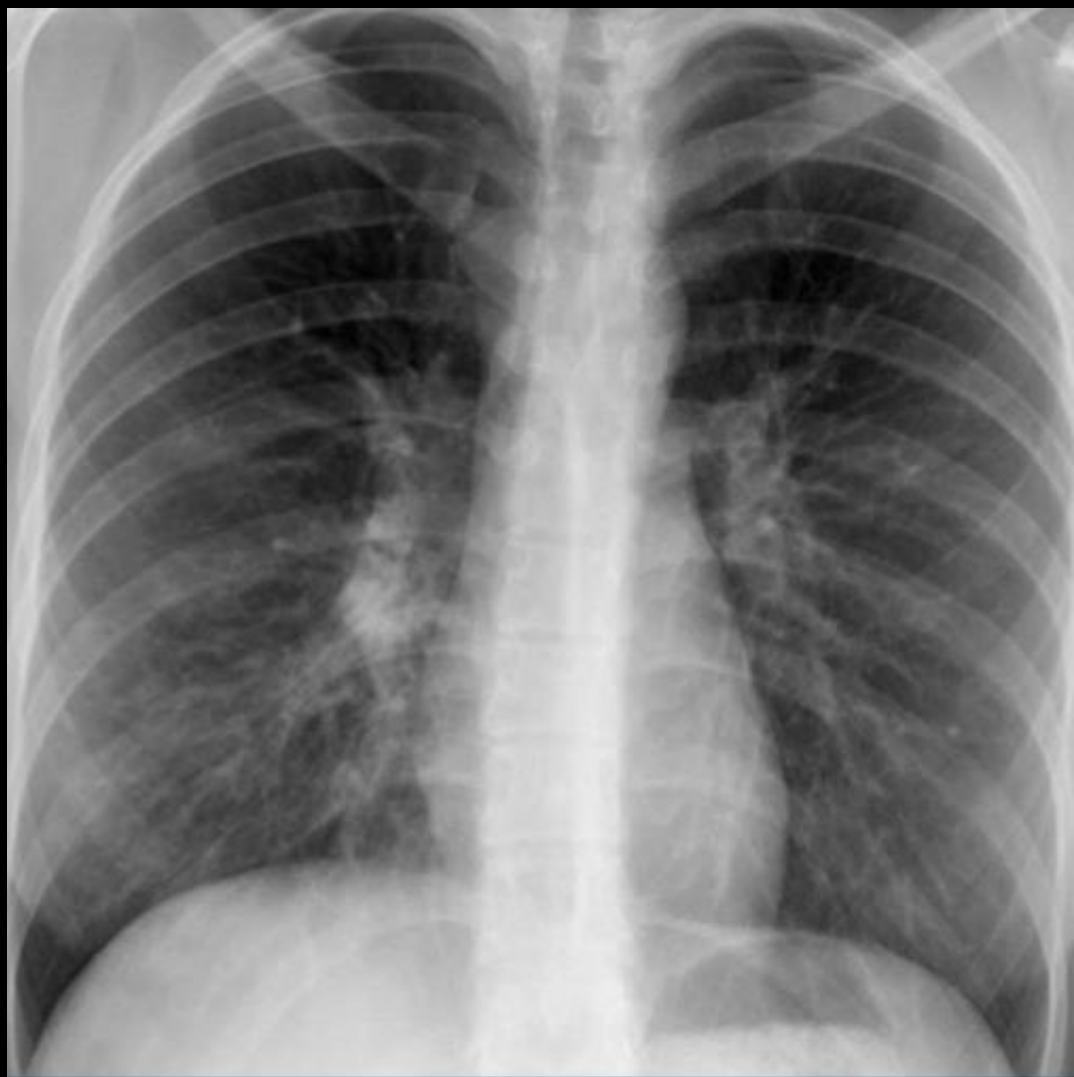
Clinical assessment really is important!



Community Acquired Pneumonia (CAP)

- CxR: role?
- Best for pleural effusions and lobar involvement!
- But:
 - (1) Peri-bronchovascular distribution
 - (2) Bronchial wall thickening
- Clinically significant infections but CxR: subtle!
- Nonspecific! Infections? Non-infectious diseases? (ER or OPD)





Pulmonary Infections

- (1) Detection of infection: CxR -> CT chest
- **(2) Differentiation: infections? Non-infectious lung disease?**
- (3) Infection: complications
- (4) Specific pathogens: Chronic fibrocavitary disease

(2) Differentiation: infections? Non-infectious lung disease?

- (1) Septal thickening (線)
- (2) Nodule patterns (點)
- (3) Consolidation patterns (面)

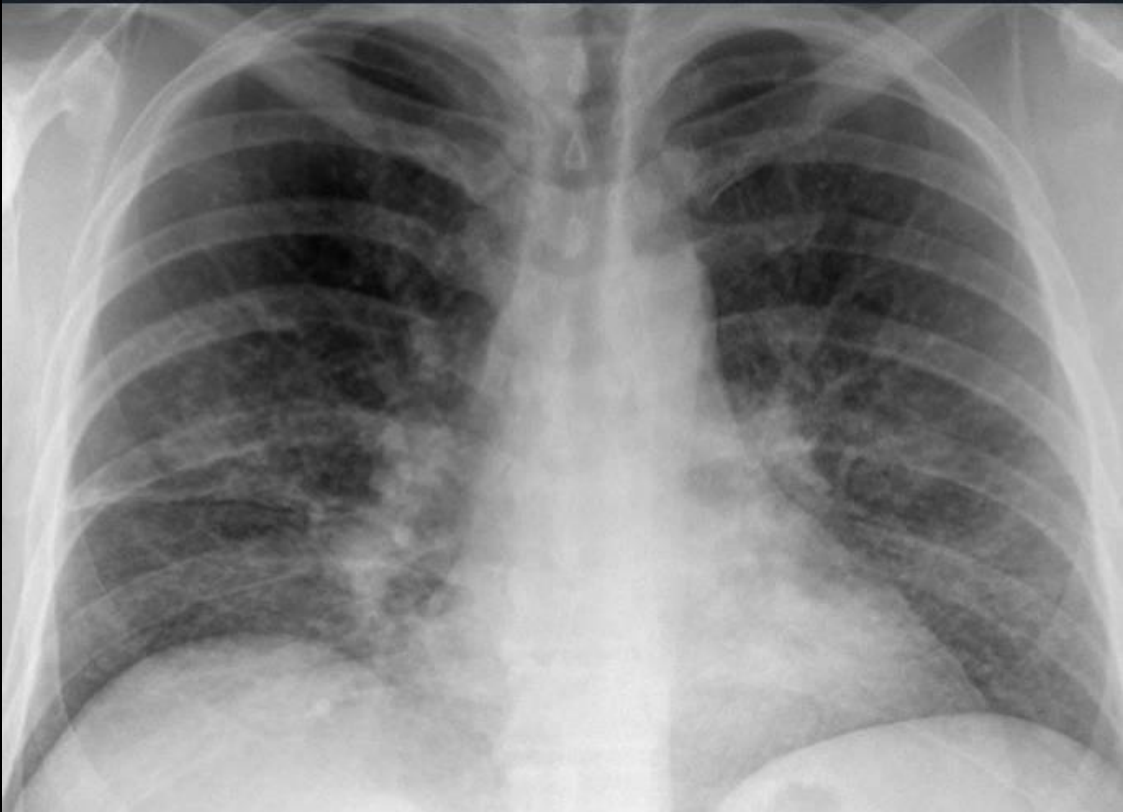
(點)

(線)

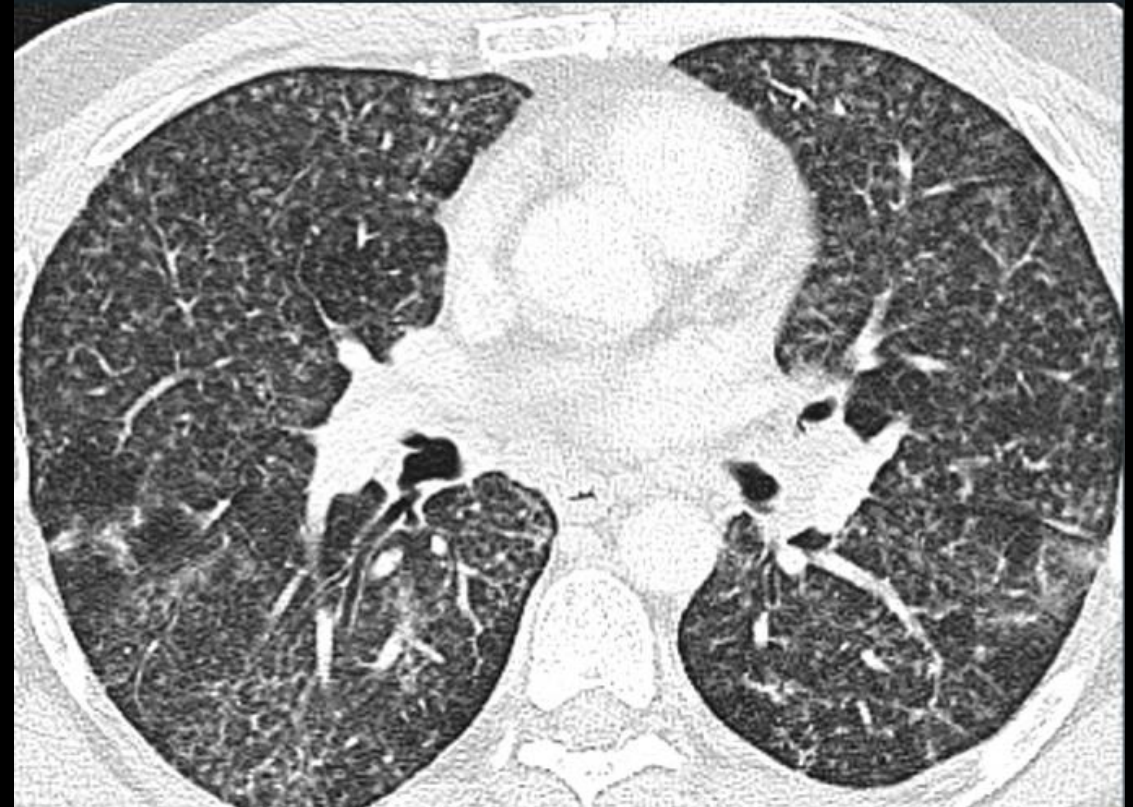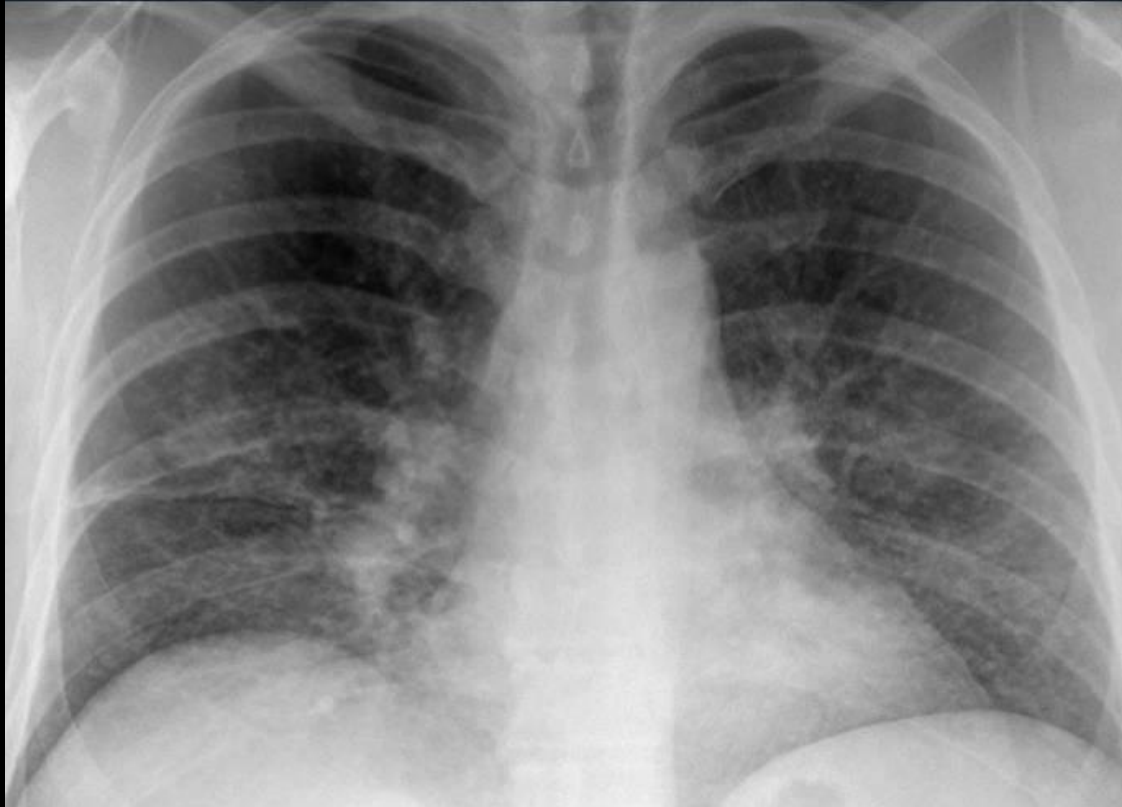
(面)

急診醫學發展

- CXR -> Sonography; POCUS -> CT chest -> Echocardiography -> Lumbar puncture -> TEE -> Whole body CT ->..... -> AI (2019 急診醫學年會主題)
- “Rapid” Diagnosis -> “Early” Treatment
- EMT: “pre-ER”
- Infectious source ?



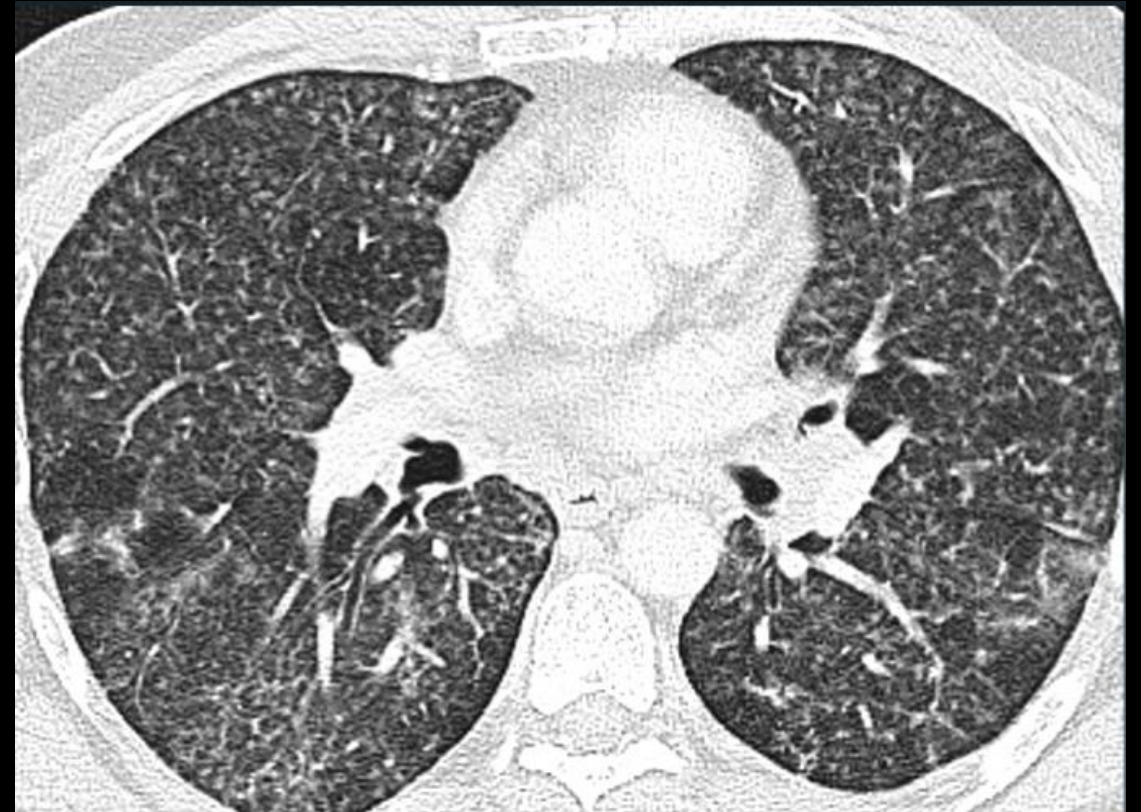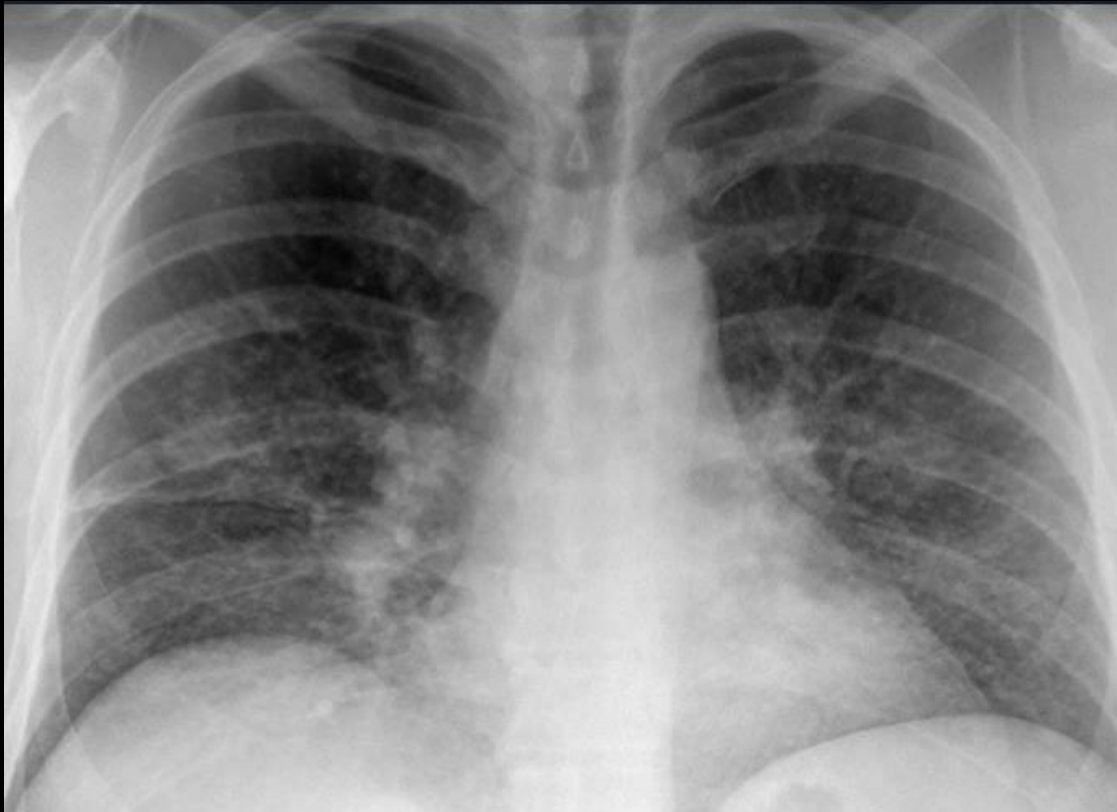
- OPD
- 40 Y/O Male
- Severe cough
- Dx: ?
- Rx:?



Case:

Answer: *Mycoplasma pneumoniae*

- Tree-in-bud pattern

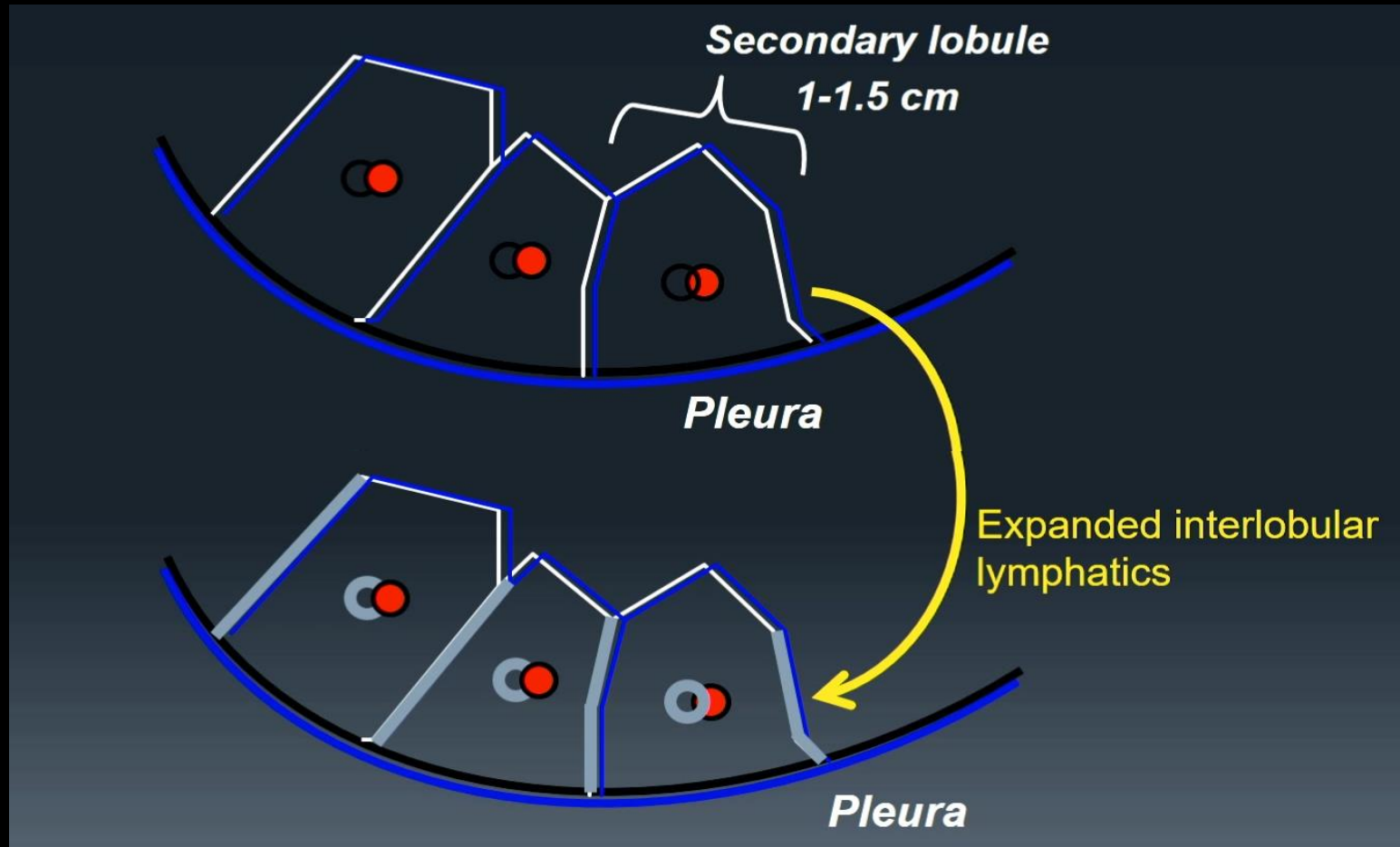


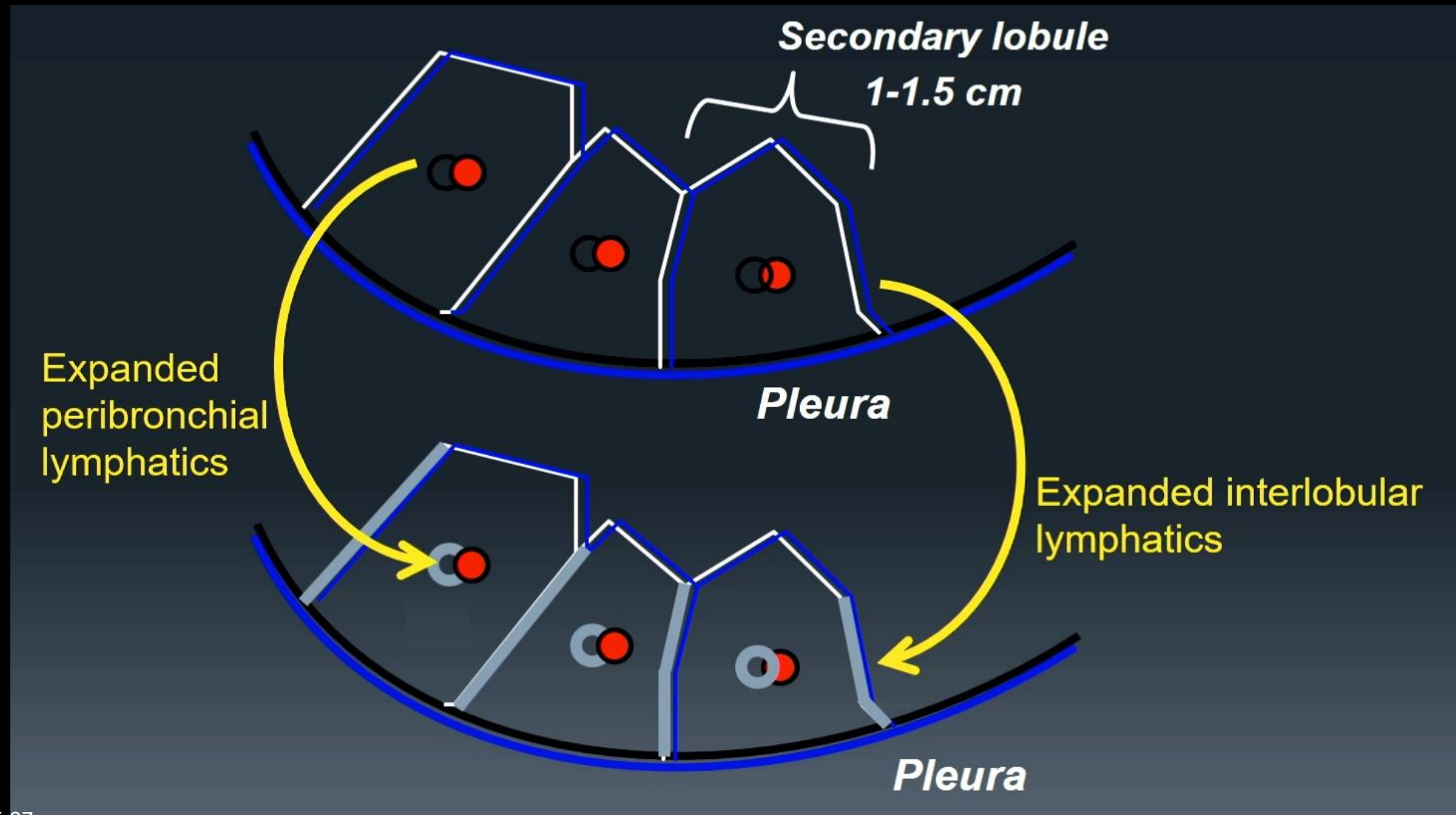
(2) Differentiation: infections? Non-infectious lung disease?

- **Septal thickening**
- Nodule patterns
- Consolidation patterns



CT pattern: interlobular septal thickening (dominant)





CT pattern: interlobular septal thickening (dominant)

■ **Common: non-infectious**

=> Congestive heart failure

=> Lymphangitic carcinoma

=> Acute eosinophilic pneumonia

=> Drug reaction

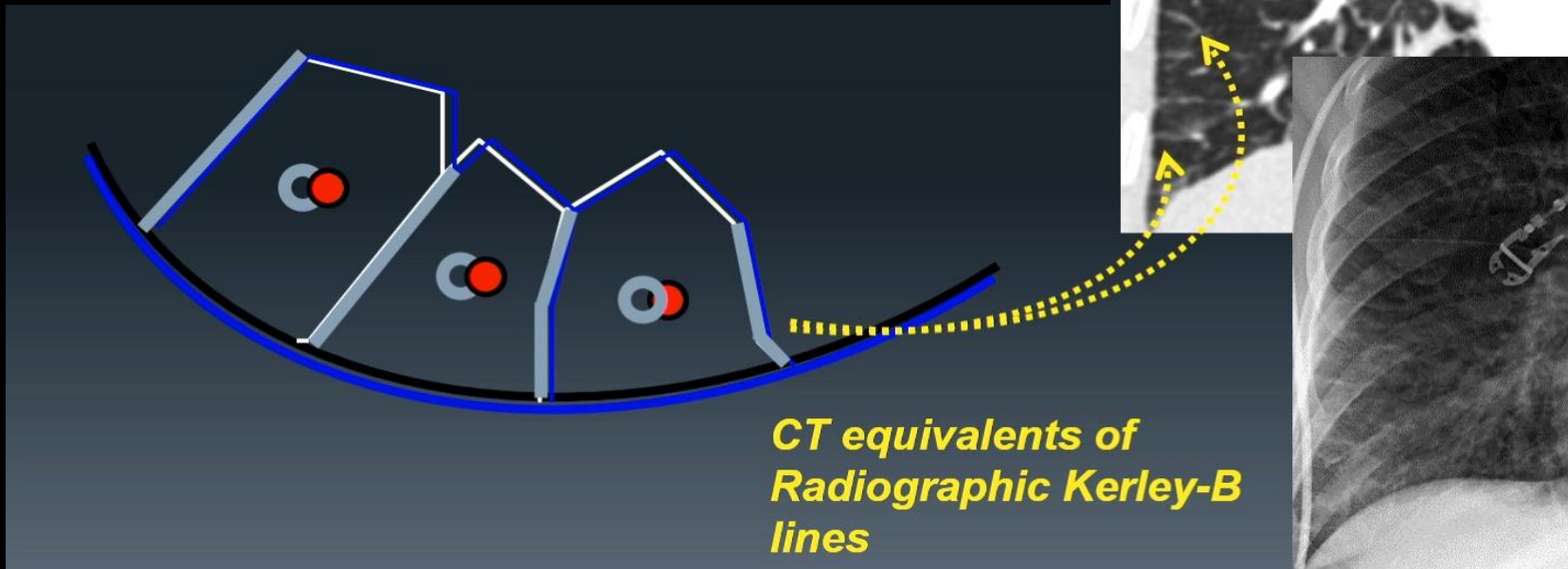
■ **Infections: rarely dominant or diffuse**

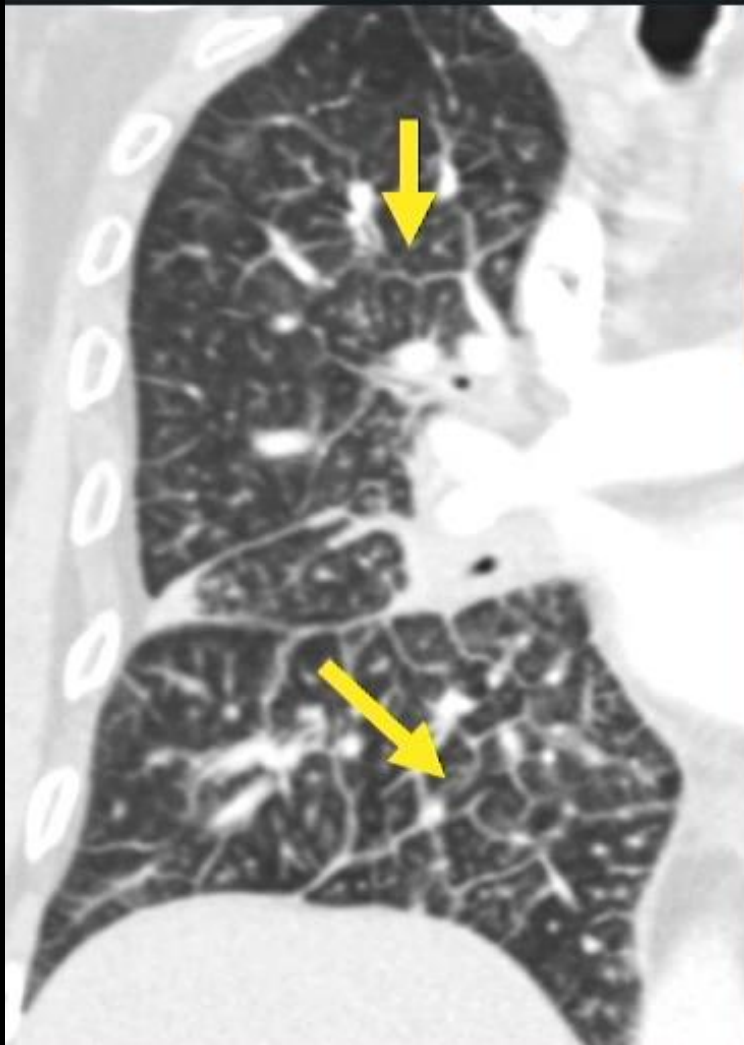⇒ Hantavirus (if cardiac dysfunction present)

⇒ Rickettsia diseases

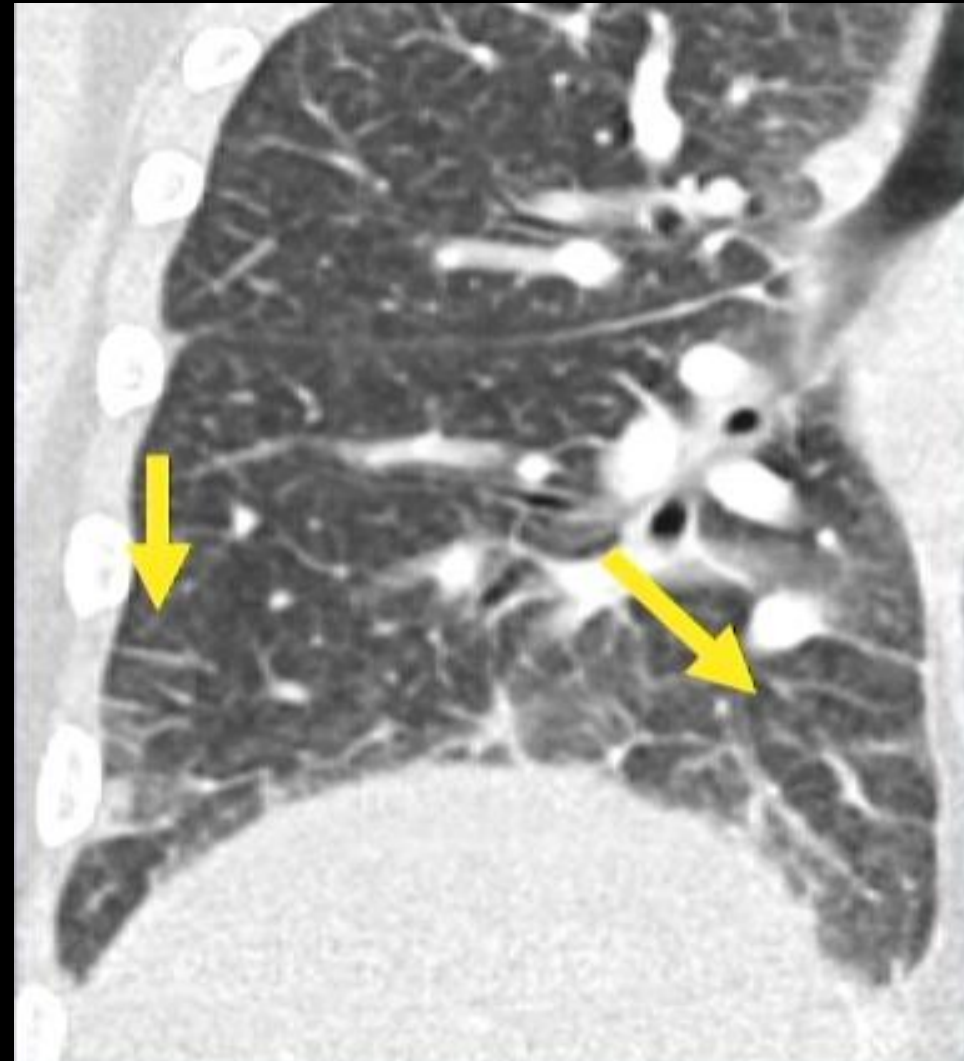(Common: Scattered thickened septa intermixed with other opacities)

CT pattern: interlobular septal thickening (dominant)

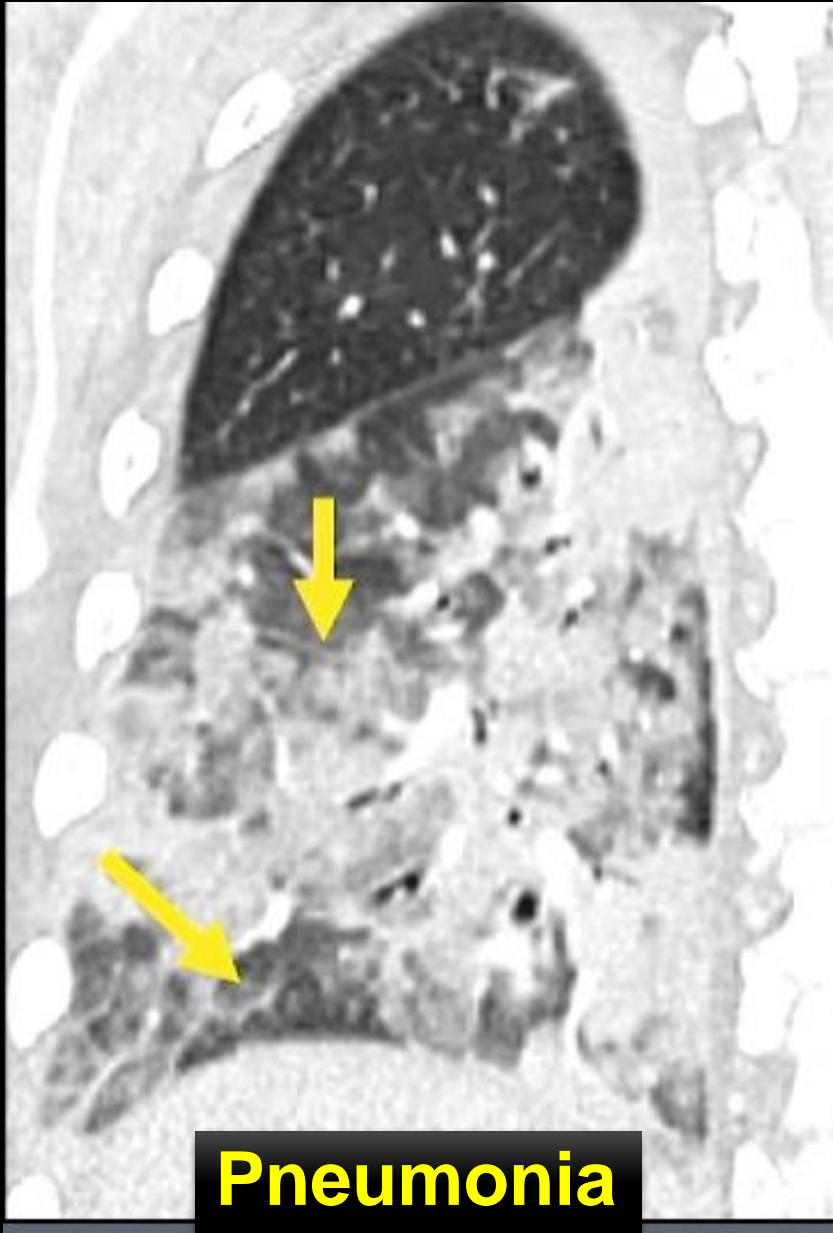




Lymphangitic carcinoma



Acute eosinophilic pneumonia



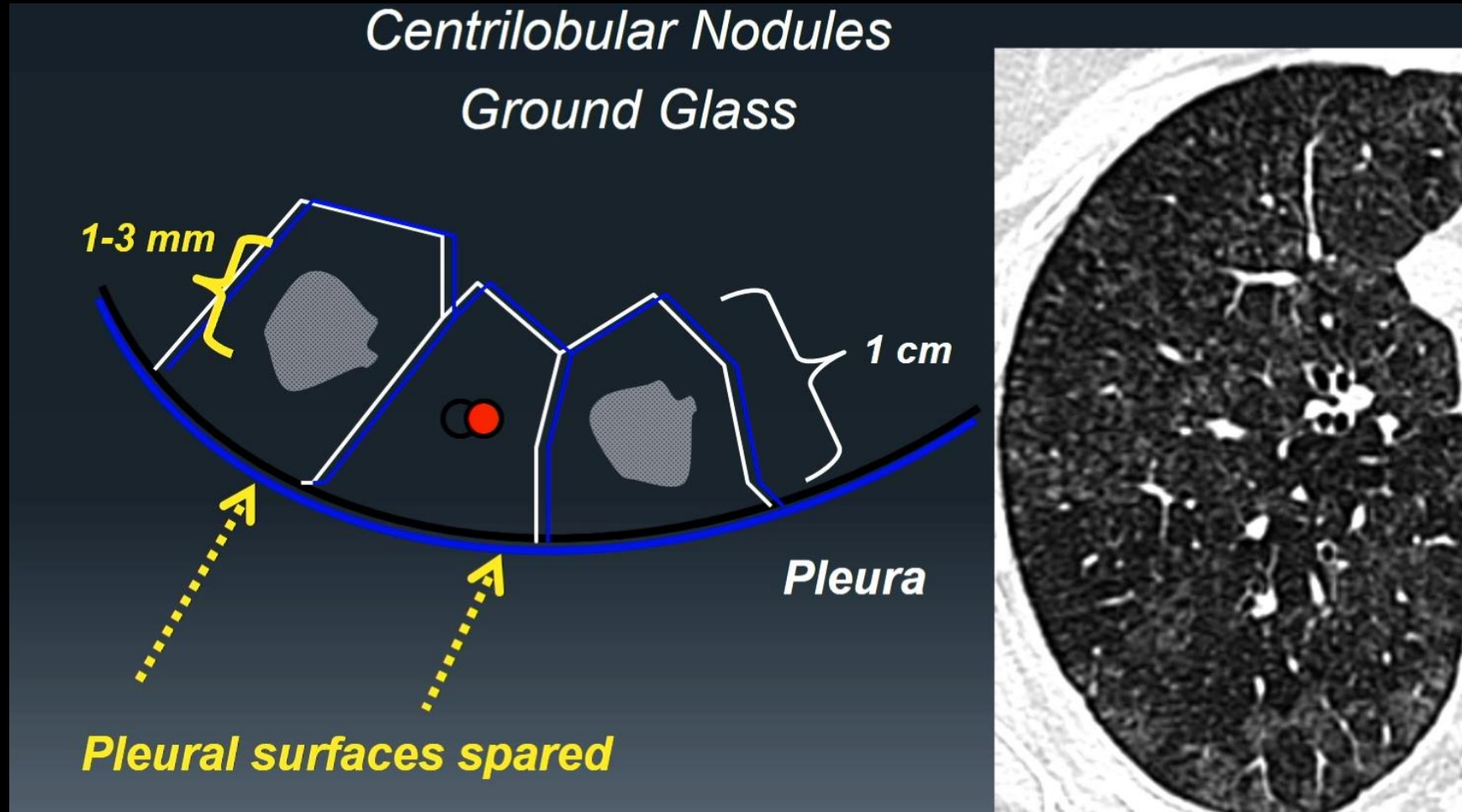
(2) Differentiation: infections? Non-infectious lung disease?

- Septal thickening
- **Nodule patterns**
- Consolidation patterns



CT pattern: Centrilobular nodules

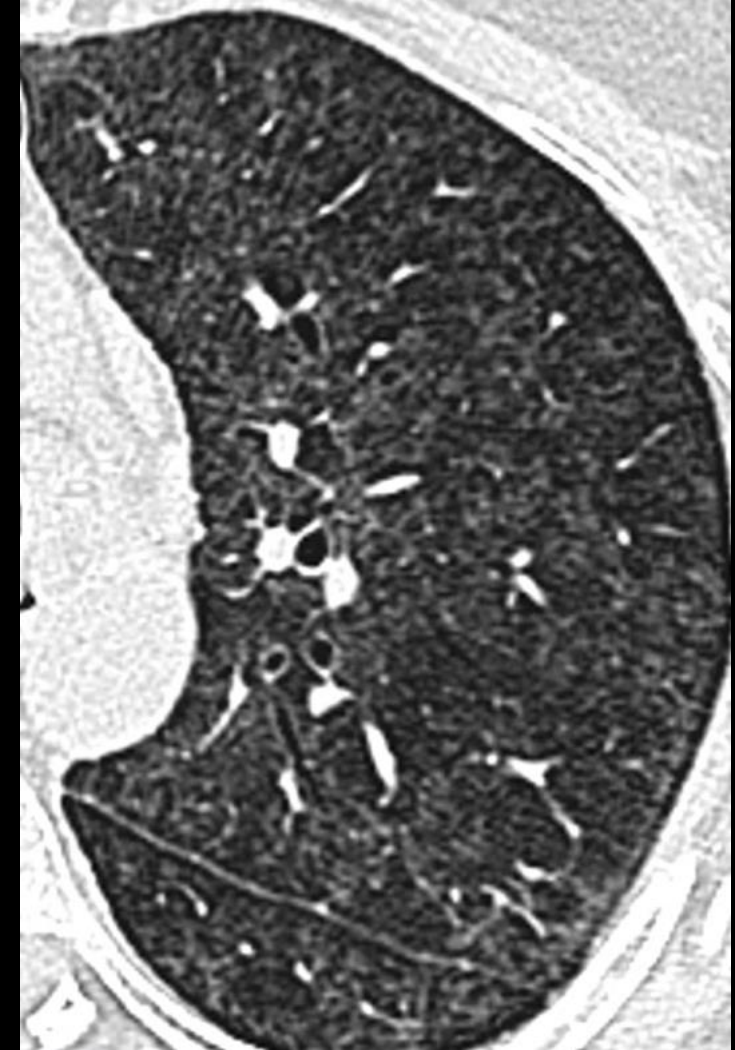
(黒点)



CT pattern: Centrilobular Ground Glass nodules

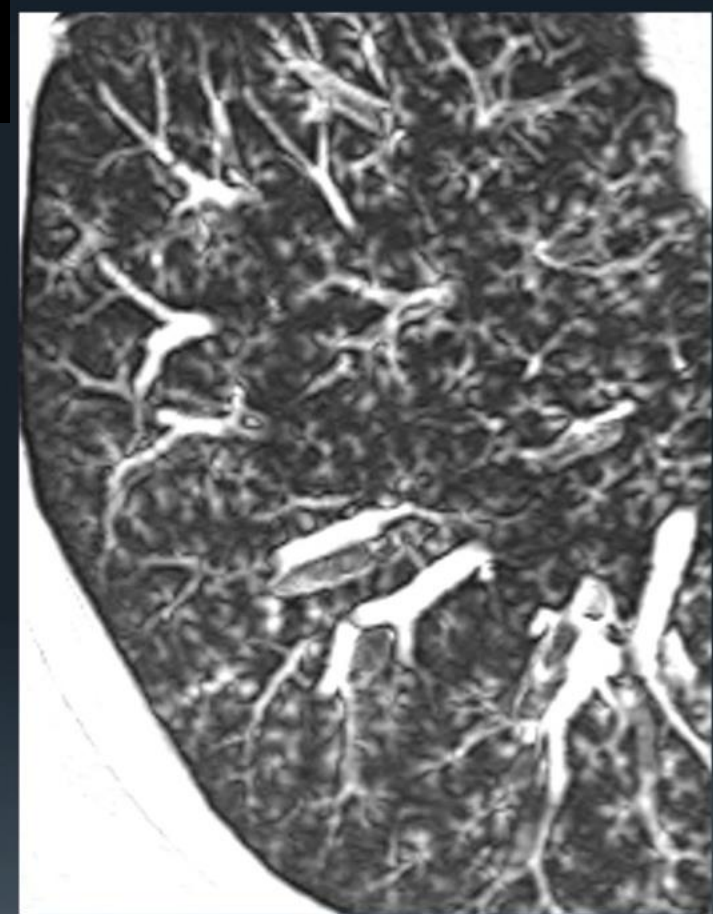
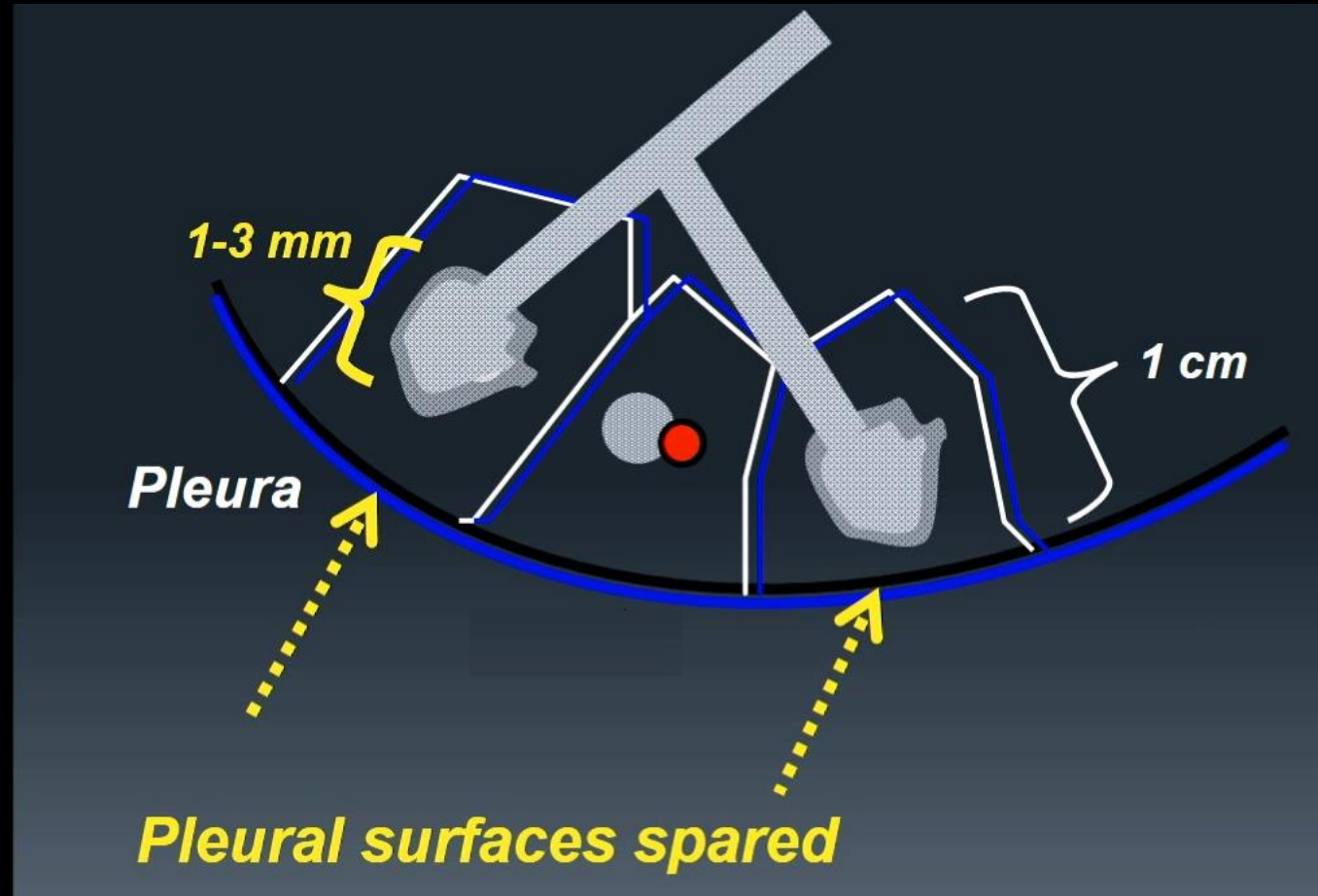
Non-infectious disease: common

- Hypersensitivity pneumonitis
- Respiratory bronchiolitis
- Pulmonary hemorrhage/pulmonary vasculitis



* CT pattern: Centrilobular
nodules with “Tree-in-bud”
(TIB)

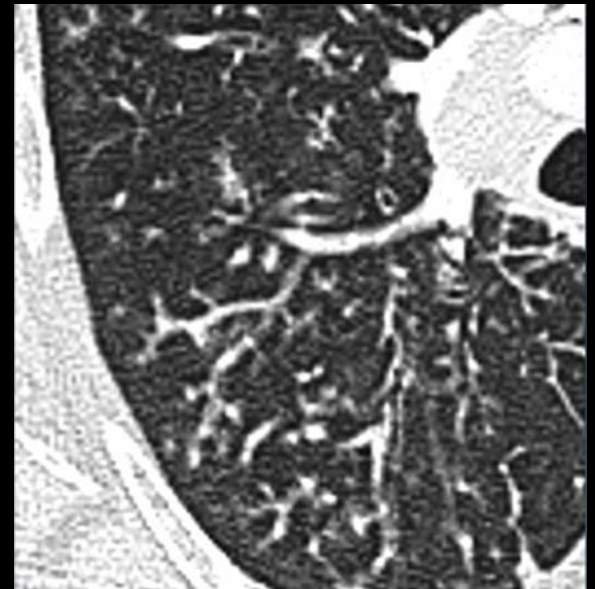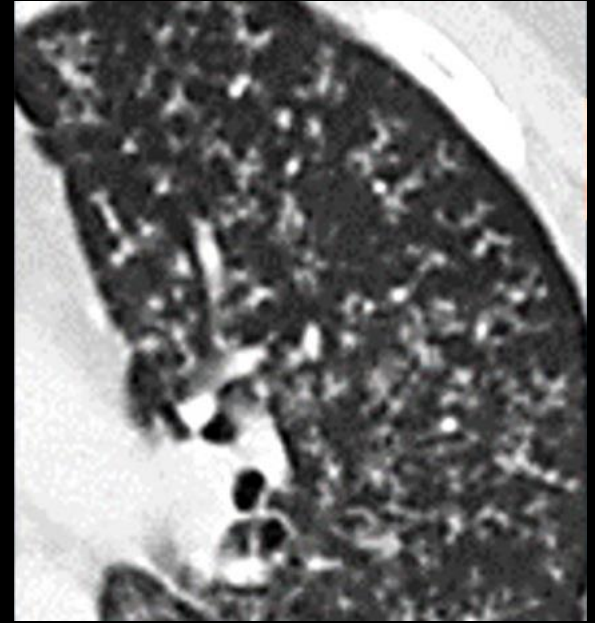
(黑點)



CT pattern: TIB

Centrilobular nodules

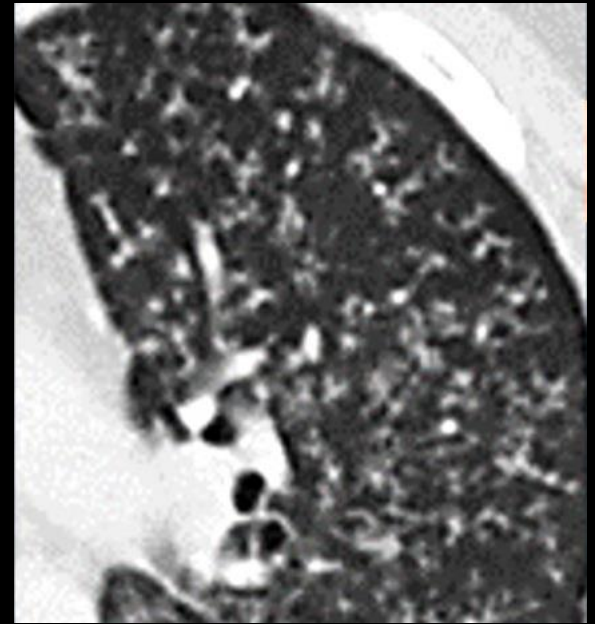
- Infectious: most common
- Mycobacterial
- Bacterial: H. influenza
- Mycoplasma –usually adults
- Viral (RSV, Parainfluenza, Influenza, Human Metapneumovirus)



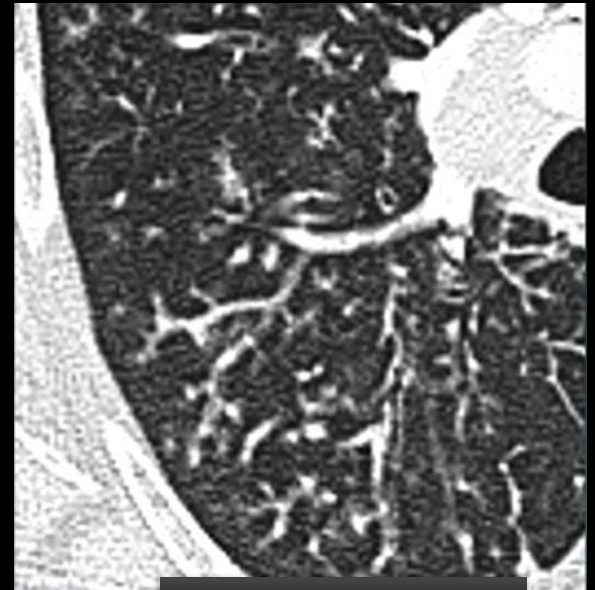CT pattern: TIB

Centrilobular nodules

- Infectious: most common
- Mycobacterial
- Bacterial: H. influenza
- Mycoplasma –usually adults
- Viral (RSV, Parainfluenza, Influenza, Human Metapneumovirus)



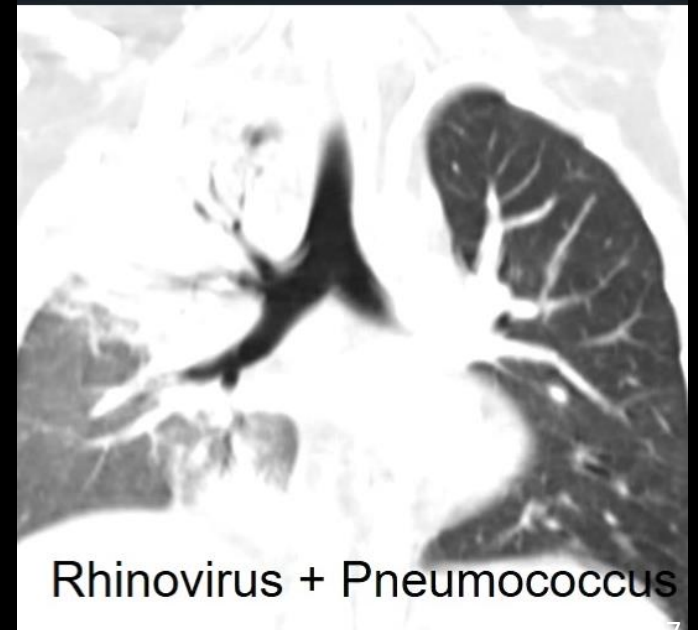
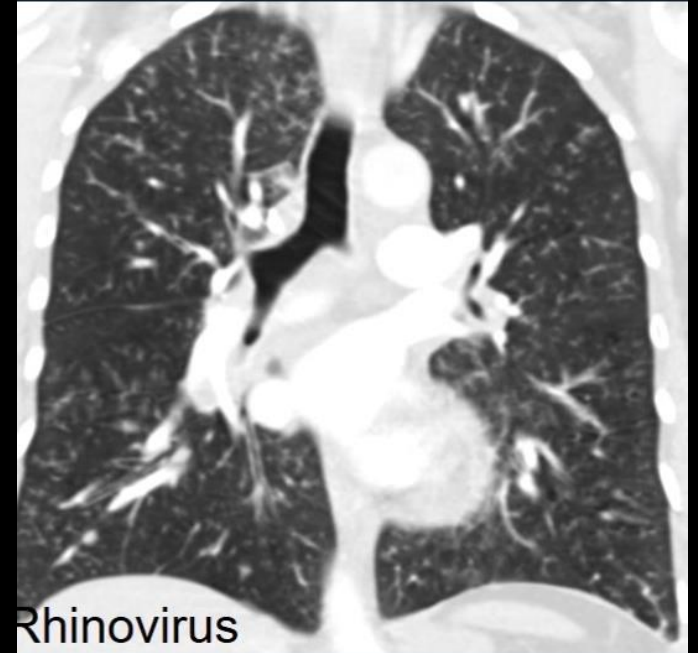Tuberculosis



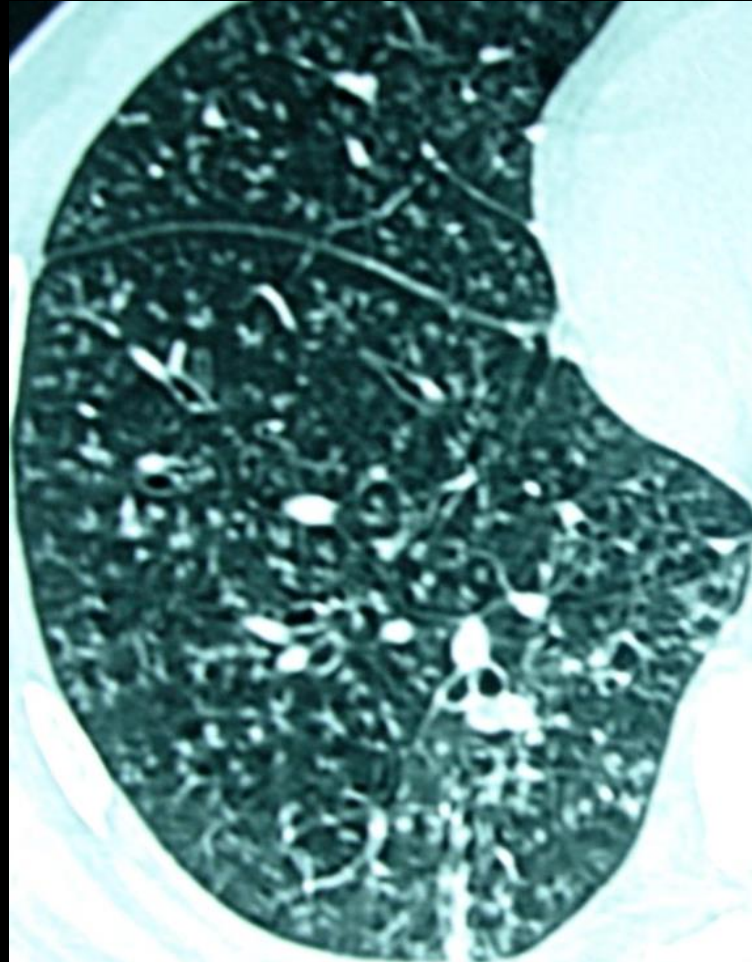
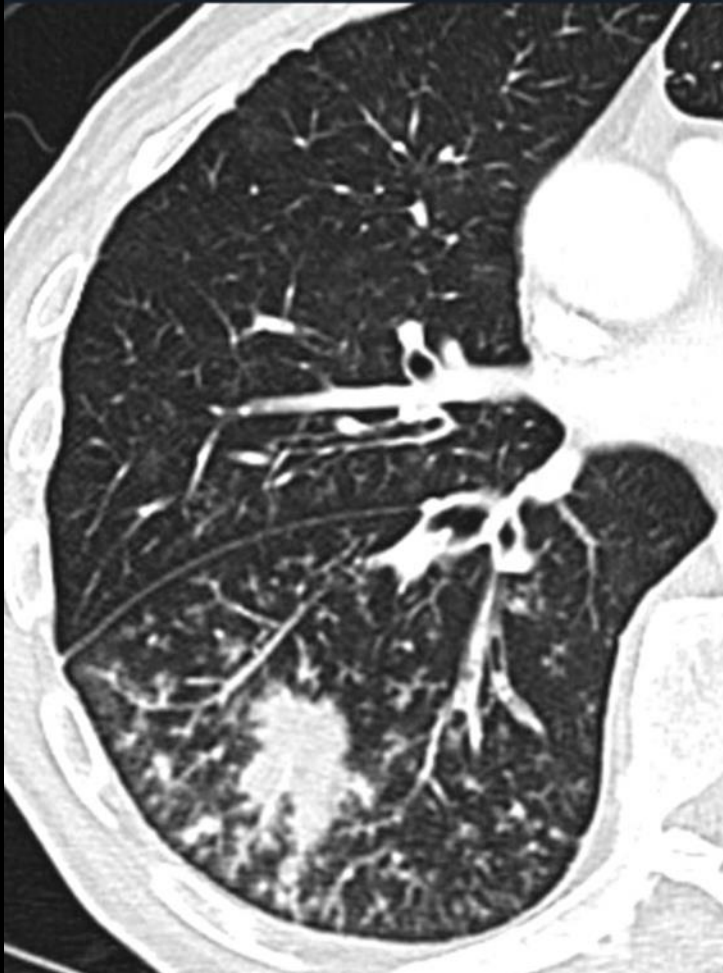Influenza

CT pattern: TIB Centrilobular nodules

- Viral
- Radiologic pattern may be dominated by bacterial co-infection
- Influenza
- Rhinovirus infections



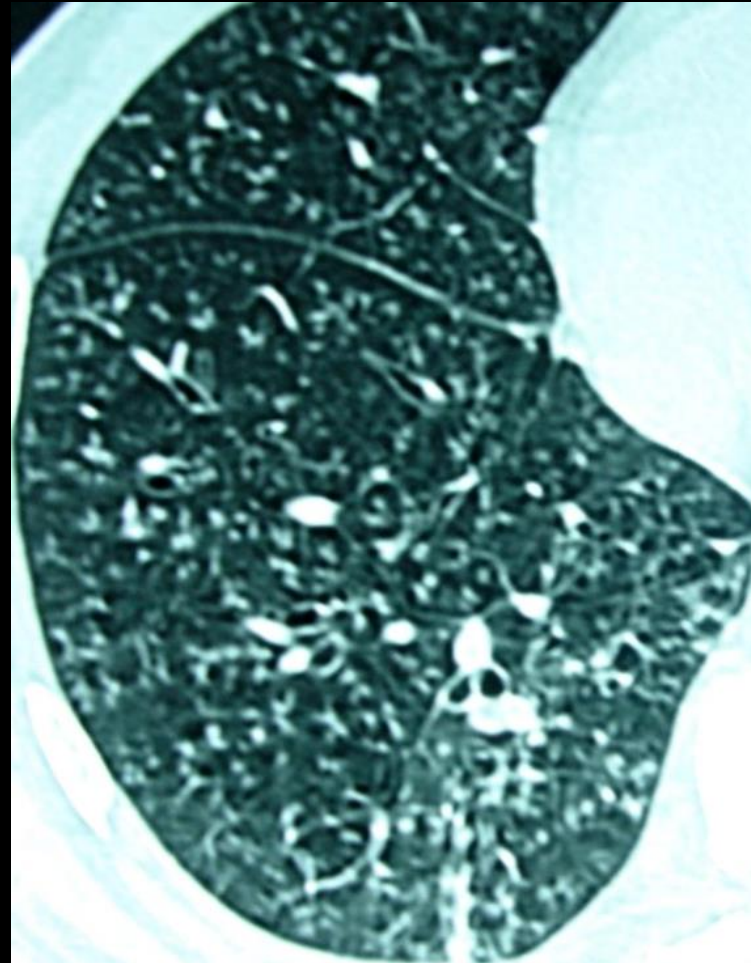
Non-infectious TIB: less common



Non-infectious TIB: less common



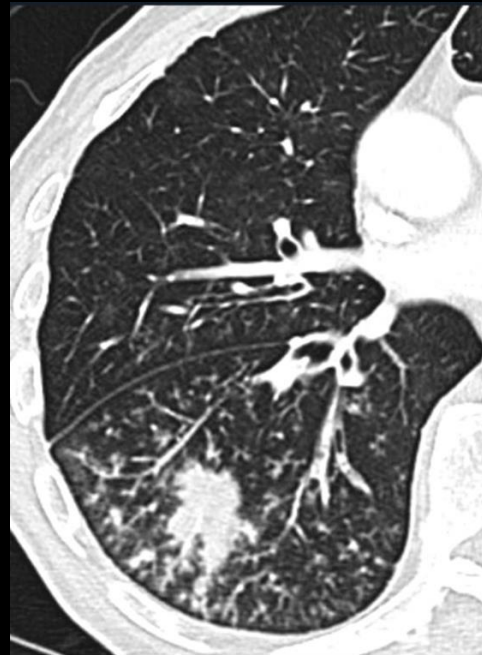Aspiration



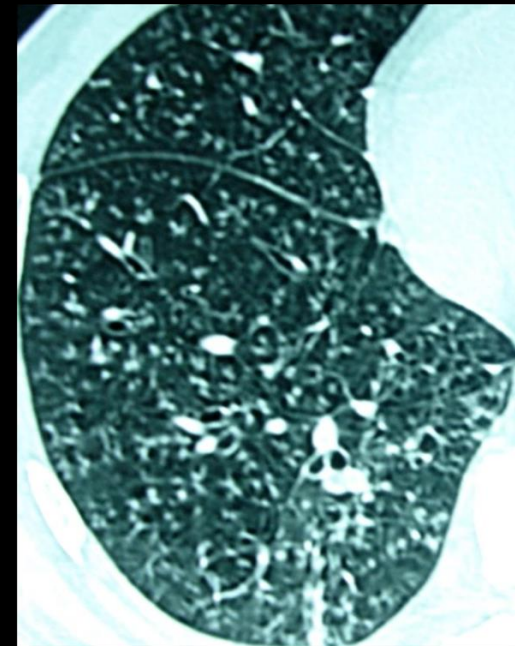
Infectious bronchiolitis

Non-infectious TIB: less common

- **Aspiration: clue:** dependent part and lots of secretion in the bronchi
- Mycoplasma pneumonia



Aspiration

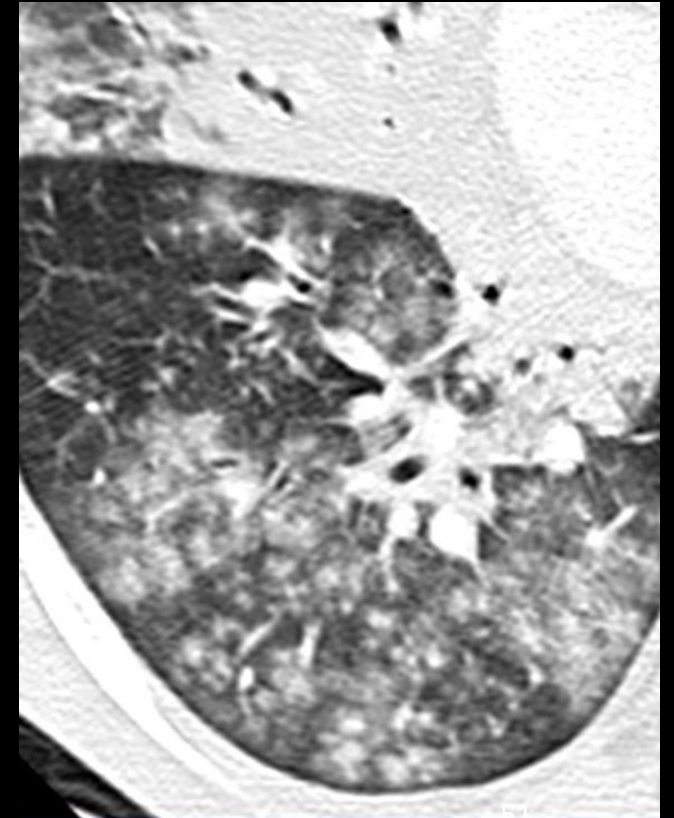


Infectious bronchiolitis

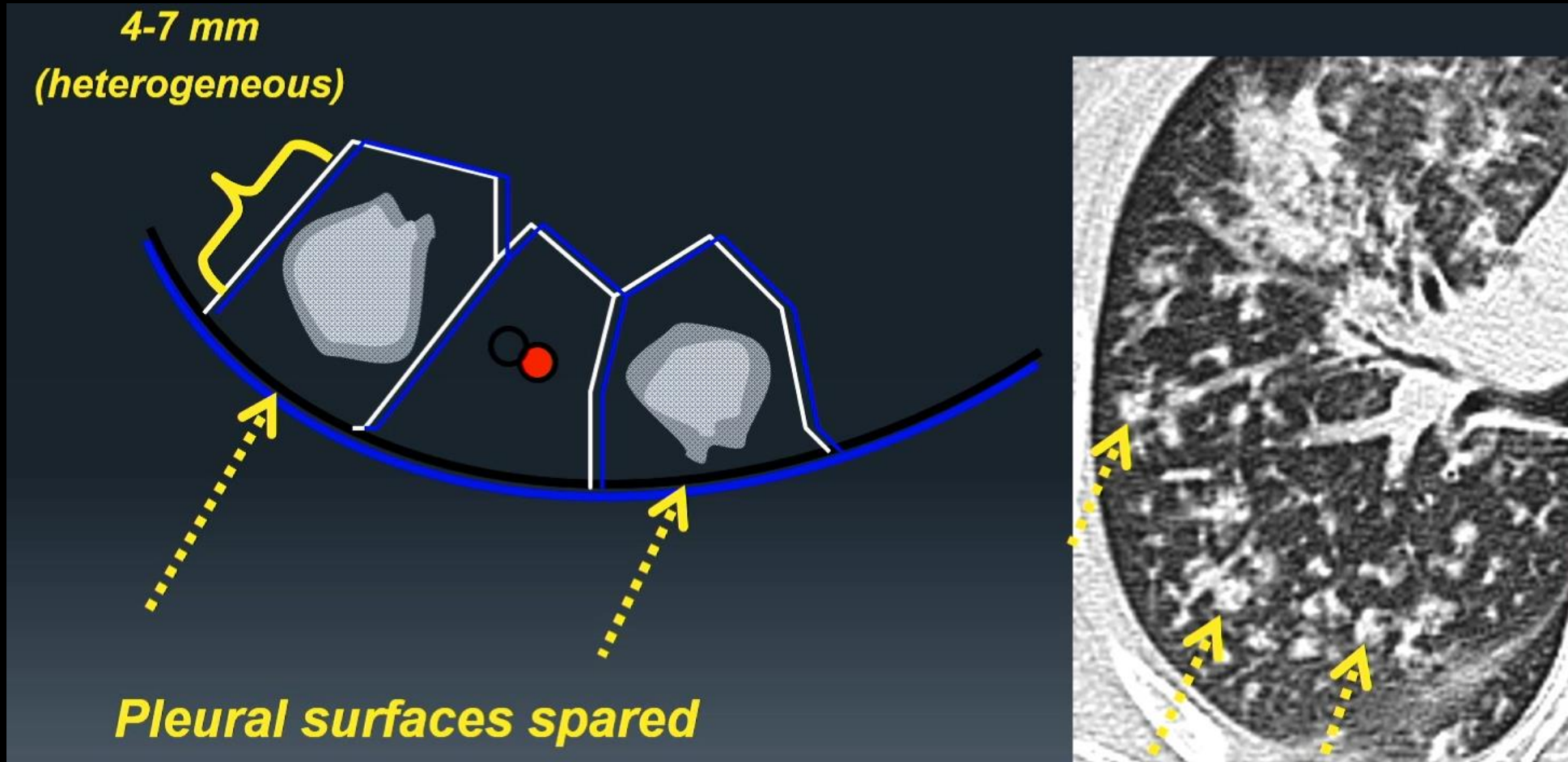
** CT pattern: Soft tissue Centrilobular nodules



- Soft tissue centrilobular nodules: **Bigger size**
- **Heterogeneous** in size
- Patchy
- **Common in infections:**
= Acinar consolidation; often associated with TIB
- **Non-infectious causes:**
= aspiration; invasive adenocarcinoma-chronic;

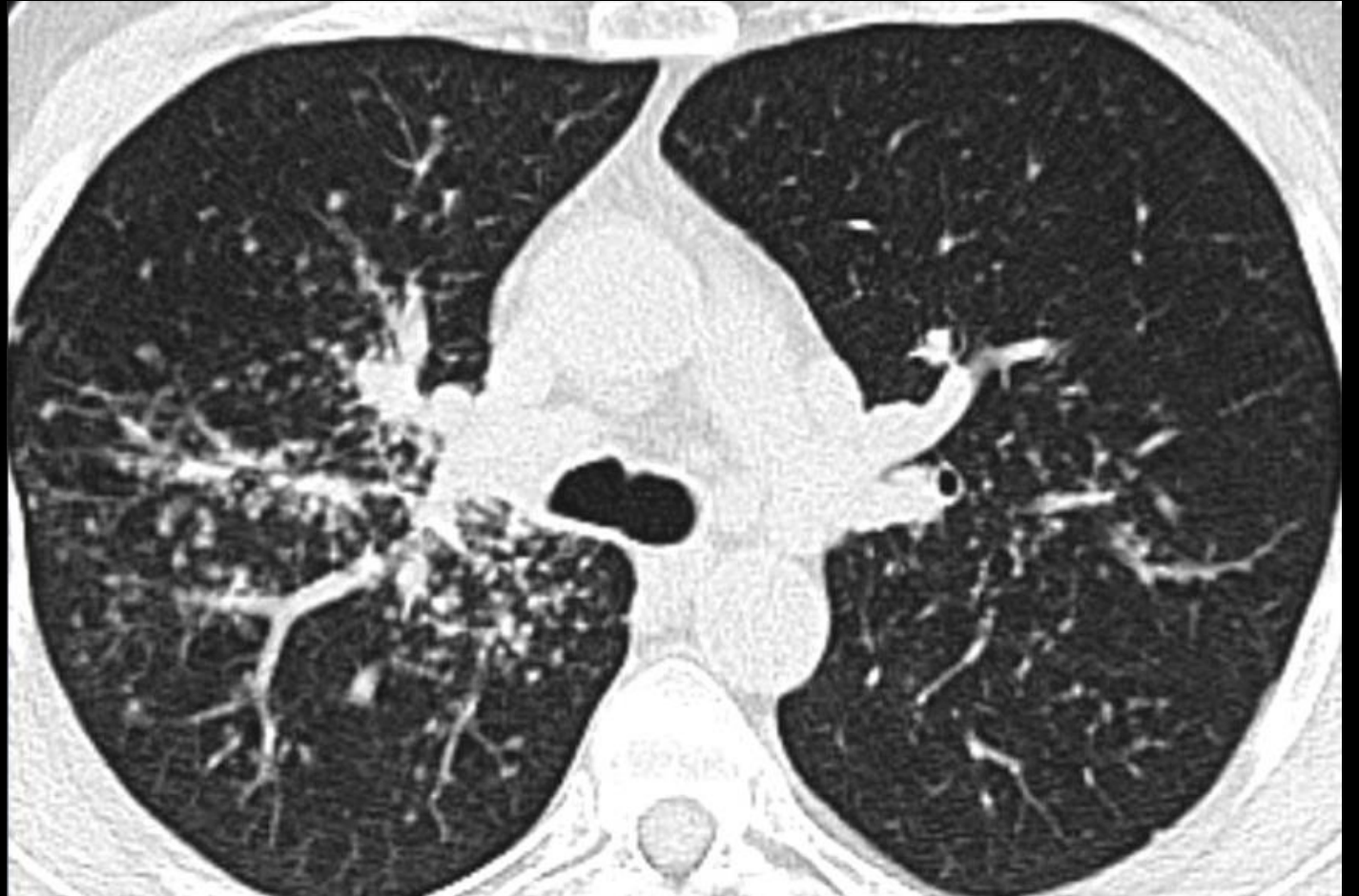

** CT pattern: Soft tissue Centrilobular nodules

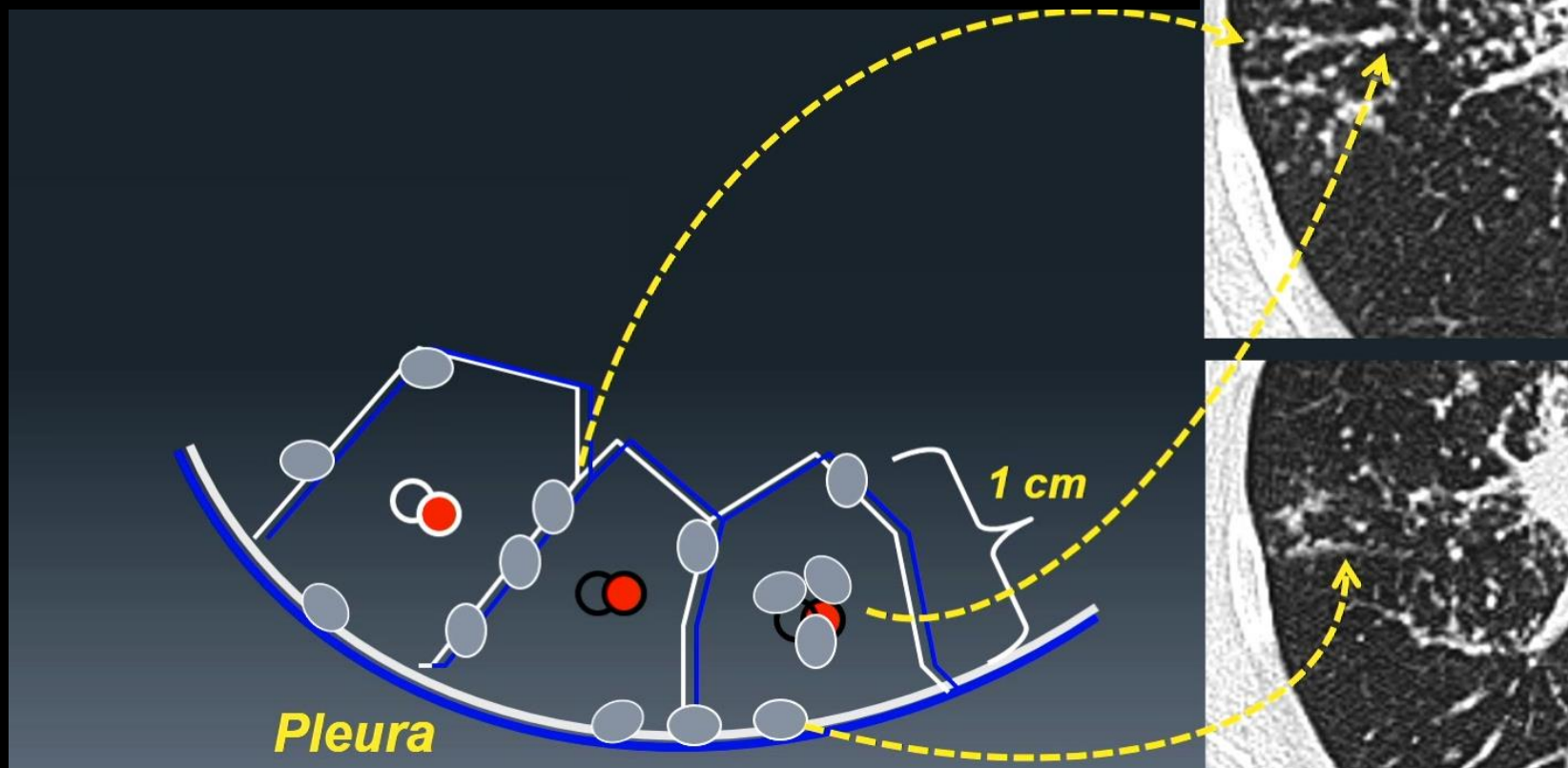


Case:

- 52 Y/O
- Female
- ER: chest pain
- Hx of 2 cm thyroid nodule
- CxR
- CT chest
- Diagnosis?



*** CT pattern: Perilymphatic nodules



CT pattern: perilymphatic nodules

- Predilection
- Centrilobular/Peribronchial lymphatics
- Interlobular Septa
- Pleural Surfaces
- Nodules “clumpy” (often)
- **DDx: Sarcoid, silicosis and lymphangitic cancer**
- **Usually not from infection**

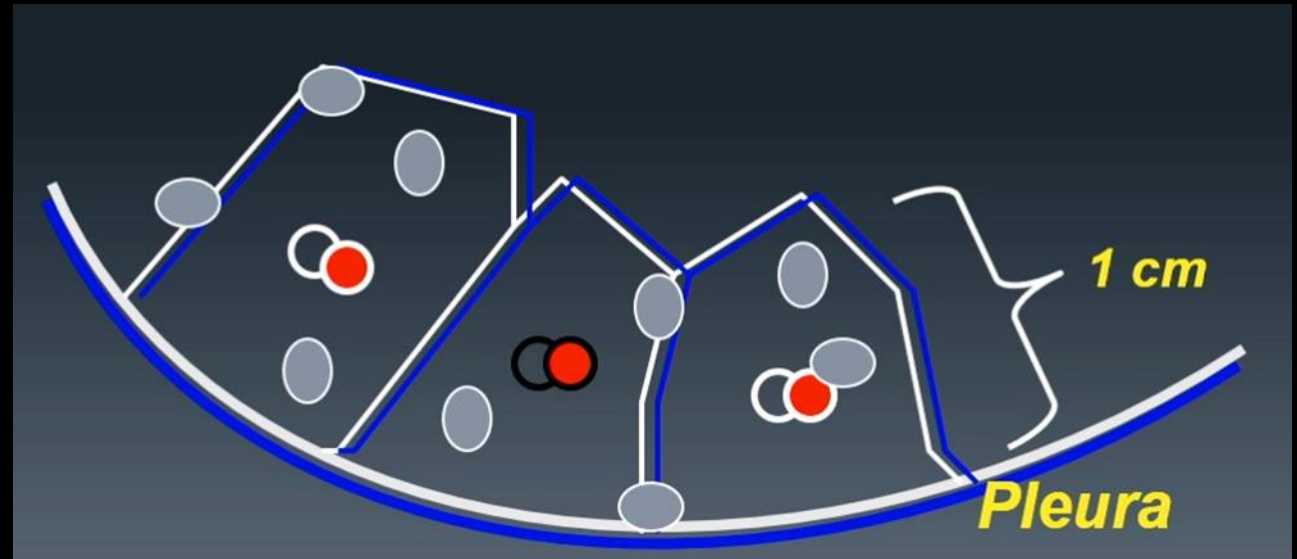
Case: Diagnosis: **Sarcoidosis**

- 52 Y/O
- Female
- ER: chest pain
- Hx of 2 cm thyroid nodule
- CxR
- CT chest

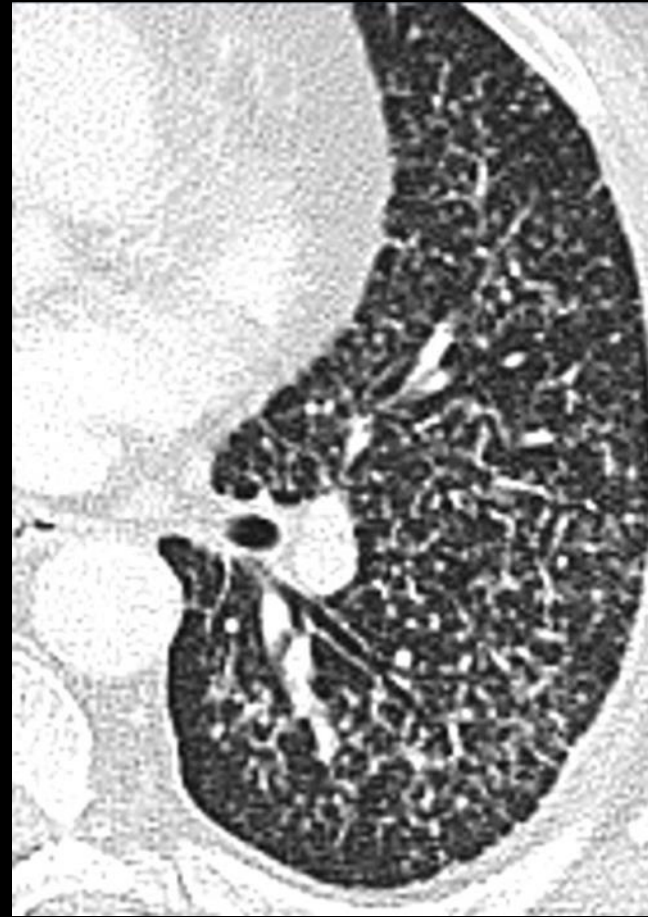
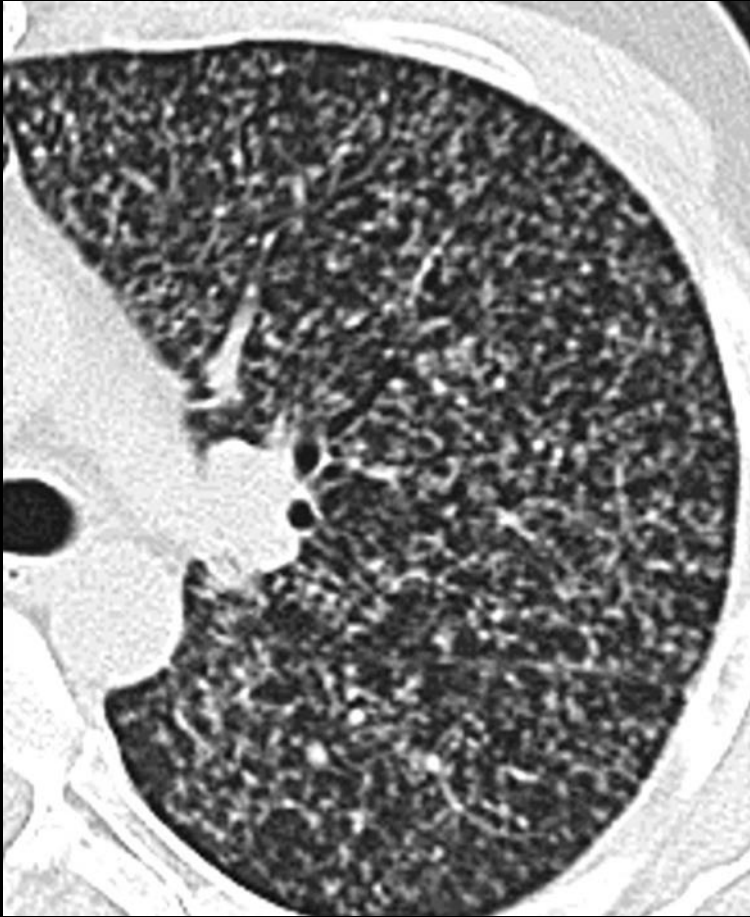

**** CT pattern: Random nodules

- Diffuse, randomly contact interlobular septa and pleural surfaces (hit the pleural surfaces)
- Infection – **miliary TB**, endemic fungi
- Non-infectious – **Metastatic neoplasm**
- **Blood-borne usually**



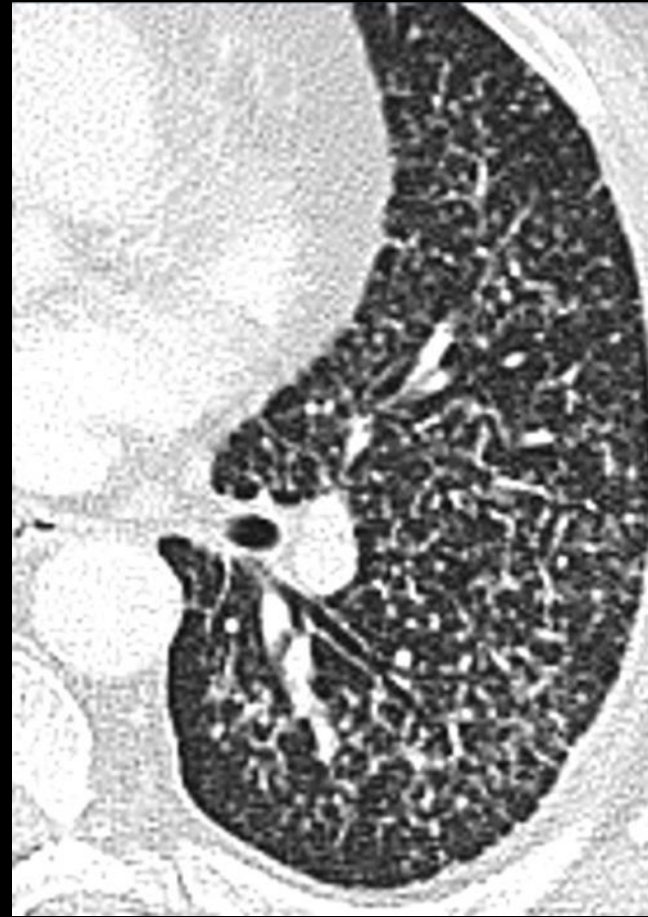
CT pattern: Random nodules



CT pattern: Random nodules



Miliary Tuberculosis



Metastasis: testicular cancer

CT pattern: Micronodules: Summary



<i>Nodule pattern</i>	=	Etiology
■ <i>Centrilobular with TIB</i>	=	Infection >> Non-Infection
■ <i>Centrilobular soft tissue</i>	=	Infection (acute) > Non-infectious
■ <i>Random</i>	=	Infection / Non-infection
■ <i>Centrilobular ground glass</i>	=	Non-infectious > Infection
■ <i>Perilymphatic</i>	=	Non-infectious

(2) Differentiation: infections? Non-infectious lung disease?

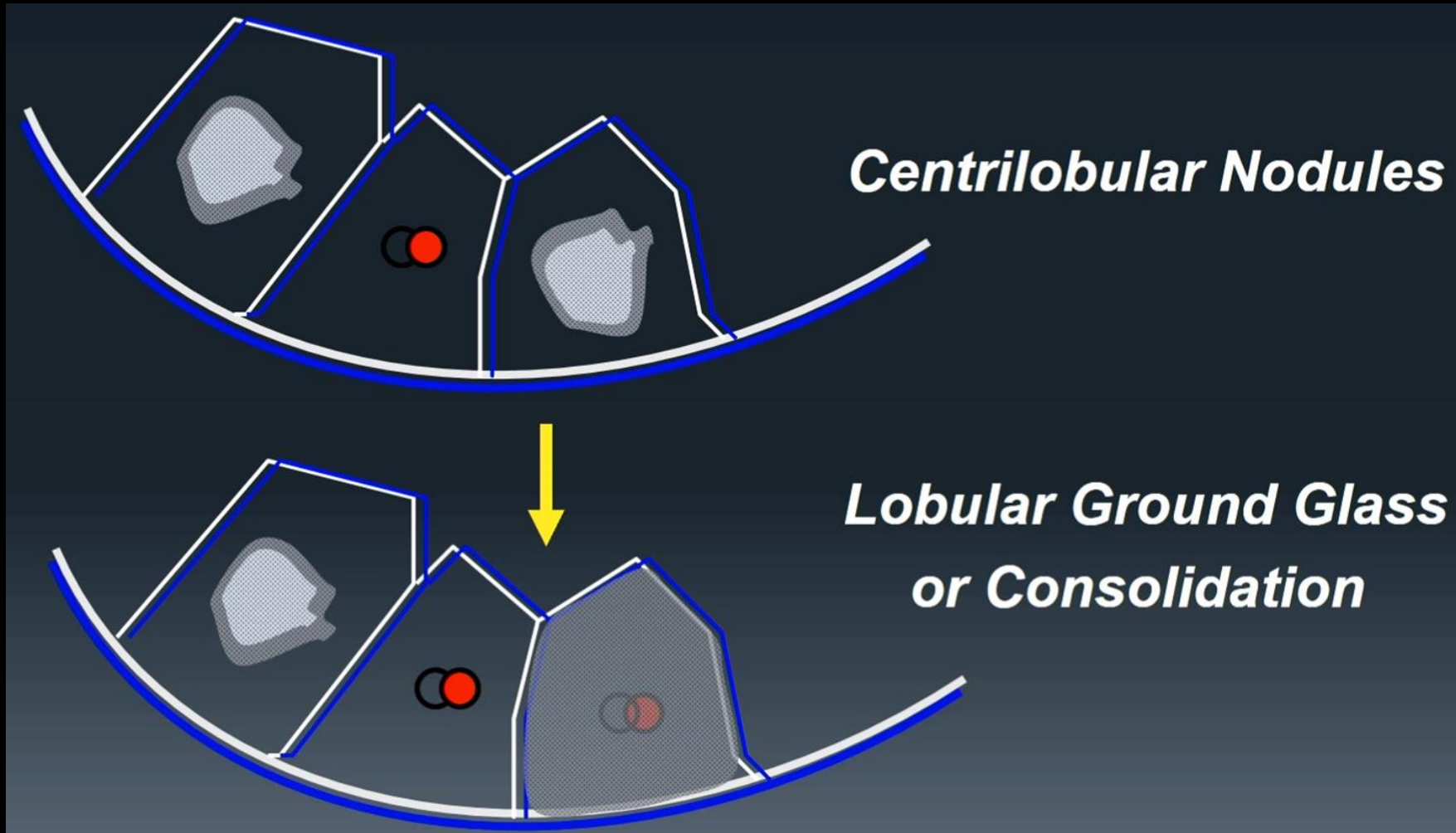
- Septal thickening
- Nodule patterns
- **Consolidation patterns**



(3) CT pattern: “Consolidation” pattern

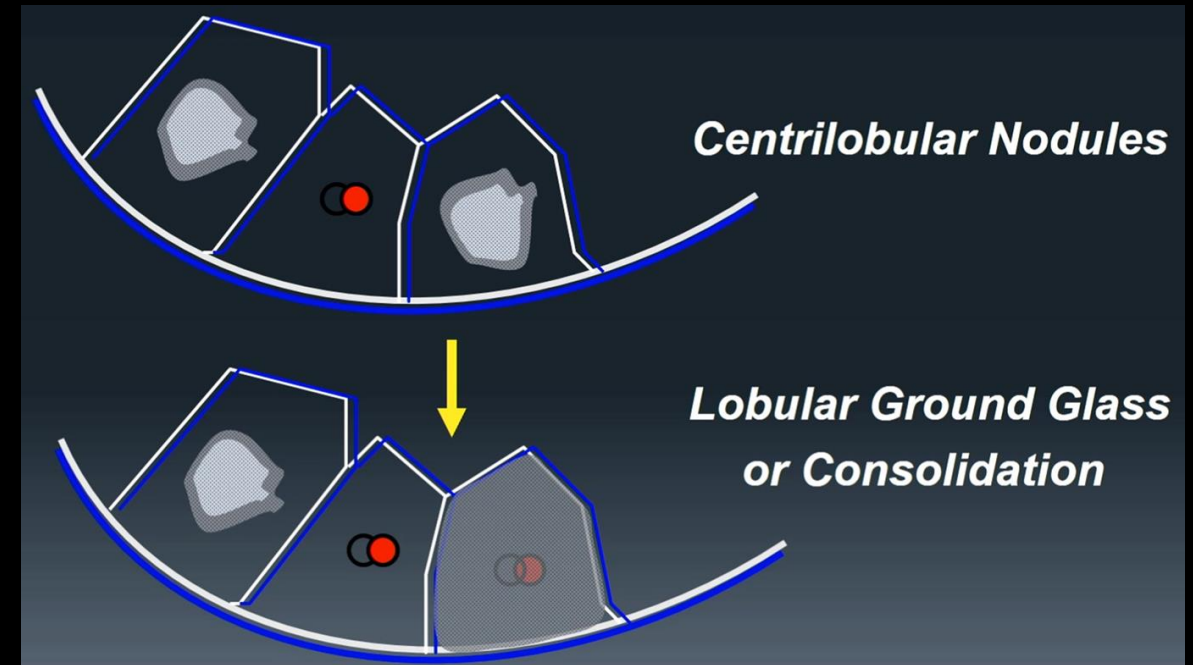
- Lobular Ground Glass or Consolidation : lobular opacities
- **Accompanying tree in bud nodules? Or peribronchial opacities?** => infections (high possibility) => bronchopneumonia (viral, bacterial)
- **PJP: CT pattern: often without airway abnormalities;**
but COPD with PJP?

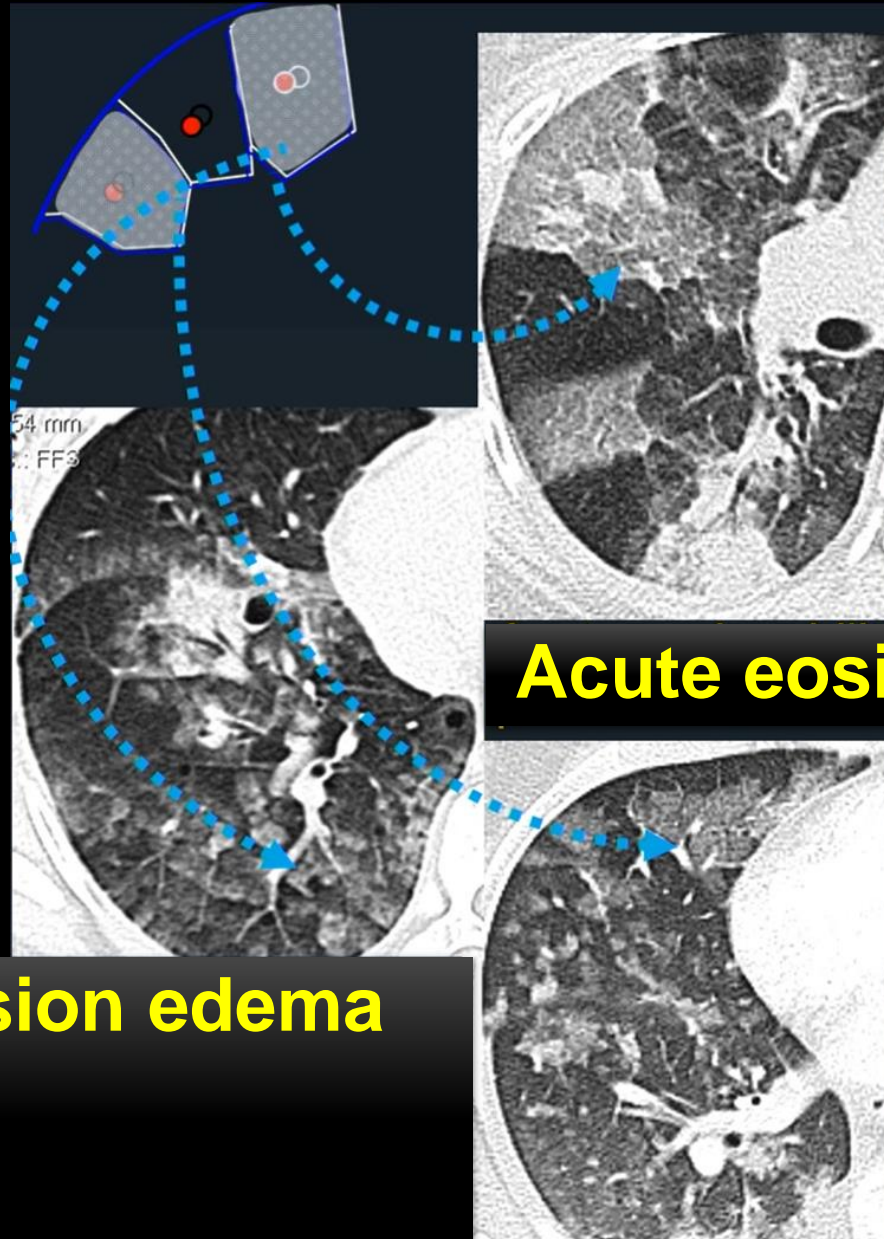
CT pattern: lobular opacity



CT Pattern: Lobular Opacities

- Infections
- Non-infectious
 - = Pulmonary edema
 - = Pulmonary hemorrhage
 - = Acute eosinophilic pneumonia
 - = Hypersensitivity Pneumonia





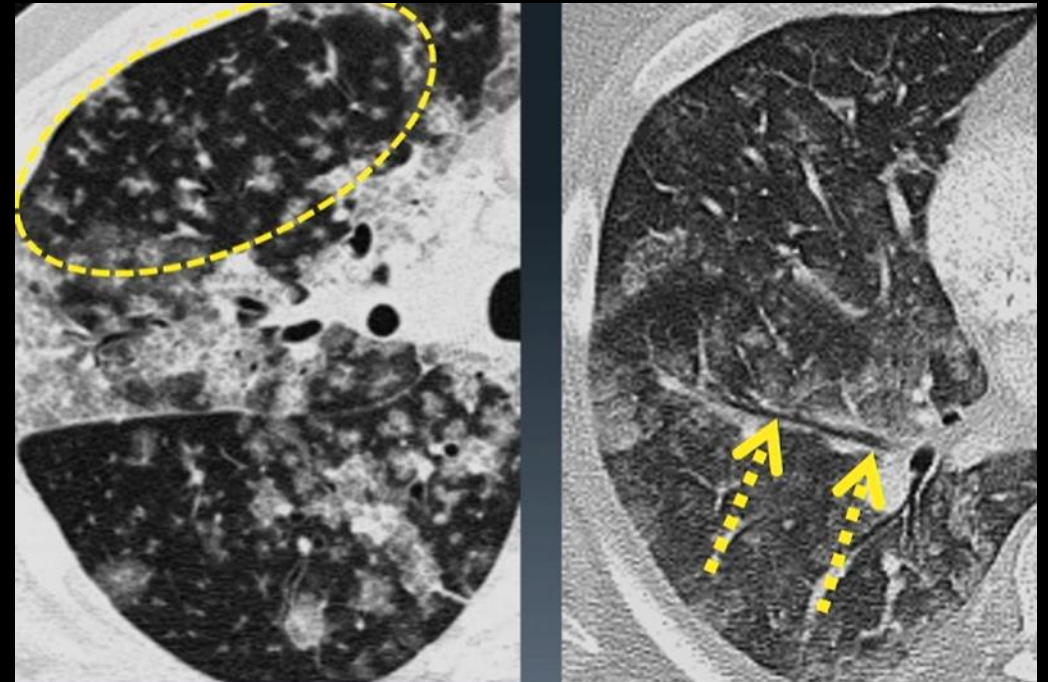
Acute eosinophilic pneumonia

Re-expansion edema

Fat emboli

CT Pattern: Lobular Opacities

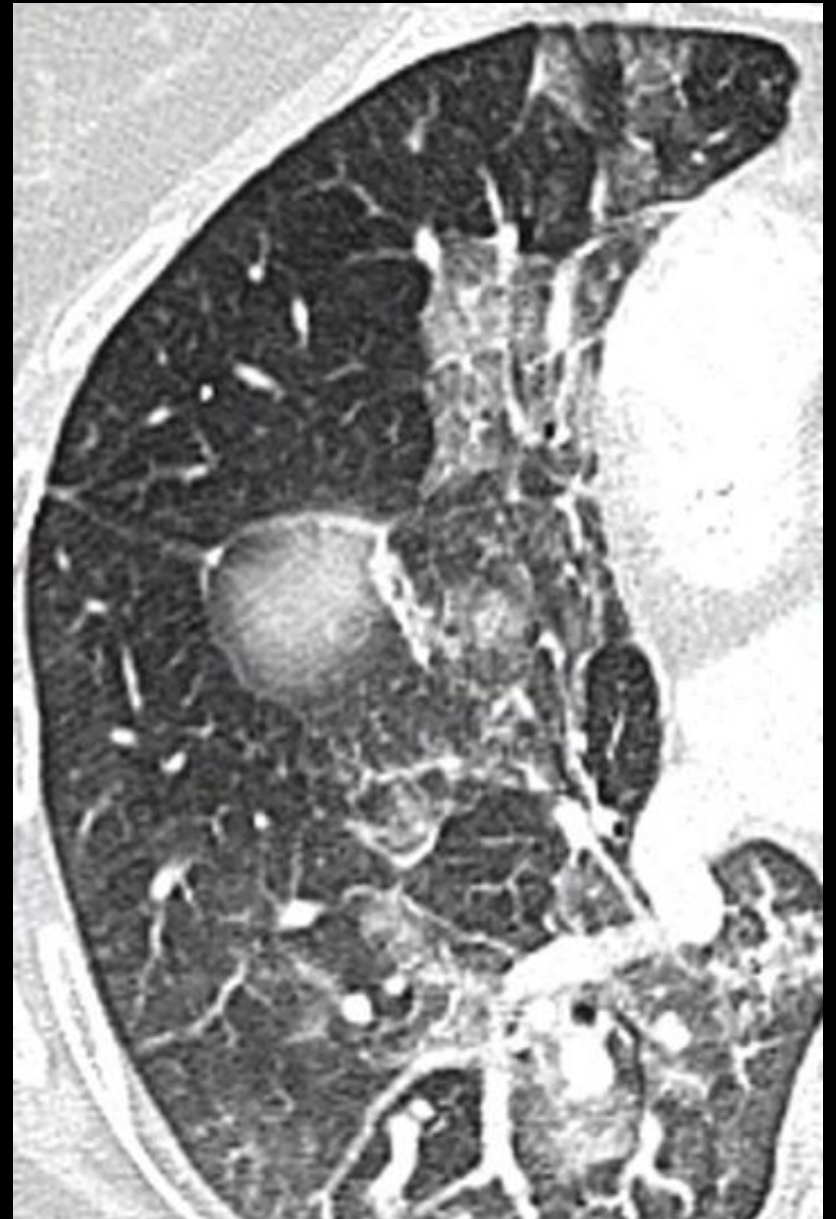- Infections
- Bronchopneumonia –Viral, Bacterial
- Many infections will demonstrate accompanying **tree in bud nodules** or **peribronchial opacities**
- An area of central lobular nodules; peribronchial thickening
- But! PJP often without these airway abnormalities (no TIB; no peribronchial vascular distribution)



Case: PJP

- But! PJP often without these airway abnormalities

(no TIB; no peribronchovascular distribution)



Case

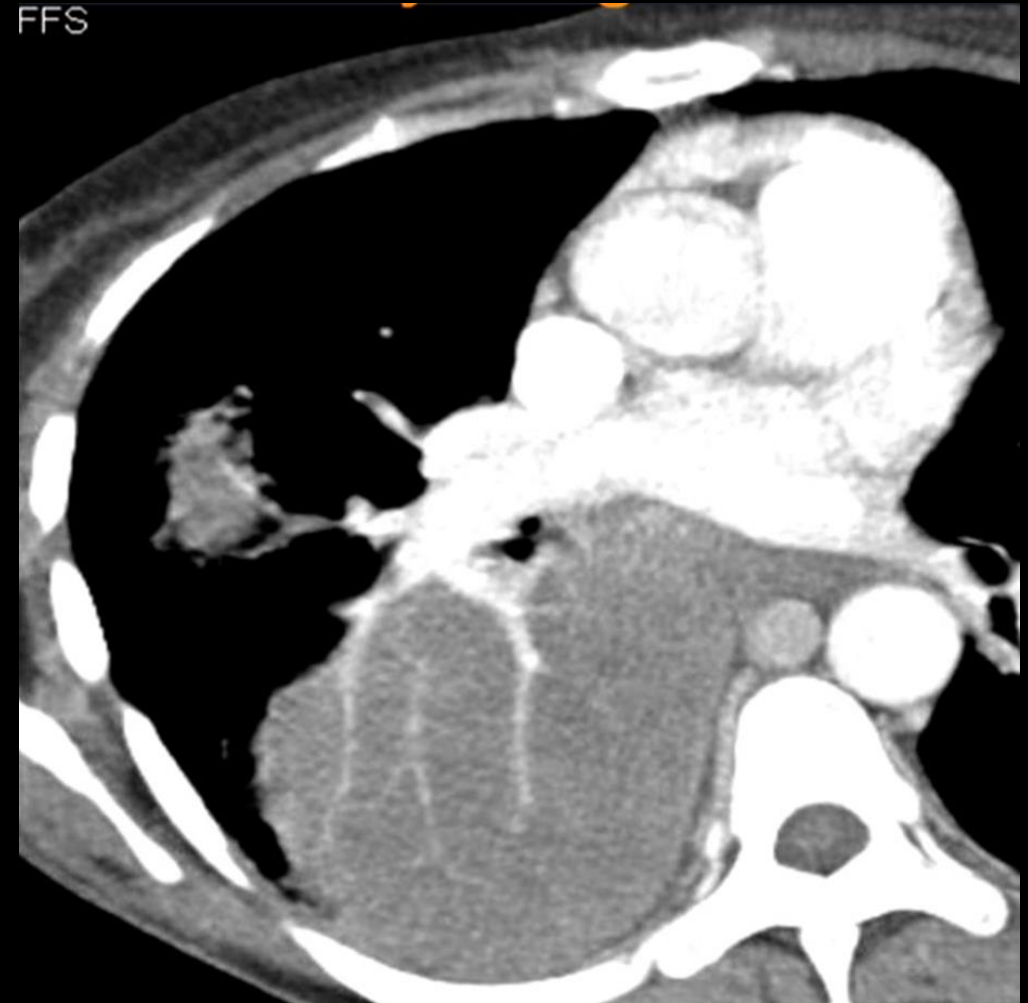- 56 Y/O Male
- ER: Shortness of breath for unknown duration.
- CxR and CNY CT chest
- **DDX:**

Pneumonia?

Obstructive atelectasis?

Passive atelectasis?

Invasive mucinous adenocarcinoma?





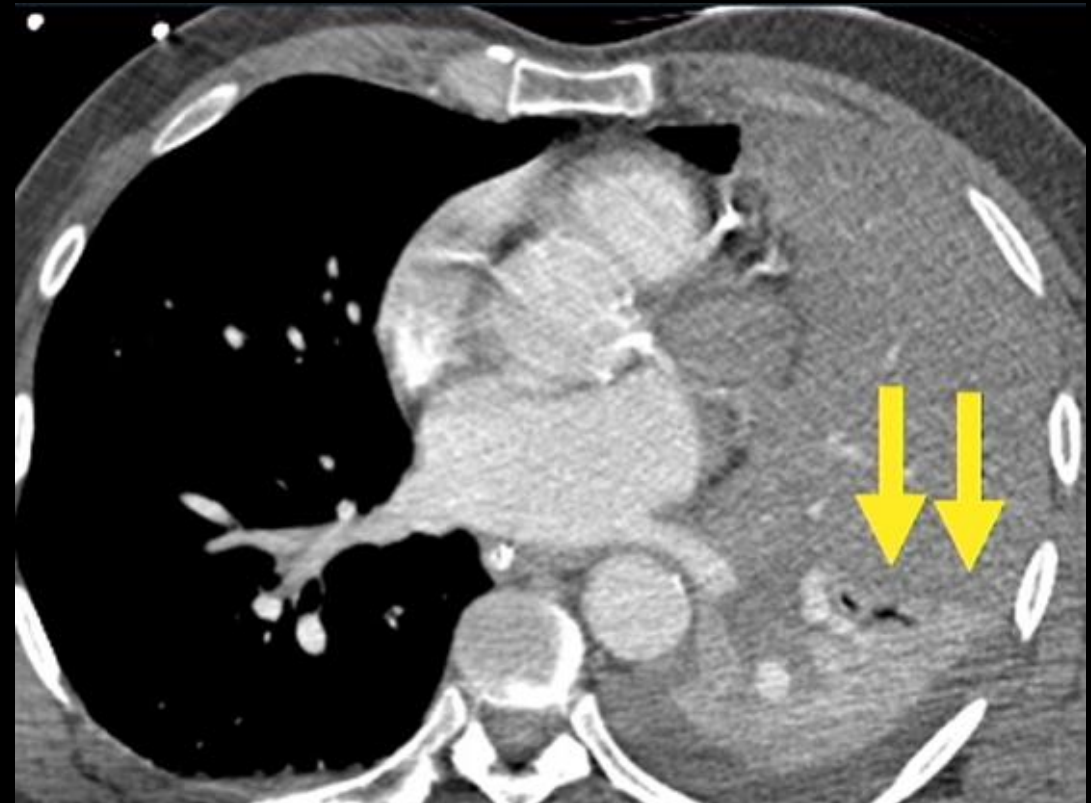
CT pattern: Atelectasis

- Non-segmental consolidation?
- Passive atelectasis?
- **CT with contrast**
- high attenuation post contrast?
- low attenuation post contrast?

CT pattern: Non-segmental consolidation vs “Non-aerated” lung from atelectasis

Passive atelectasis

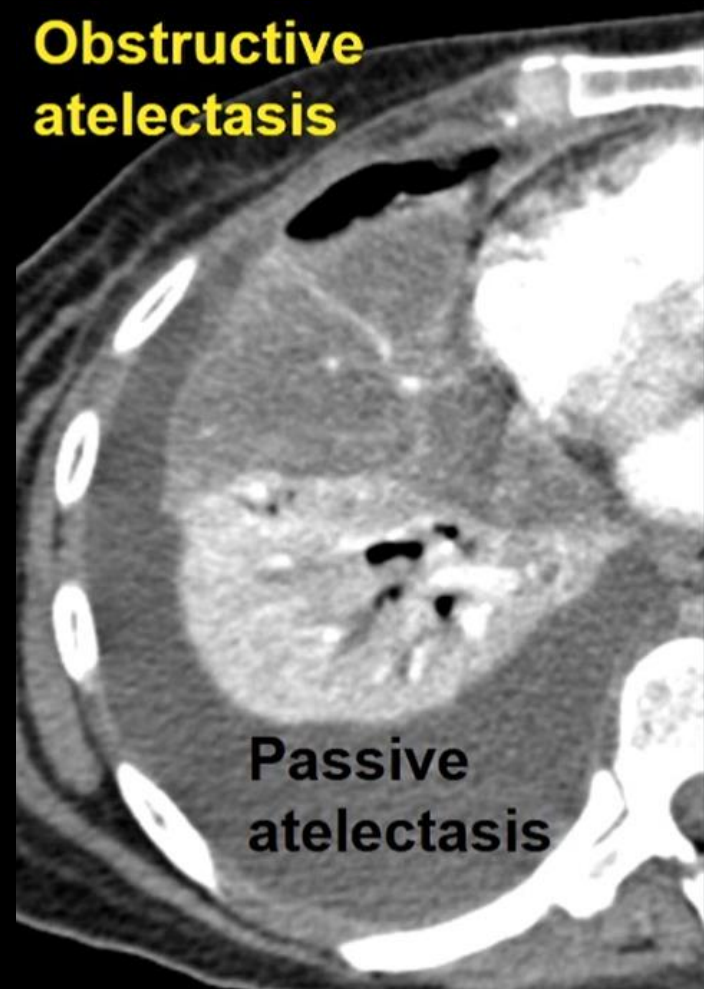
- Volume loss
- = Bronchi/vessels crowded
- = Fissures shifted
- = Areas < lobar more evident on CT than CxR
- Air bronchograms common
- High attenuation post contrast



CT pattern: Non-segmental consolidation vs “Non-aerated” lung from atelectasis

Obstructive atelectasis

- Volume loss variable (depending on how much secretions are behind the obstruction)
- Absent air bronchograms (usually)
- **Low attenuation**
- **Vessels well delineated peripherally**

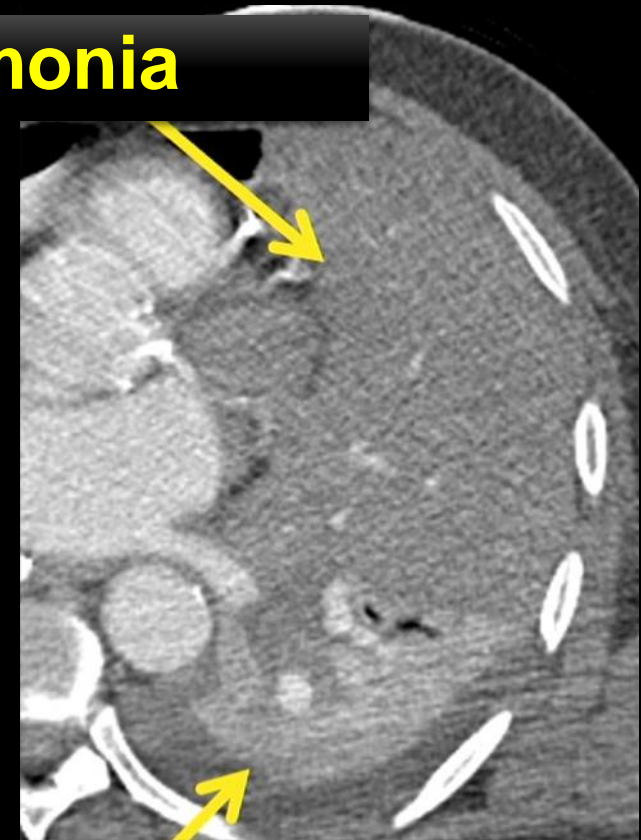


CT pattern Non-segmental consolidation (Pneumonia)

Pneumonia

- Volume loss: Minimal
- Air bronchograms: common
- **Low attenuation – post contrast**

Pneumonia



Passive atelectasis

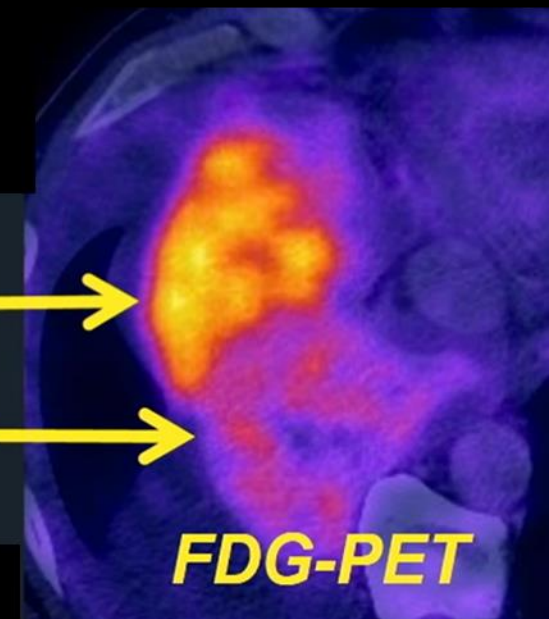
FDG-PET

- Pneumonia
- Utility of enhancement highest on CTA's
- Mean 62 HU on pulmonary CTA
- Threshold of 92 HU
- 97% sensitive; 85% specific
- 2016 JCAT, Edwards
- **Passive atelectasis: usually above 90 HU vs pneumonia: less than 90 HU;**
- FDG-uptake

Pneumonia →

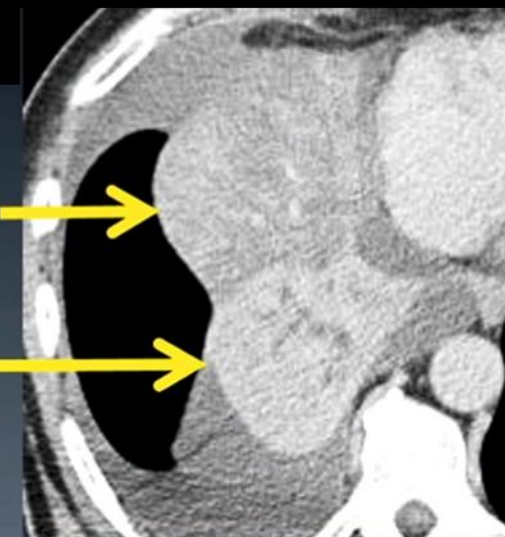
Atelectasis →

FDG-PET

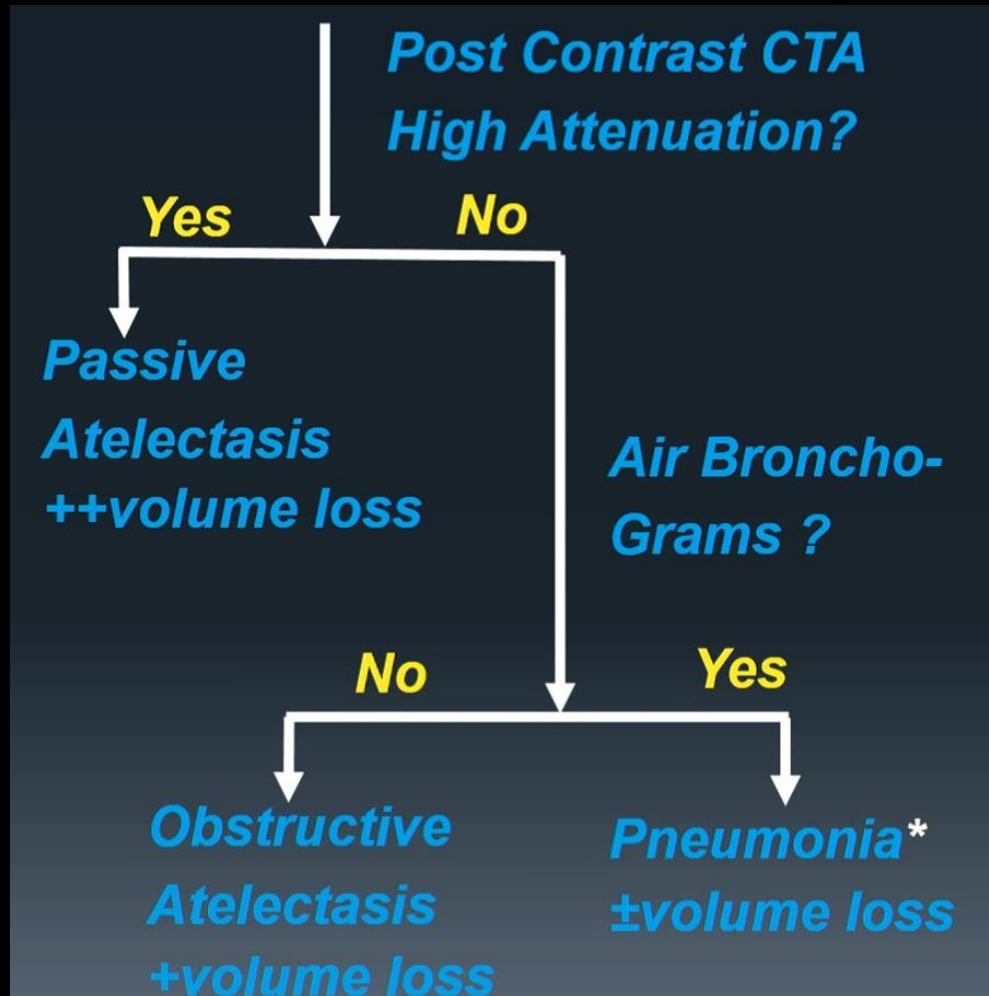


Pneumonia →

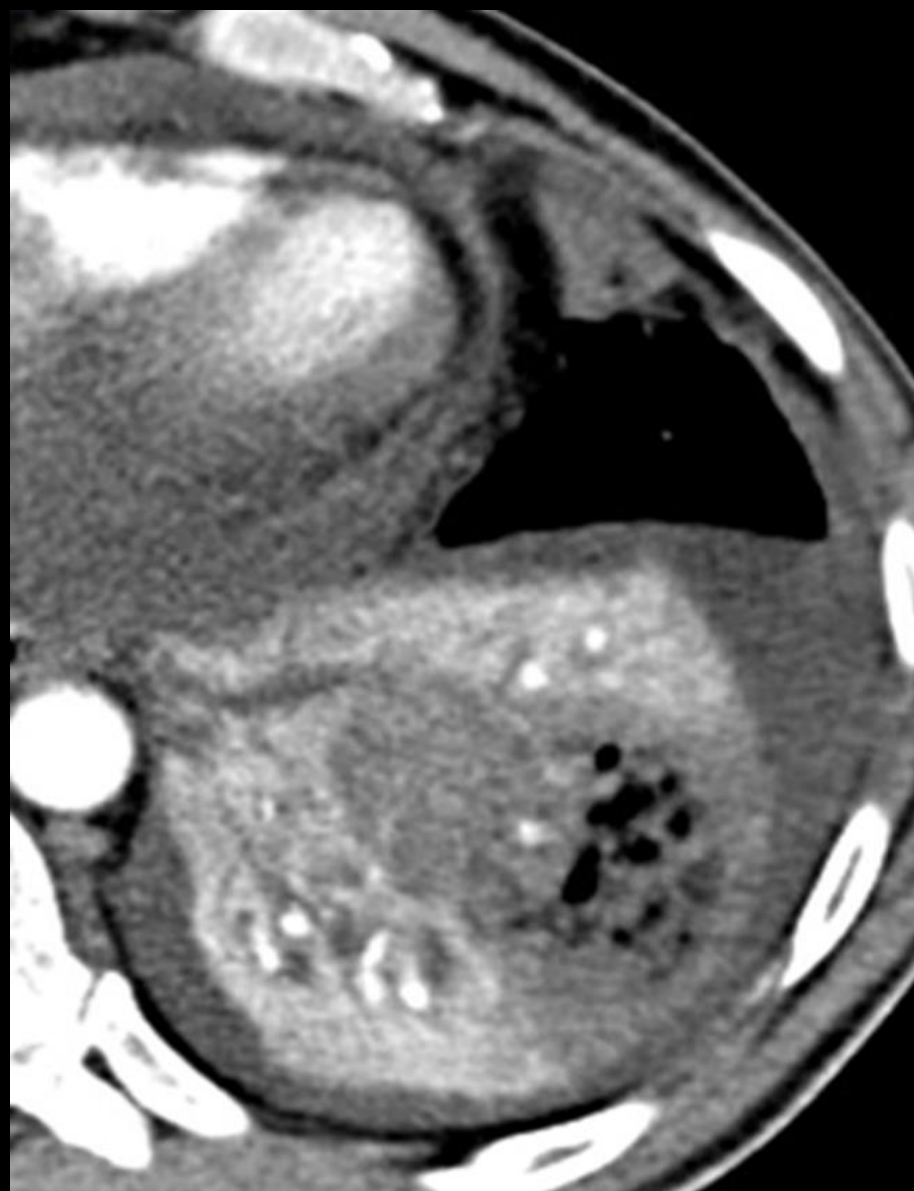
Atelectasis →

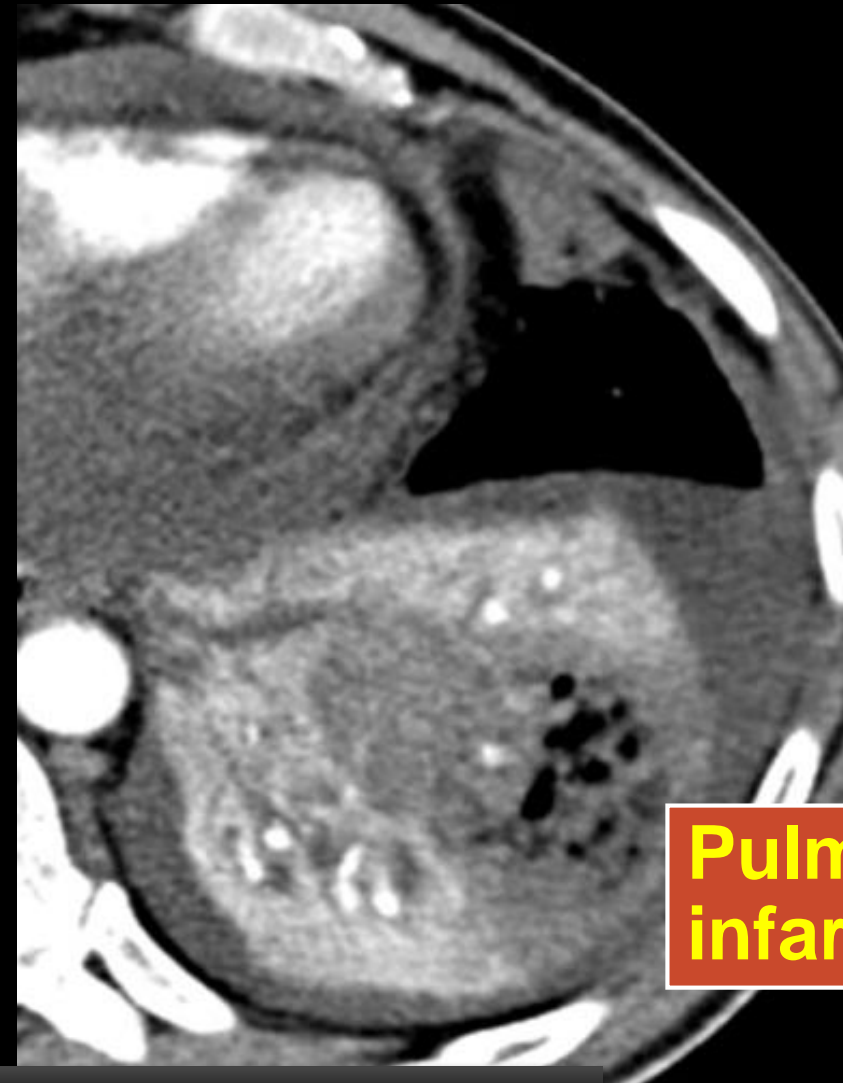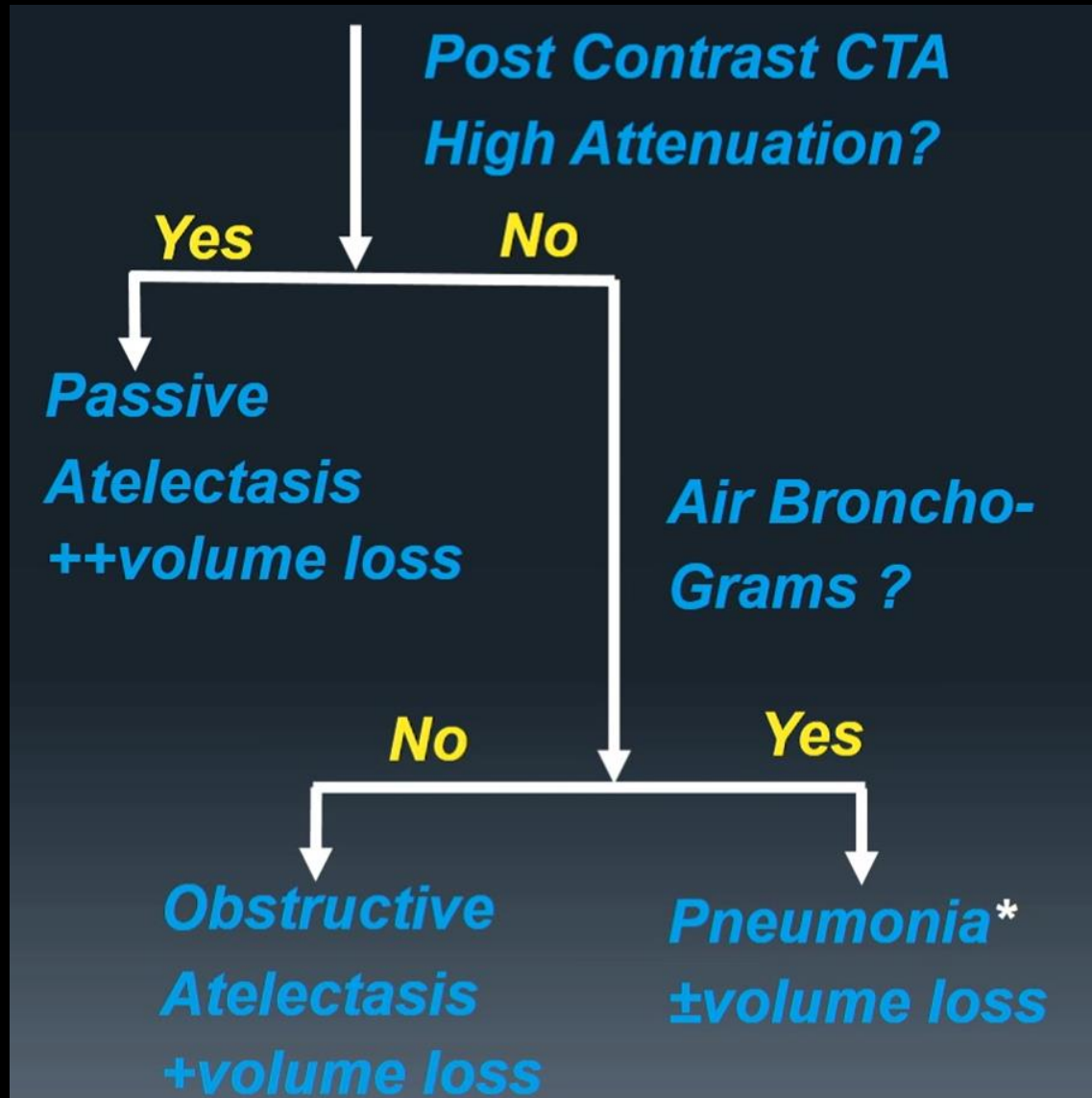


CT pattern Non-segmental opacities



Confounders: contusion,
pulmonary infarction,
adenocarcinoma





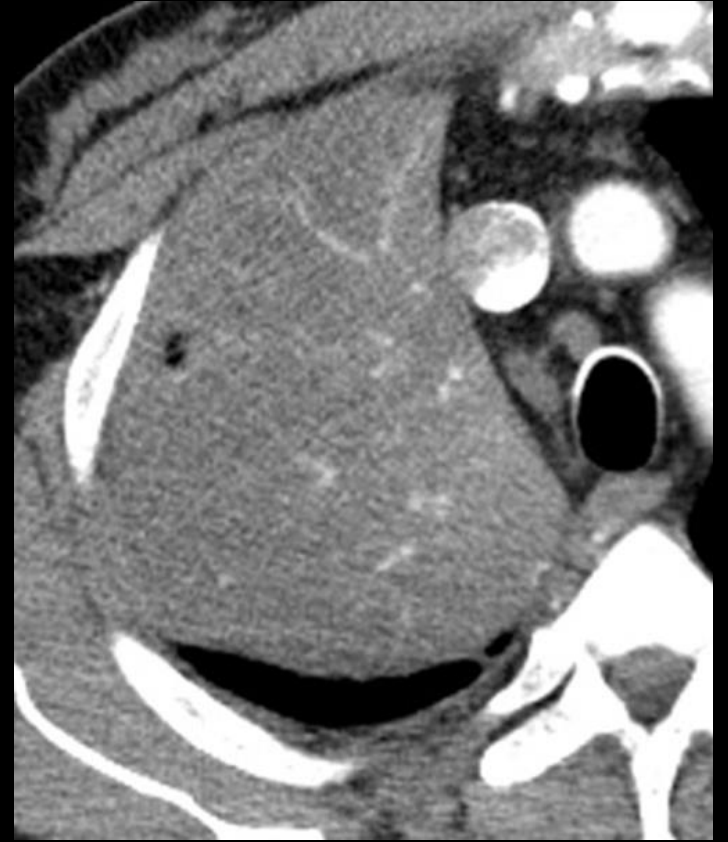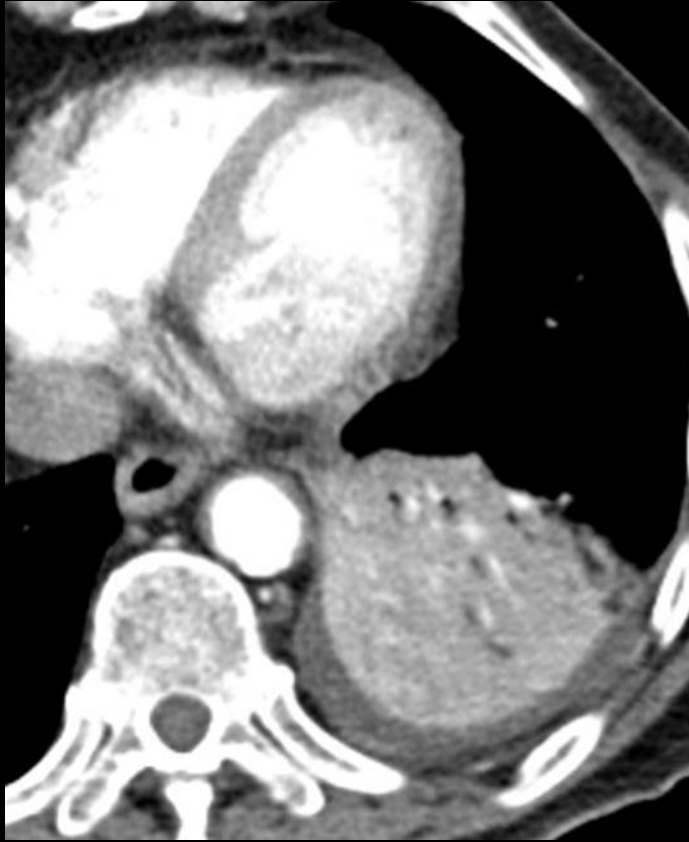
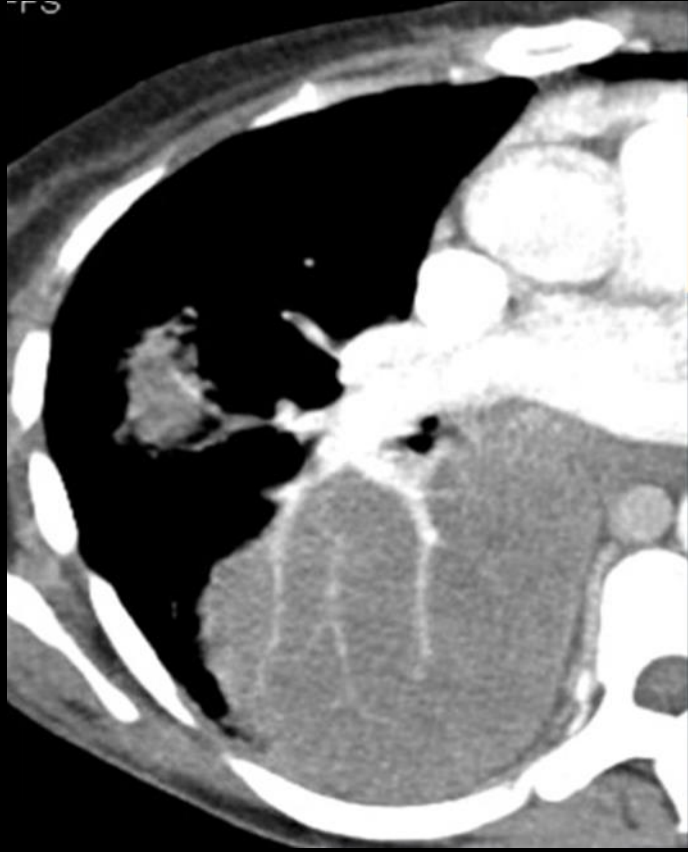**Pulmonary
infarction**

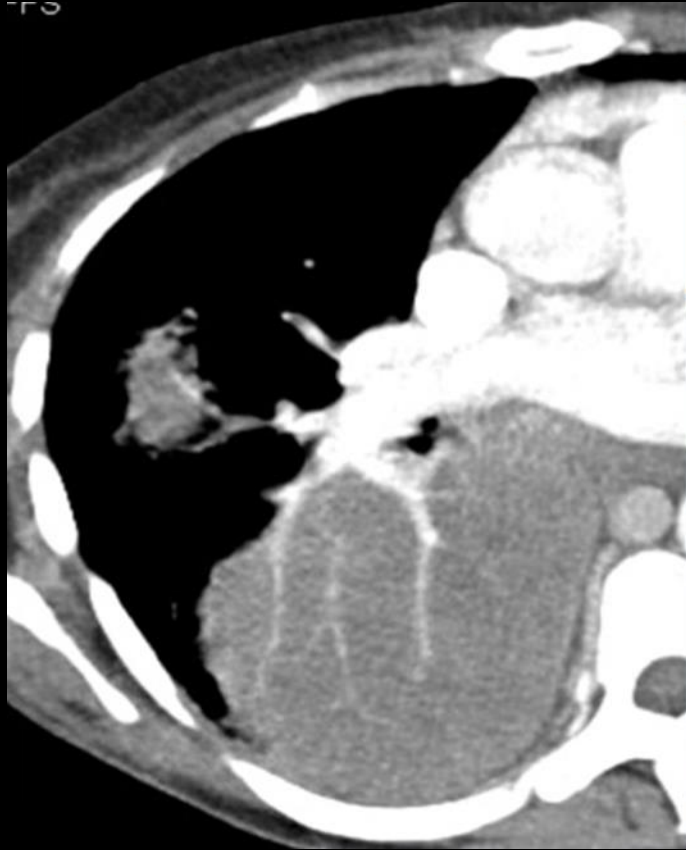Passive atelectasis

CT pattern Non-segmental "Non-aerated" lung: **subacute/chronic**

- Subacute to chronic – prior imaging diagnostic
- **Adenocarcinoma (Invasive Mucinous)**
- **Lymphoma** –variable enhancement (sometimes look like adenocarcinoma; sometimes higher enhancement)
- **GPA**
- **Cryptogenic organizing pneumonia**
- **Sarcoid**

TS

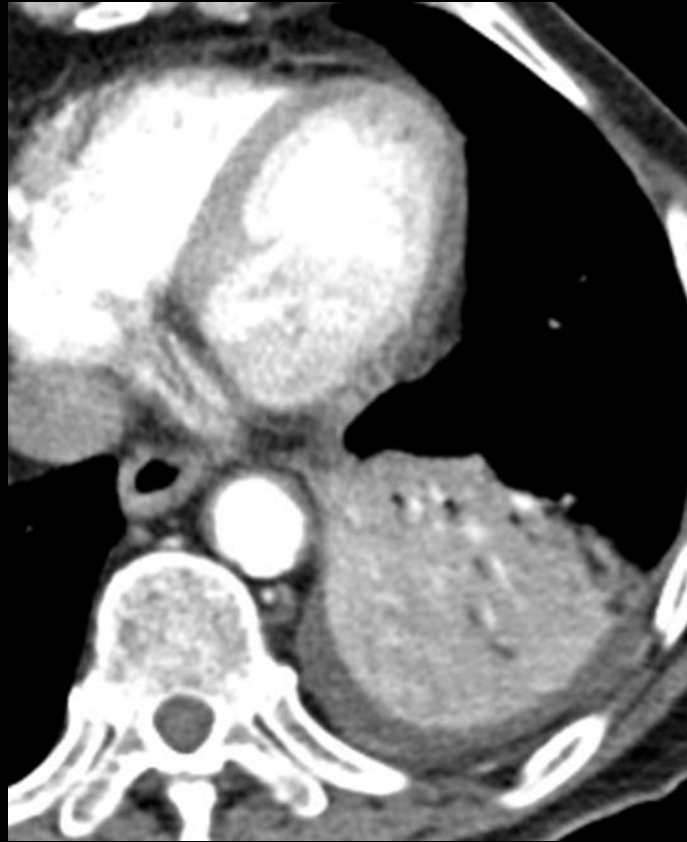




Adeno Ca:

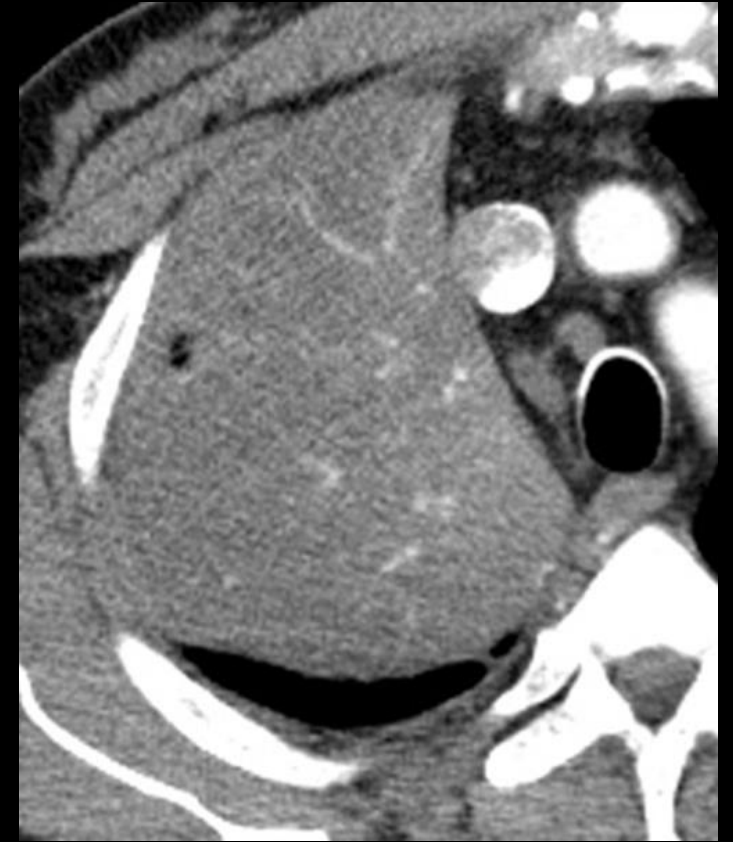airless lung with low attenuation and the vessels are very well delineated

07:16:07



Lymphoma

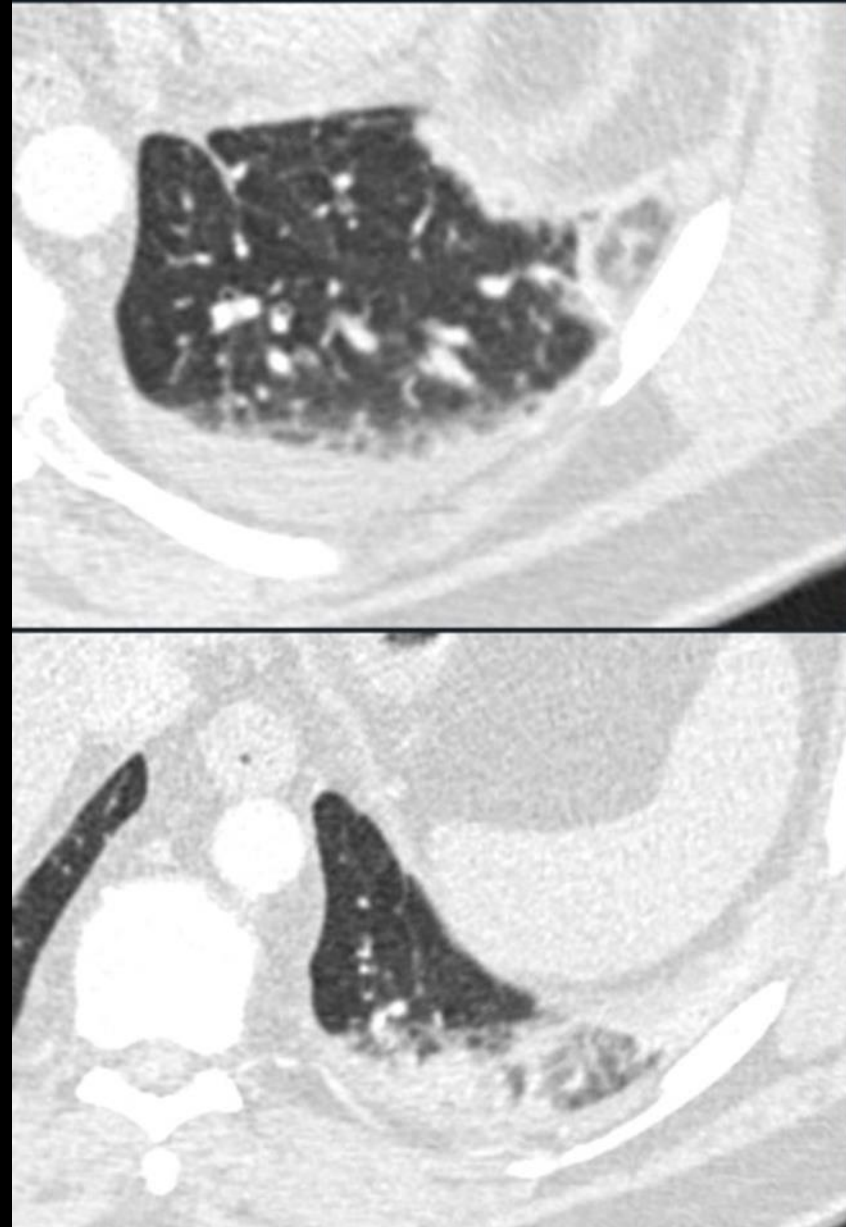
–variable enhancement (sometimes look like adenocarcinoma; sometimes higher enhancement)



79

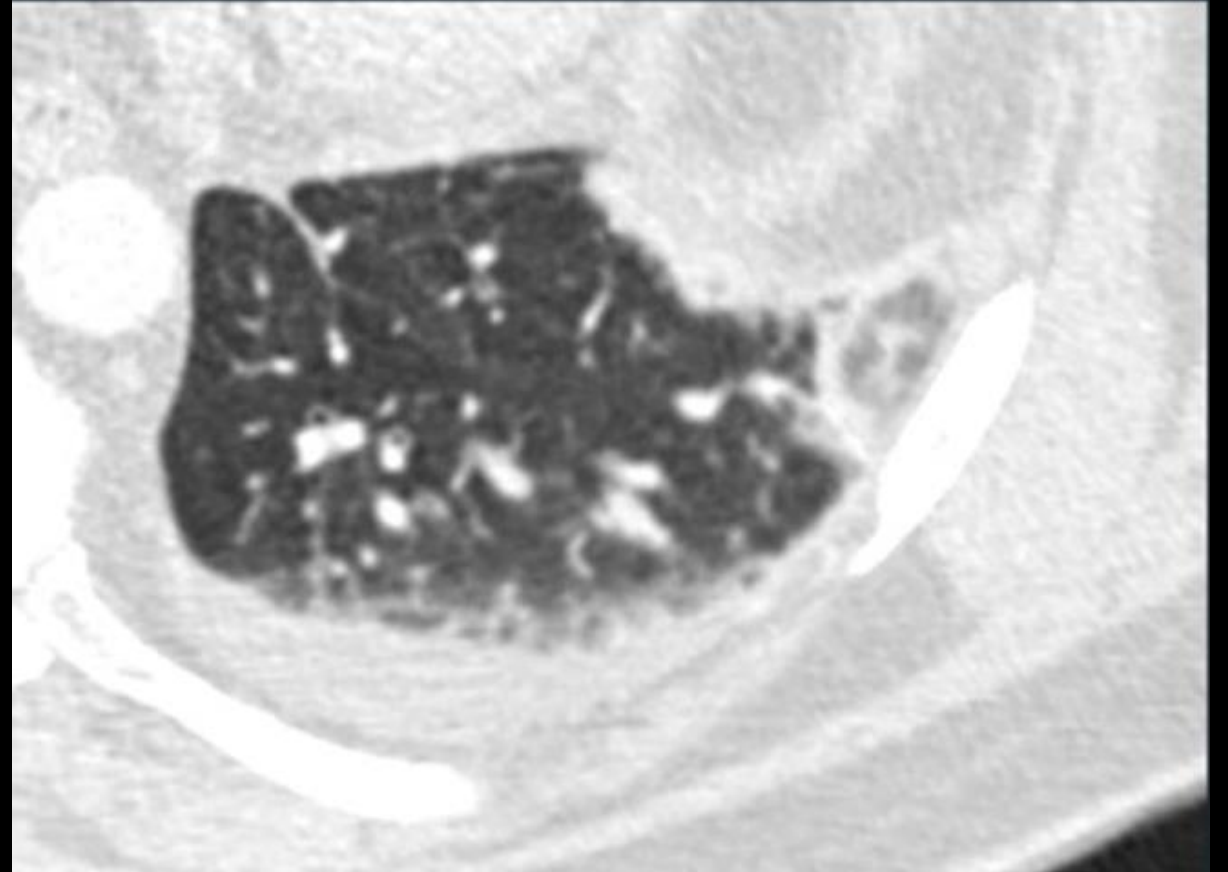
Case

- 42 Y/O Male
- **ER: for LUQ pain**
- Abdominal CT -> admission
- How to use abdominal CT for further differential diagnosis of lung diseases!
- **Next step?** Pulmonary CTA?
Empiric treatment for CAP?
US guided thoracentesis?
Echocardiogram for tricuspid valve?



Case

- 42 Y/O Male
- ER: for LUQ pain
- Abdominal CT -> admission
- Next step
- => **Pulmonary CTA!**
- => Some fluid but there is an area of consolidation with some **central lucency**.



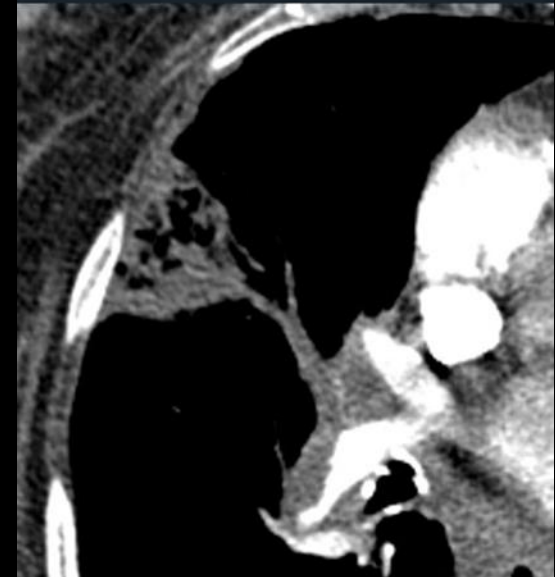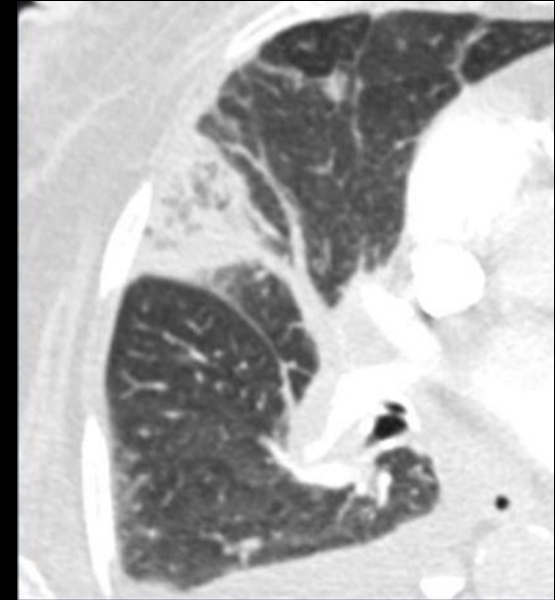
CT pattern: segmental opacities

- Infection: common
- **Non-infectious- occasional**
- *Pulmonary infarction*
 - = Lower lobes
 - = Peripheral
 - = Truncated apex
- **Vessel sign** = enlarged vessel leading to wedge shaped opacity : specific but uncommon (Great! But insensitive!)
- **Air bronchograms** are uncommon
- **Segmental opacity with central lucency!**

Non-specific in distinguishing
from infection

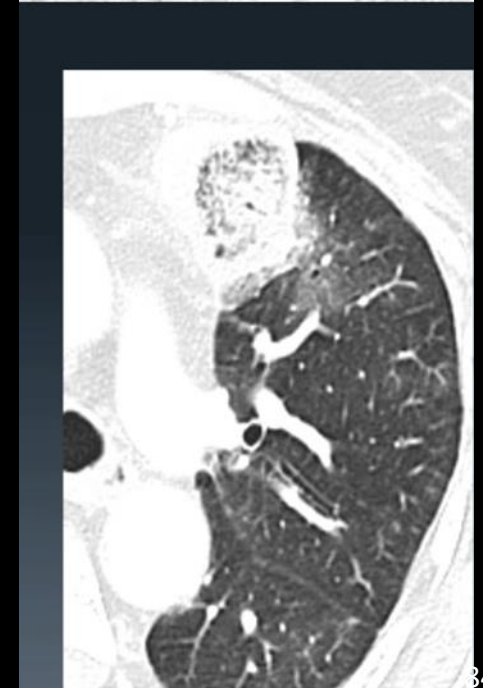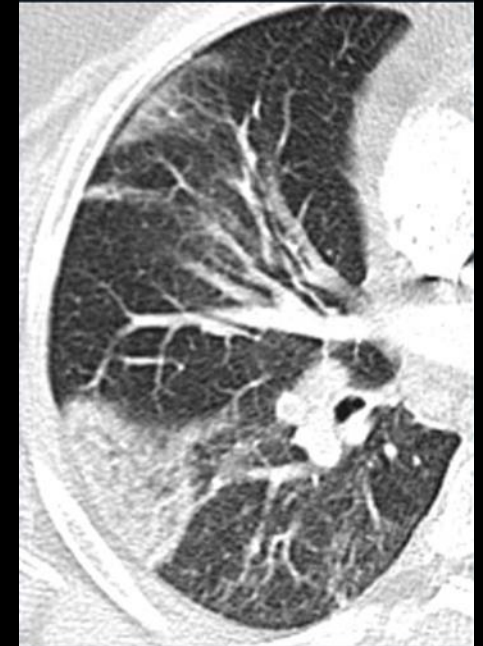**Segmental opacity with
central lucency!**

Vessel sign = enlarged vessel
leading to wedge shaped opacity



Pulmonary Infarction

- Segmental consolidation with central lucency
- 46% Sensitive
- 98% Specific
- Appearance fits description of “**reversed halo sign**”
- Differential varies widely depending on clinical setting

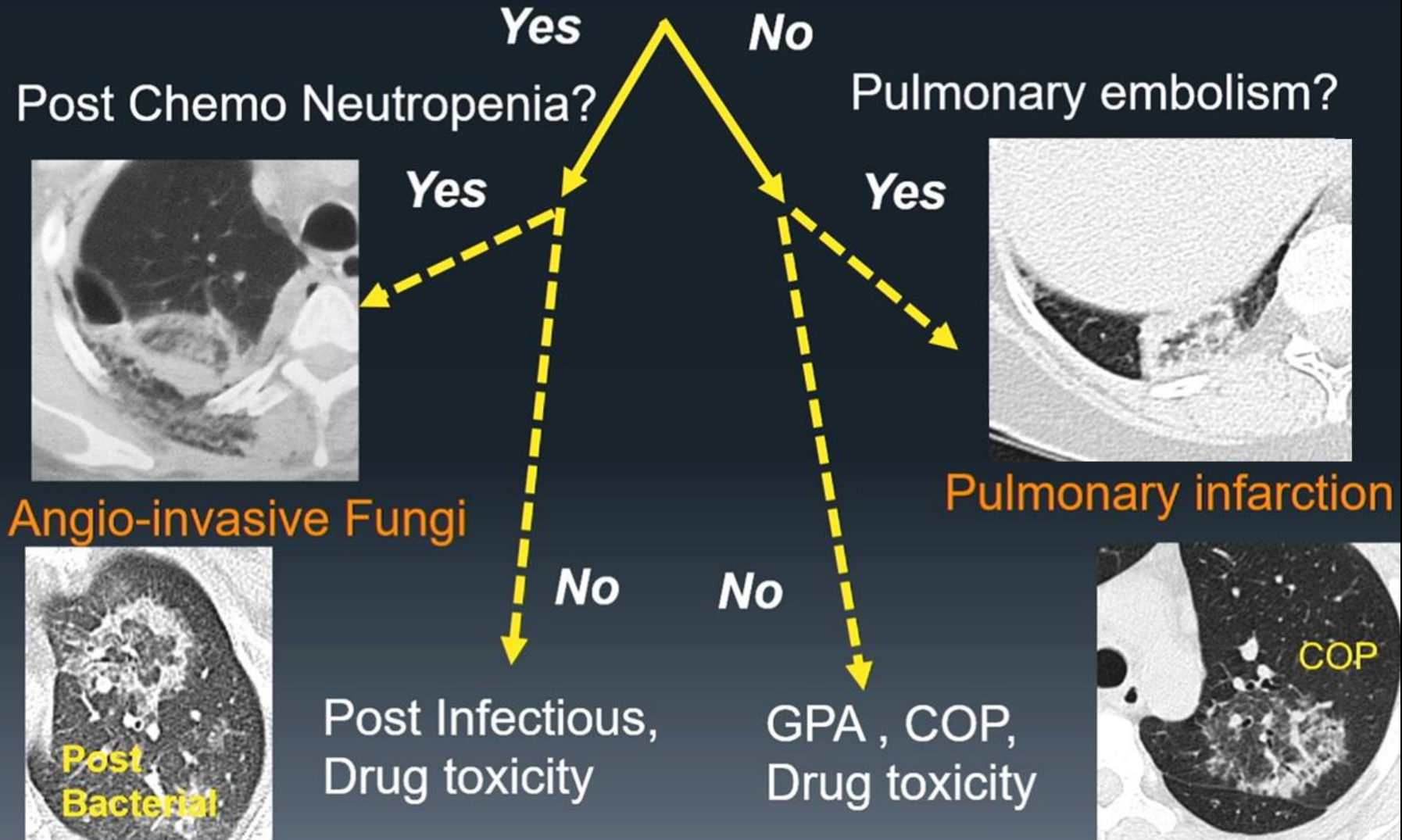


Differential diagnosis of “reversed Halo”

- Clinical signs of pulmonary infection?
- Post Chemo Neutropenia? -> Angio-invasive Fungi
- Post infections, drug toxicity
- Pulmonary embolism? Pulmonary infarction
- GPA, COP, Drug toxicity

Reversed Halo sign

Clinical signs of pulmonary infection ?

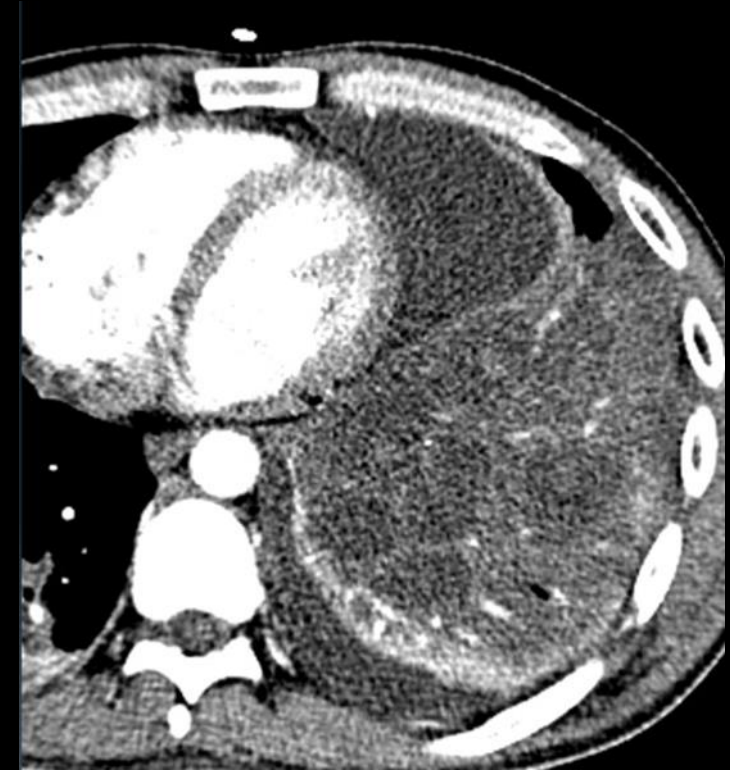

Pulmonary Infections

- (1) Detection of infection: CxR -> CT chest
- (2) Differentiation: infections? Non-infectious lung disease?
- **(3) Infection: complications**
- (4) Specific pathogens: Chronic fibrocavitary disease

Complications of Pneumonia

- Pleural disease
- Lung necrosis
- (1) **Low attenuation** parenchymal with and without abscess formation – common
- (2) **Abscess** : common
- (3) **Pneumatocele** – occasional
- (4) **Pseudo-aneurysm** – rare

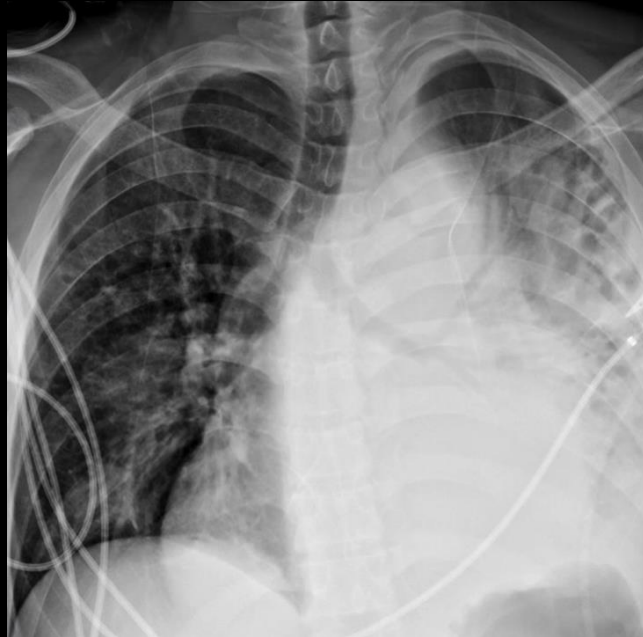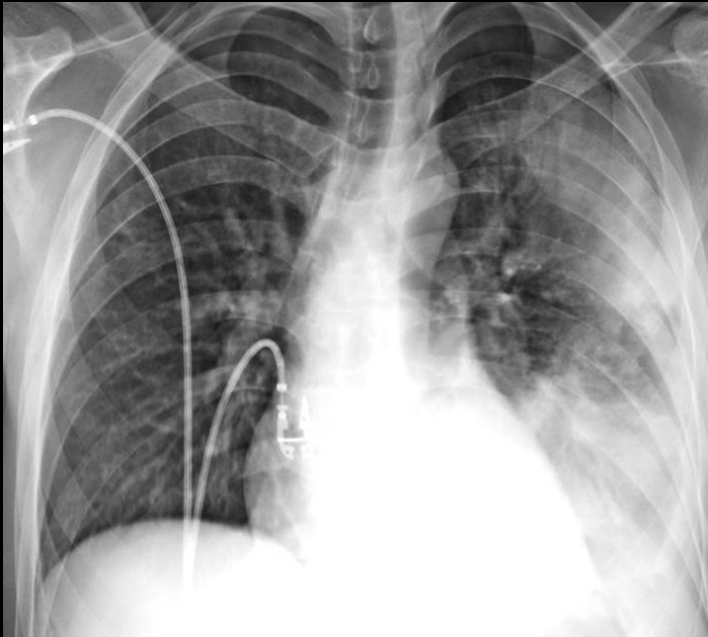


Pneumonia: Complications

- Pneumonia -> Lung abscess -> empyema -> mixed: cancer?
TB? Foreign body? -> bronchiectasis ? Pulmonary
sequestration? Hiatal hernia? Fistula?
- Pleural disease?
- Lung necrosis :
= low attenuation parenchyma -> abscess formation ->
Pneumatocoles -> Pseudo-aneurysm

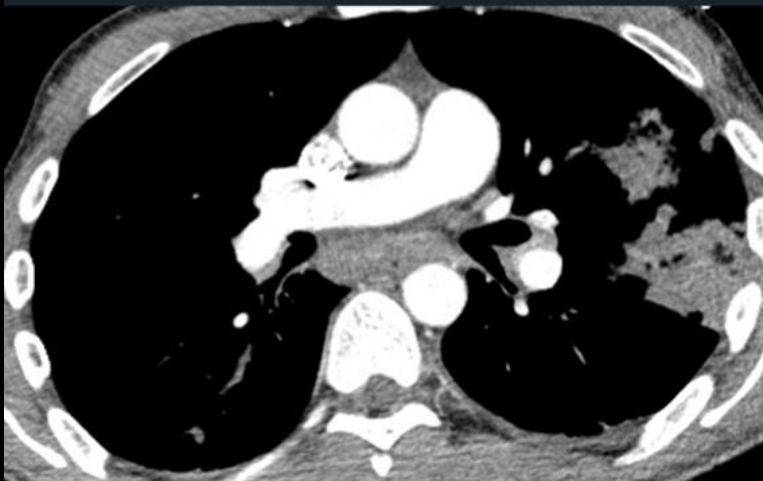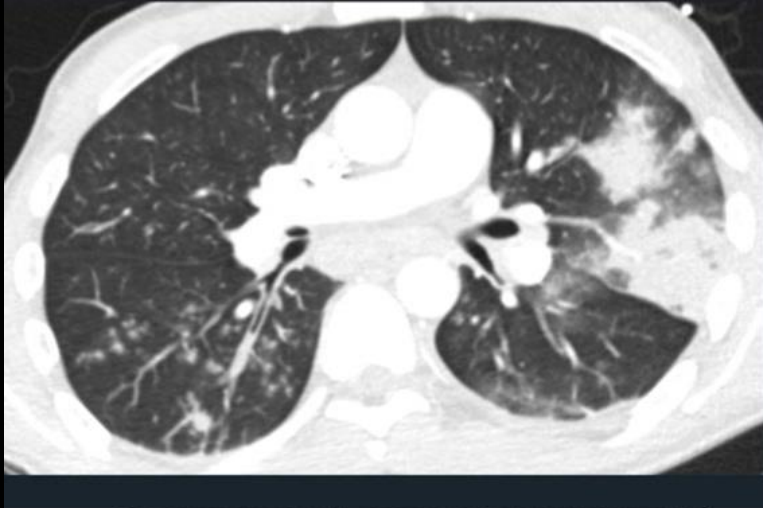Case

- Community acquired pneumonia – course
- Day 1 vs Day 6

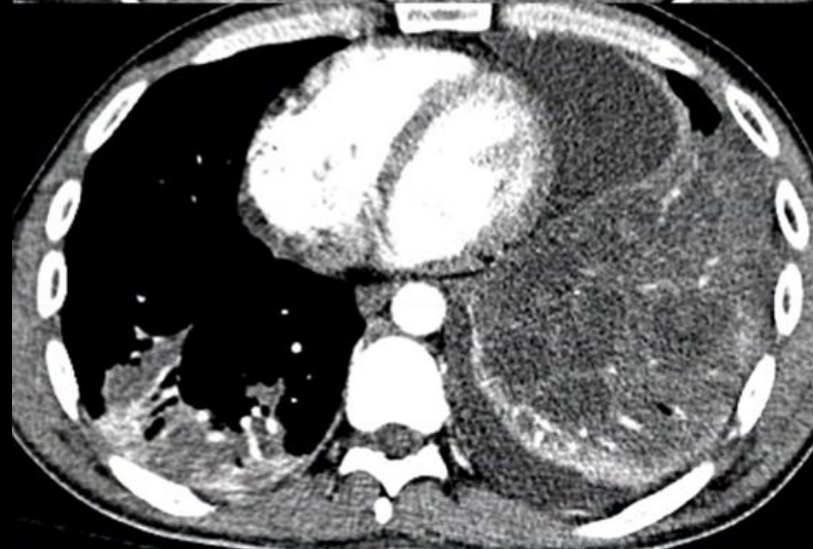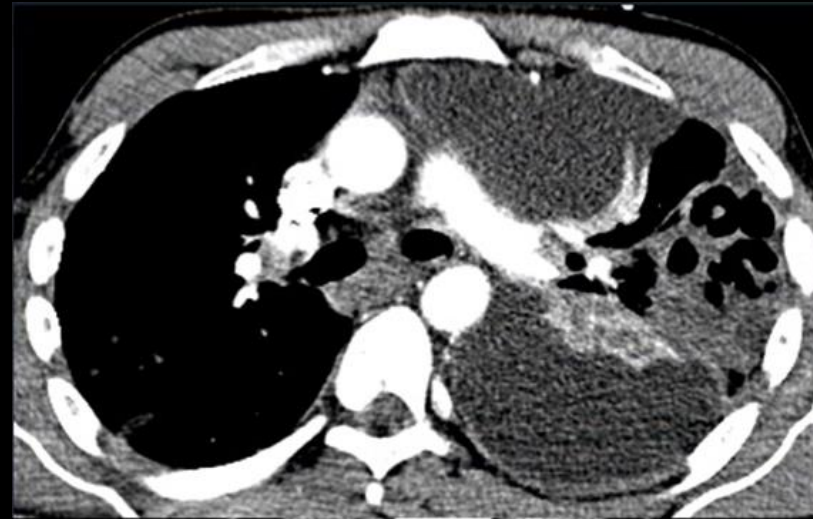


■ Community acquired pneumonia – course **MRSA pneumonia**

■ Day 1



Day 6



Pulmonary necrosis

- Diffuse necrosis
- Non enhancing lung parenchyma approaching water attenuation
- Without discrete margin
- Can have associated **gas locules**
- Staphylococcal pneumonia (PVL toxin?), pneumococcus, Klebsiella
- Prolonged hospital stay (**antibiotics treatment: duration?**)

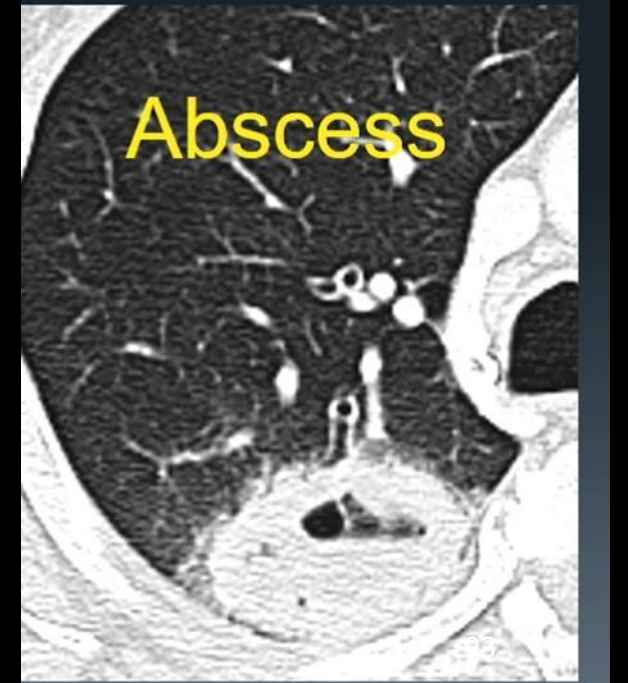
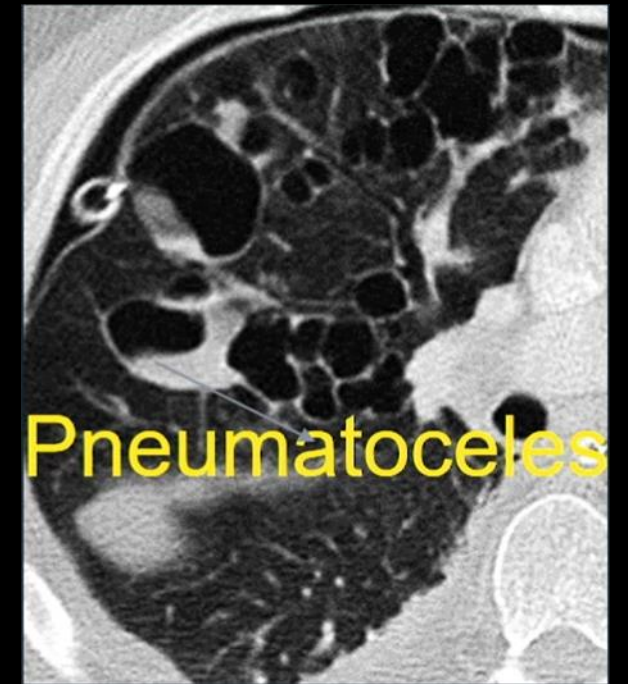
Pneumatoceles

Pneumatocele

- Focal necrosis allows air to dissect into parenchyma
- Displaces parenchyma rather than destroying it
- Thin walled, associated with pneumothoraxes

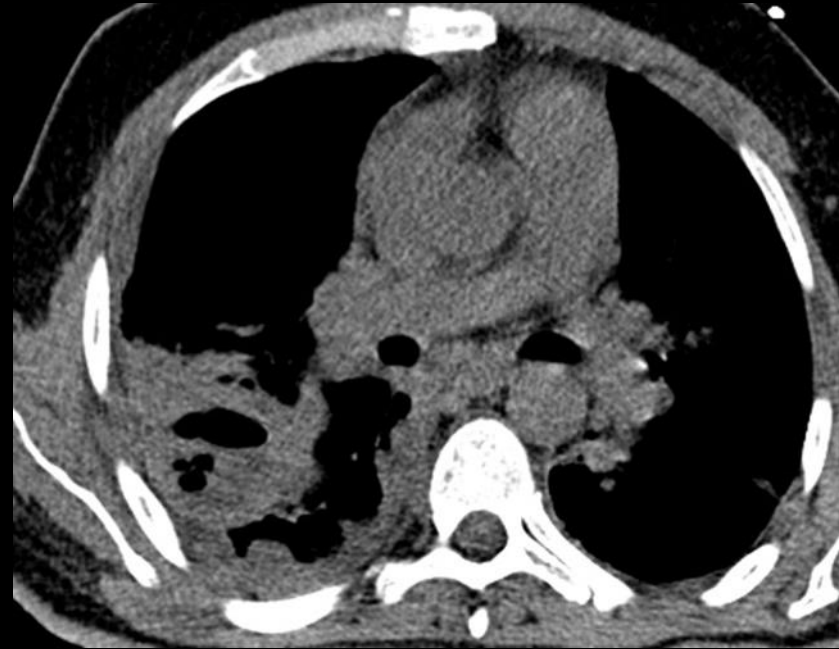Abscess

- Thick, irregular walls
- Destroyed lung, vessels and bronchi may end abruptly at margin



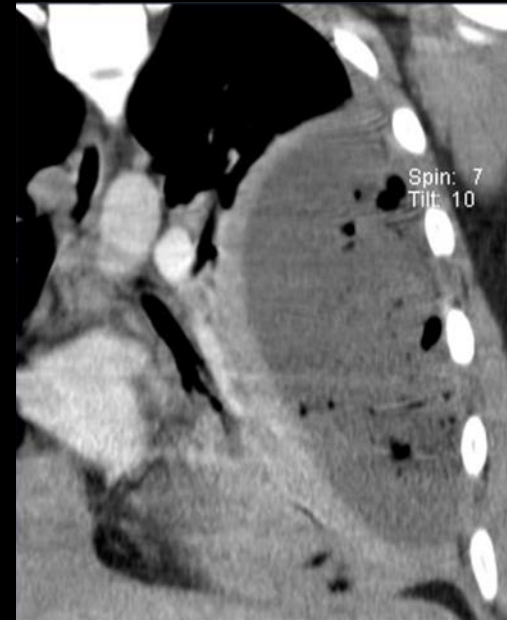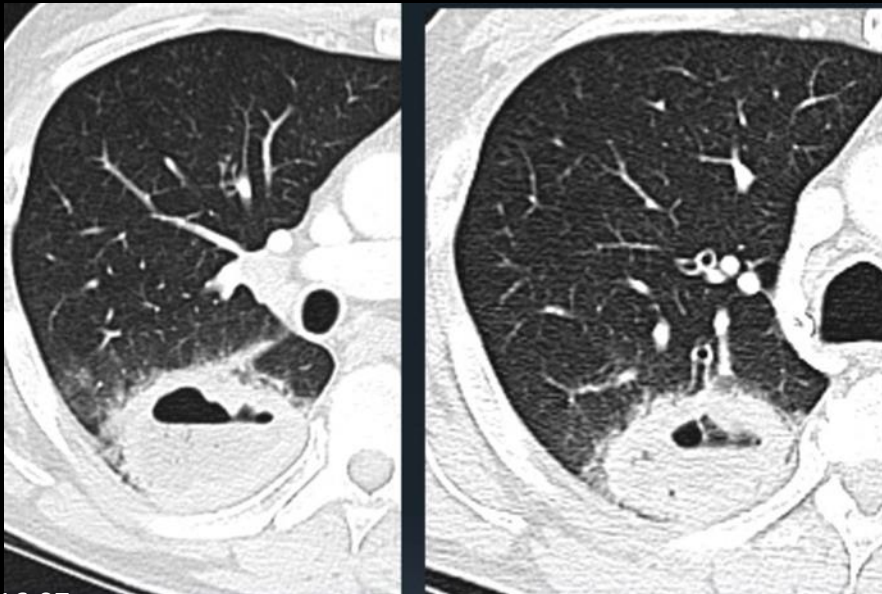
Lung abscess

- Empyema: Drain
- Lung abscess: Drain or not?



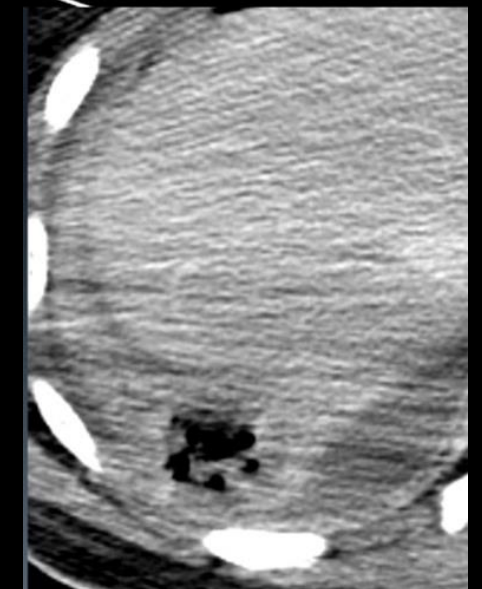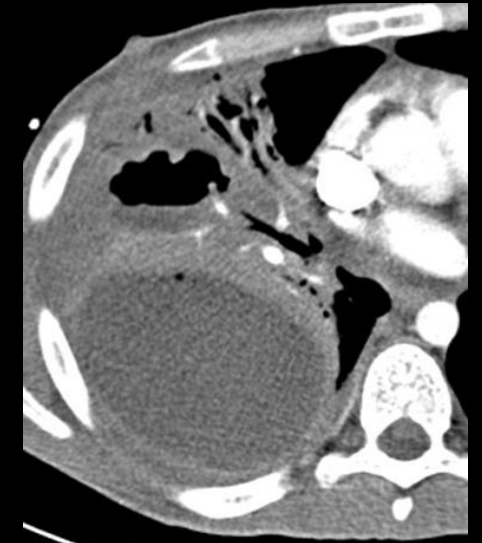
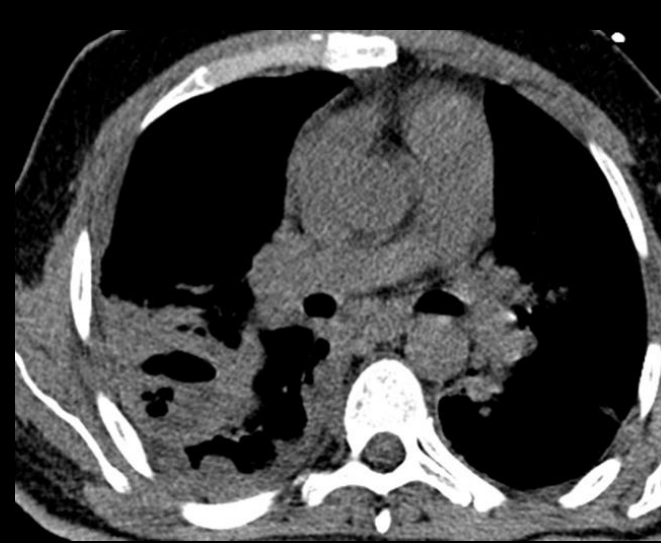Abscess vs Empyema

- **Abscess**: Round, irregular inner margin, truncates vessels/bronchi
- **Empyema**: lenticular/smooth inner margin/deviates vessels/bronchi (push vessels and bronchi aside);



CT of complications of pneumonia - Necrosis

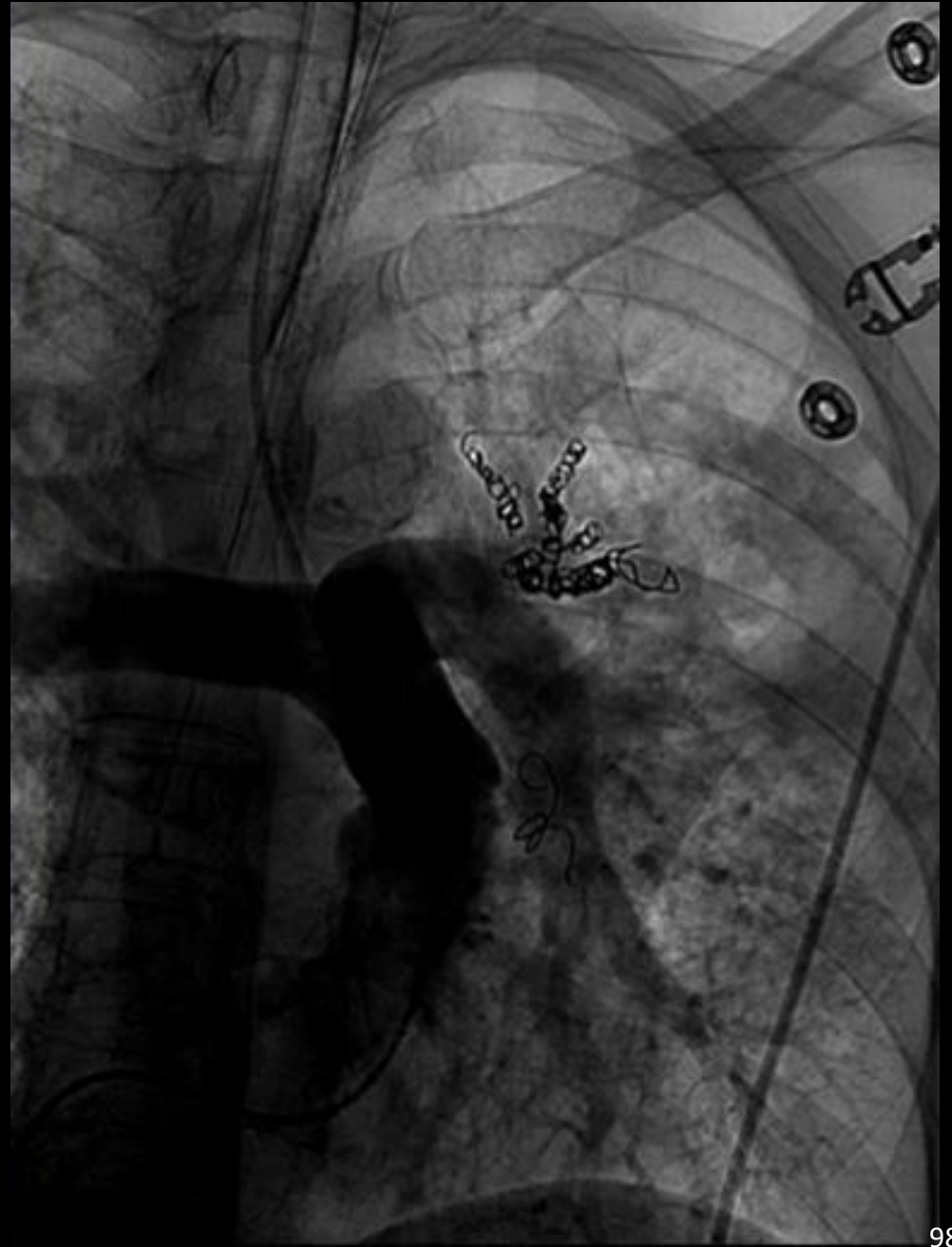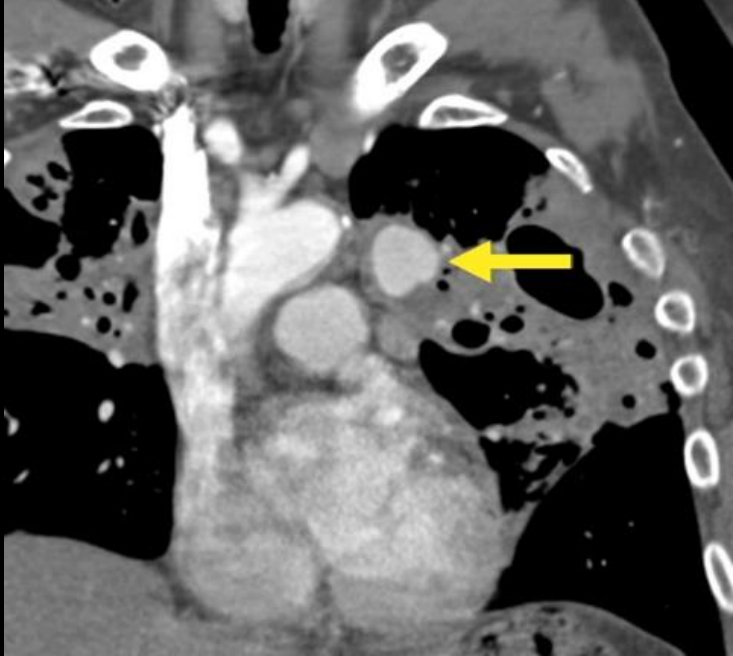
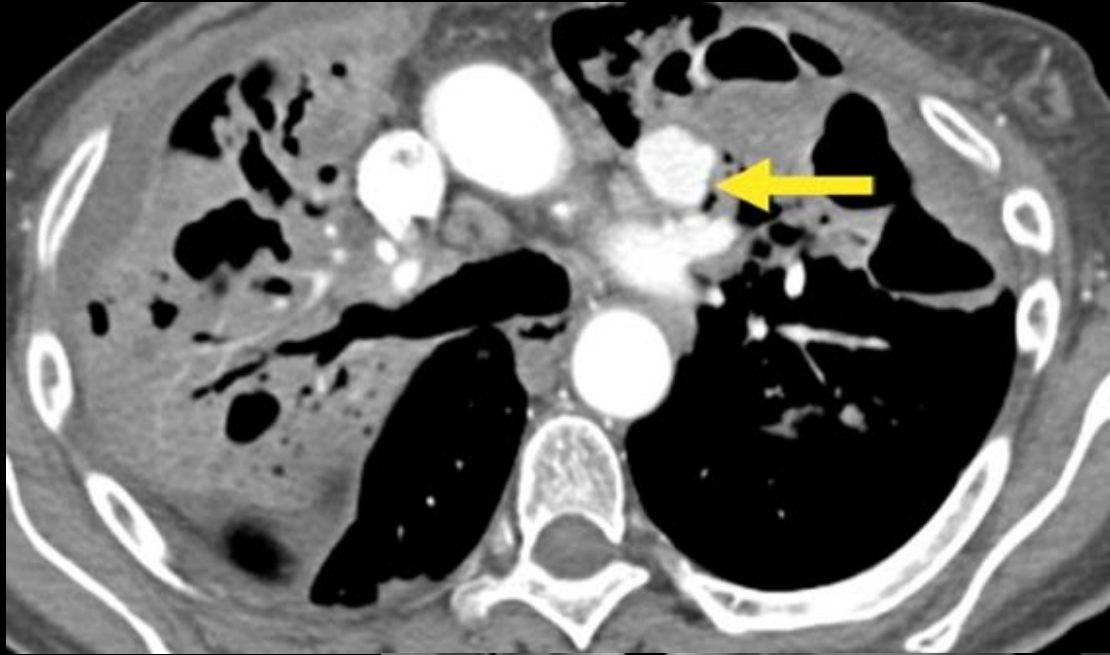
- Underlying lung abscesses present in 10-50 % of empyemas, probably due to rupture into pleural space
- Catheter drainage can transform unruptured abscess (without empyema) to ruptures abscess
- Example: 3 days later: lung abscess -> multilocular empyema;



Pulmonary artery pseudoaneurysm

(1) Direct extension from necrotic pneumonia

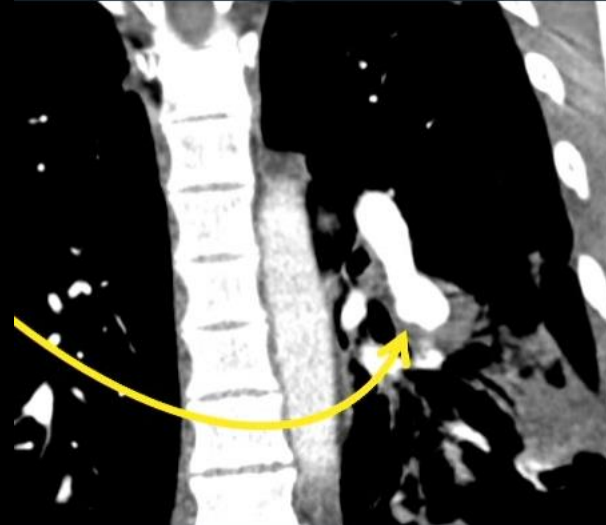
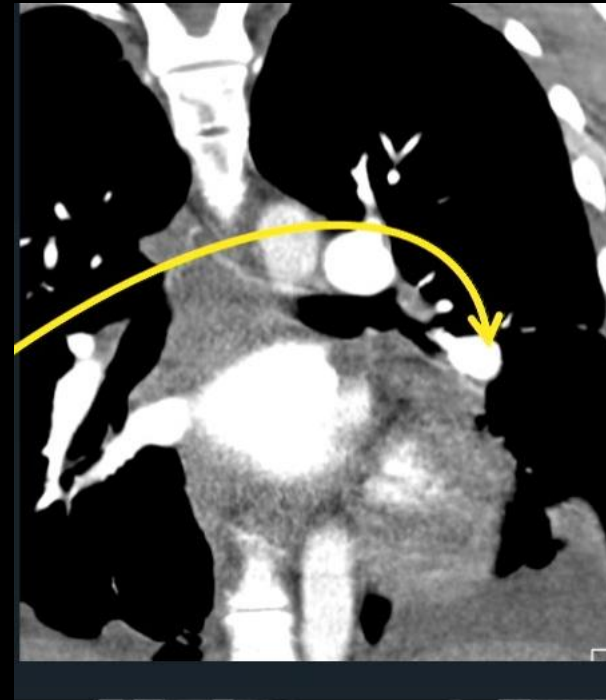
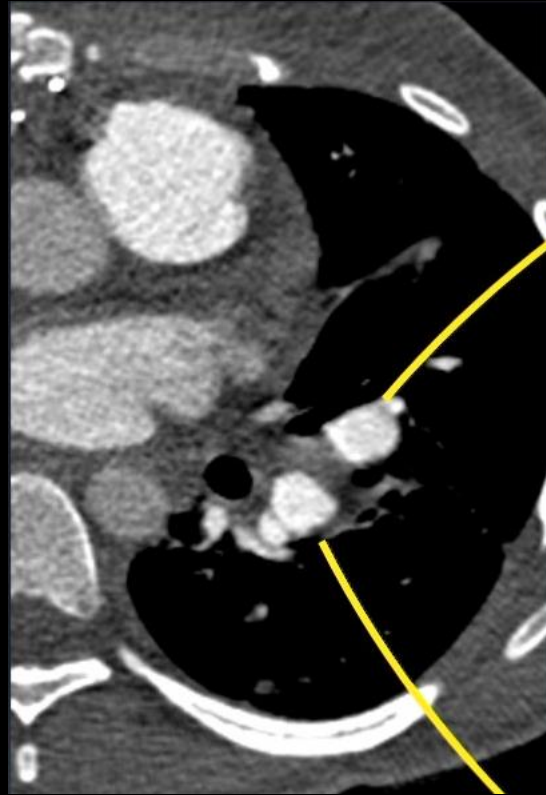
- Usually single
- Tuberculosis, Staph, Klebsiella, Angio-invasive fungi,
- Amenable to embolotherapy
- **Rasmussen aneurysm**: case: direct invades the pulmonary artery due to tuberculosis
- Case: embolization: need lots of coils to stop from bleeding!



Lung Necrosis – Pulmonary Artery Pseudoaneurysm

(2) Hematogenous spread of infection

- Often multiple – can be problematic to embolize (not amenable to embolization; examples: staph)
- Usually segmental or subsegmental arteries
- Subtle: Can be missed on initial CT read

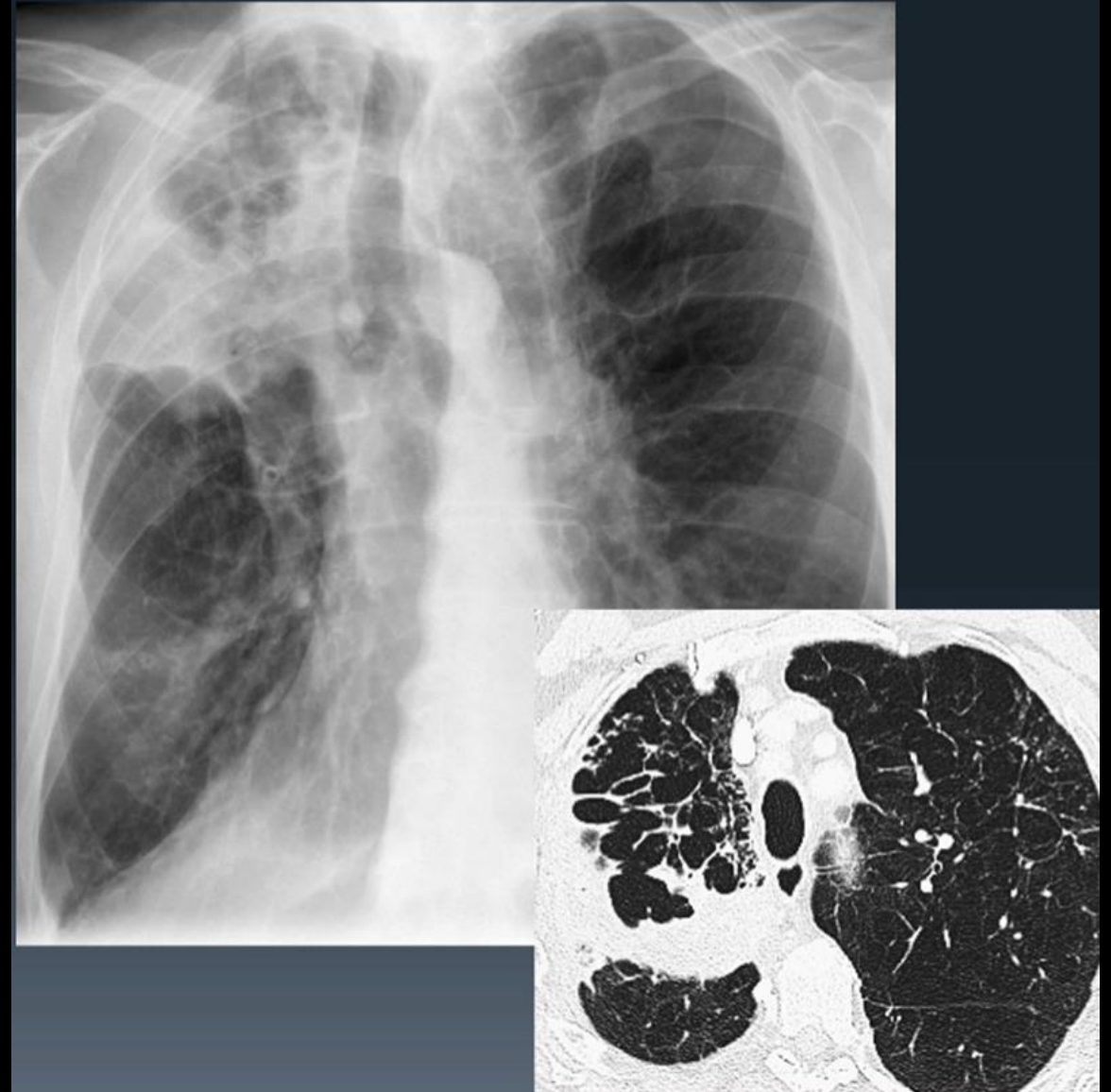

Pulmonary Infections

- (1) Detection of infection: CxR -> CT chest
- (2) Differentiation: infections? Non-infectious lung disease?
- (3) Infection: complications
- **(4) Specific pathogens:**

Case

- 57 Y/O Male
- COPD
- Increased cough for more than 3 months
- Quanti-FERON-TB GOLD: negative
- DDX:



Non-Tuberculous mycobacteria

Mycobacterium Avium Complex (MAC)

“Non-classic” Most common form

- Multiple ill-defined nodules clustered around airways
- Bronchiectasis : often greatest in middle and lingula

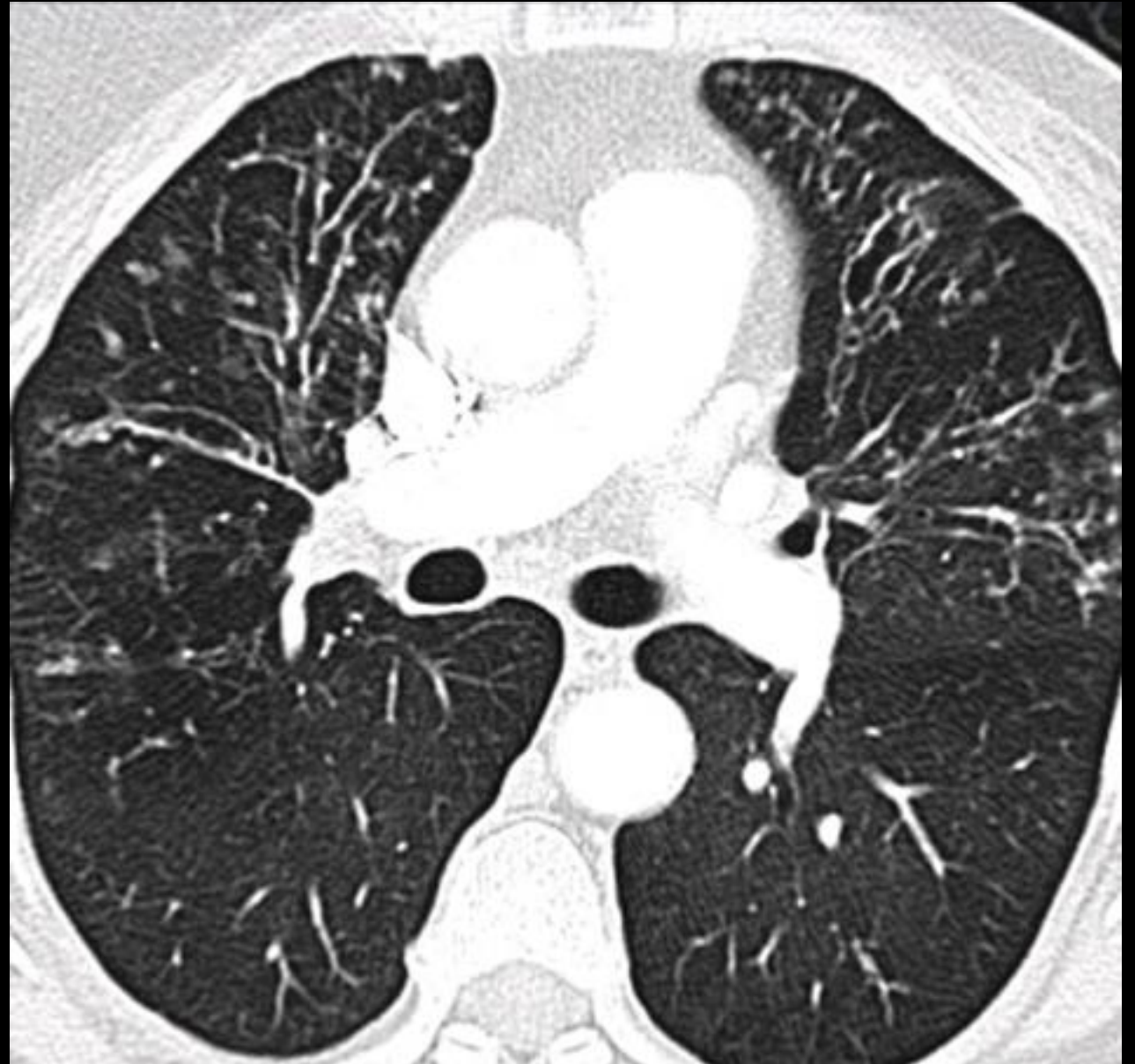“Classic” Post primary TB-like

- Thinner walled cavities > TB
- Unilateral disease > TB
- Pleural thickening adjacent to cavity > TB

NTM-MAC

“ Non-classic” Most common form

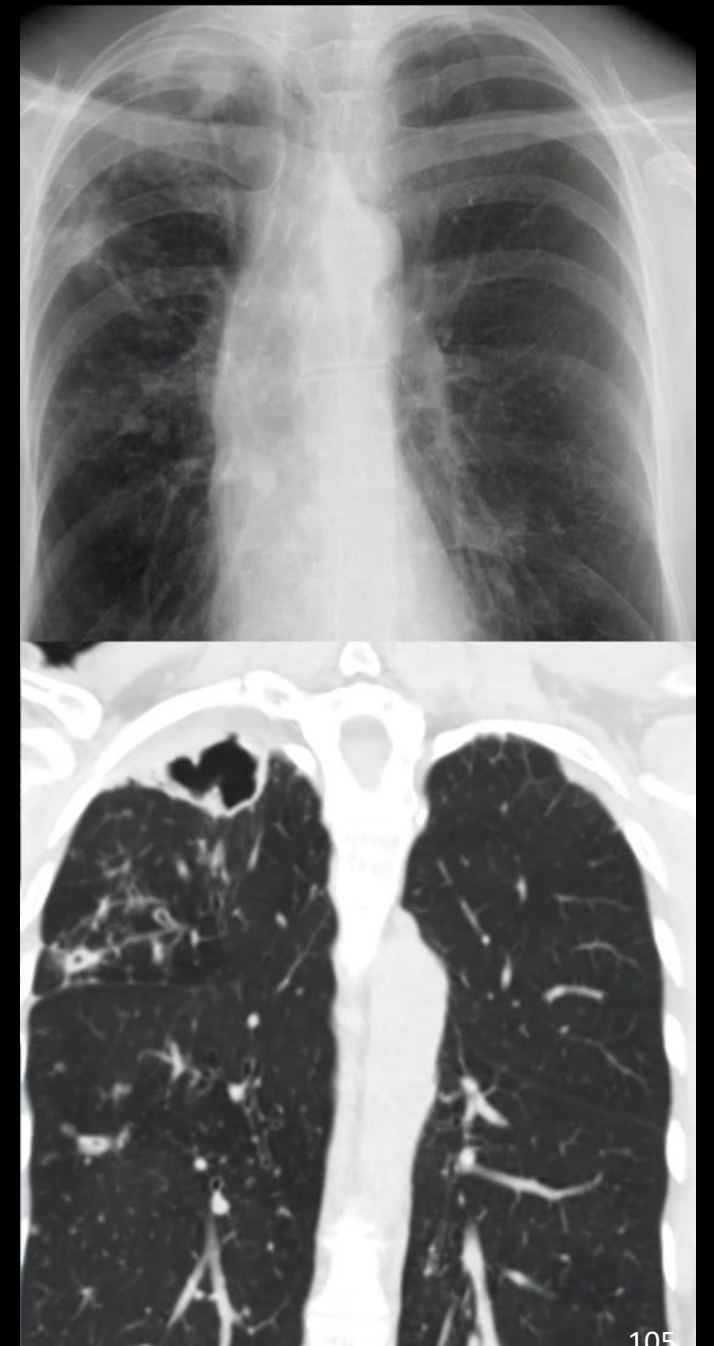- Multiple ill-defined nodules clustered around airways
- Bronchiectasis : often greatest in middle and lingula



NTM-MAC

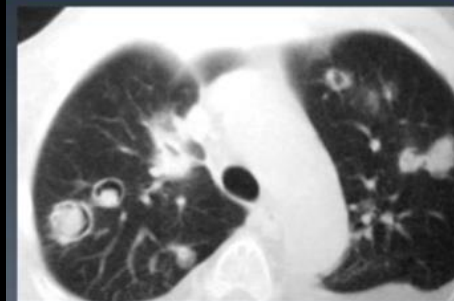
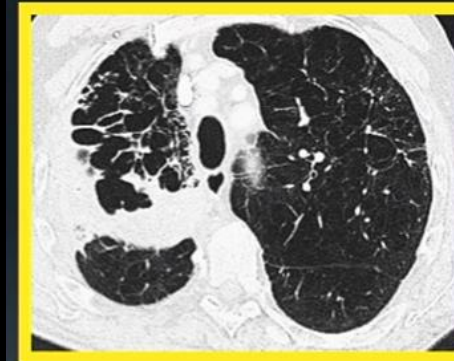
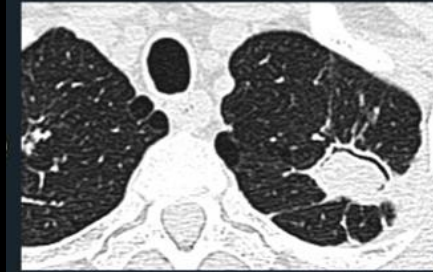
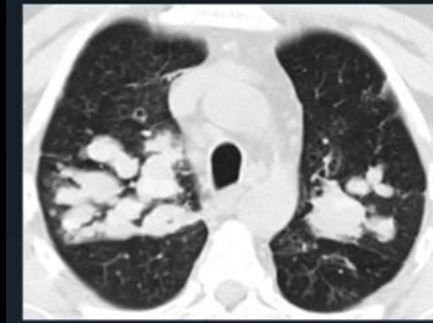“Classic” Post primary TB-like

- Thinner walled cavities > TB
- Unilateral disease > TB
- Pleural thickening adjacent to cavity > TB



Aspergillus infections: immune status

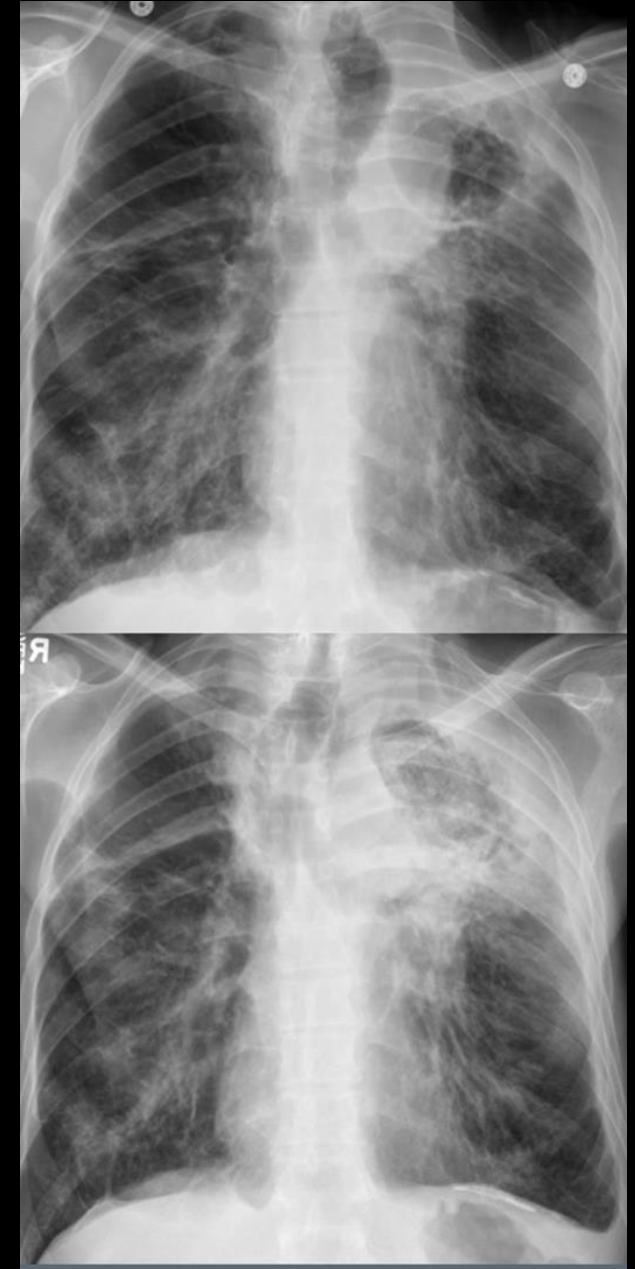
- ABPA: Asthma
- Aspergilloma: forms in existing cavity lung disease
- **Chronic pulmonary aspergillosis**: DM, underlying lung disease (prior TB, COPD)
- **Invasive**: neutropenia, immuno-suppressives



Immune status

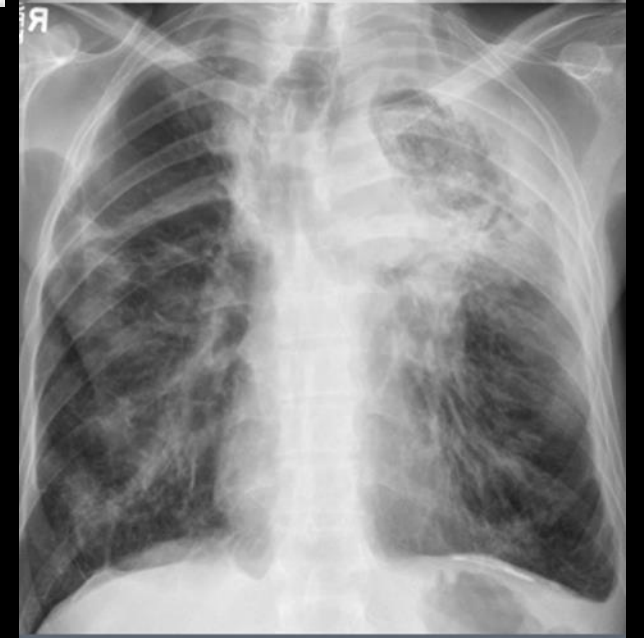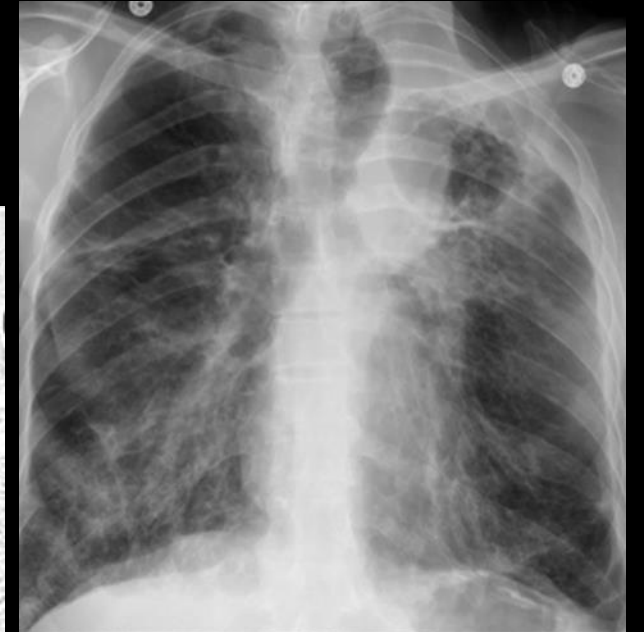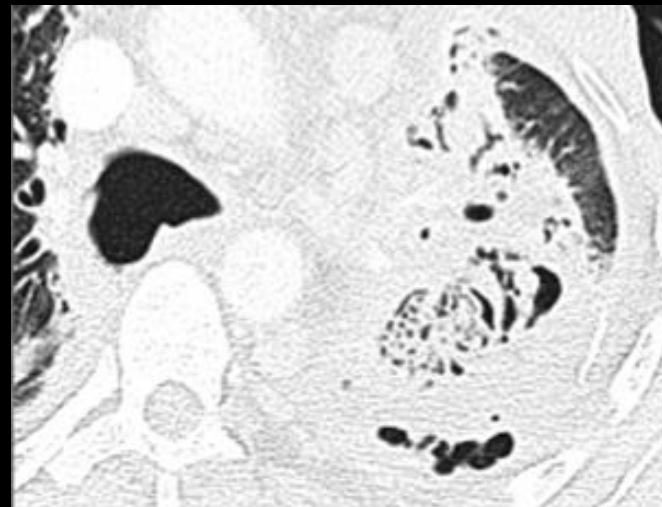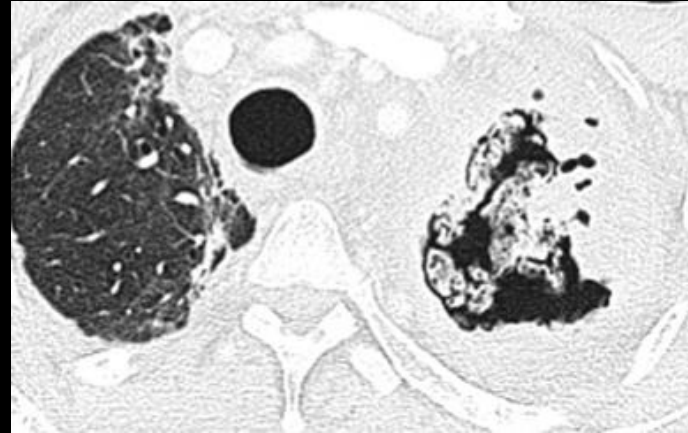
Chronic pulmonary aspergillosis

- Subcategories not well differentiated by imaging
 - = Subacute invasive aspergillosis
 - = Chronic cavitory aspergillosis
 - = Fibrosing aspergillosis
- Associated diseases
 - = Worldwide: affects 20% of patients with **cavitary TB**
 - = Where TB is rare **COPD** is major risk factor
 - = Middle aged/elderly patients
 - = Cough, fever, weight loss over months



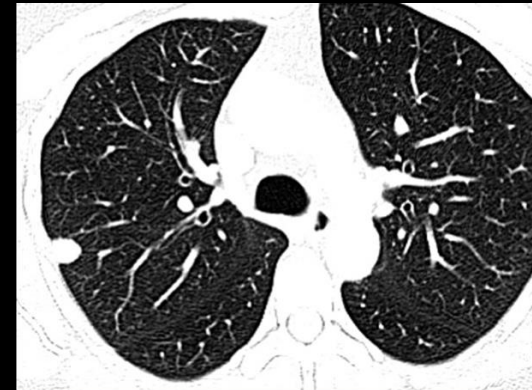Chronic pulmonary aspergillosis: Imaging

- Upper lobe disease initially
- Chronic consolidation, cavity formation and pleural thickening
- Untreated may progress to bilateral lung fibrosis

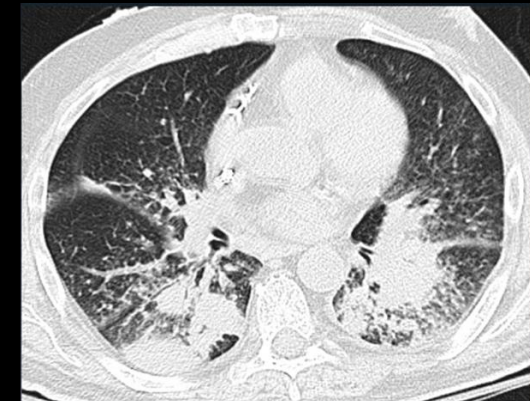


Cryptococcus

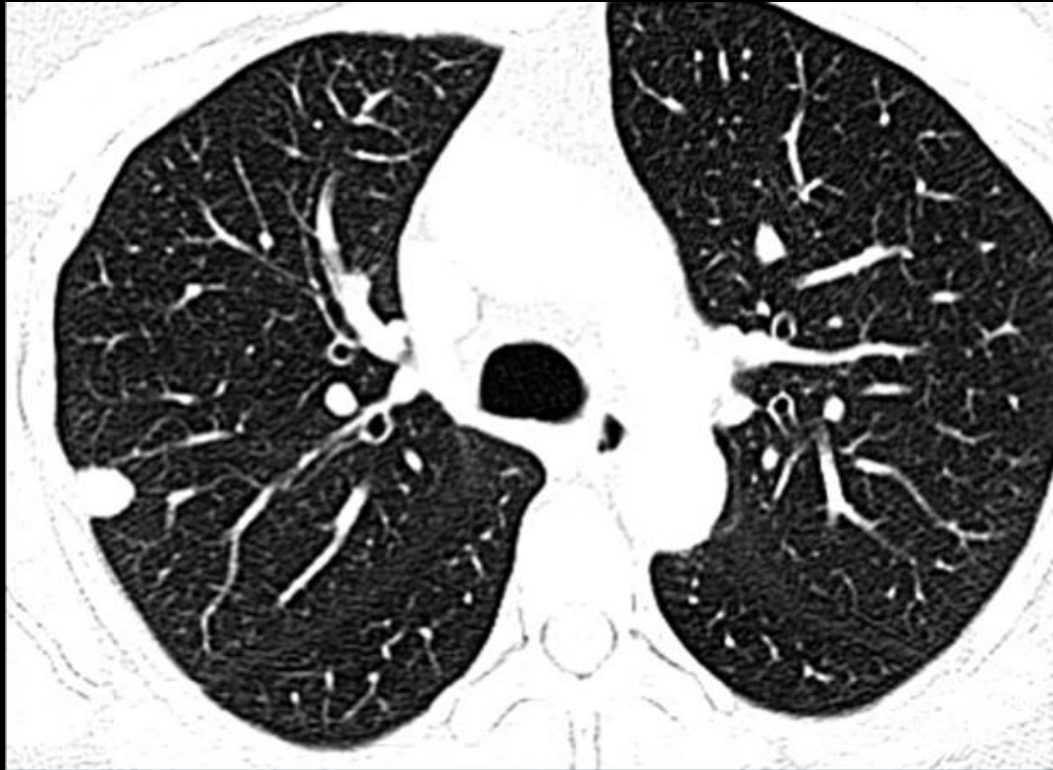
- Cryptococcus Neoformans
 - ***One or more macronodules: immuno-competent***
 - No upper lobe predilection
 - Consolidation and cavitation (within nodules or consolidation) more common in immunocompromised hosts
-
- Cryptococcus Gattii
 - Nodules/Masses
 - Consolidation



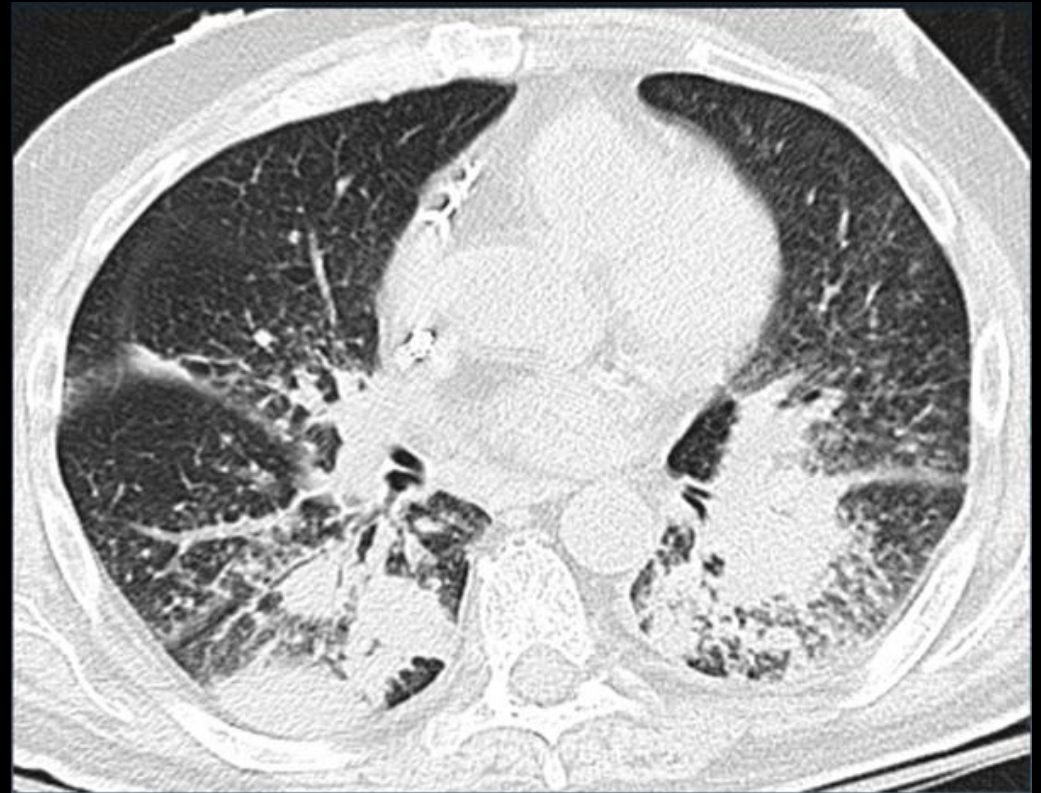Immunocompetent



Immunocompromised



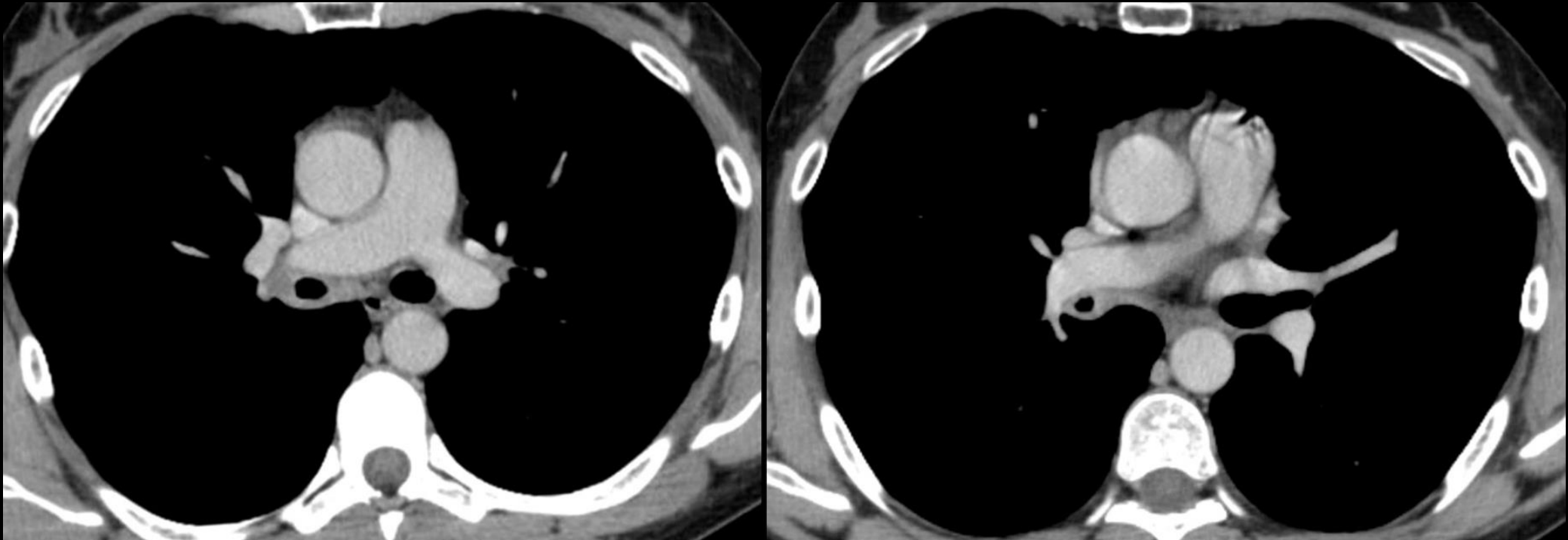
Immunocompetent



Immunocompromised

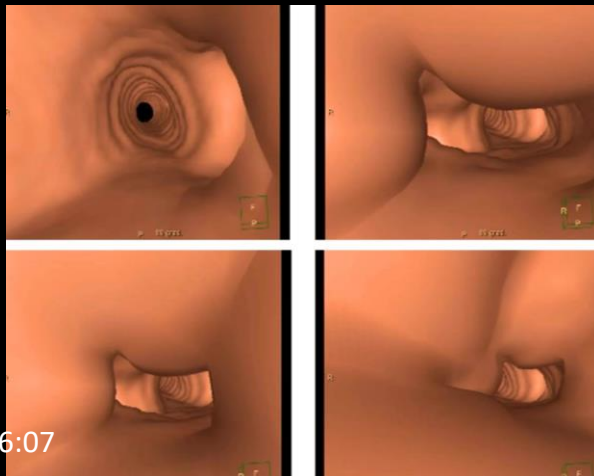
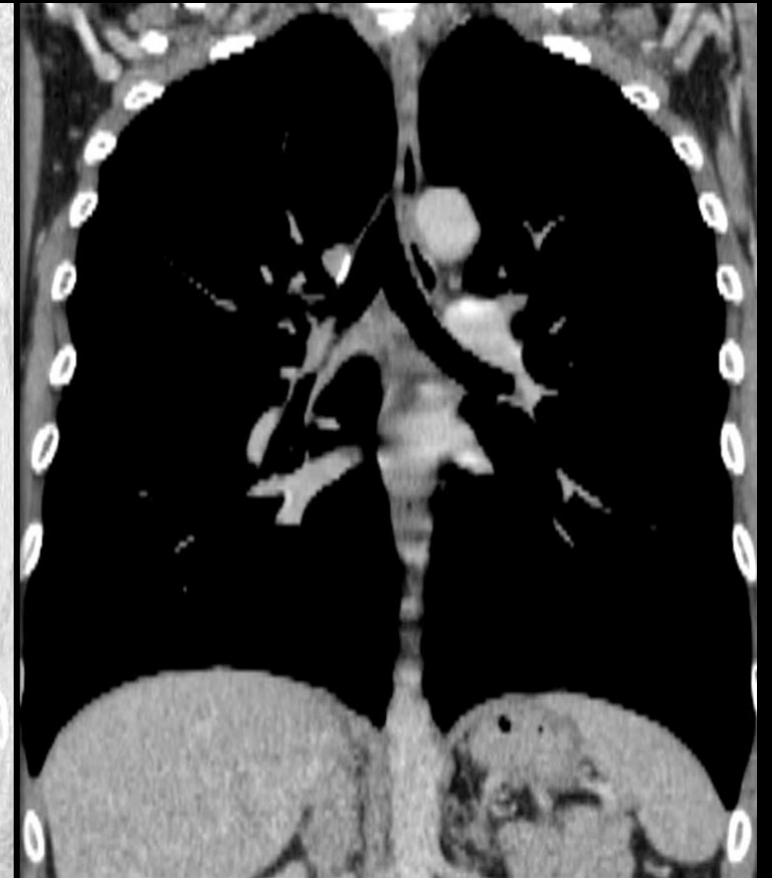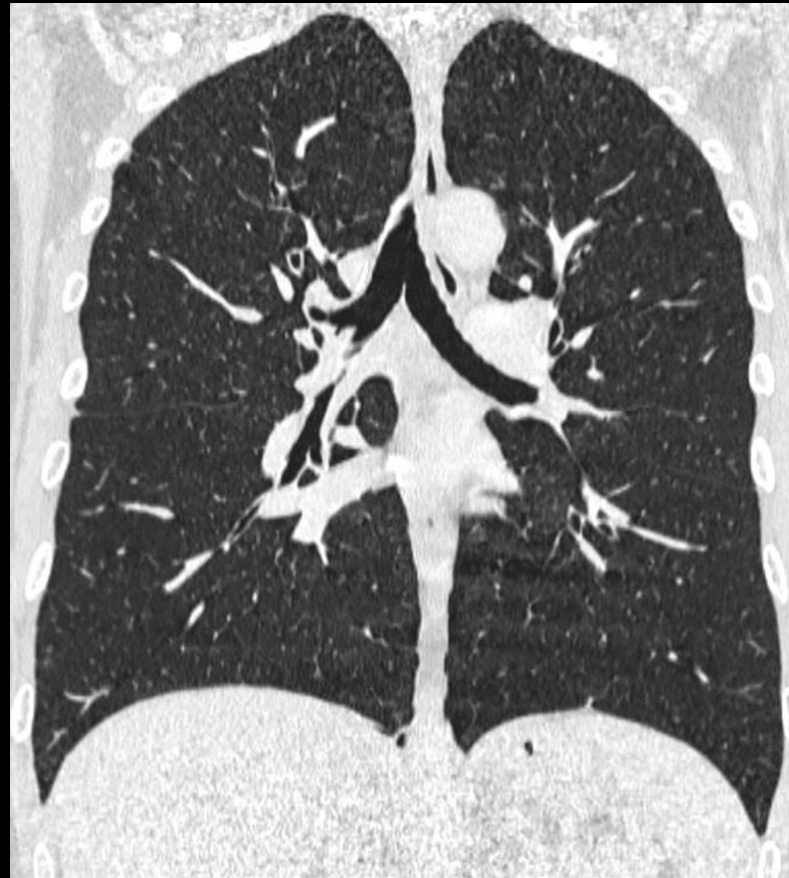
Case

- 47 Y/O; female; Wheezing; Former smoker: 10 pack-year
- Normal laryngoscopy



Lung window and mediastinal window

- The narrowing of the lumen of the bronchus intermediates
- A surrounded soft tissue mass
- Virtual bronchoscopy

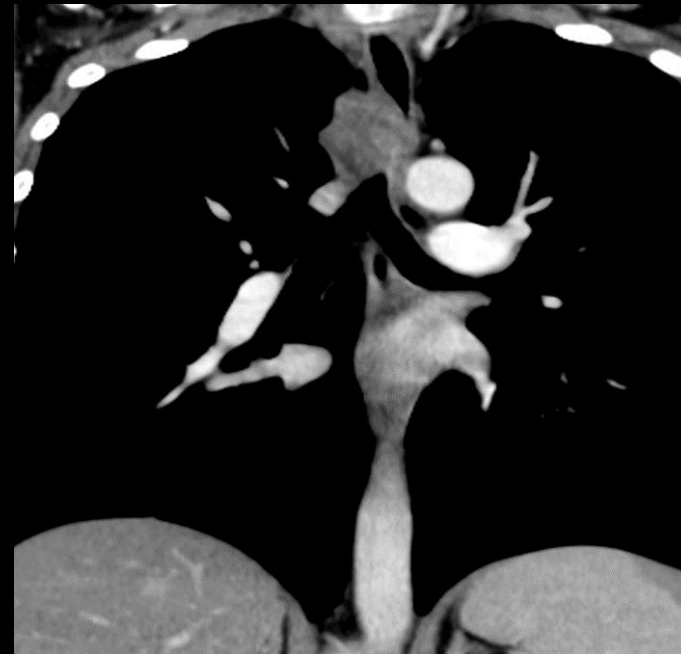
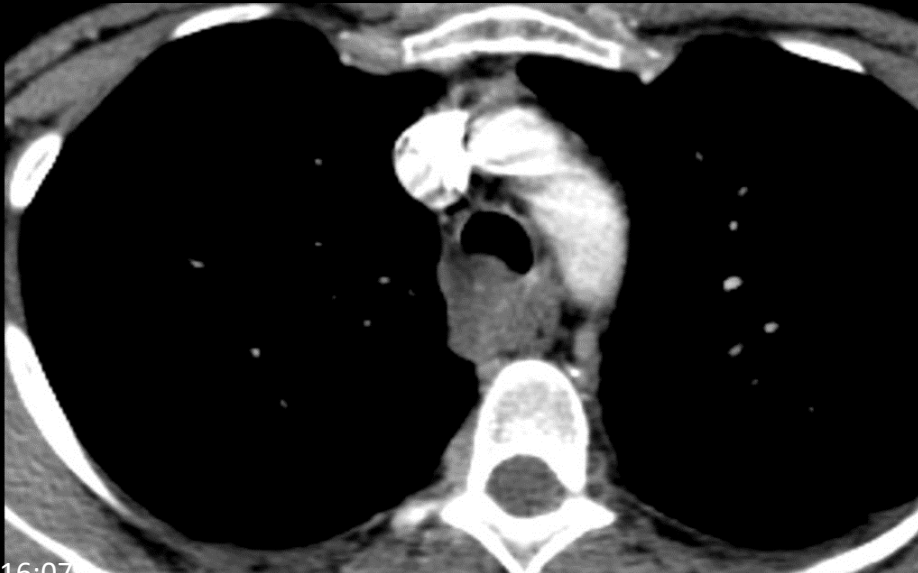
Case: Adenoid cystic carcinoma

- Usually arise from distal trachea or proximal main bronchi
- Most: Polypoid intraluminal mass or Invade adjacent structures
- Scant: Rarely multifocal or diffuse

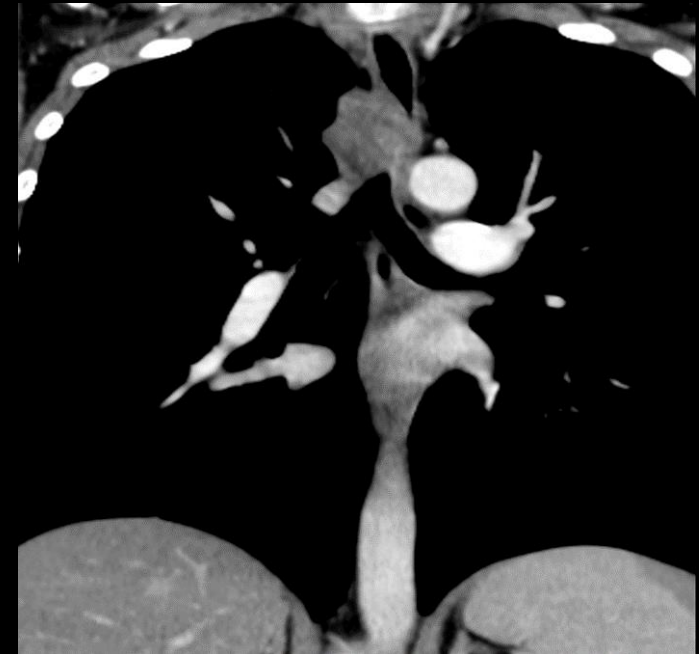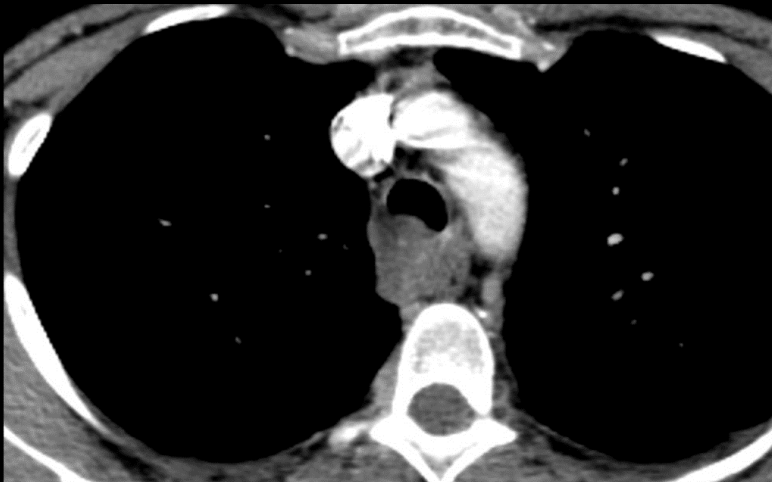Case: Dx?

- 39 Y/O female
- Progressive shortness of breath
- **Wheezing? Localized? Asthma? True or not true?**
Pulmonary function test?



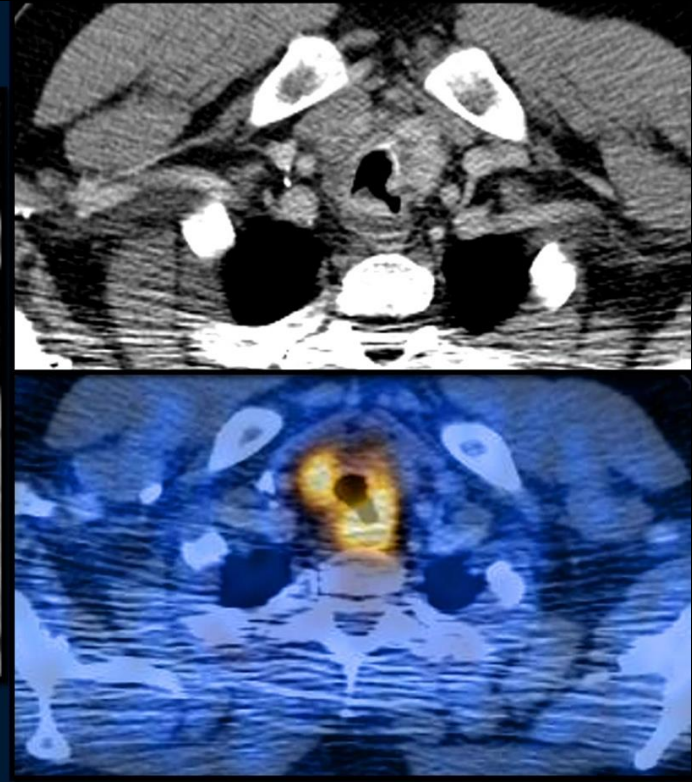
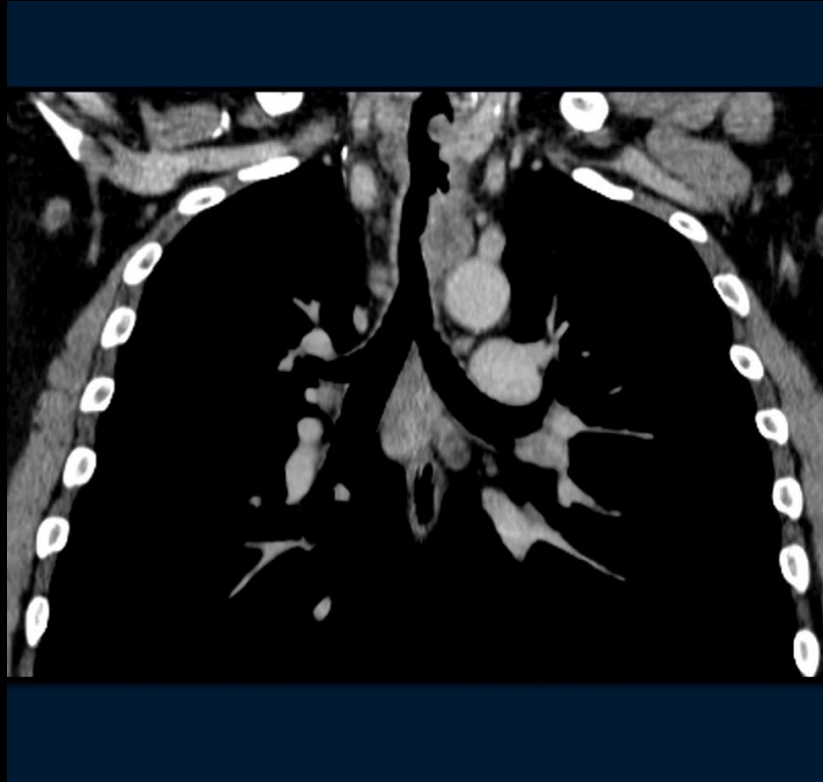
Case: Dx: Adenoic cystic carcinoma

- Coronal and Axial view
- A mass invade the adjacent structures and protrude into the lumen of a trachea
- Invade the adjacent esophagus
- Image: not for pathologic diagnosis!



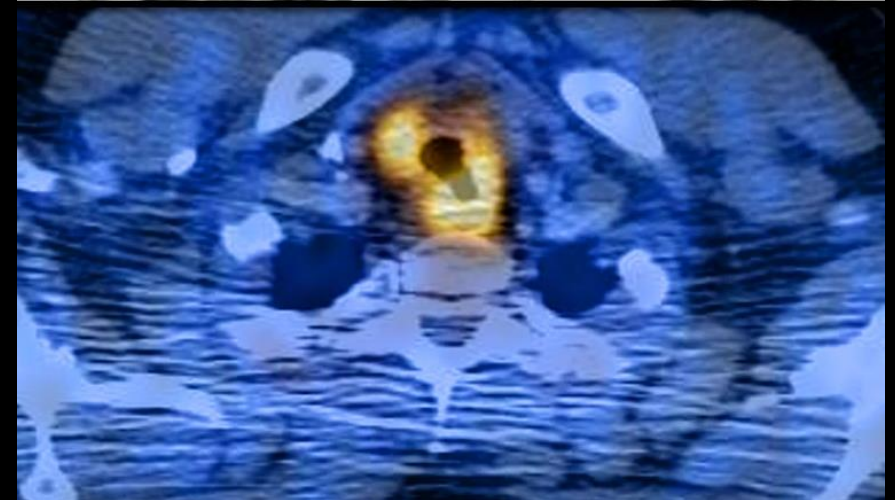
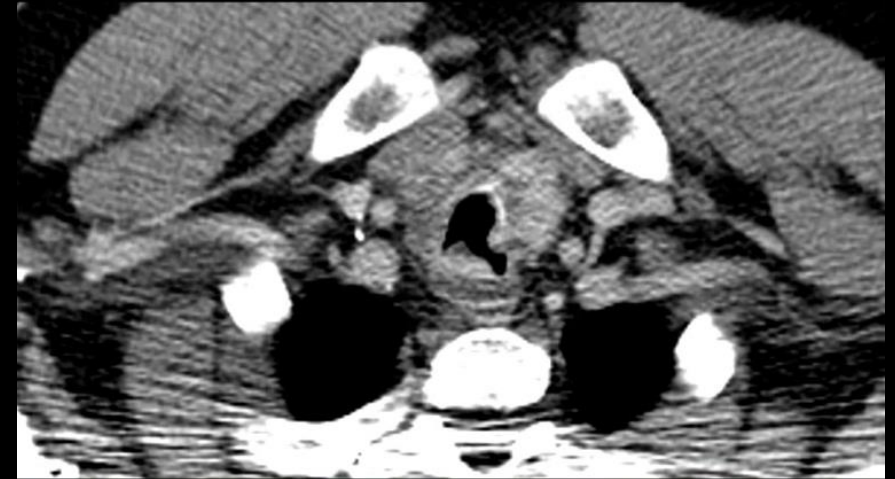
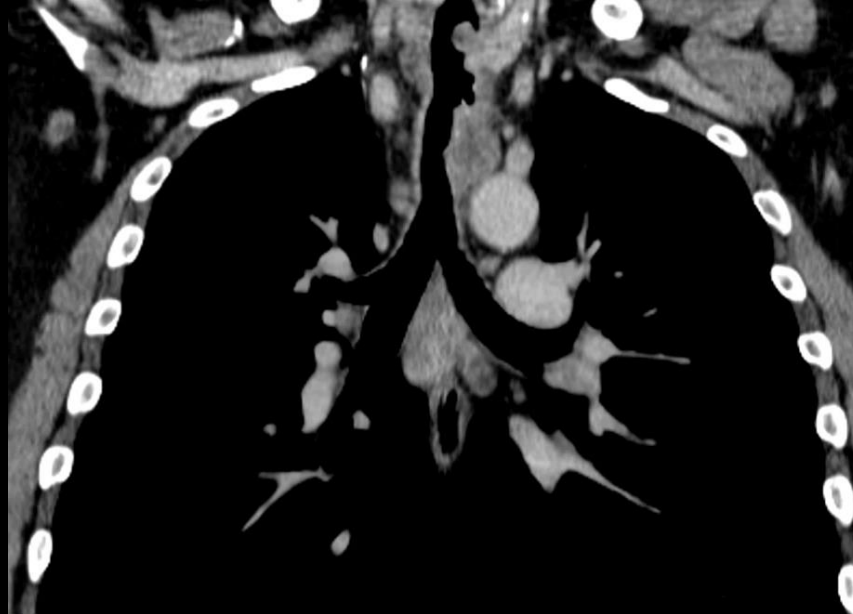Case

- 54 Y/O Male
- Shortness of breath



Case: Dx: Squamous cell carcinoma

- Irregular thickening of the tracheal wall, **heterogeneous with some areas of necrosis**: extension into the lumen;
- PET scan: avid FDG uptake in the whole mass



(2) Large airways diseases

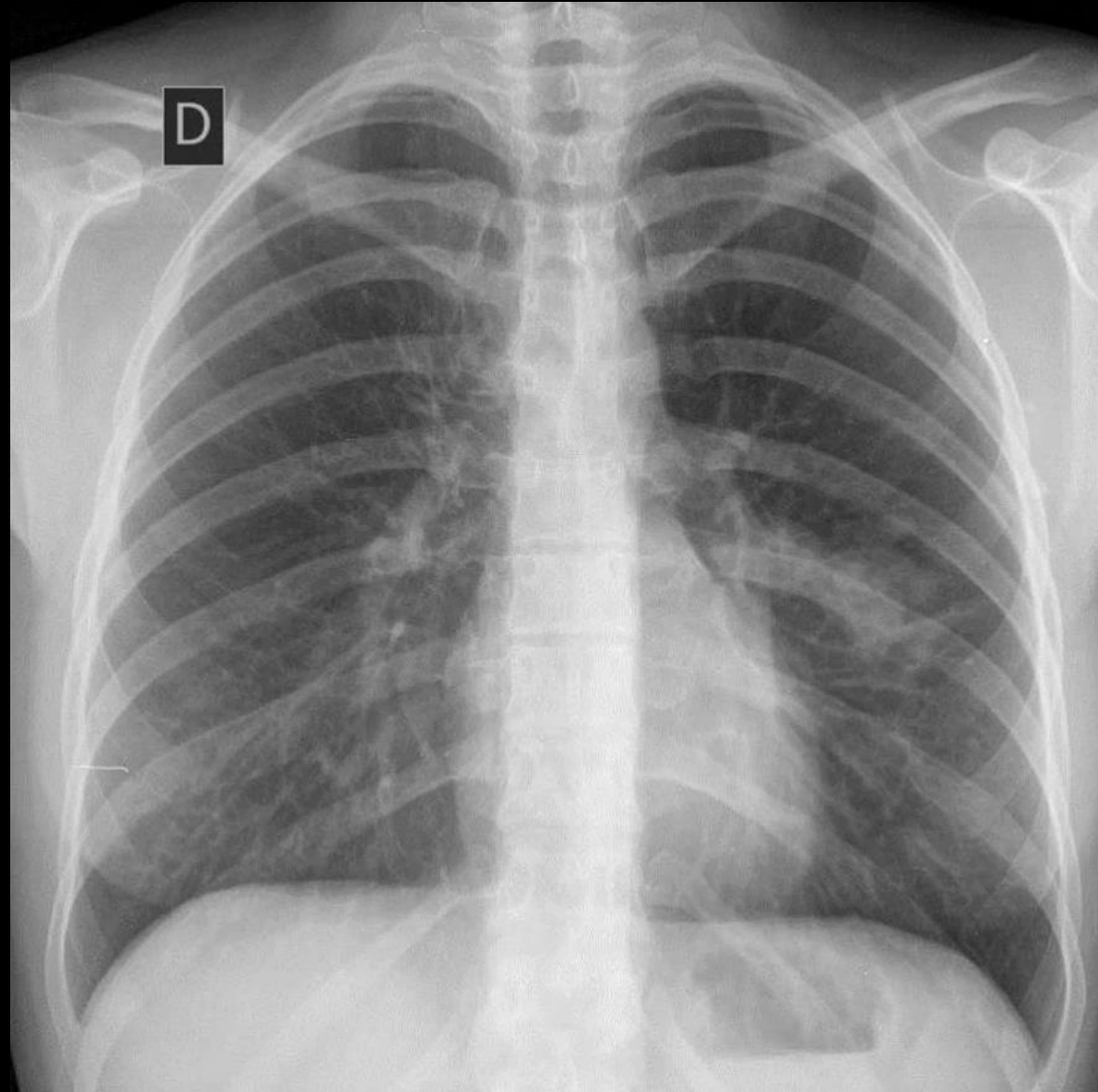
- CT: focal and diffuse tracheobronchial disease
- Bronchiectasis
- Differential diagnosis: clinical and imaging clues

Case: Squamous cell carcinoma

- **Male; usually smokers > 50 Y/O**
- Poor prognosis
- **Intraluminal polypoid mass (most common)**
- **Eccentric nodular wall thickening**
- Frequently extends into mediastinum and adjacent structures
- Rarely diffusely infiltrate tracheal wall

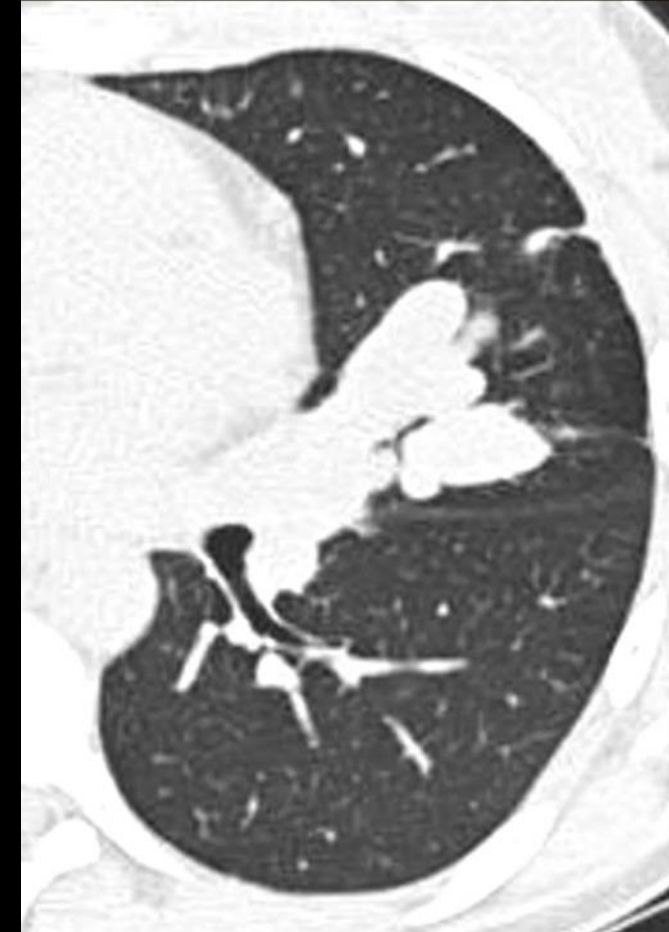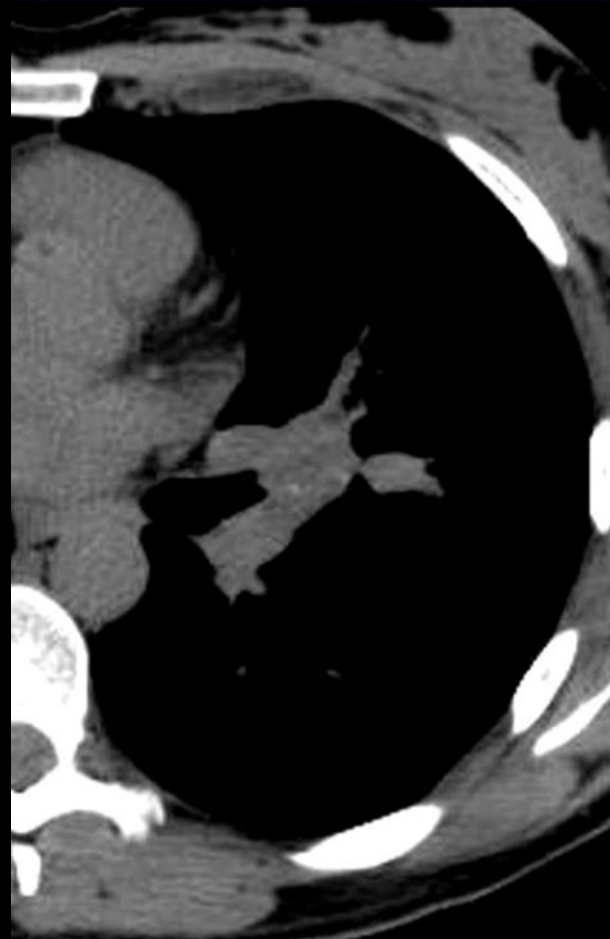
Case

- 42 Y/O: Male: s/s: cough and shortness of breath
- CxR: tubular opacity in the mid left lung



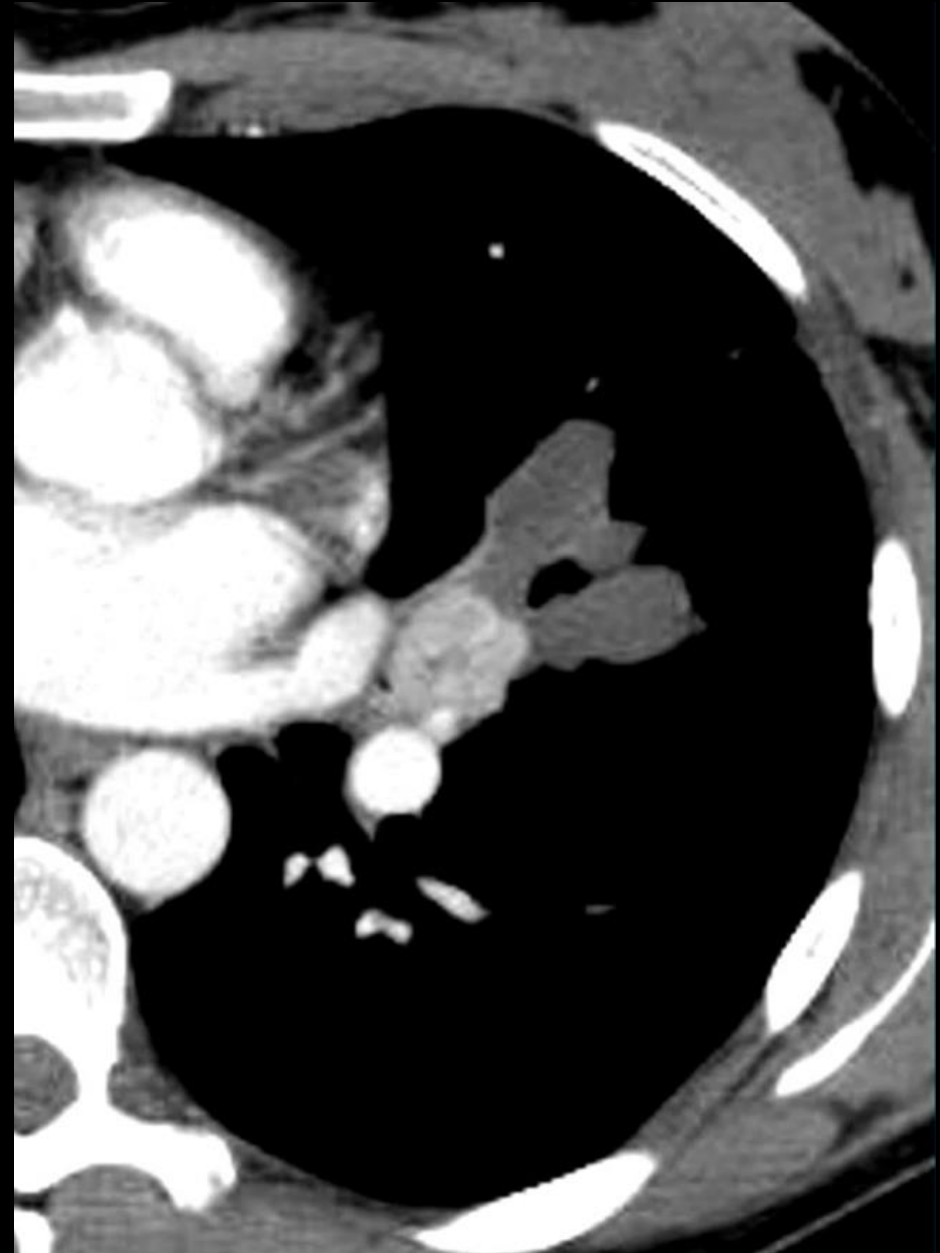
Case

- 42 Y/O: Male: s/s: cough and shortness of breath
- CxR: tubular opacity in the mid left lung
- CT chest: Without contrast: nodular lesions within the bronchus; tubular lesions in the lung window, **fingering**;



CT chest with contrast

- **IV contrast: important!**
- Tubular opacities
- Enhancing nodule lesion
- CT chest: With Contrast -> **tubular opacities, enhancing nodule lesion;**
- Bronchiectasis and secretion of mucus within bronchi;

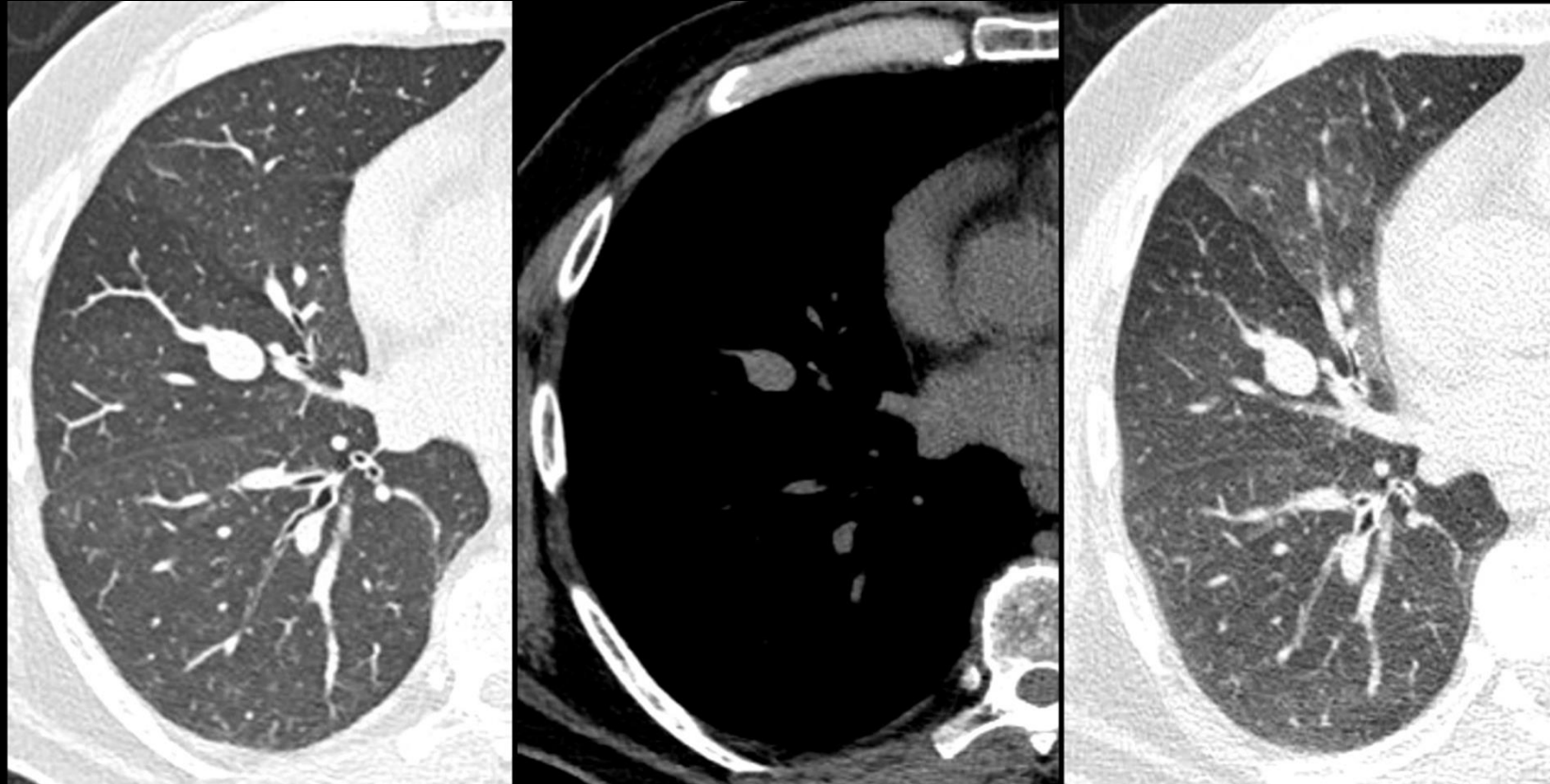


Case: Diagnosis: Carcinoid

- Hilar or discrete endobronchial mass
- Orient along long axis of airways
- **Smooth or slightly lobulated margins**
- Typically enhance following contrast administration

Case:

- 51 Y/O male (Young)
- Smoker: 30 pack-years
- A nodule, middle lung;
- **Margin: smooth!**
- **Some air-trapping distal to the nodule lesion => lesion within the bronchi!**



Large airways diseases

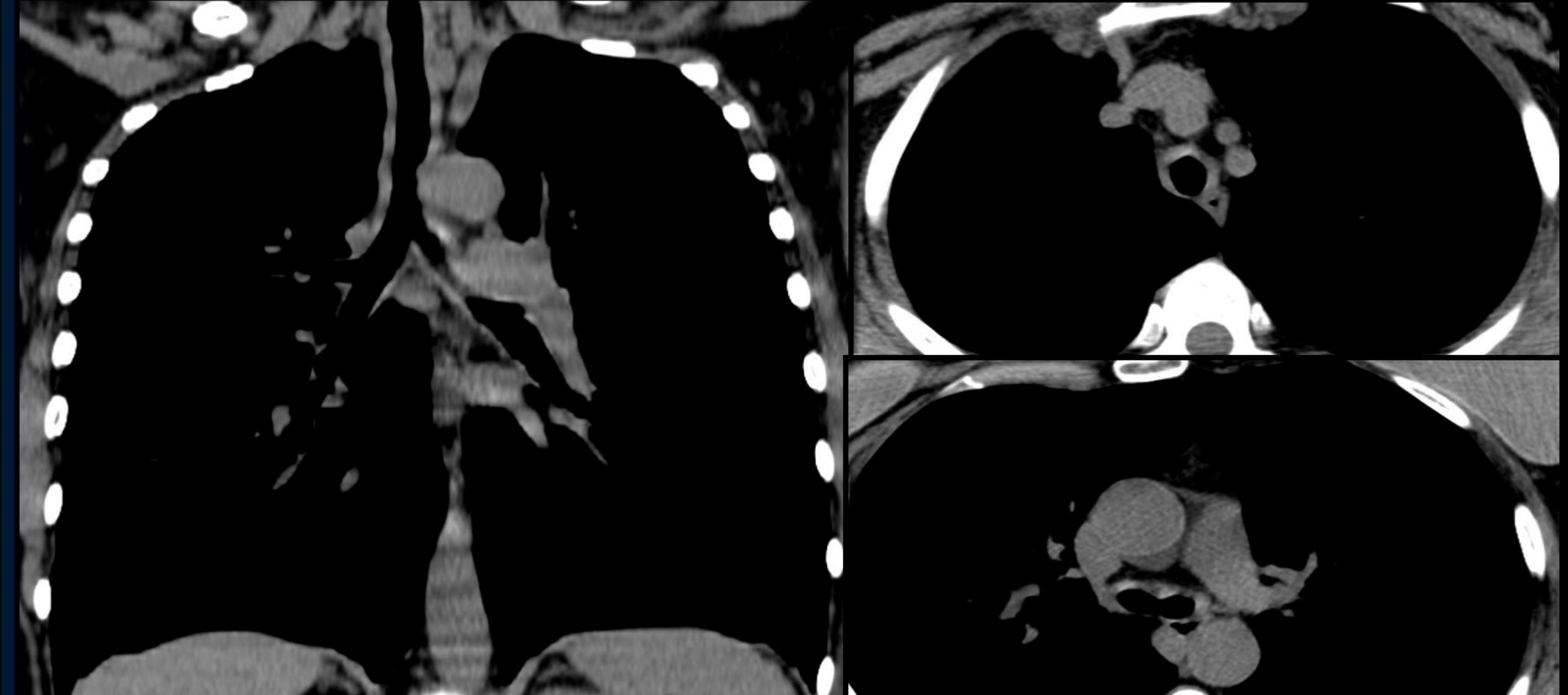
- Neoplastic



Large airways diseases: (1) neoplastic

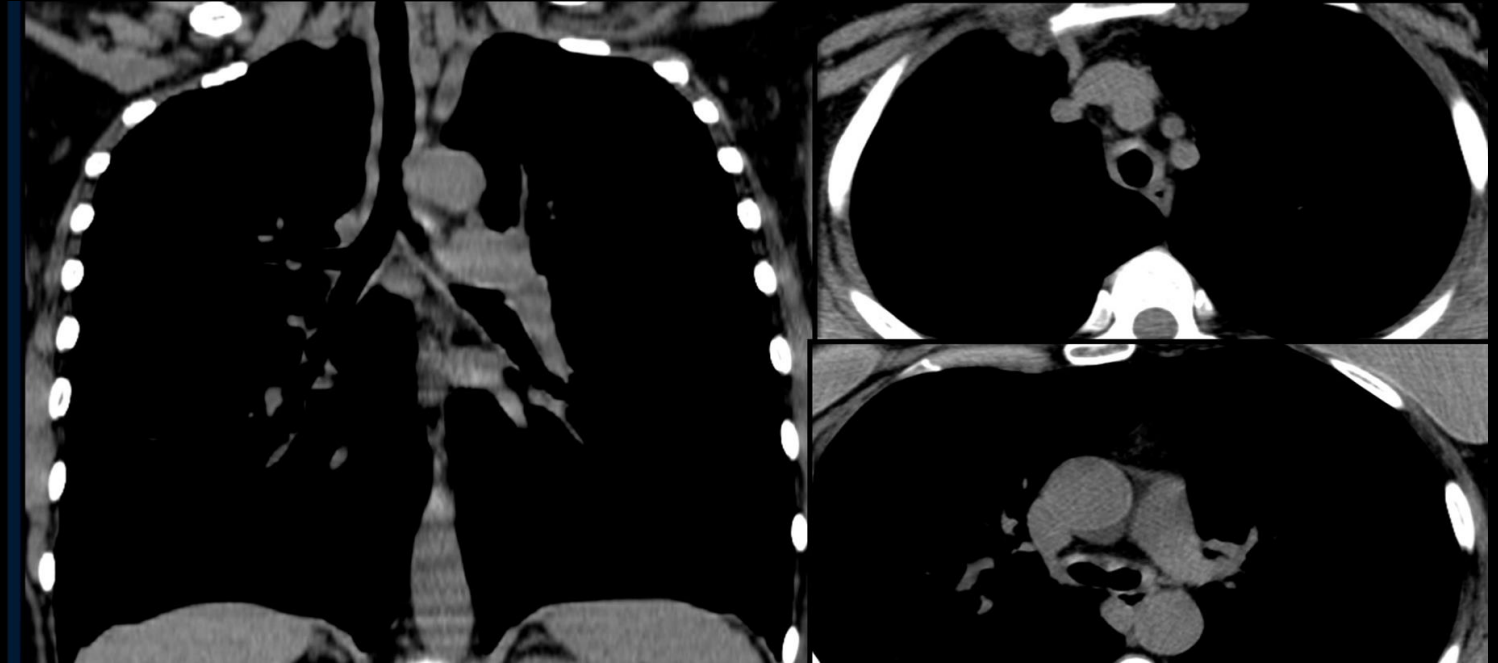
- **Goal: Location!** (Not to guess the histology)
- Primary tracheal neoplasm: < 1% of all bronchial neoplasms
- **Squamous cell carcinoma and adenoid cystic carcinoma:** > 80%

Case

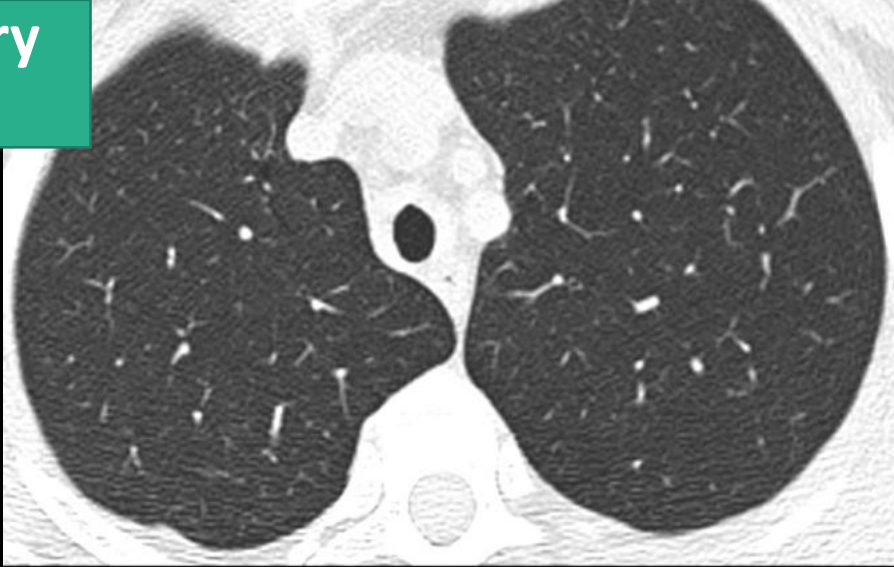

Case:

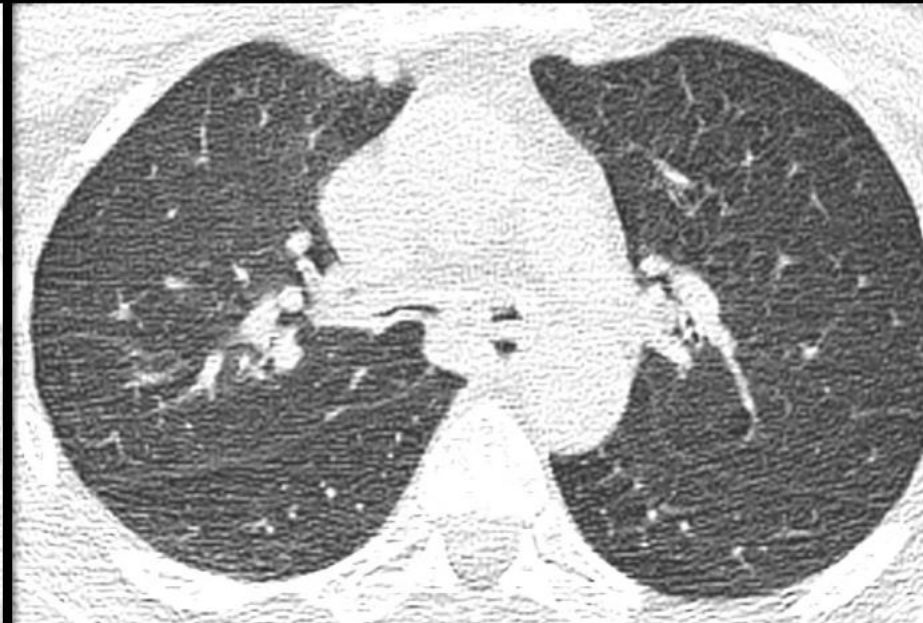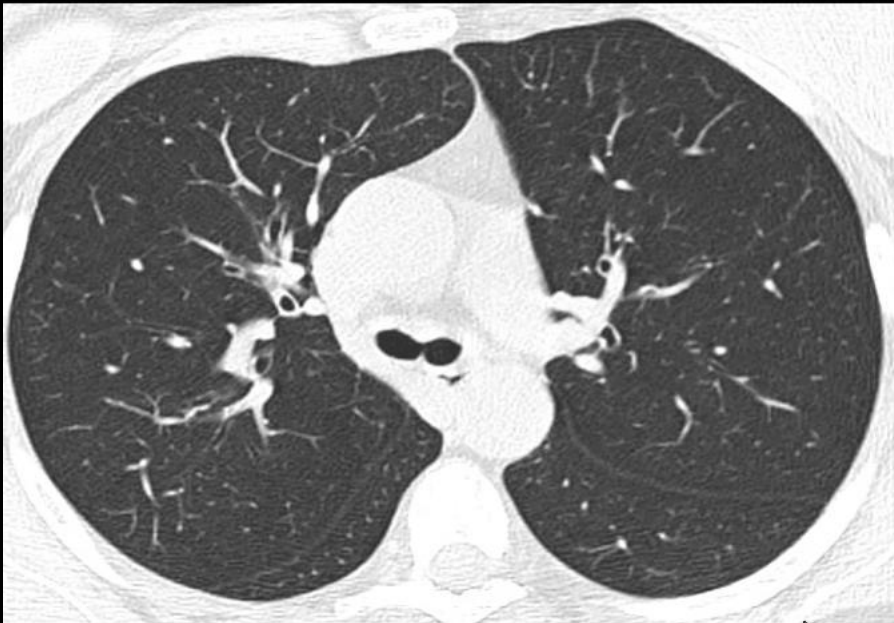
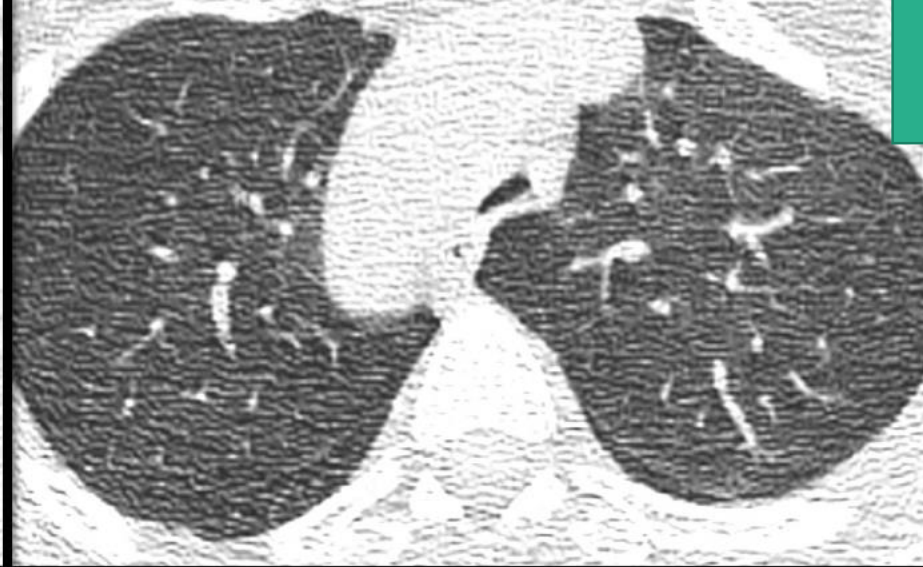
- 54 Y/O; female
- s/s: Wheezing and auricular pain
- CT chest: Some thickening of the trachea, smooth and regular;
- Mainly in their anterolateral portions of the trachea



**Inspiratory
CT**



**Expiratory
CT**

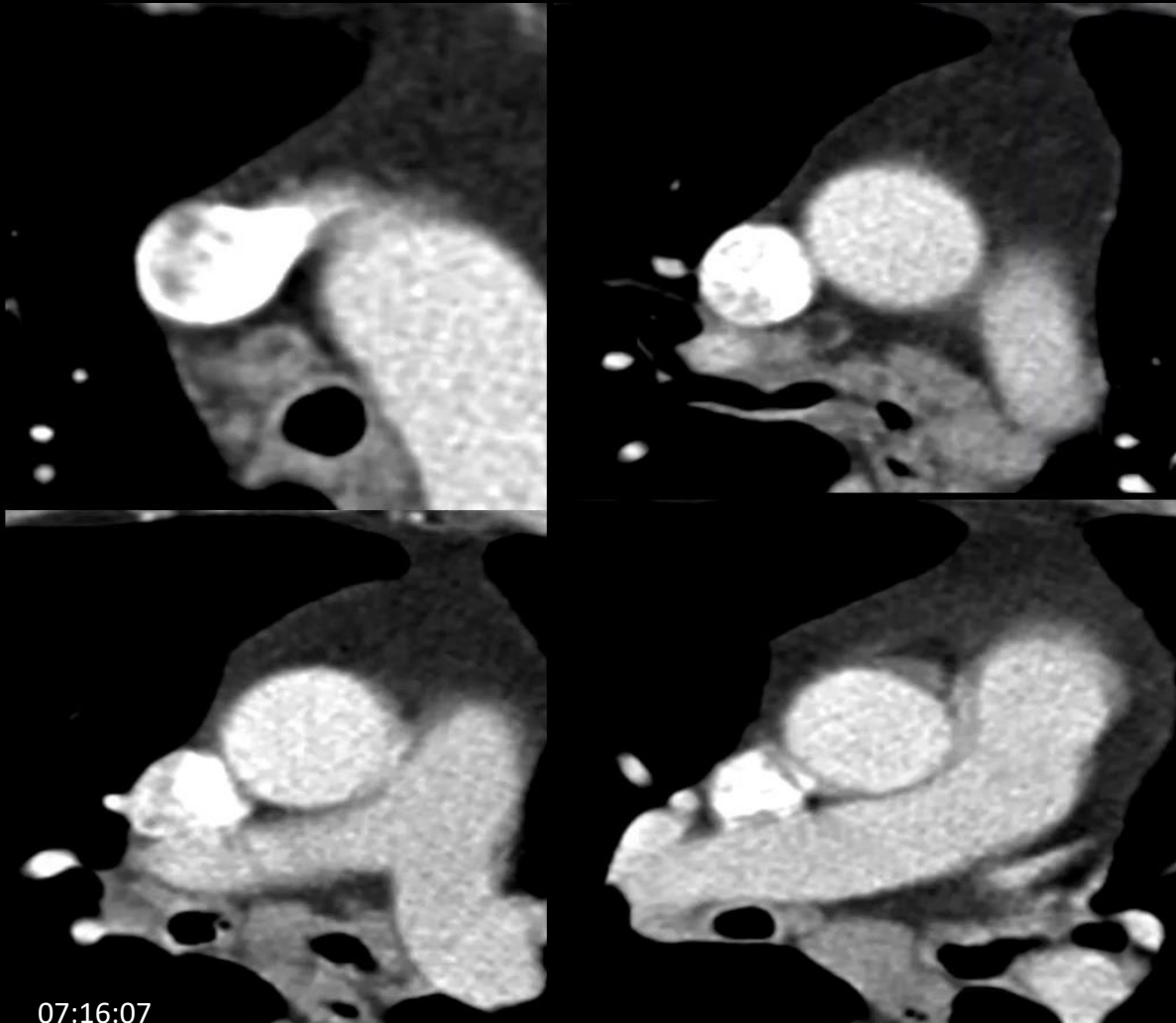


Inspiratory and Dynamic Expiratory CT: collapse and air trapping

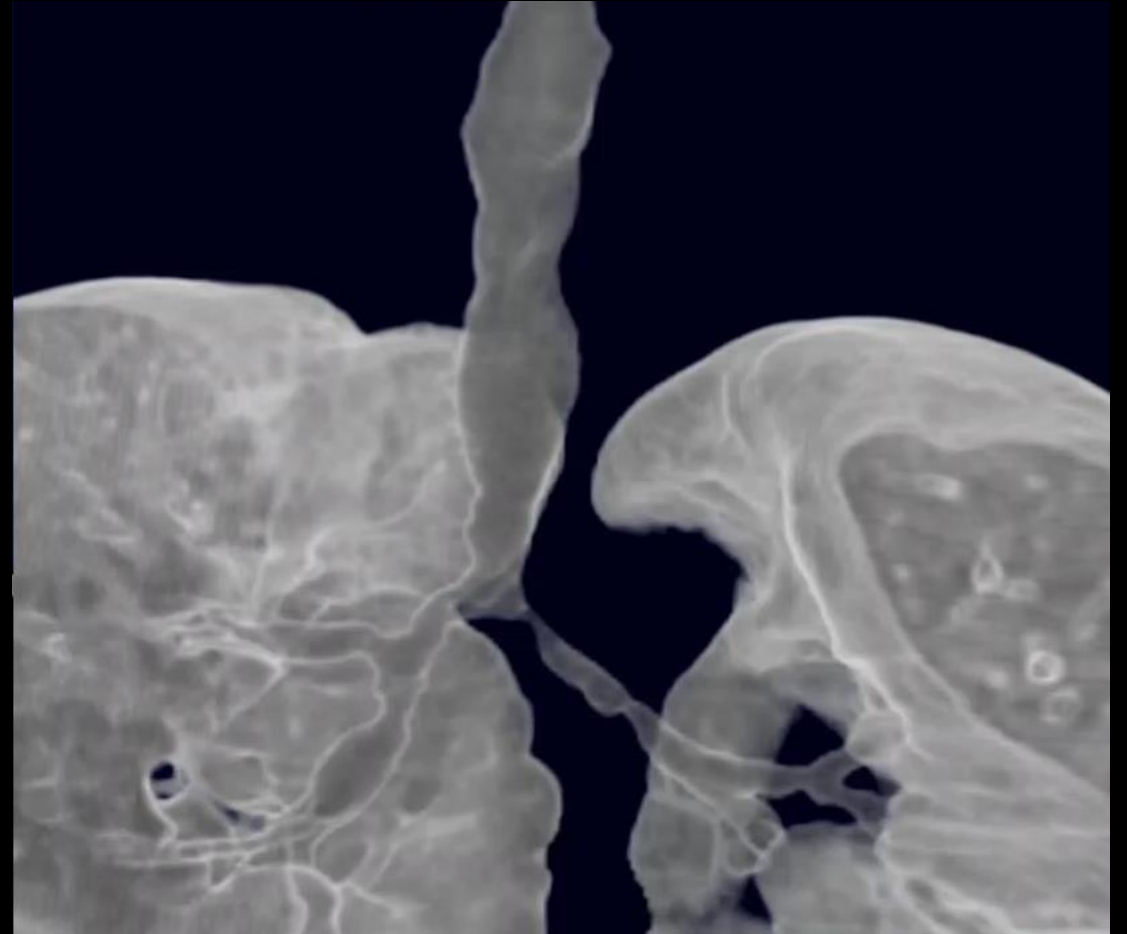Case: Relapsing polychondritis

- Clinical information: **Recurrent episodes of cartilage inflammation** (ear, nose, joints, larynx and tracheobronchial tree)
- CT shows **smooth tracheal and bronchial wall thickening**, with or without calcification)
- Characteristic **sparing of posterior tracheal membrane**
- Diffuse tracheal narrowing (a late finding)

Case



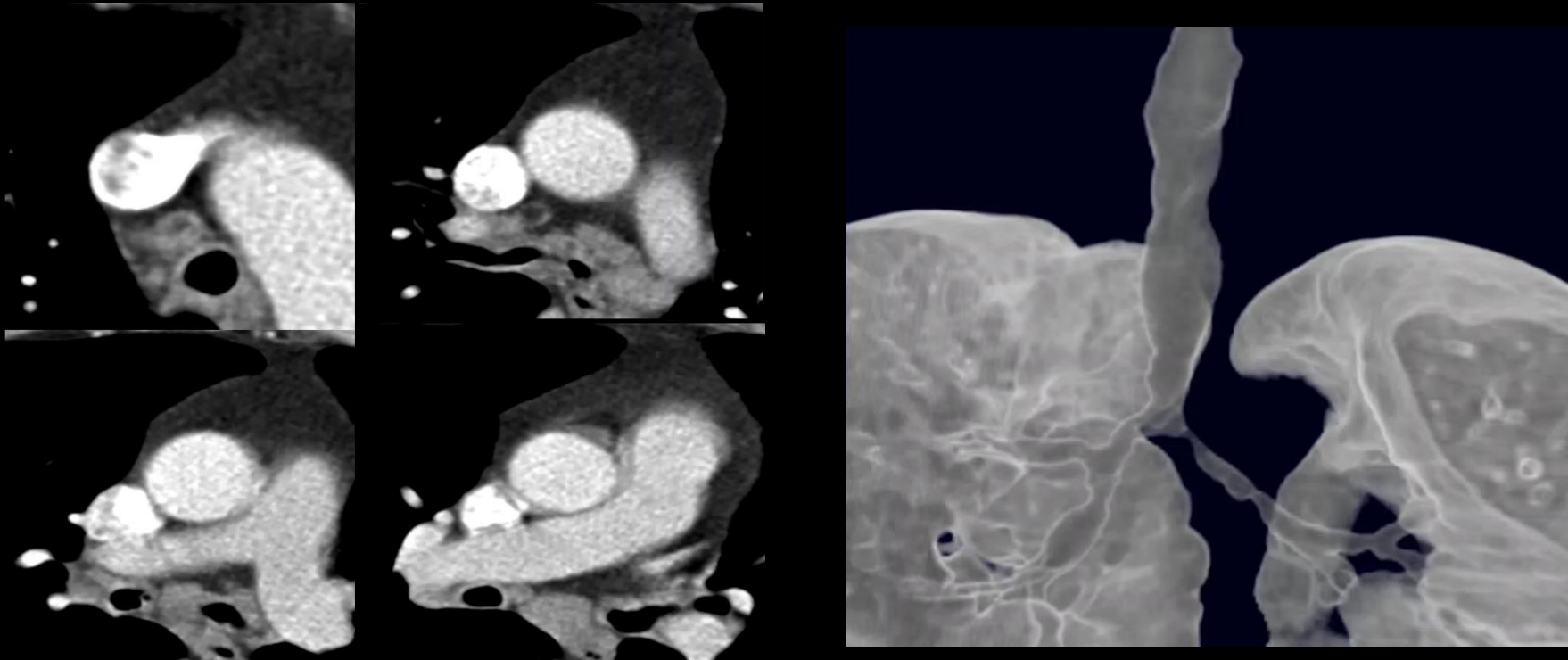
07:16:07



131

Case: Granulomatosis with polyangiitis

- Case: circumferential thickening of trachea and main bronchi
- Stenosis on the left main bronchi;



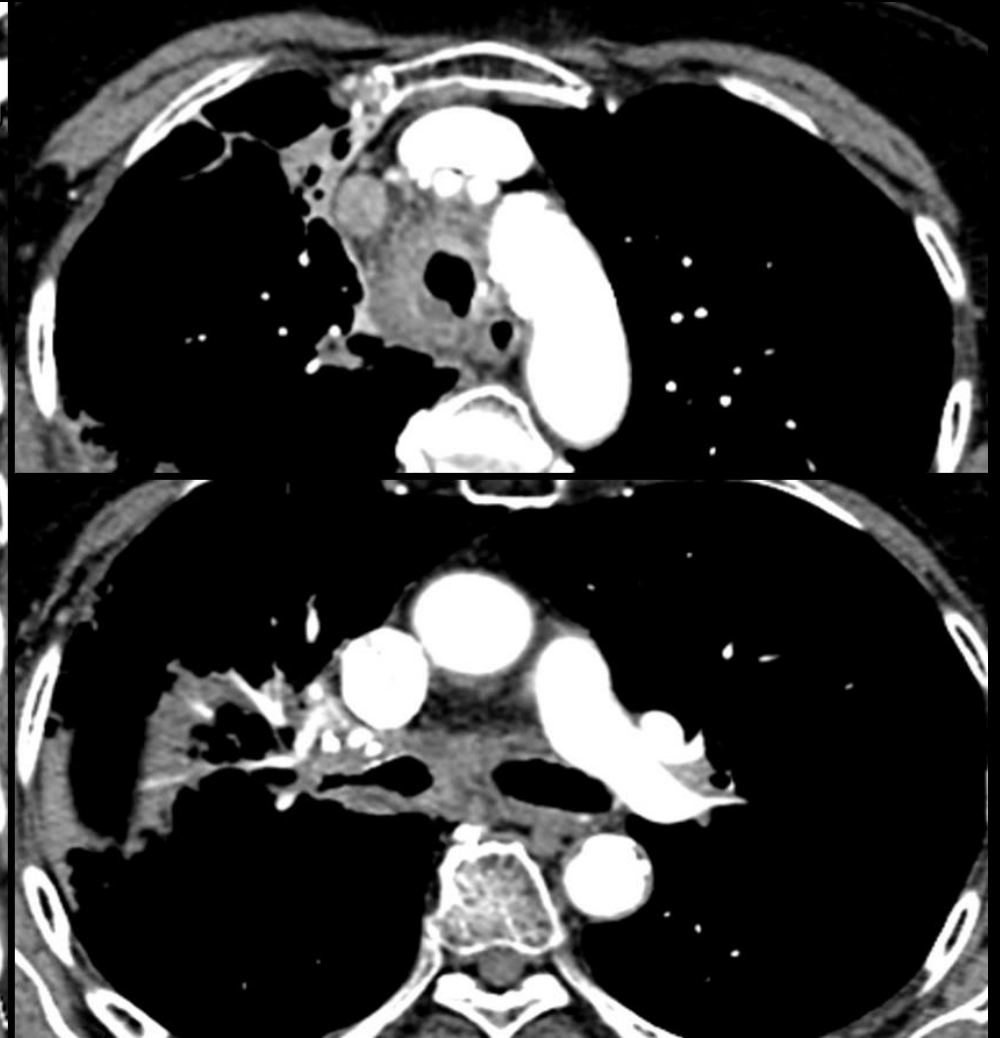
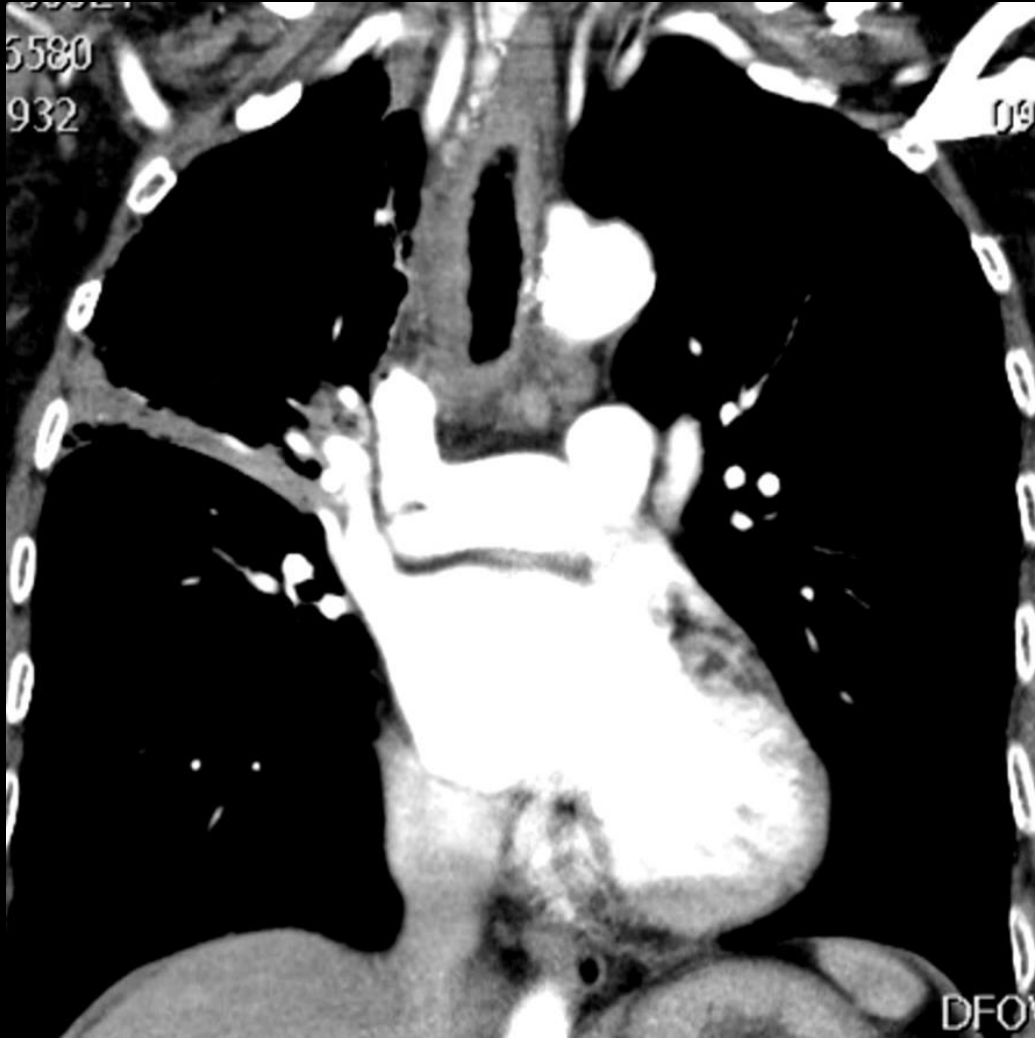
Case: Granulomatosis with polyangiitis

- Large airway involvement just over half of patients
- Circumferential wall thickening
- Tracheal or bronchial stenosis (especially **subglottic trachea**)
- **Tracheobronchomalacia**

Large airways diseases: (2) noninfectious inflammatory

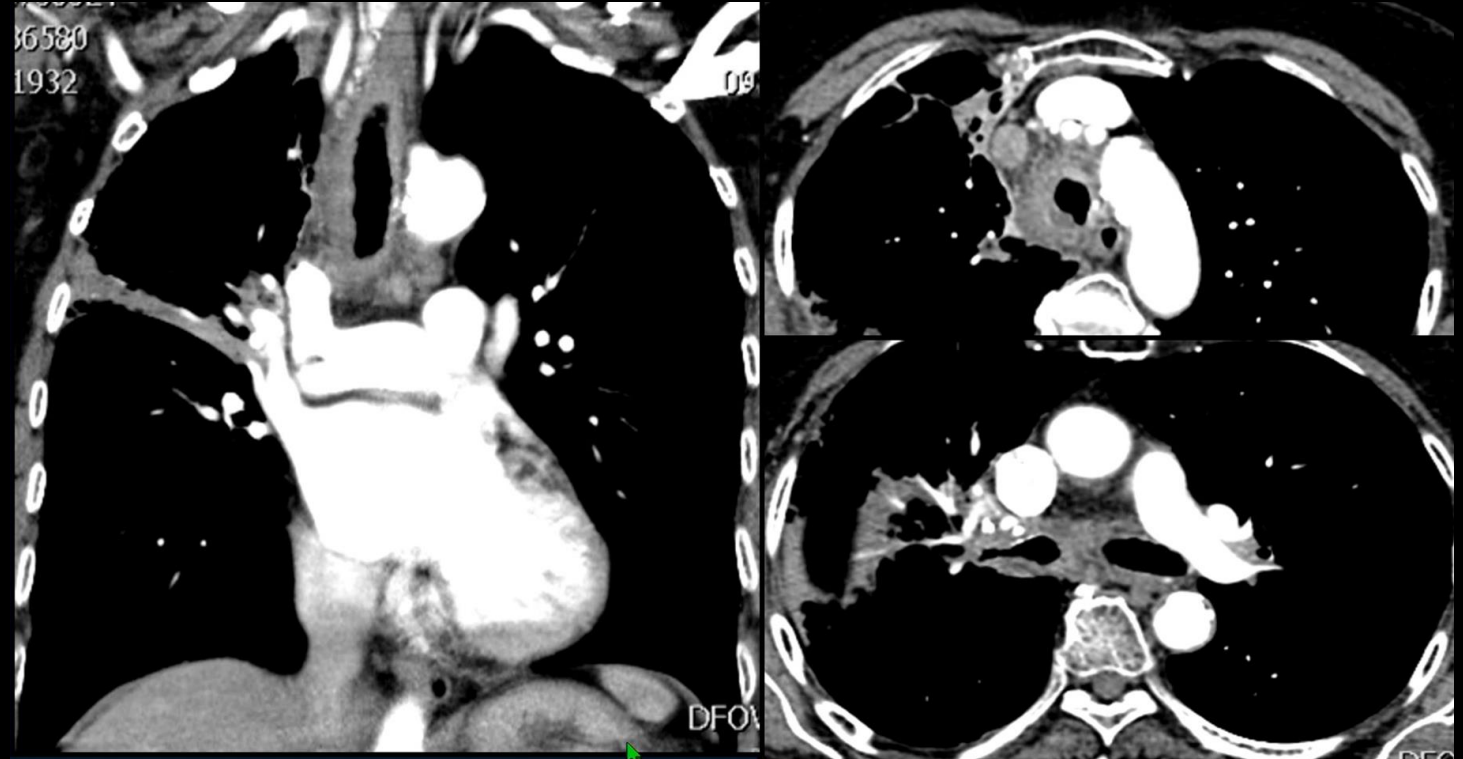
- Relapsing polychondritis
- Granulomatosis with polyangiitis
- Fibrosing mediastinitis
- Sarcoidosis
- Inflammatory bowel disease

Case



Case:

- A thickening of the trachea and main bronchi;
- Irregular thickening, some atelectasis
- **Right hilar: some calcifications**, right hilar region;



Large airways diseases: (3) Infection

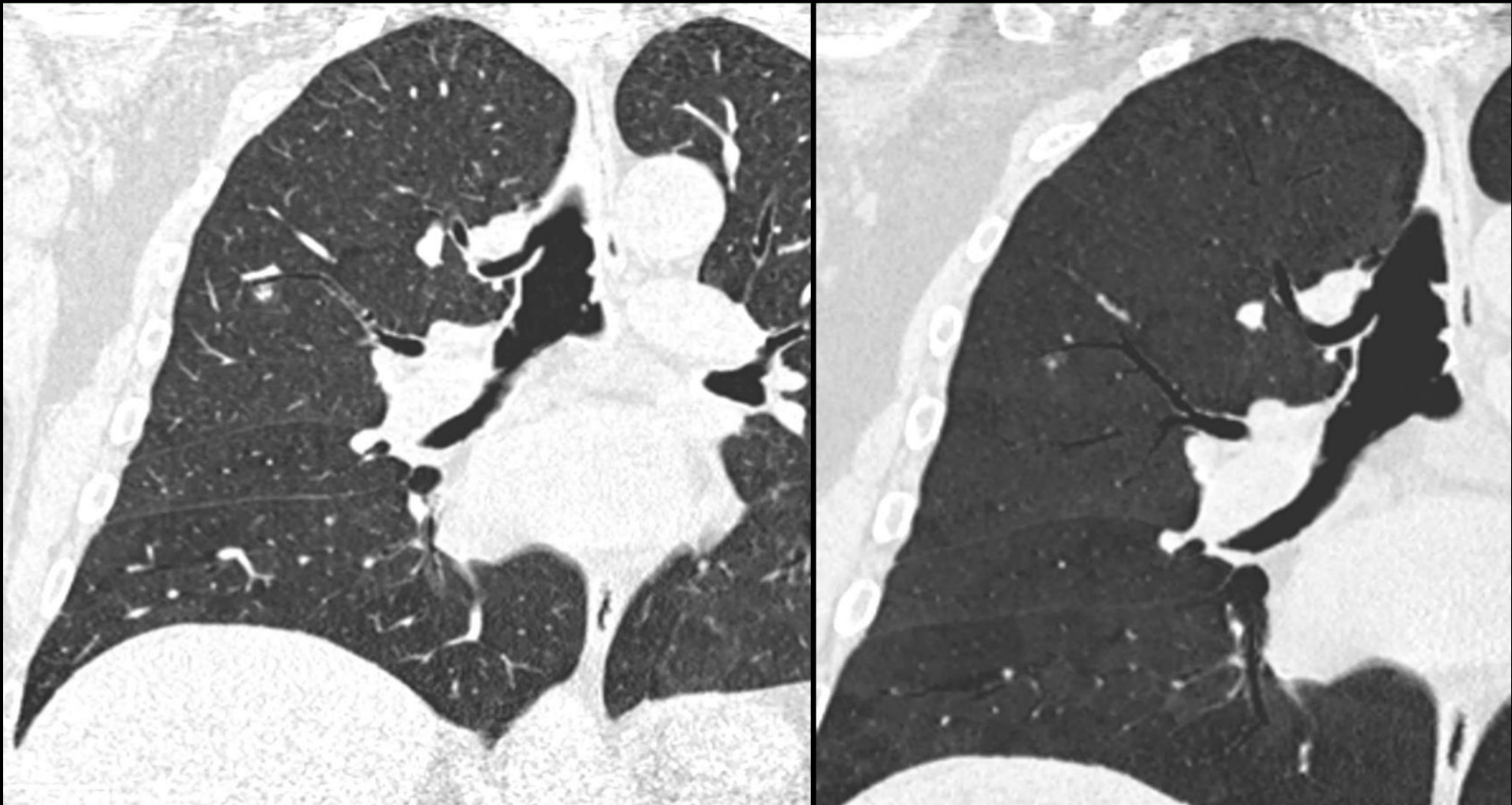
Tuberculosis

- Usually involves **distal trachea and proximal bronchi**
- Tracheobronchial wall thickening and stenosis
- **Late stage of stenoses usually long (>3cm)**
- **Left main bronchi (LMB)** > right main bronchi (RMB)
- Concentric luminal narrowing
- Atelectasis or obstructive pneumonitis
- Lymphadenopathy

Large airways diseases: (3) Infection

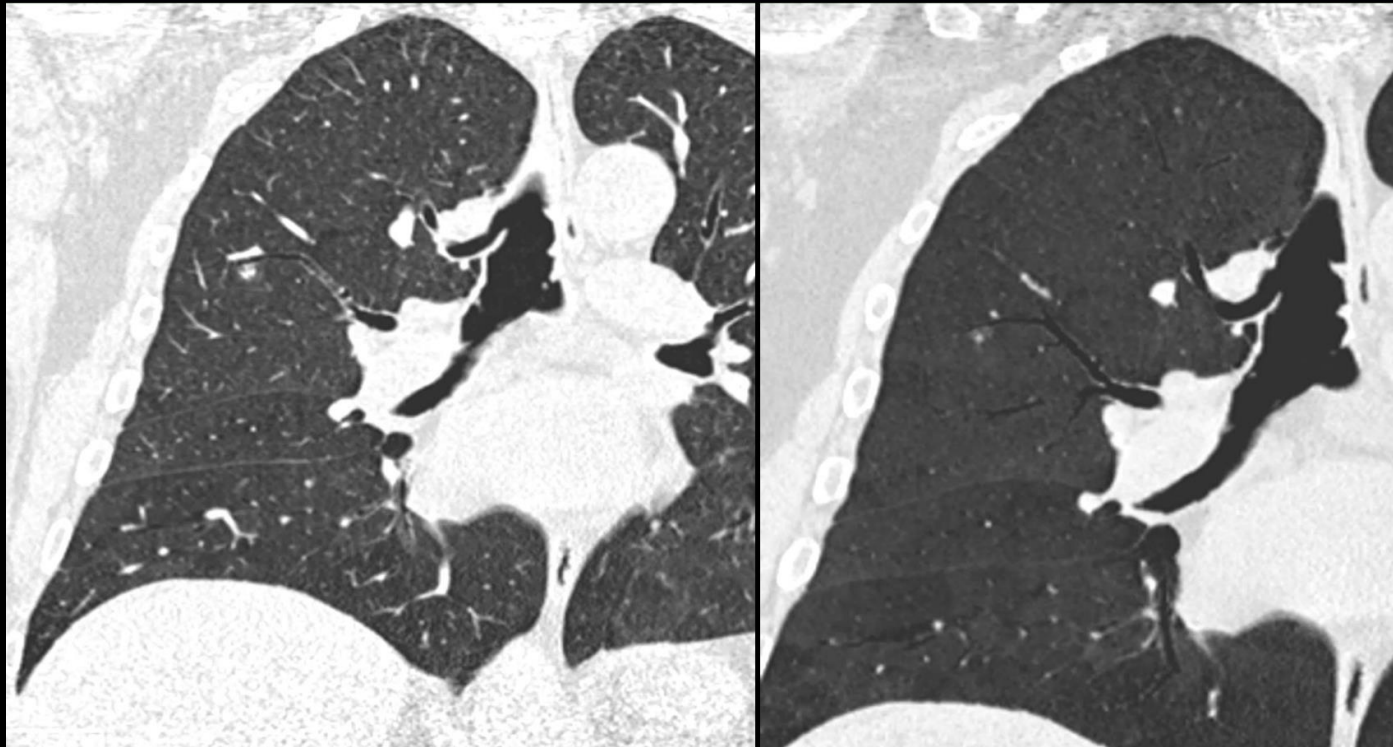
- **Chronic infections** more common than acute infections in adults
- Bacterial tracheitis
- Tuberculosis
- Fungus (especially Aspergillus)
- Rhinoscleroma

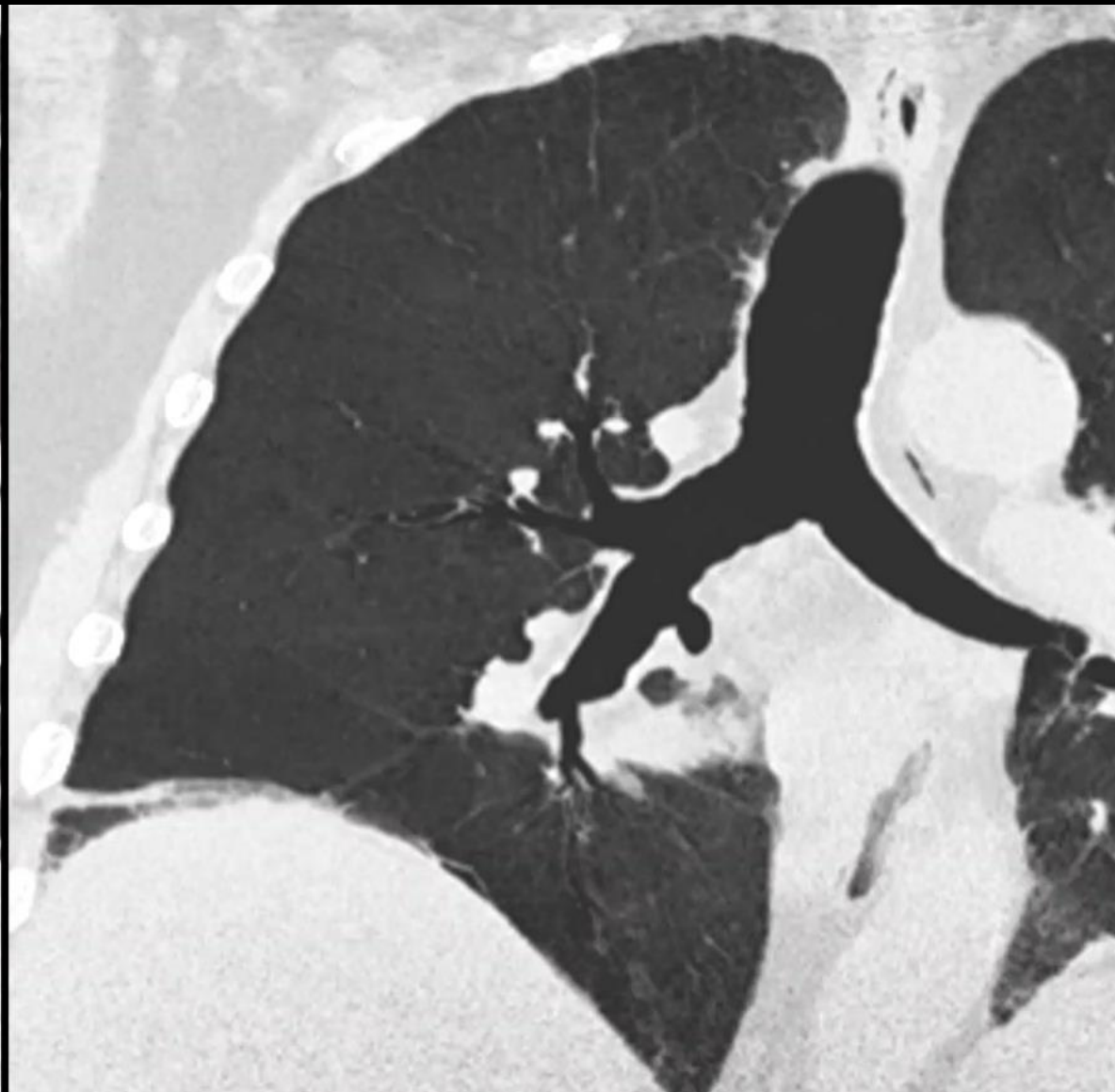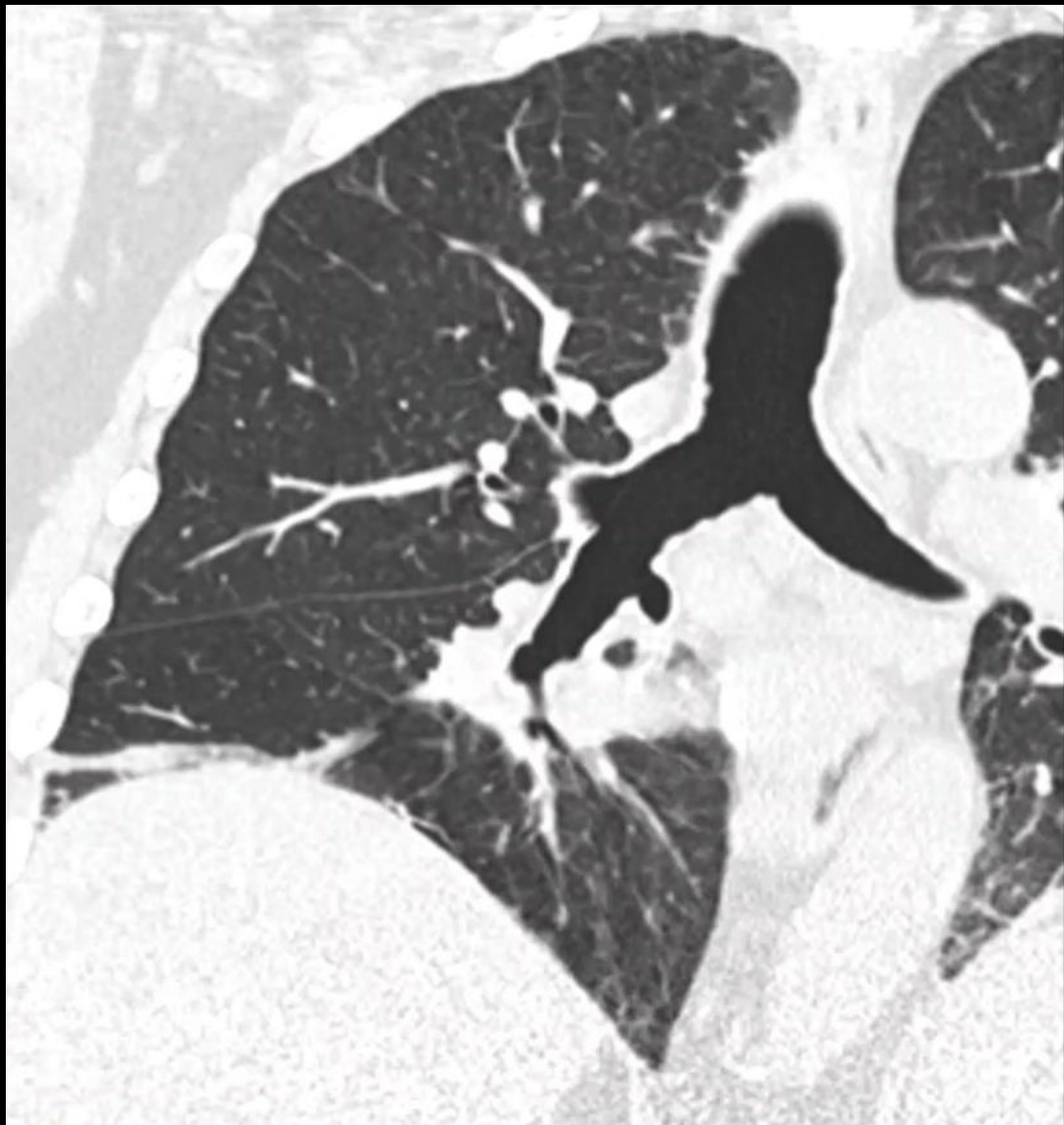Case:



Case: Tracheal bronchus

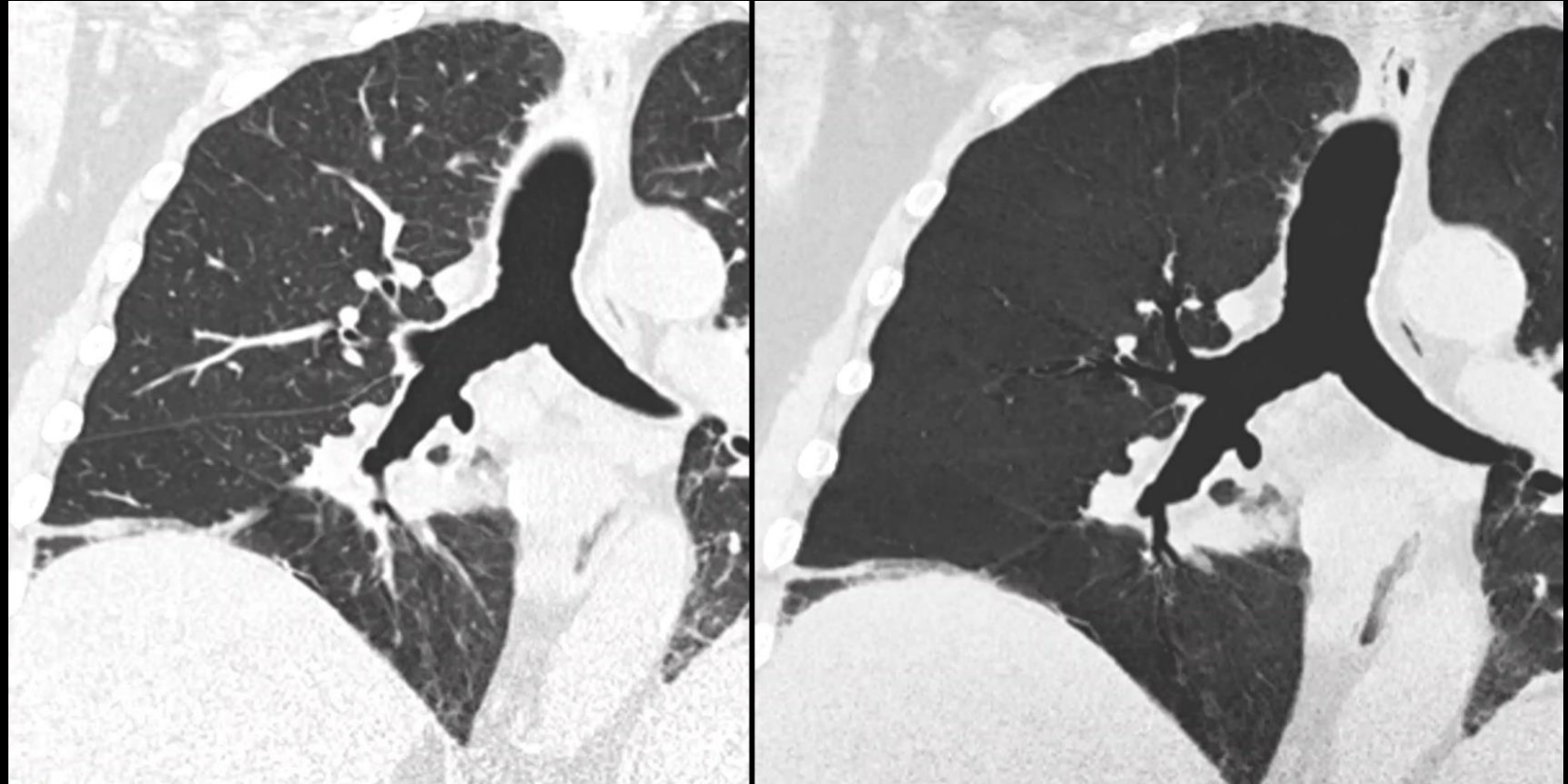
- Usually have some vascular abnormalities
- Case: extends into the right lung





Cardiac bronchus

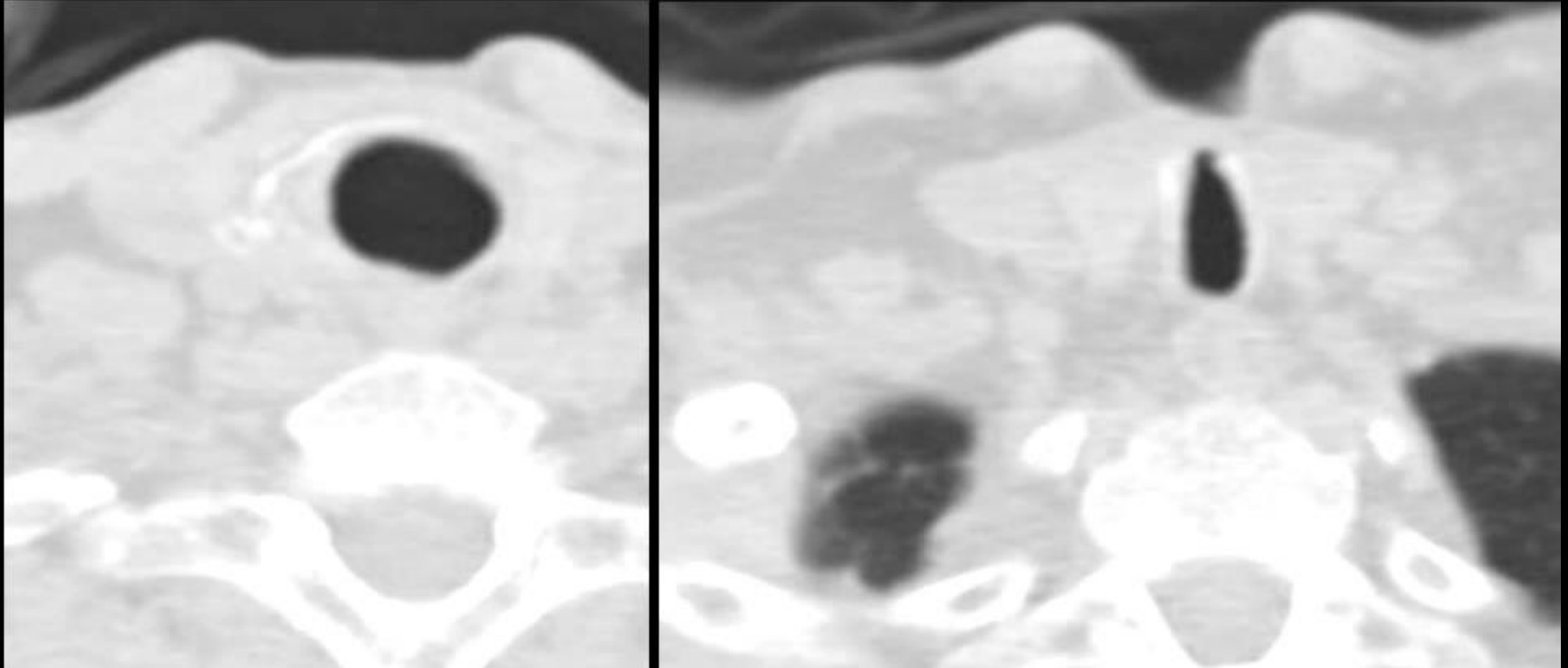
- Can have some kinds of symptoms
- **A pouch in the bronchial intermediate in the medial aspect of the bronchus**
- Can be filled with mucus
- **Repetitive infections: middle lung**



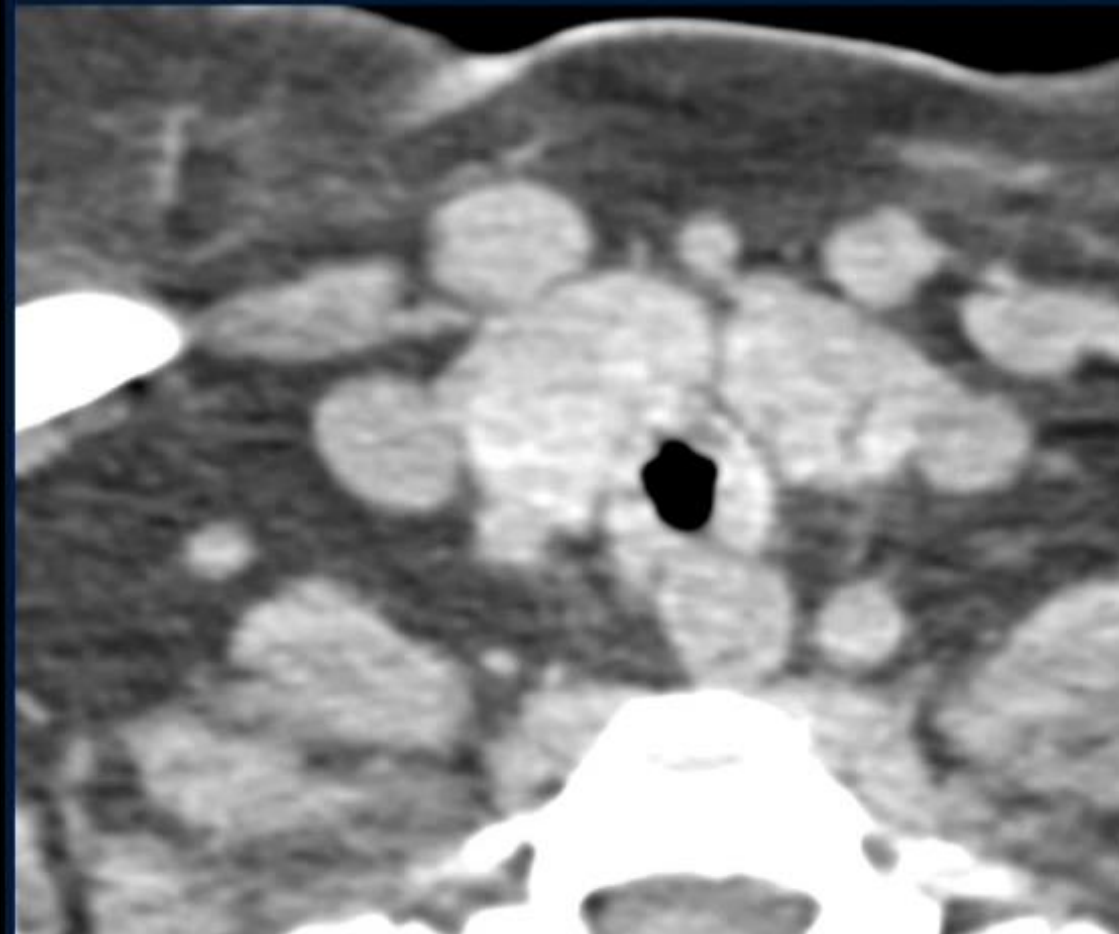
Large airways diseases: (4) congenital

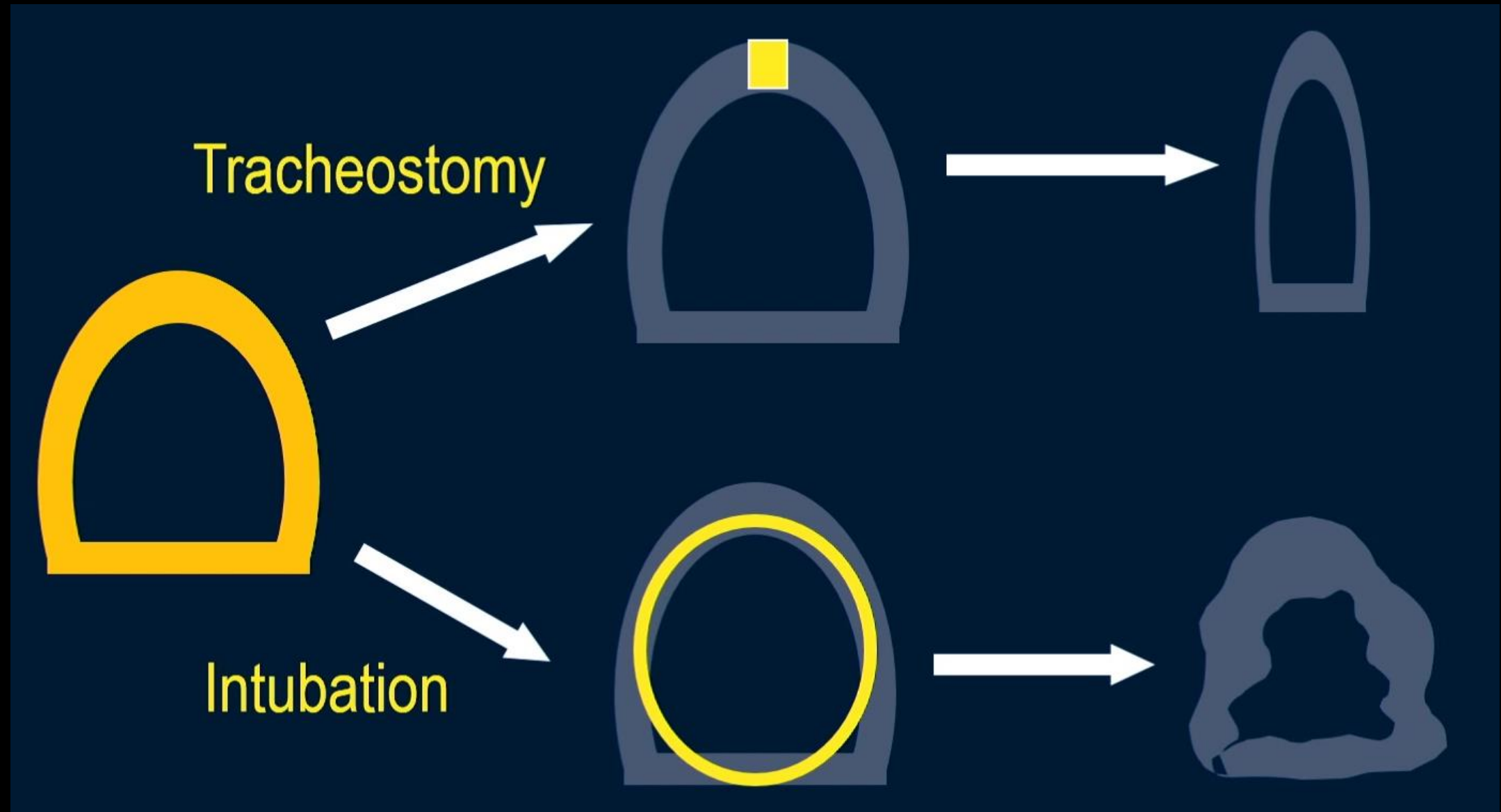
- Numerous variants of airway branching exist
- Variation more common in **the distal airways**
- Accompanying vascular anomalies may be present
- Two main variations:
 - (1) **Tracheal bronchus (0.5-2%)**
 - (2) **Cardiac bronchus (0.5%)**
- Occasionally associated with tiny rudimentary lobe (未發育完全)

Case:



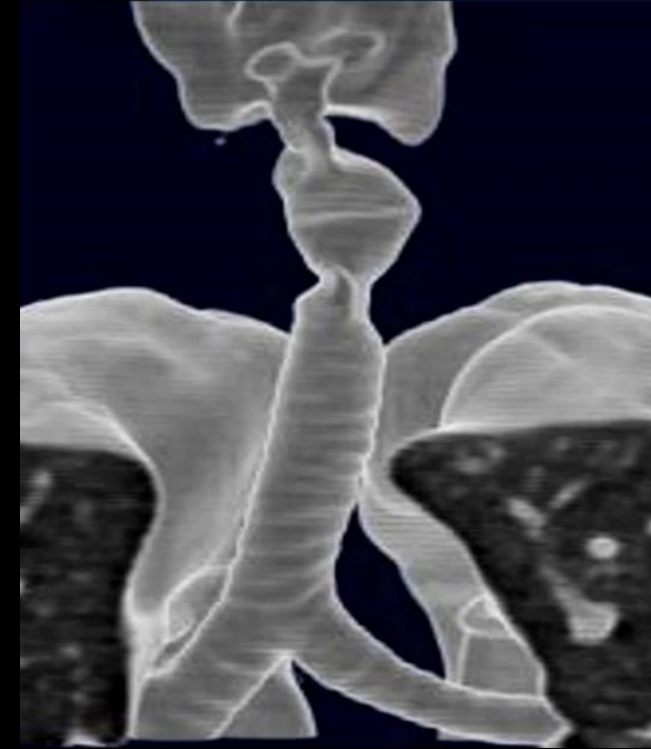
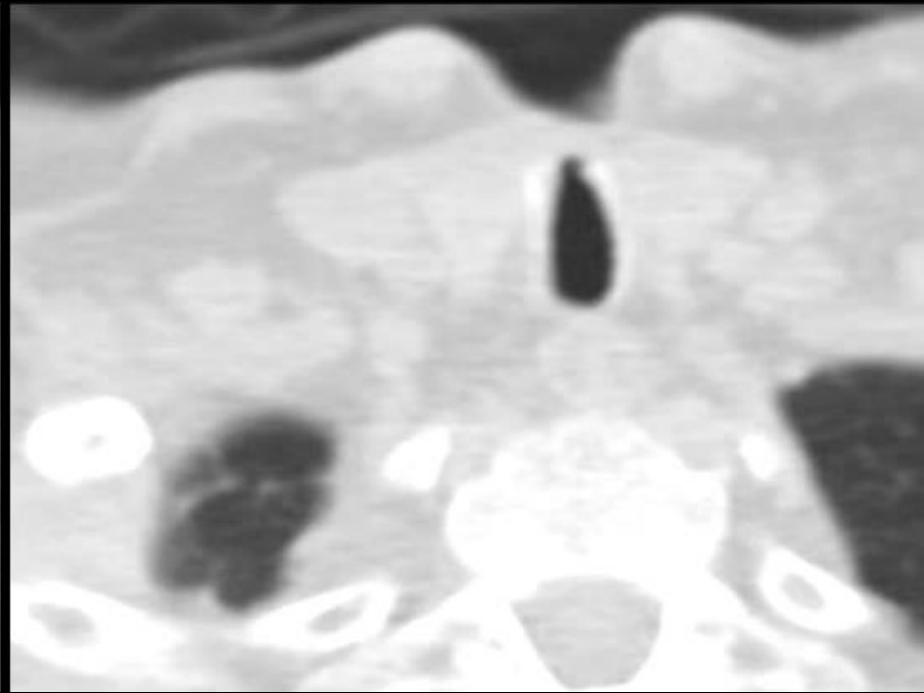
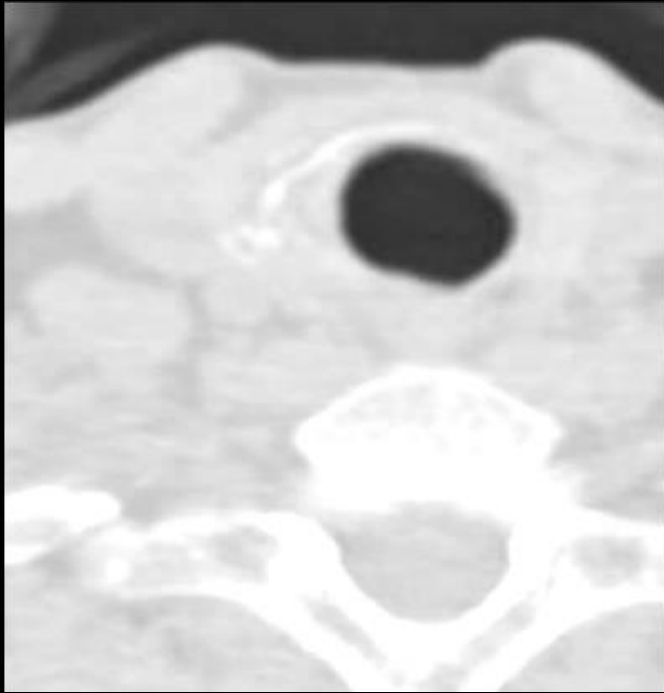
Case:



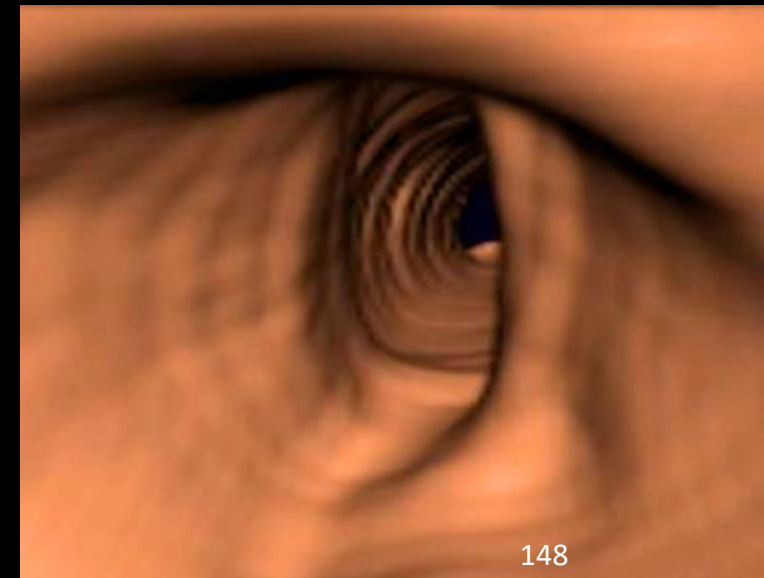


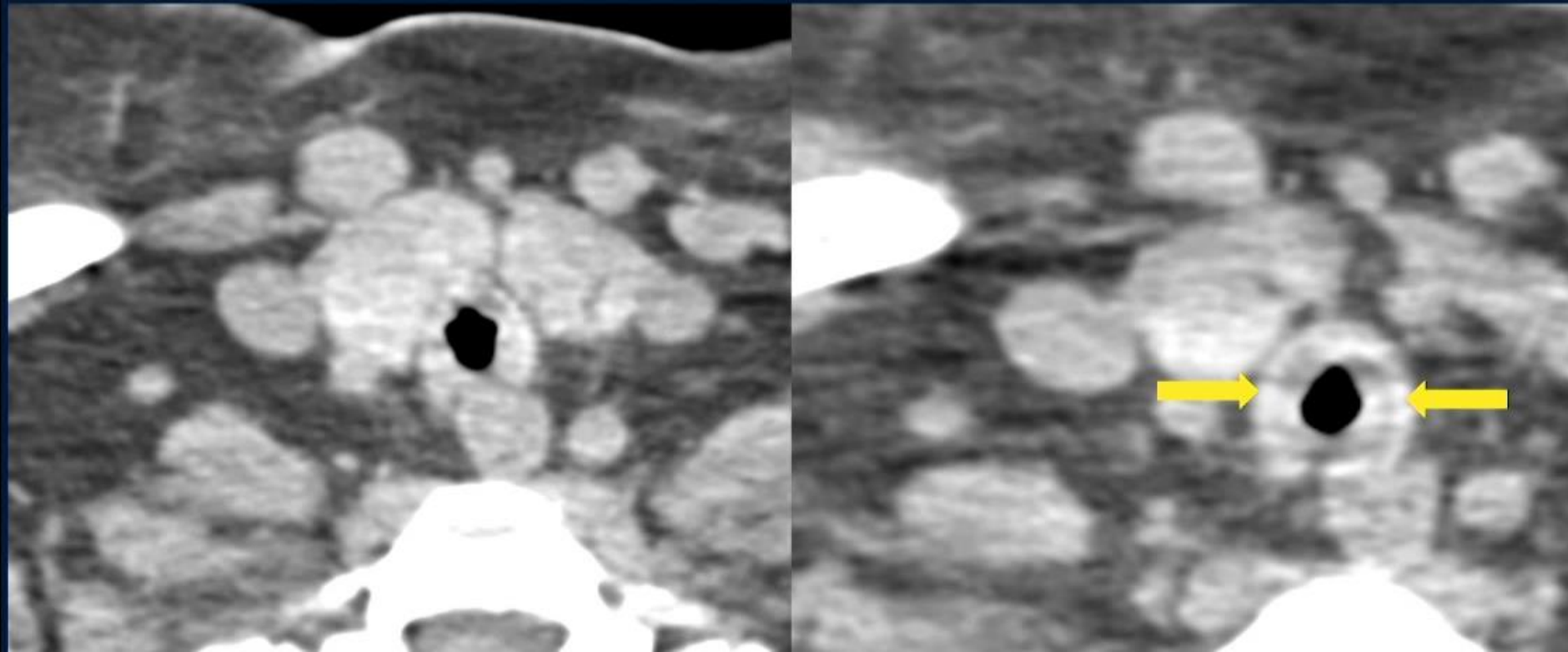
Case: Post-intubation vs post-tracheostomy

- Post-intubation vs post-tracheostomy
- Post-tracheostomy: CT: anterior –posterior enlargement due to ischemic injury of the site of tracheostomy (measure the width and the extension; narrowing of the trachea)
- Post-intubation: granulomatous tissue due to compression of the balloon at the area of the trachea;



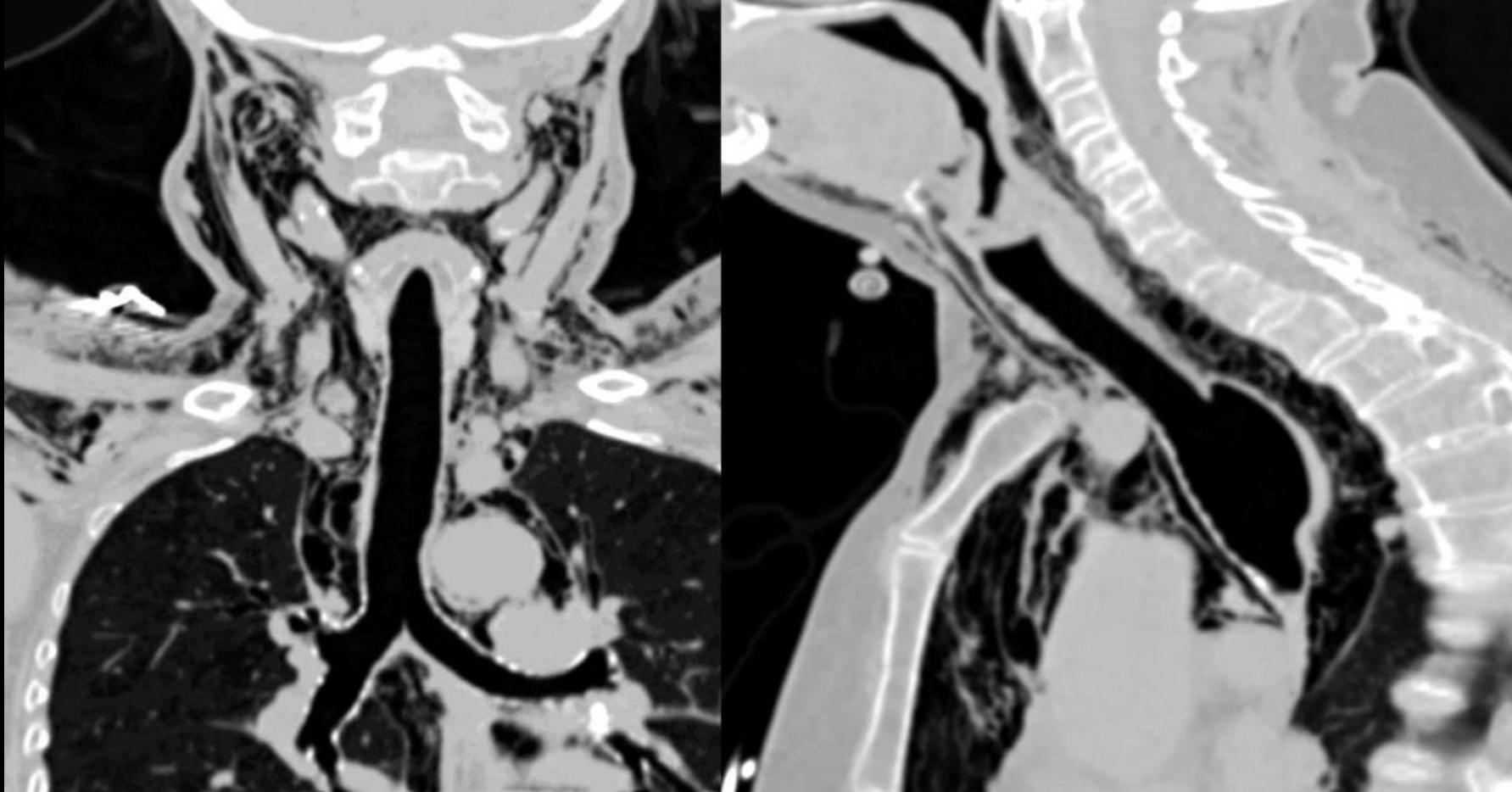
- Post-tracheostomy: CT: **anterior –posterior enlargement** due to ischemic injury of the site of tracheostomy
(measure the width and the extension;
narrowing of the trachea)





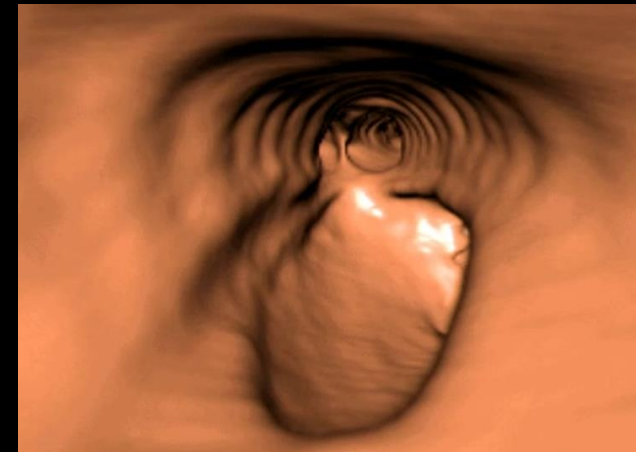
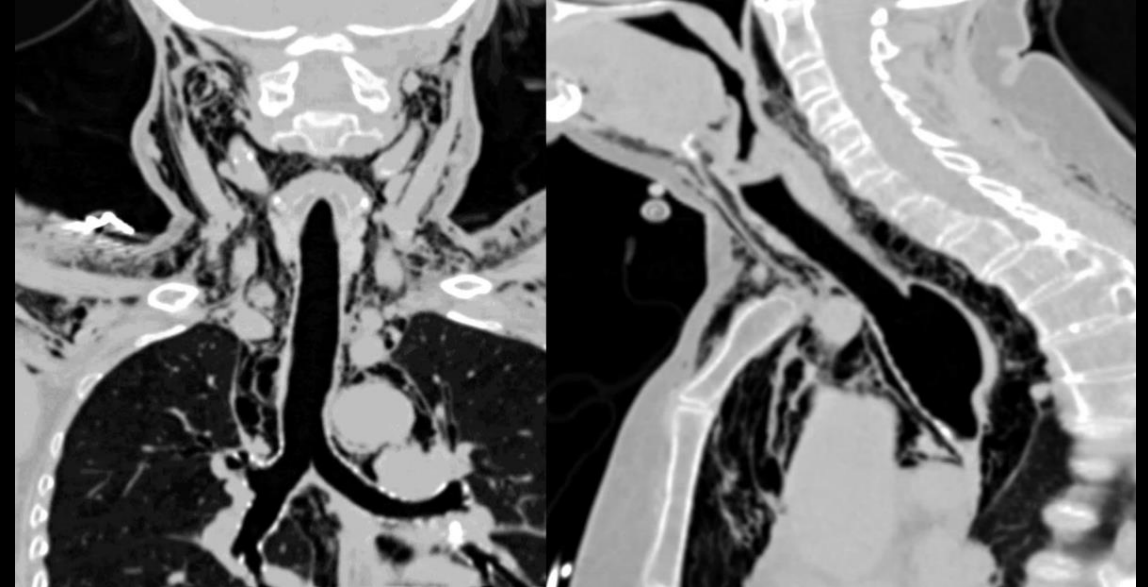
- Post-intubation: granulomatous tissue due to compression of the balloon at the area of the trachea;

Case:



Case: tracheal rupture

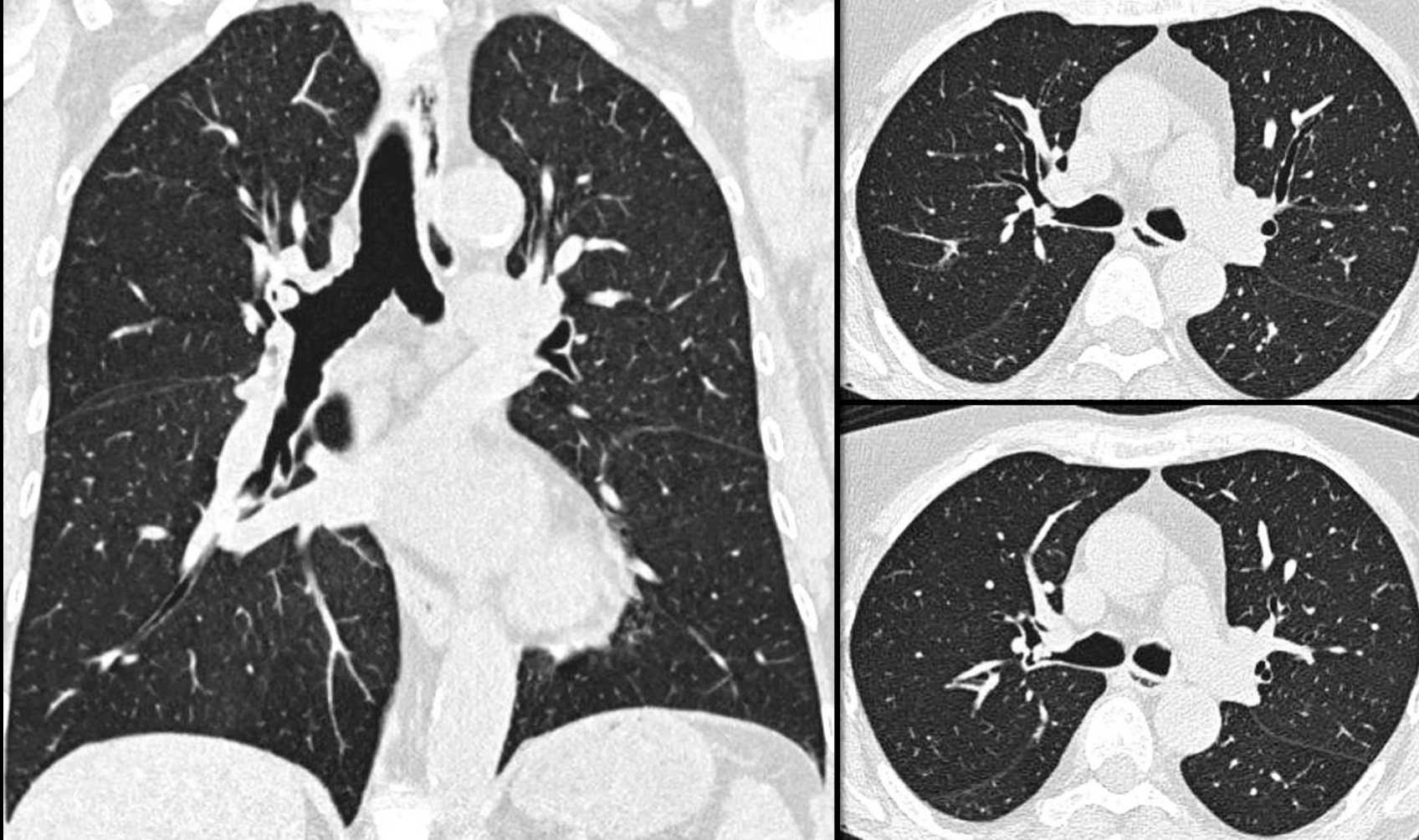
- CT chest: Subcutaneous emphysema
- Pneumomediastinum
- Bulging of the trachea
- **Cause: iatrogenic; trachea rupture through an endoscopic procedure**
- Endotracheal tube intubation;



Large airways diseases: (5) Trauma

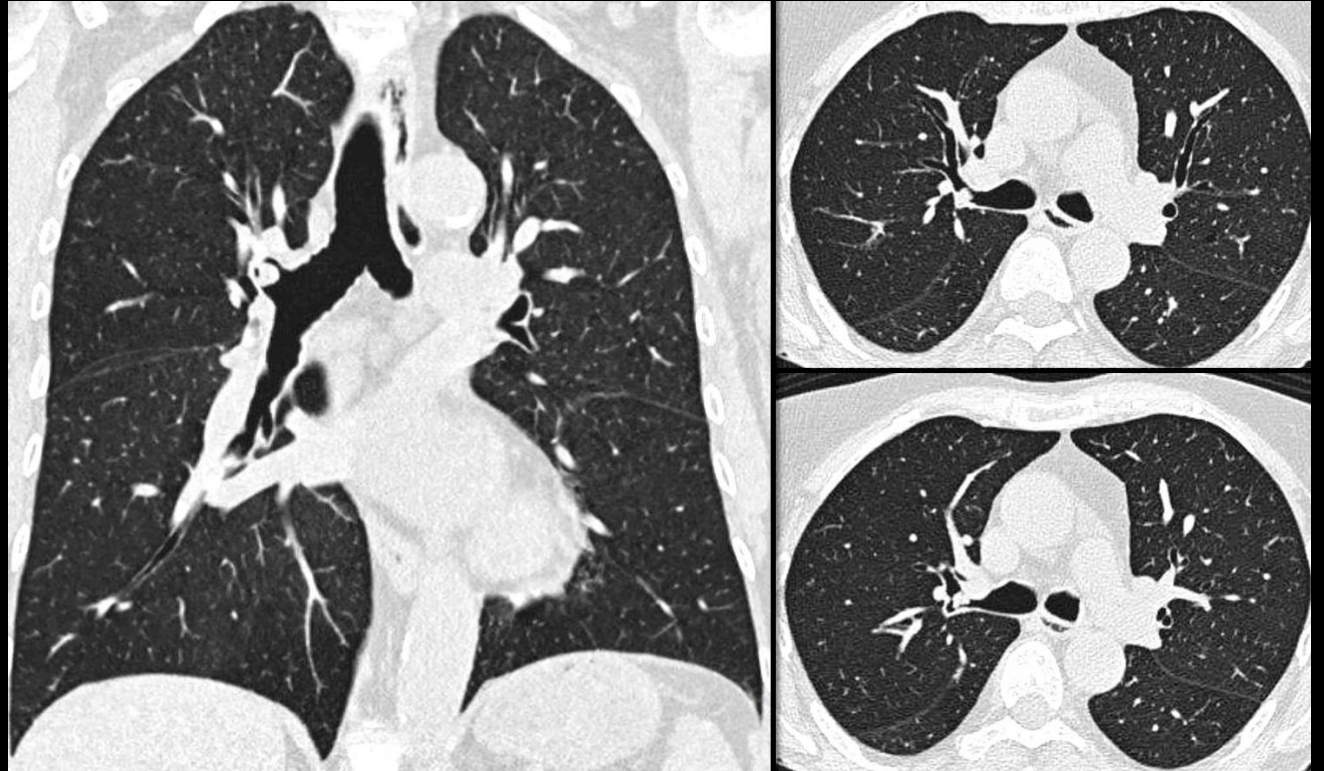- Deceleration injuries (motor vehicle accidents, MVCs and falls)
- Penetrating trauma
- Iatrogenic:
 - - Rupture
 - - Stenosis
 - - Mucosal ischemic injury

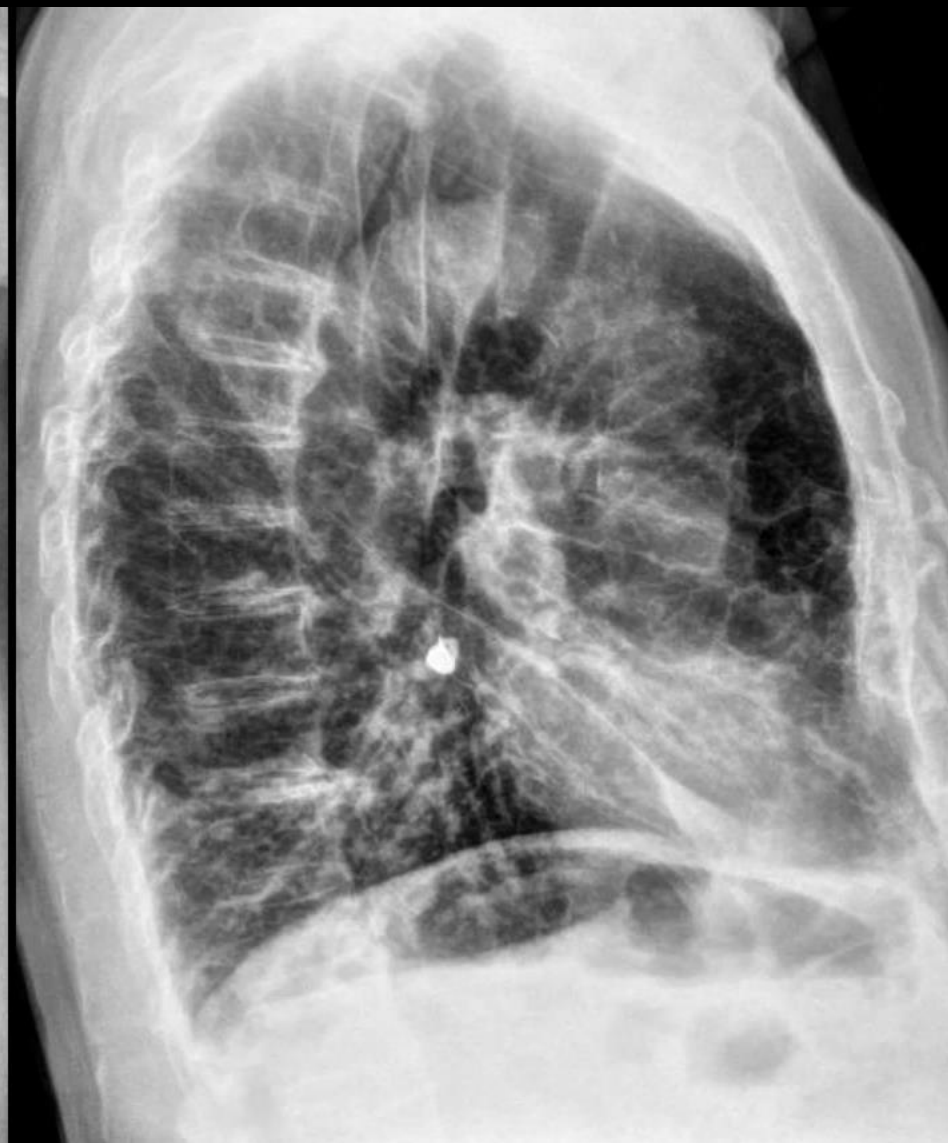
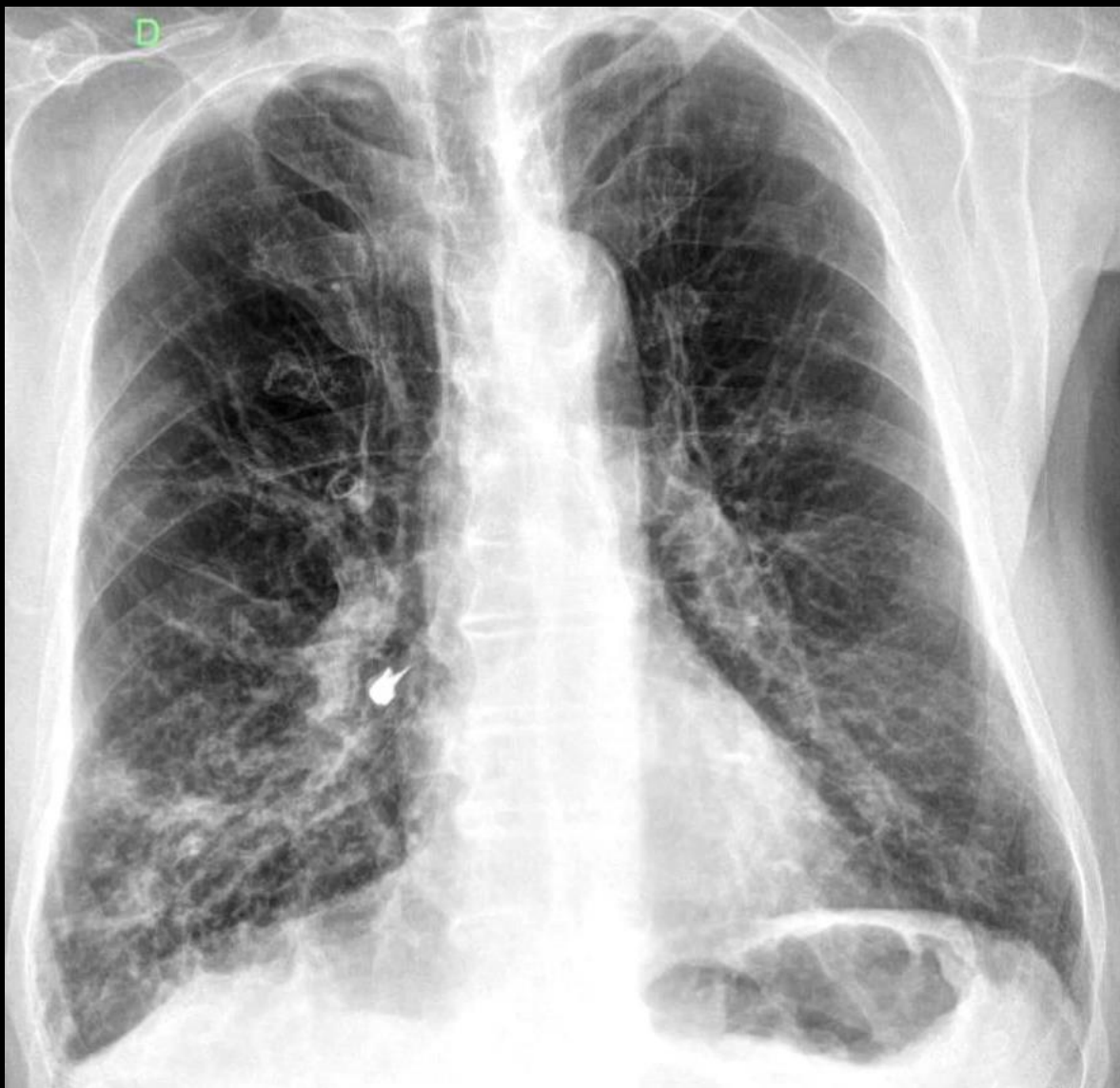
Case:

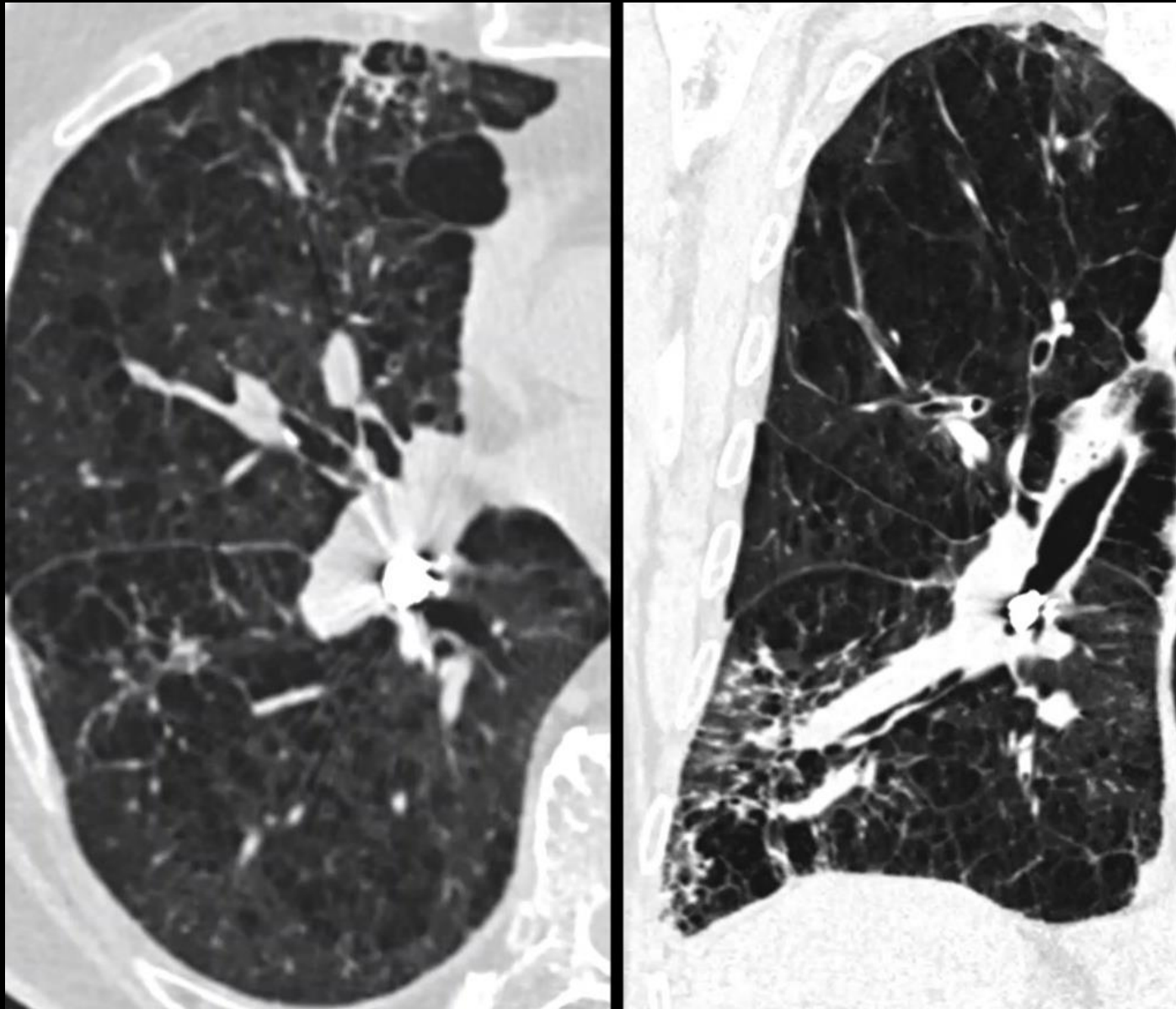


Case: Foreign body

- Case: 45 Y/O female
- S/S: Cough and dyspnea
- CT chest: A nodule lesion in the right bronchus
- **Foreign body (Corn)**

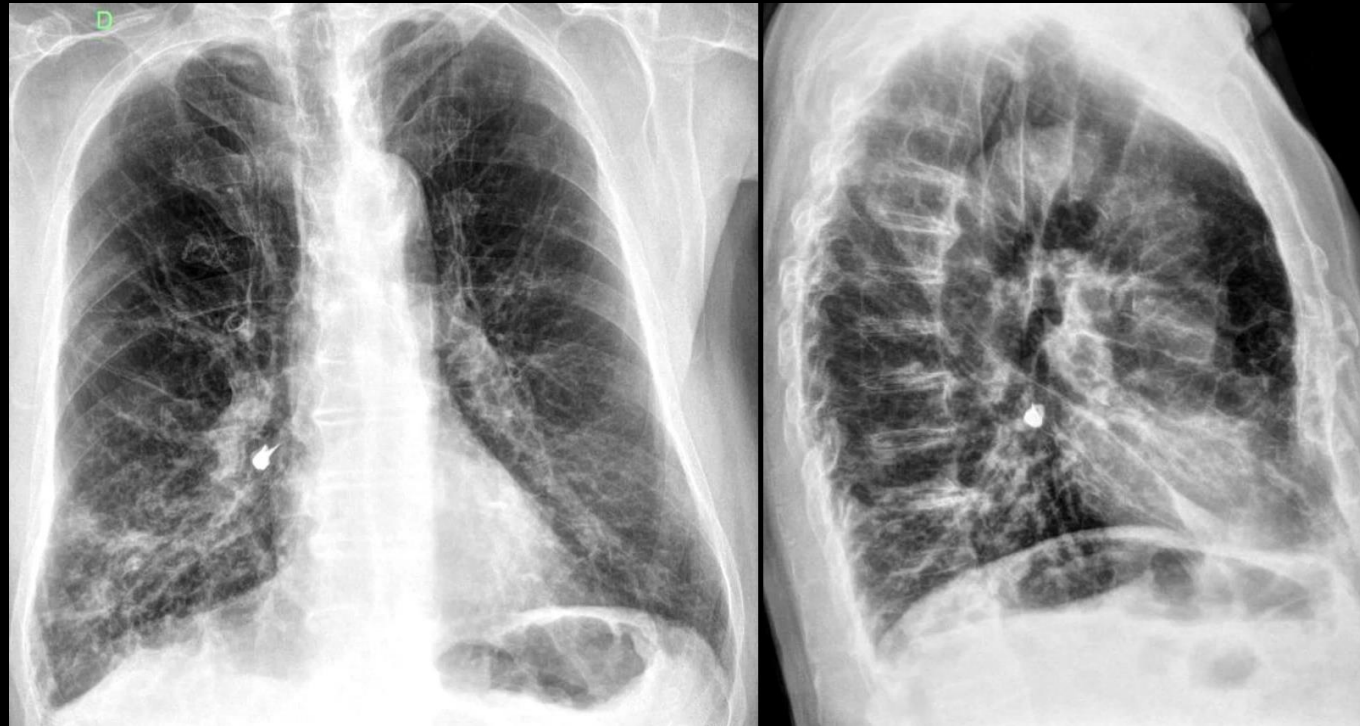





Case: Foreign body

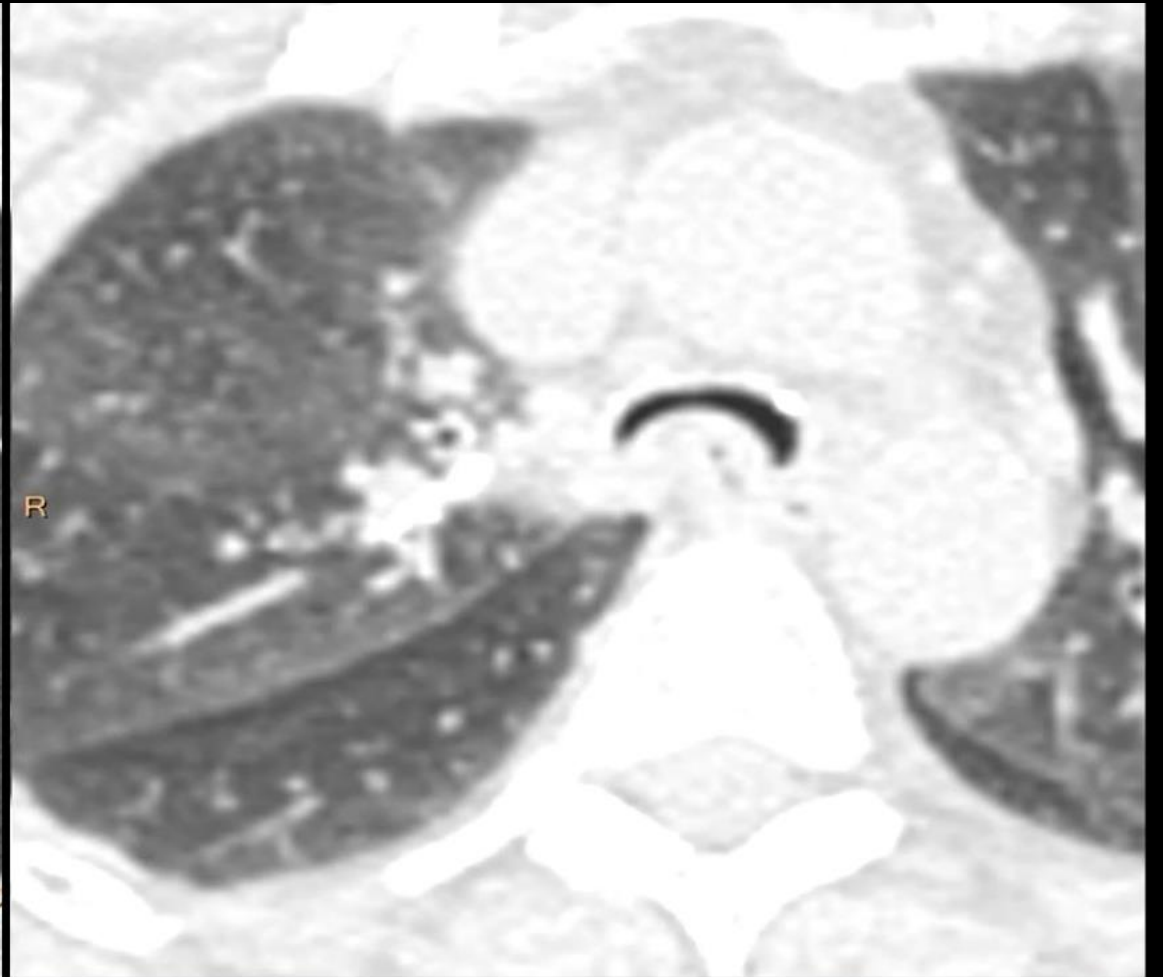
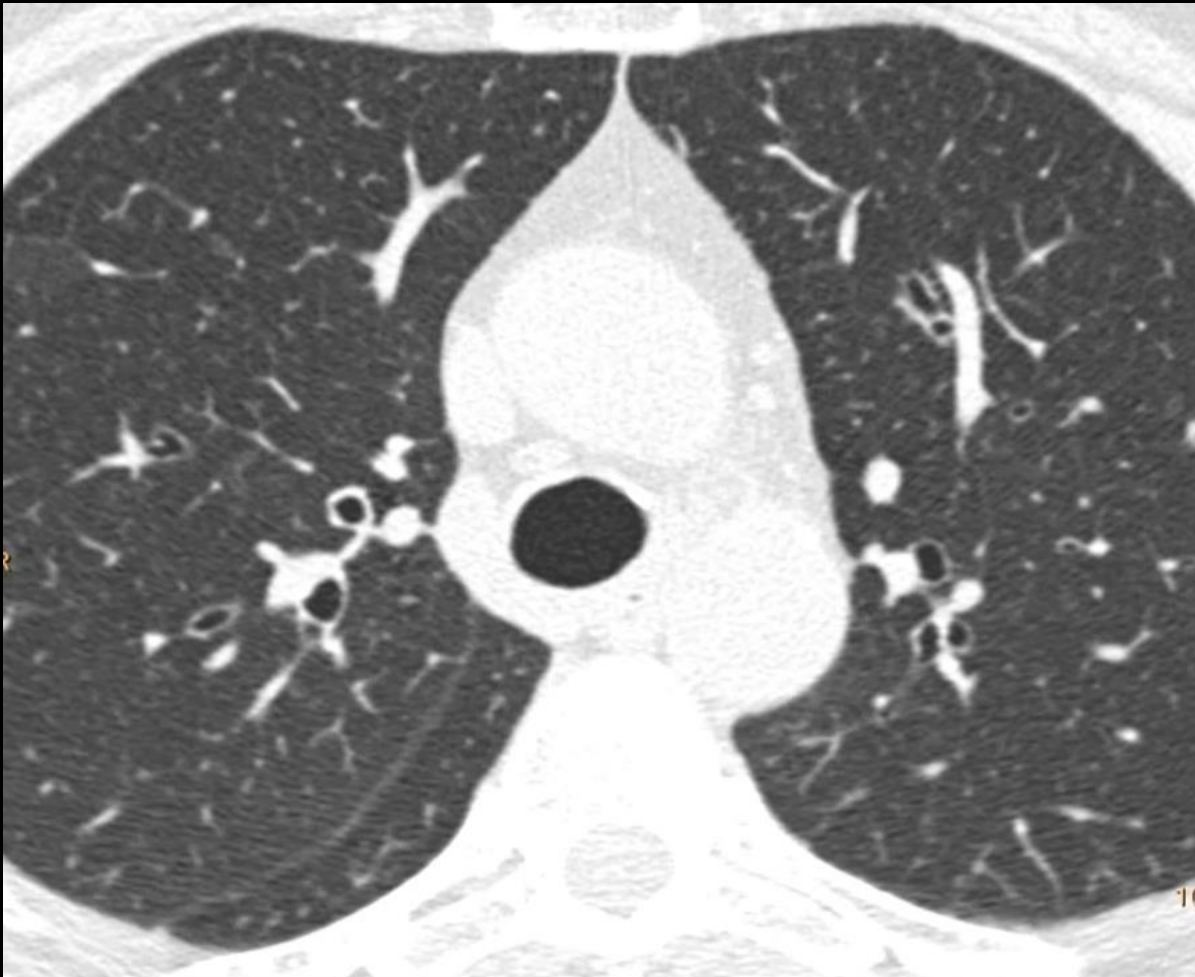- 84 Y/O Male
- S/S: Cough
- Former smoker 80 pack-years
- CxR: emphysema; right lower lung: **A dental device in the right lower bronchi**; obstructive pneumonitis; inflammation;



Large airways diseases: (6) Foreign body

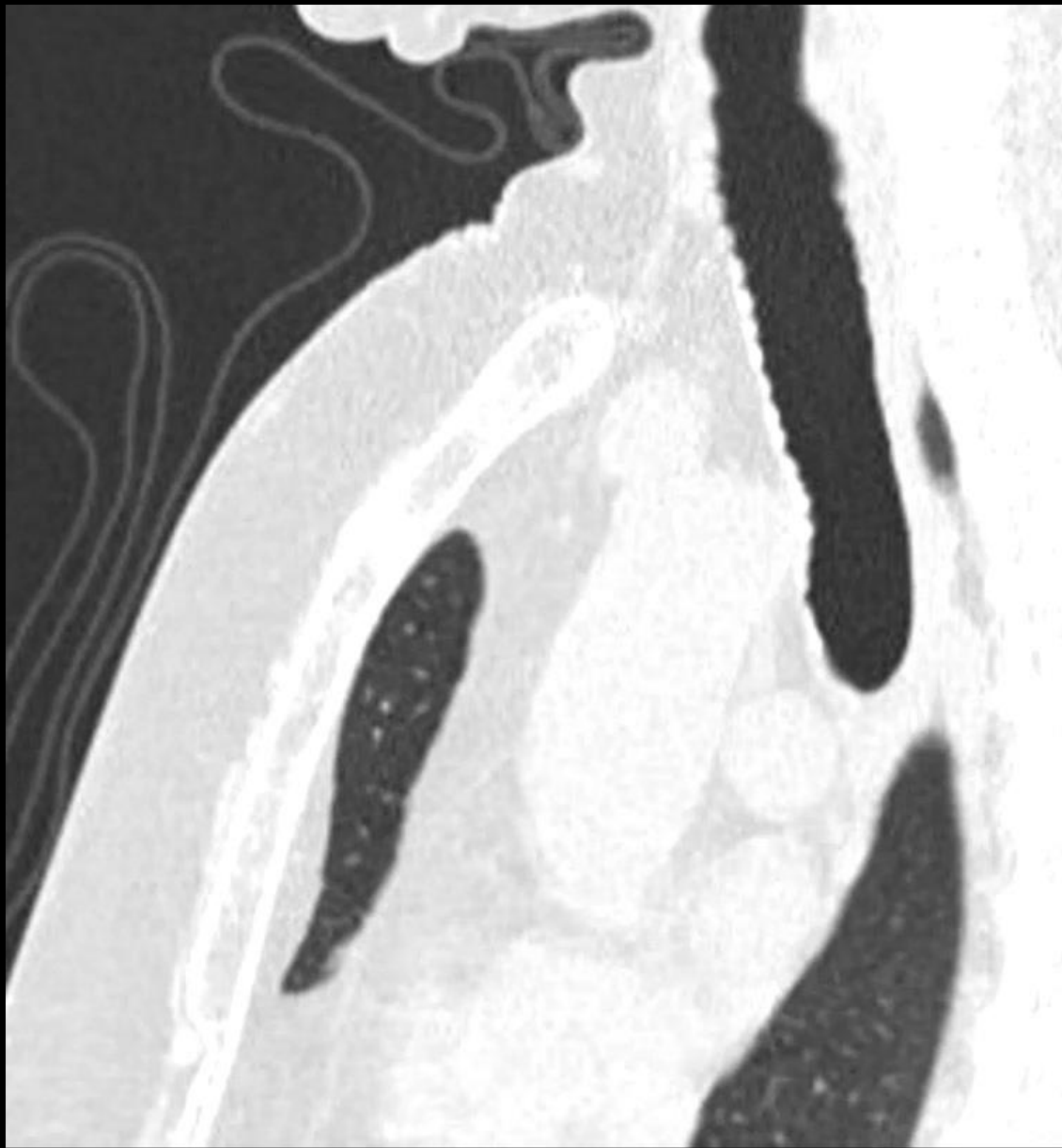
- Most commonly caused by **aspiration**
- Incidence in children is higher than in adults
- Food (nuts), teeth, dental devices and medical instruments
- S/S: Cough, wheezing, stridor, dyspnea
- **Normal chest radiograph dose not exclude foreign body:**
ER

Case:

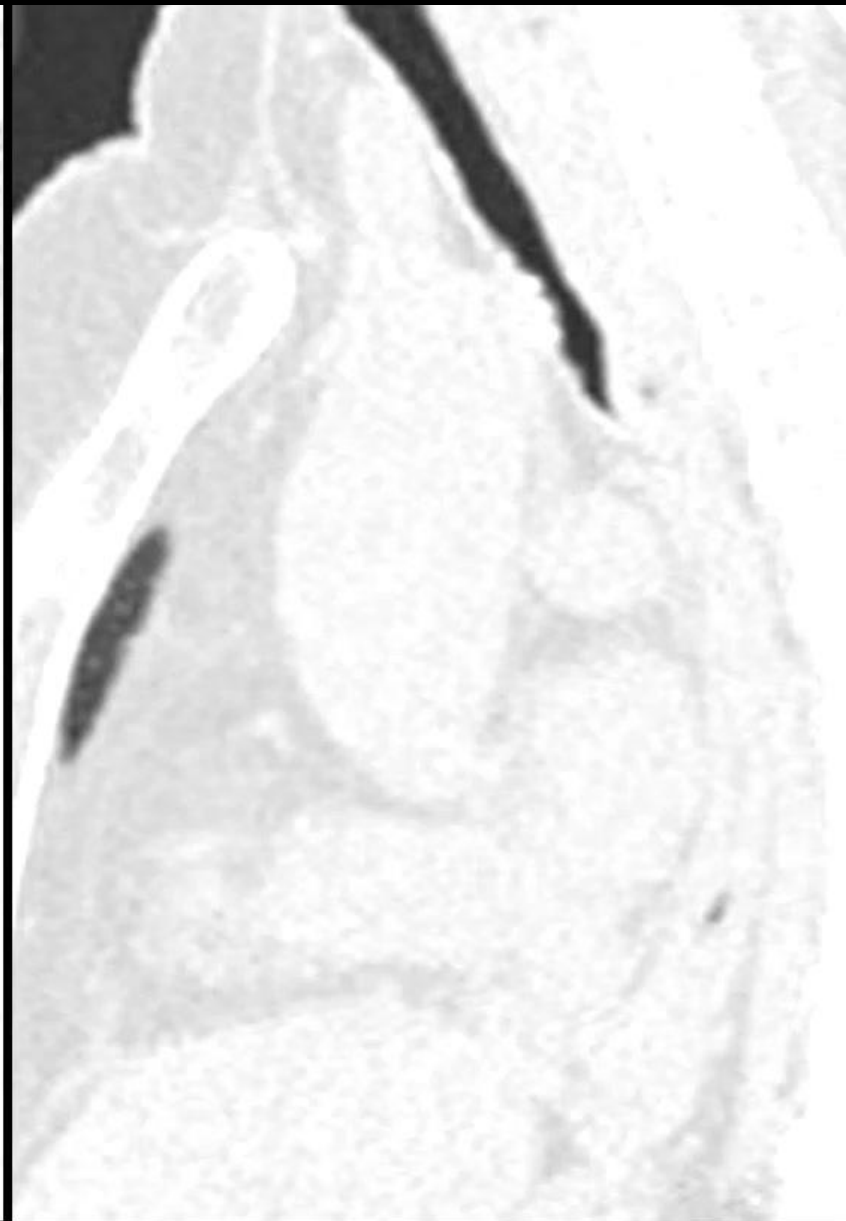

Case: Tracheobronchomalacia

- Case: 62 Y/O female
- **Recent history of asthma**
- S/S: Dyspnea
- Former smoker: 5 pack-years
- Inspiratory and Dynamic Expiratory CT:
- Use dynamic expiratory CT for dyspnea patients!
- Sagittal: CT: collapse of trachea; Tracheobronchomalacia

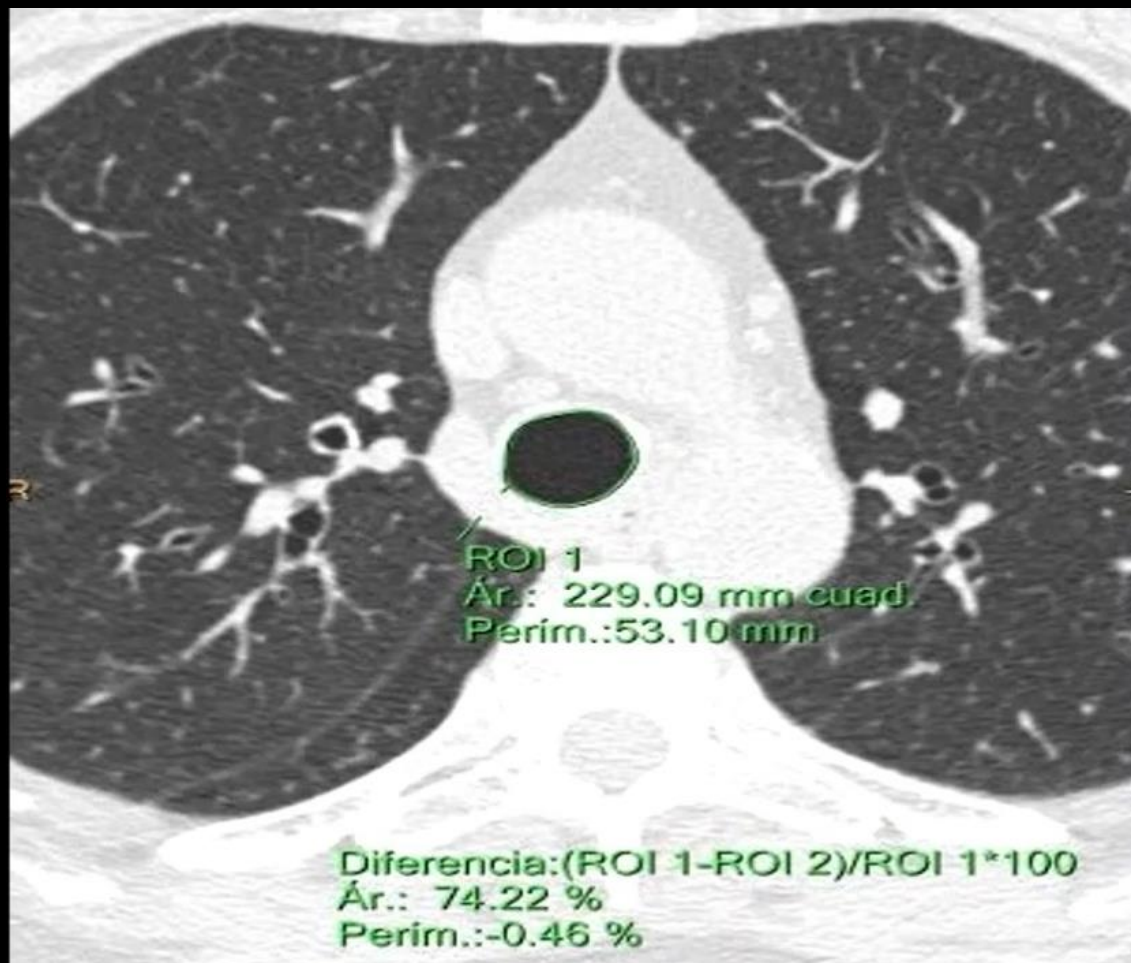


Inspiratory CT

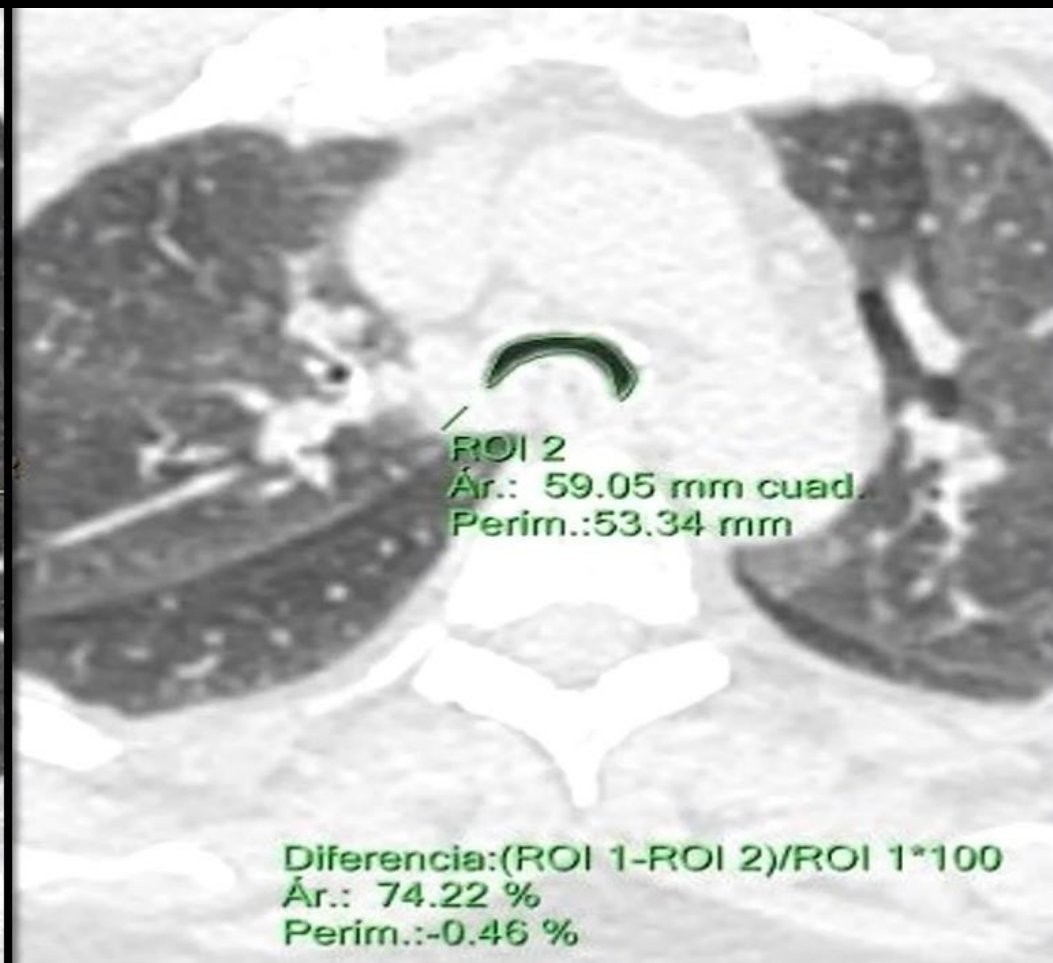


Dynamic Expiratory CT

Tracheobronchomalasia



Inspiratory CT



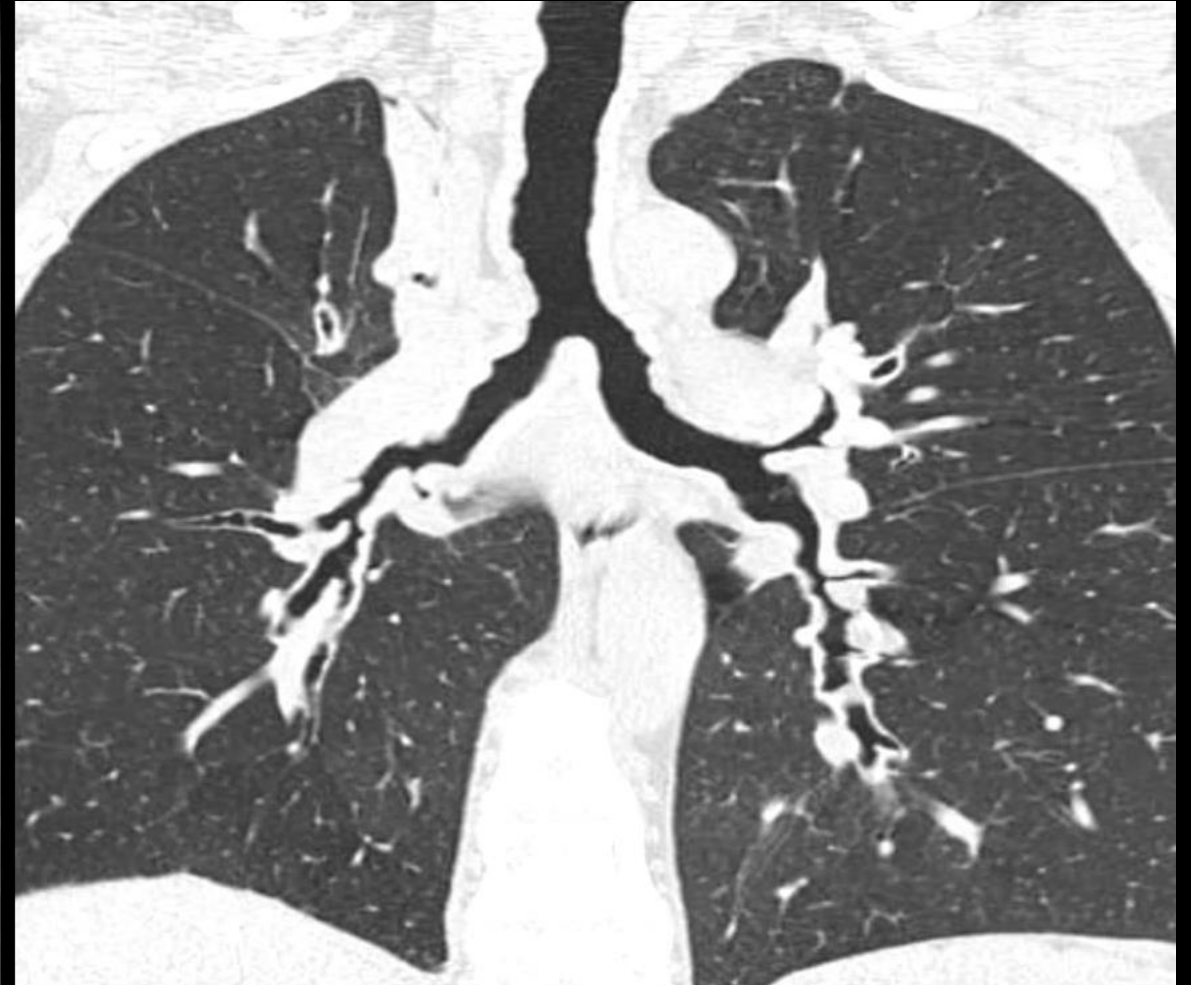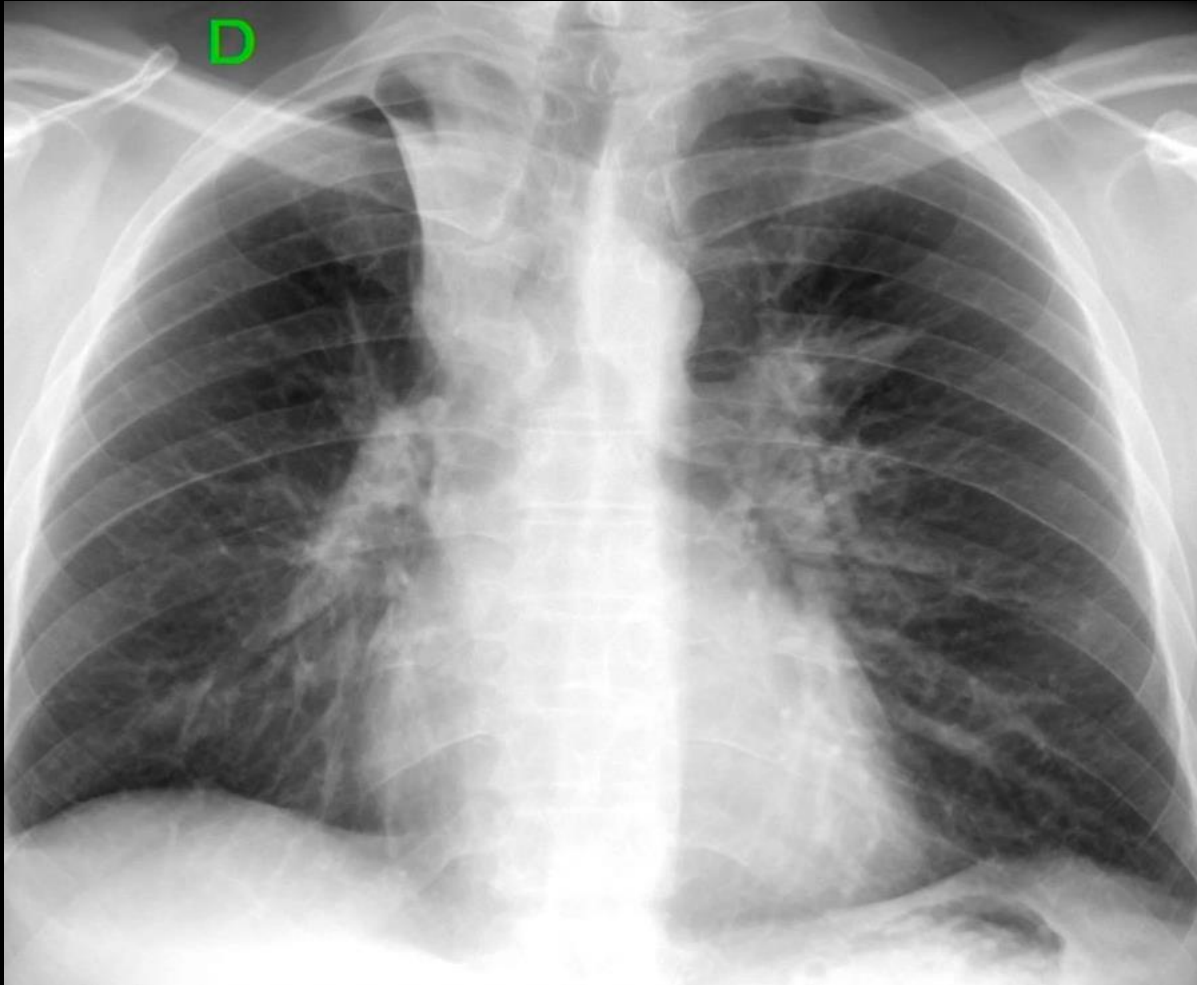
Dynamic Expiratory CT

Large airways diseases: (7)

Miscellaneous

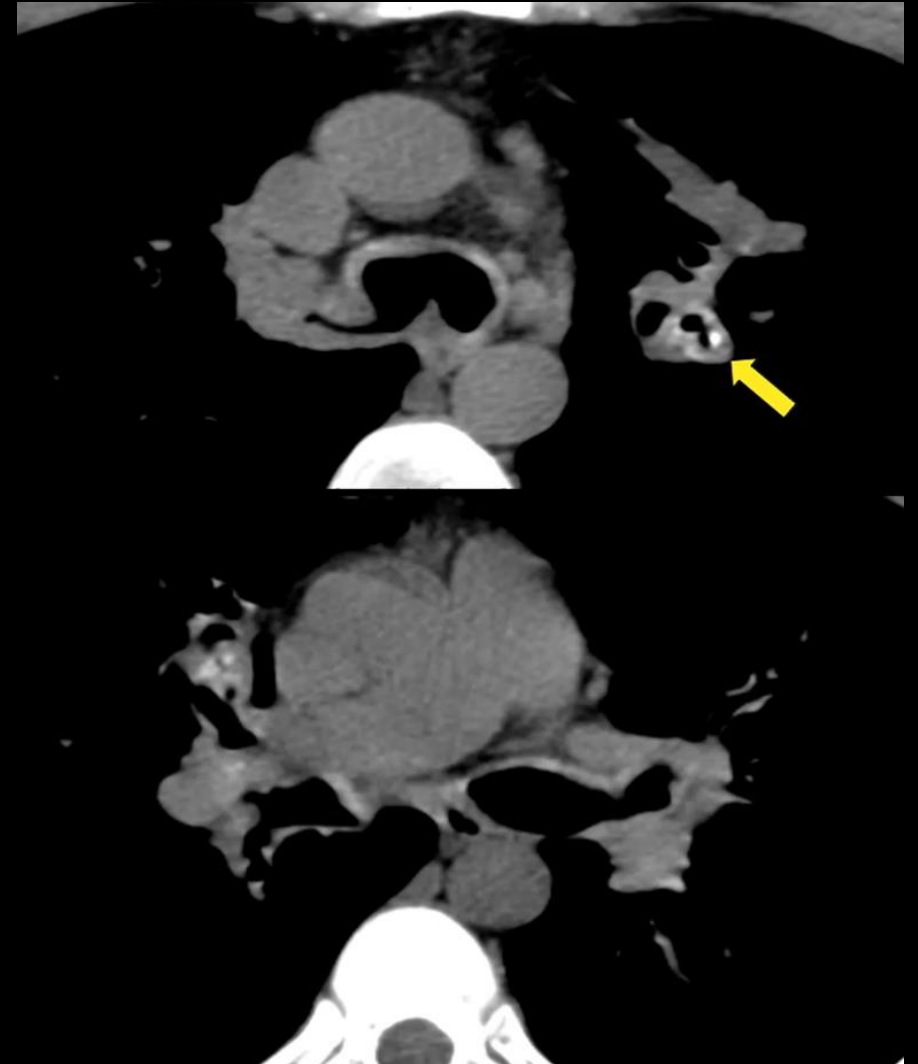
- Tracheobronchomalacia
- Increased compliance of trachea
- May only be elicited with inspiration (extrathoracic) or expiration (intrathoracic)
- Growing use of dynamic expiratory CT: for suspect dynamic compression of posterior tracheal membrane
- > 75 % cross sectional area at end expiration suggestive of malacia (COPD; asthma)
- Causes include RP, idiopathic, acute tracheitis, mucopolysaccharidoses, mediastinal lipomatosis

Case:



Case 7: Bronchial amyloidosis

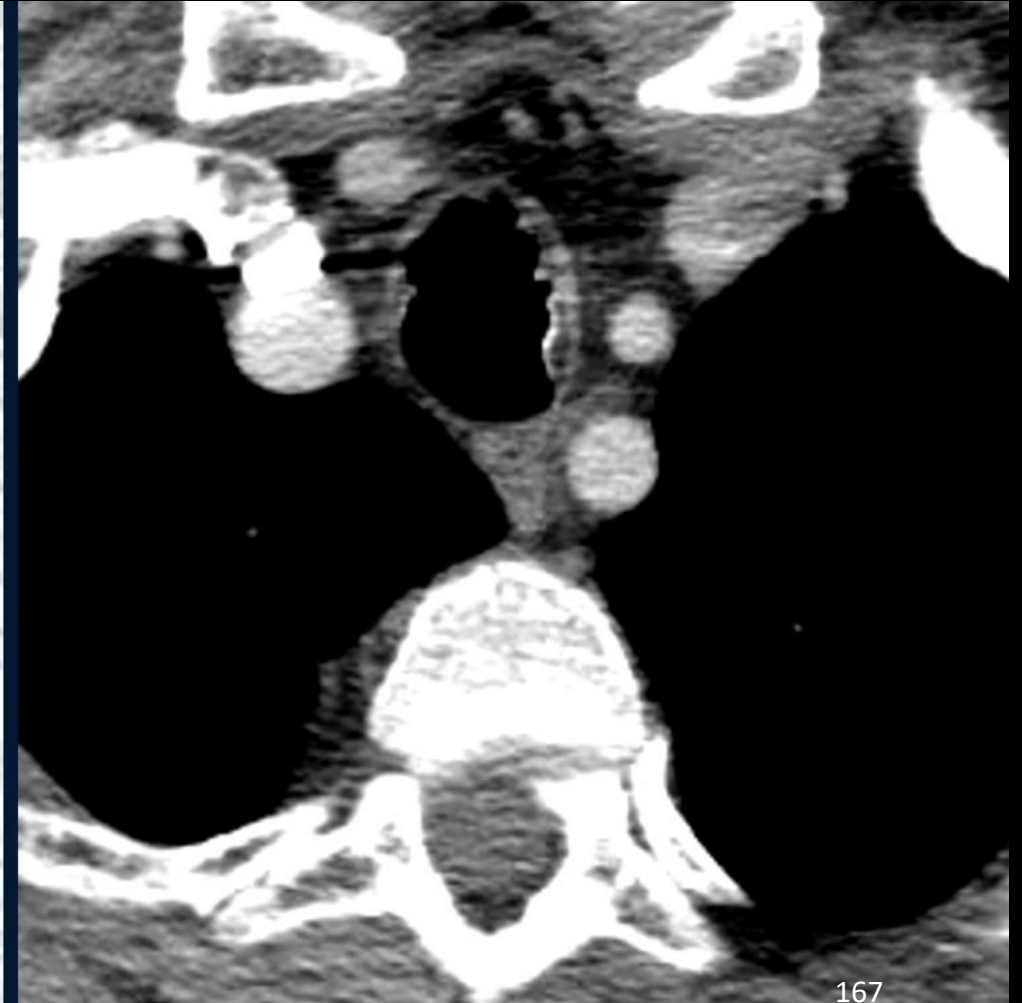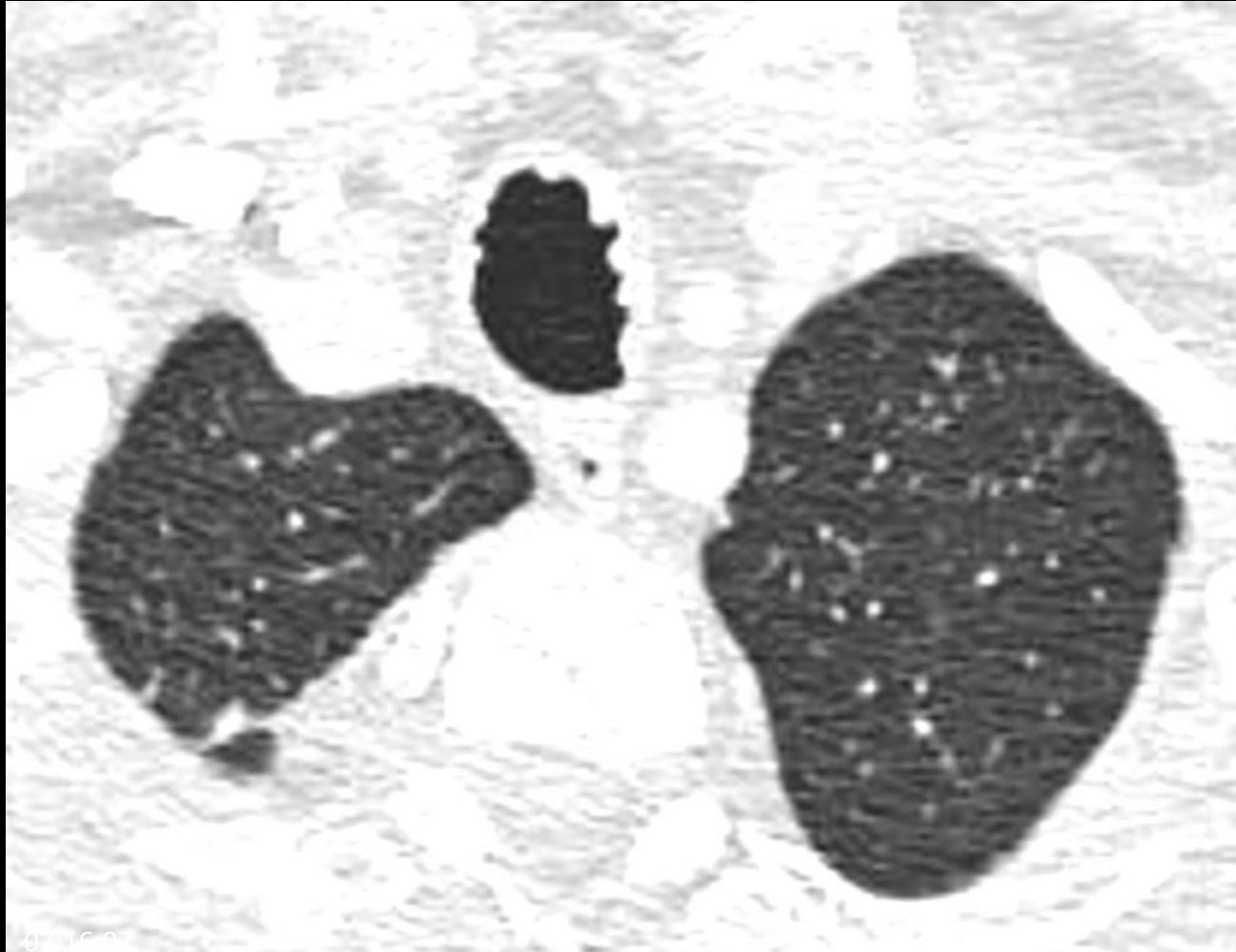
- 38 Y/O male
- Former smoker: 10 pack years
- CxR: irregular narrowing of the trachea and bronchi;
- CT chest: atelectasis of RUL; bronchial wall thickness;
- Coronal CT: narrowing of the lumen; thickness of the wall; **some calcification within the bronchi;**

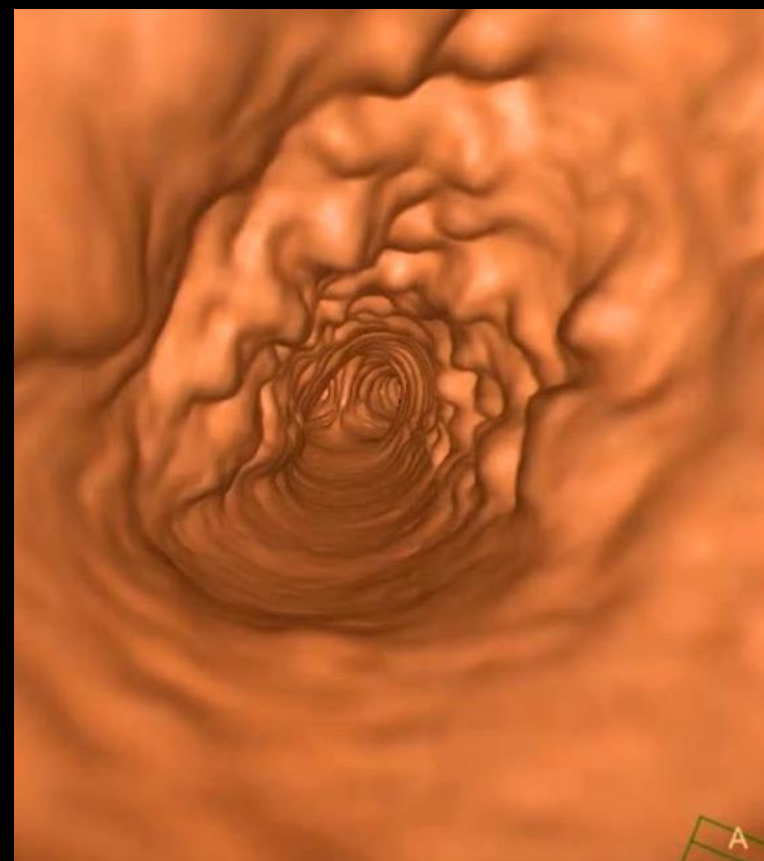
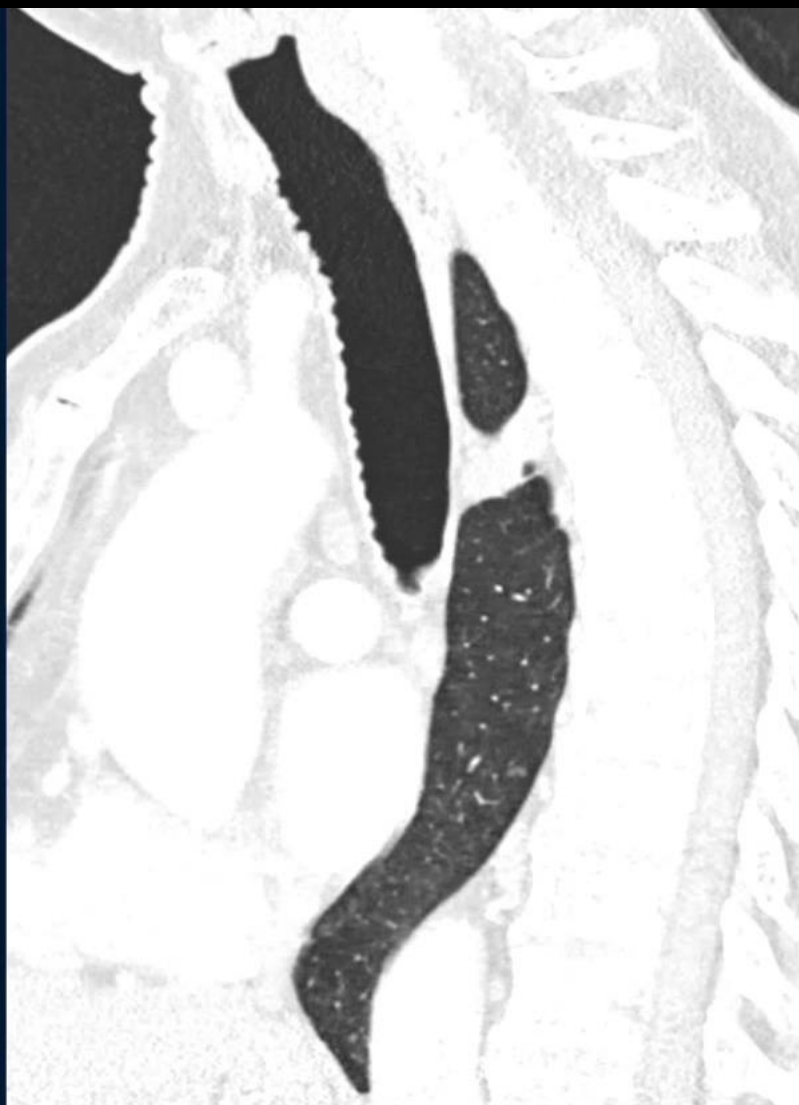
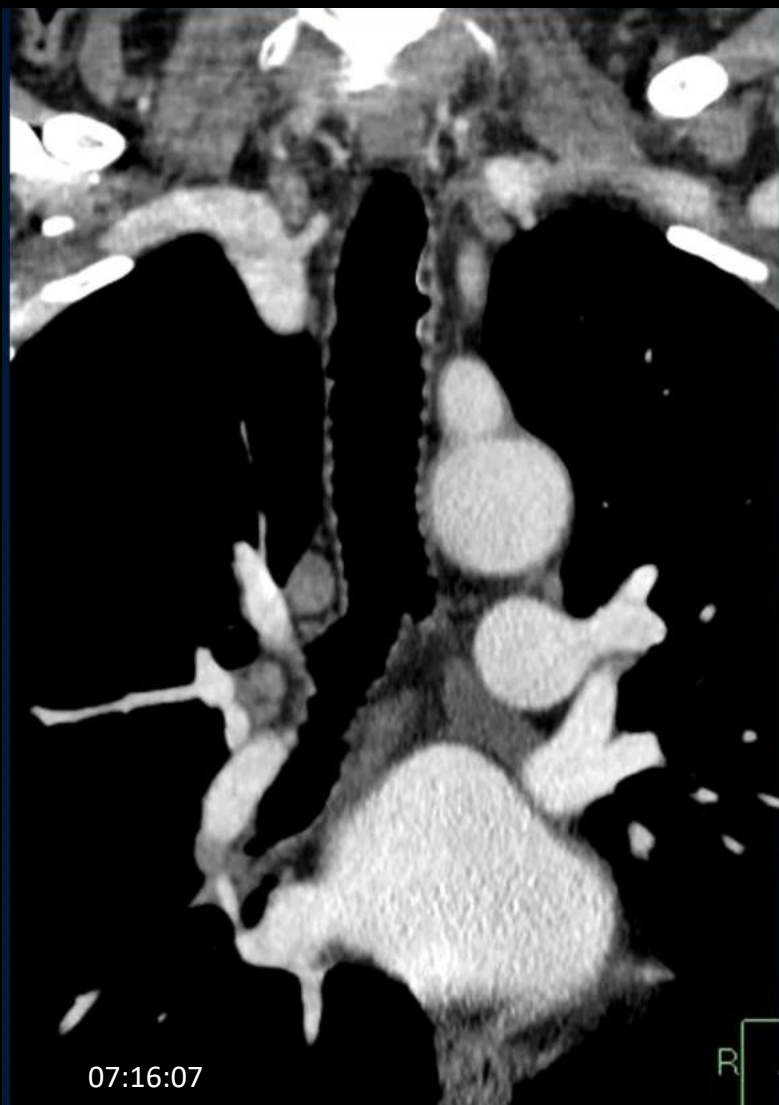

Case: tracheobronchial amyloidosis

- Rare
- Nodular or plaque like lesions caused by **deposition of amyloid protein in the airway wall**
- Circumferential multifocal or diffuse tracheal wall thickening
- Luminal narrowing common
- **Usually calcified or ossified**

Case:



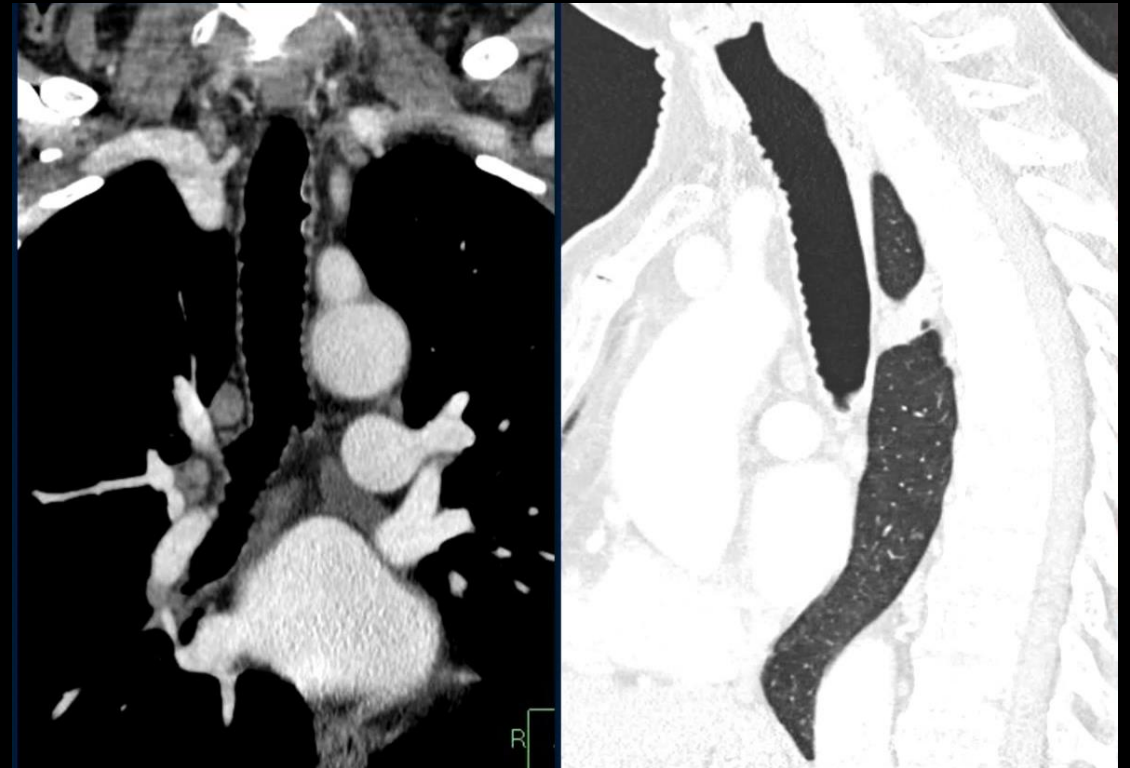


Case: tracheopathia osteocondroplastica

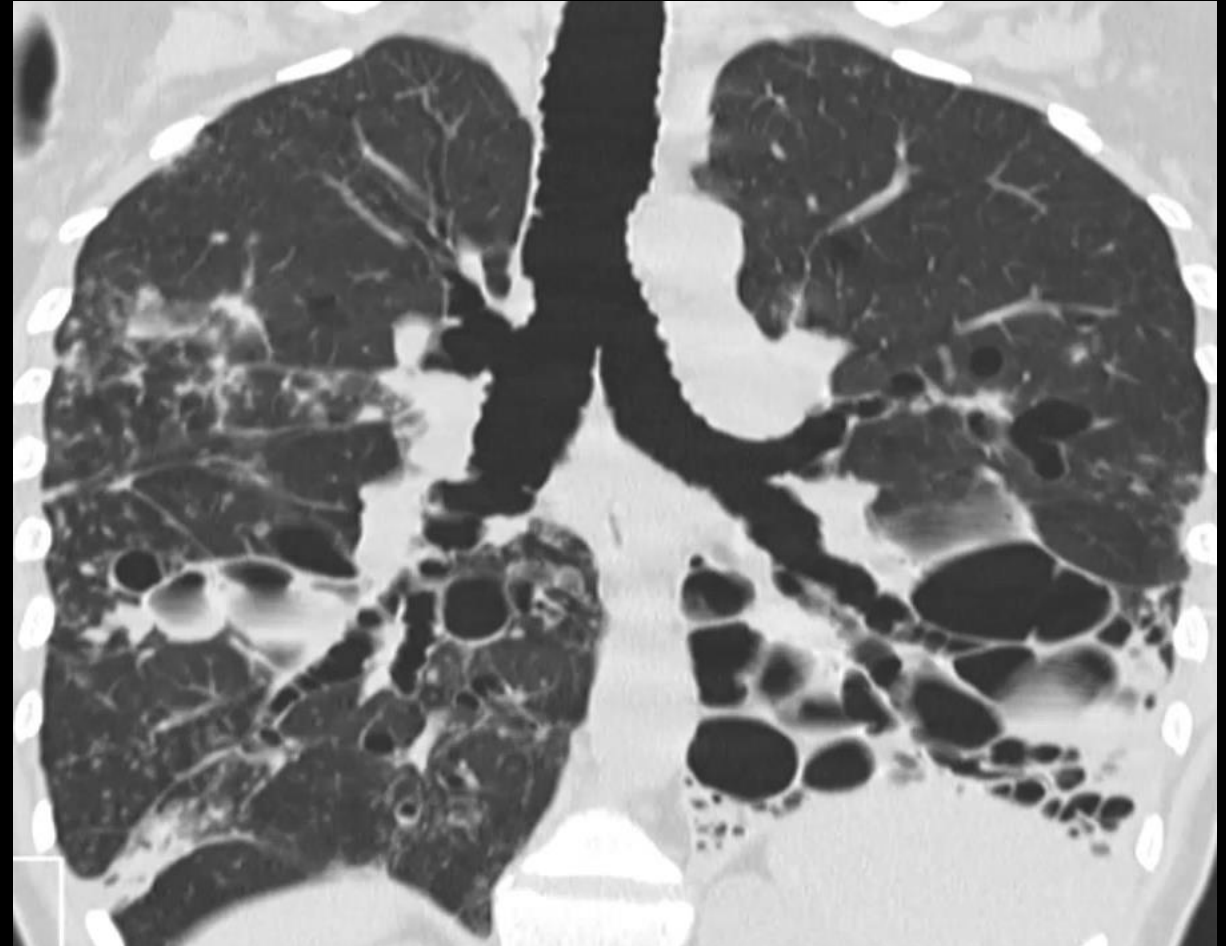
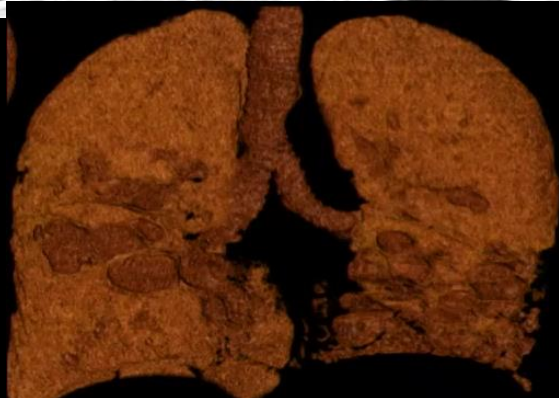
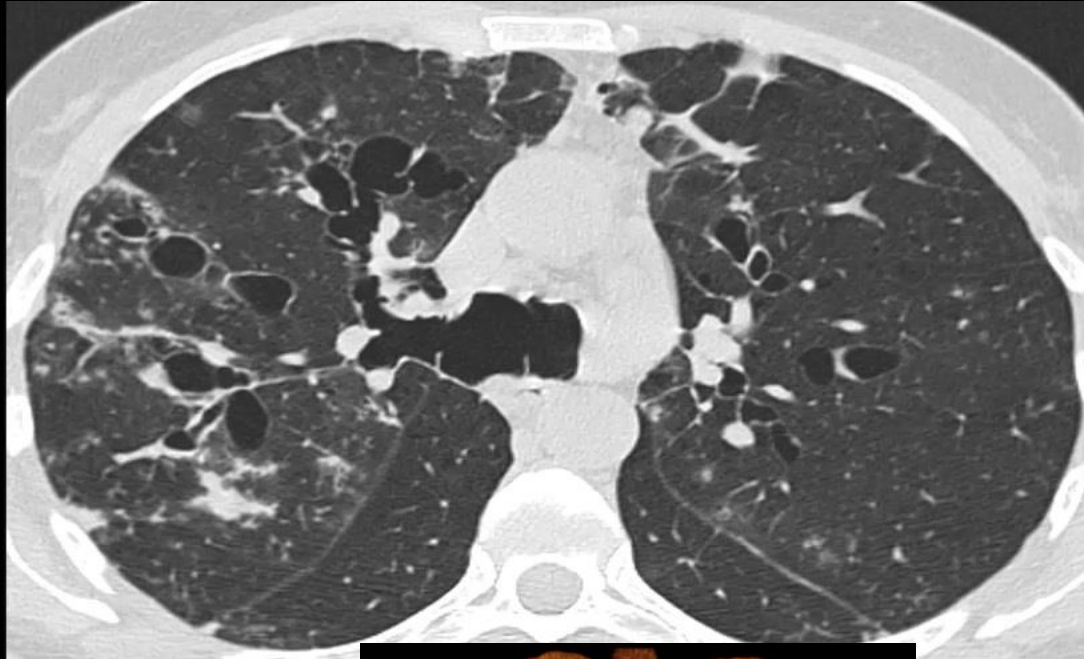
- 62 Y/O male
- S/S: **dyspnea on exertion and cough**
- CT chest: irregular protrusions into the lumen of trachea
- **Some: calcified;**
- **Sparing of the posterior membrane**
- Sagittal CT: to see the irregularity of the anterior wall;
=> but no irregularity in the posterior wall;
- Virtual bronchoscopy: protrusion of the nodules within the lumen of trachea

Case: tracheopathia osteochondroplastica

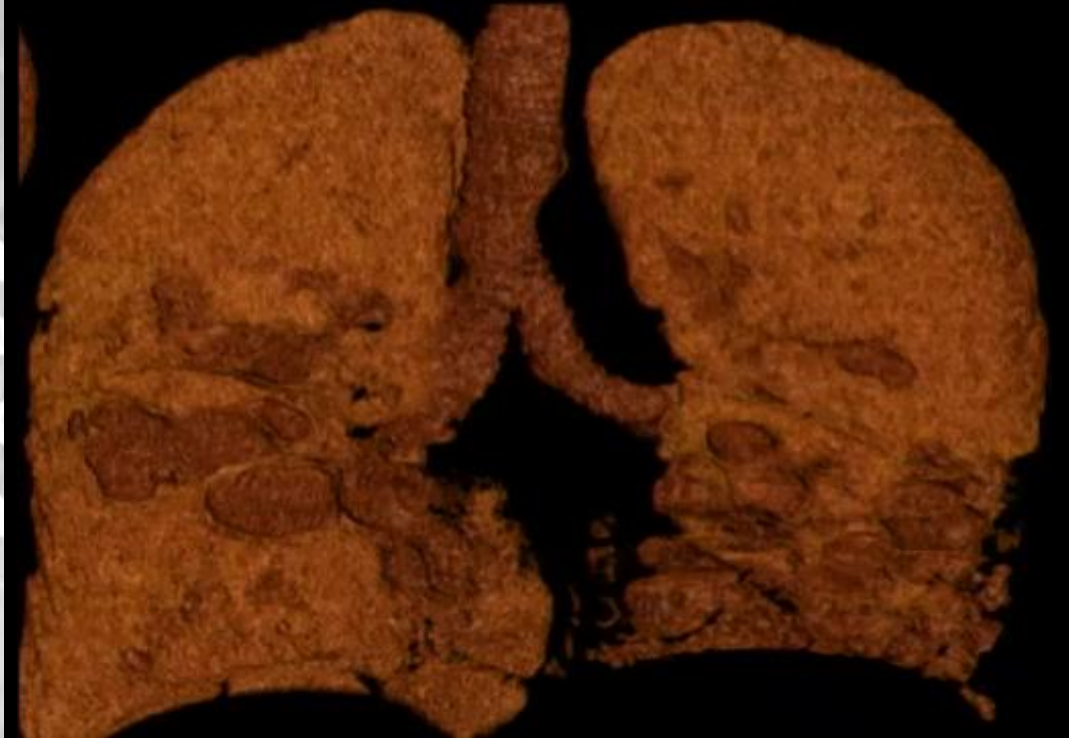
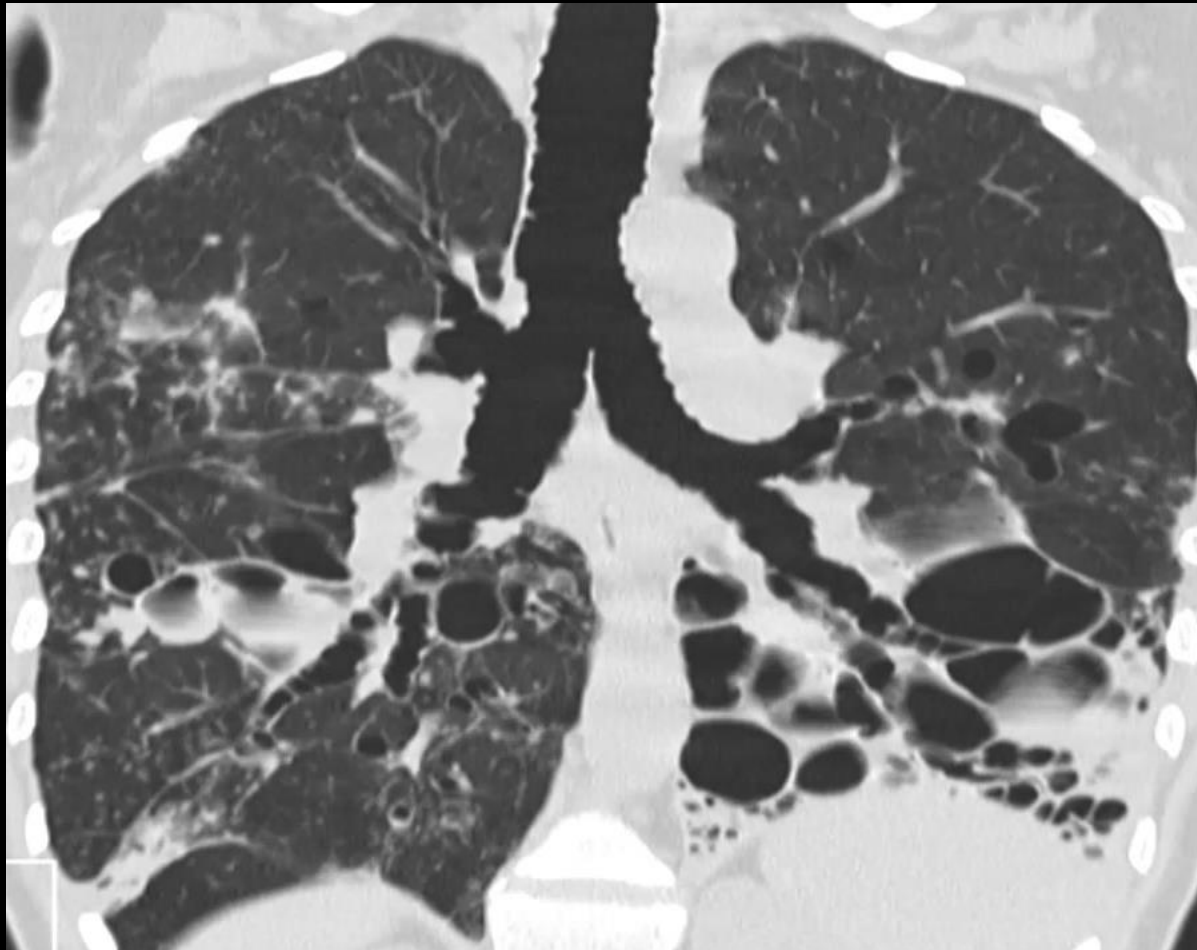- A rare entity
- Slowly progressive disease
- Involves lower half of trachea & main bronchi
- CT shows dense nodules on the anterolateral walls of the trachea, protruding into the lumen
- **Spares the posterior tracheal membrane**
- **Calcification is common**



Case:



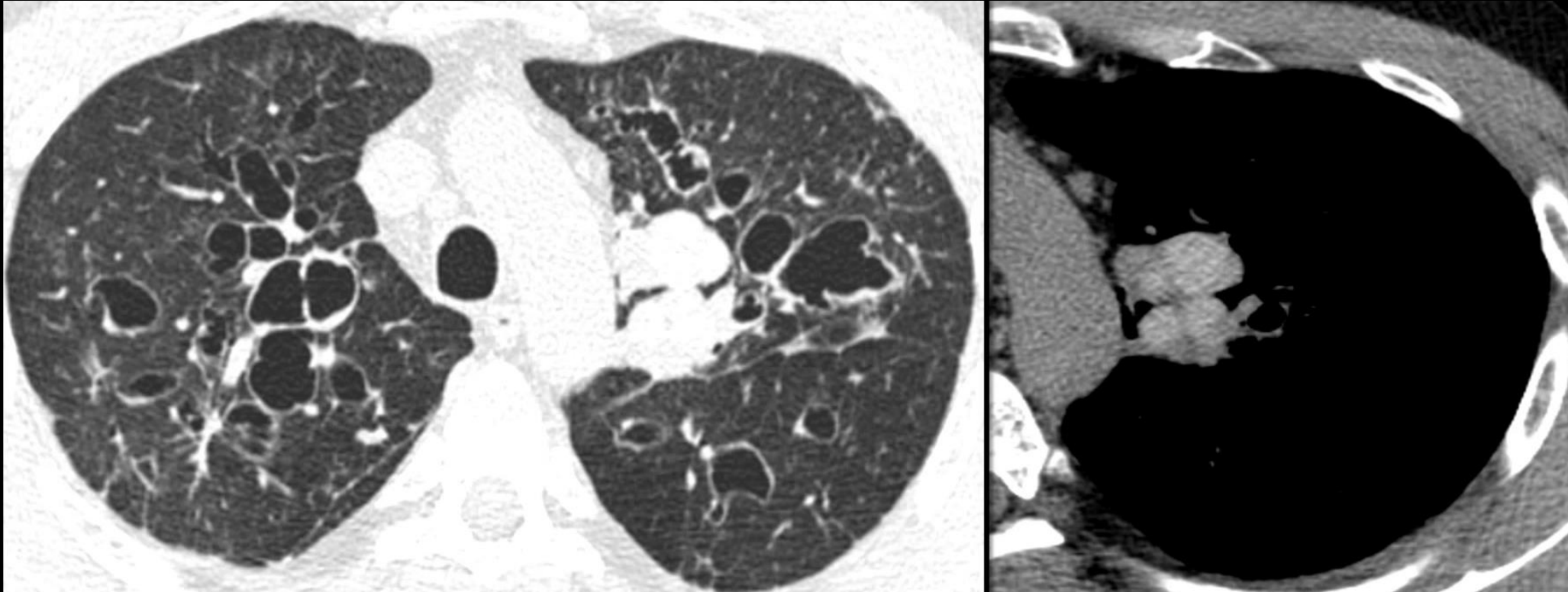
Case: Mounier Kuhn disease



Bronchiectasis

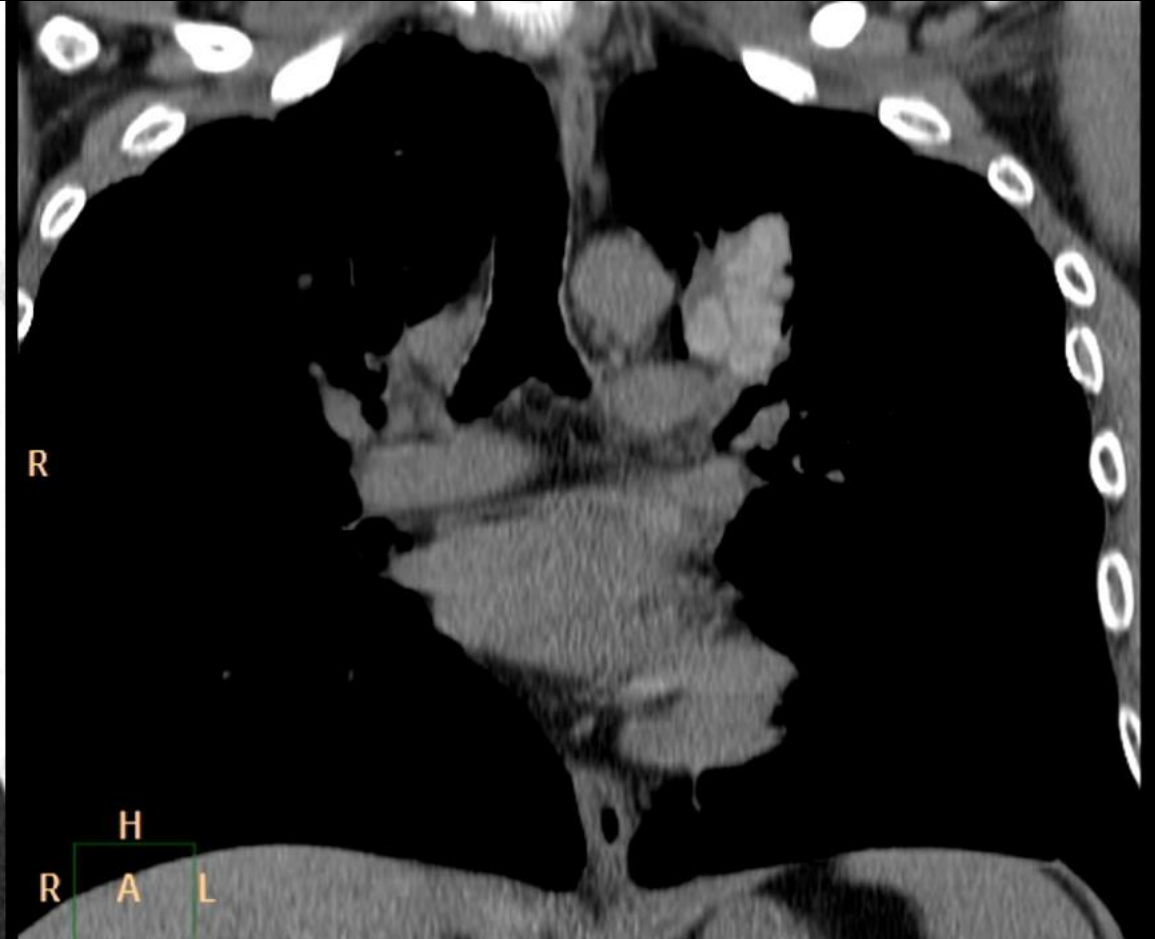
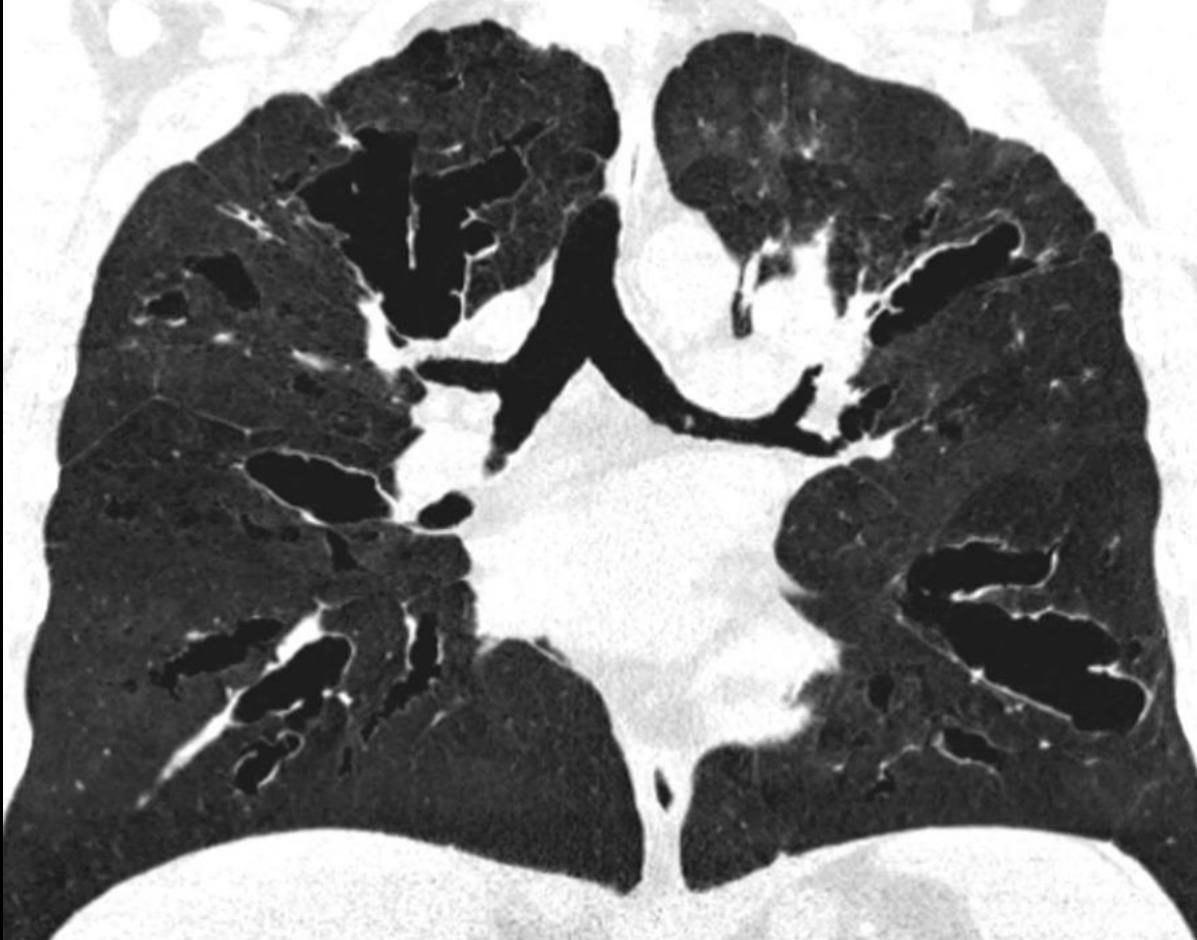
- (1) Congenital
 - = Cystic fibrosis
 - = Primary ciliary dyskinesia
- (2) Acquired
 - = Infection, toxic fume exposure
 - = Recurrent aspiration

Case:

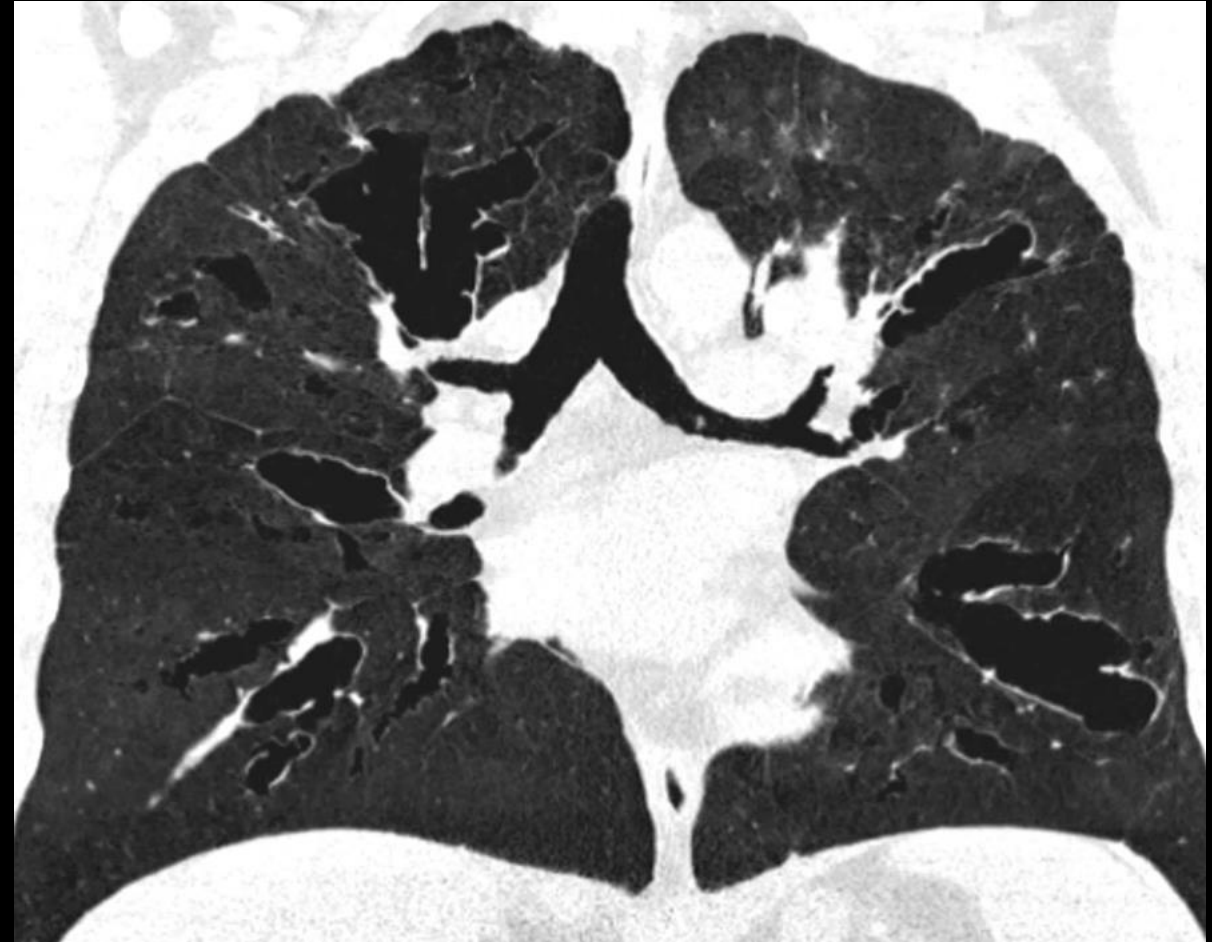


- 54 Y/O Male
- S/S: asymptomatic
- History of asthma

Case:

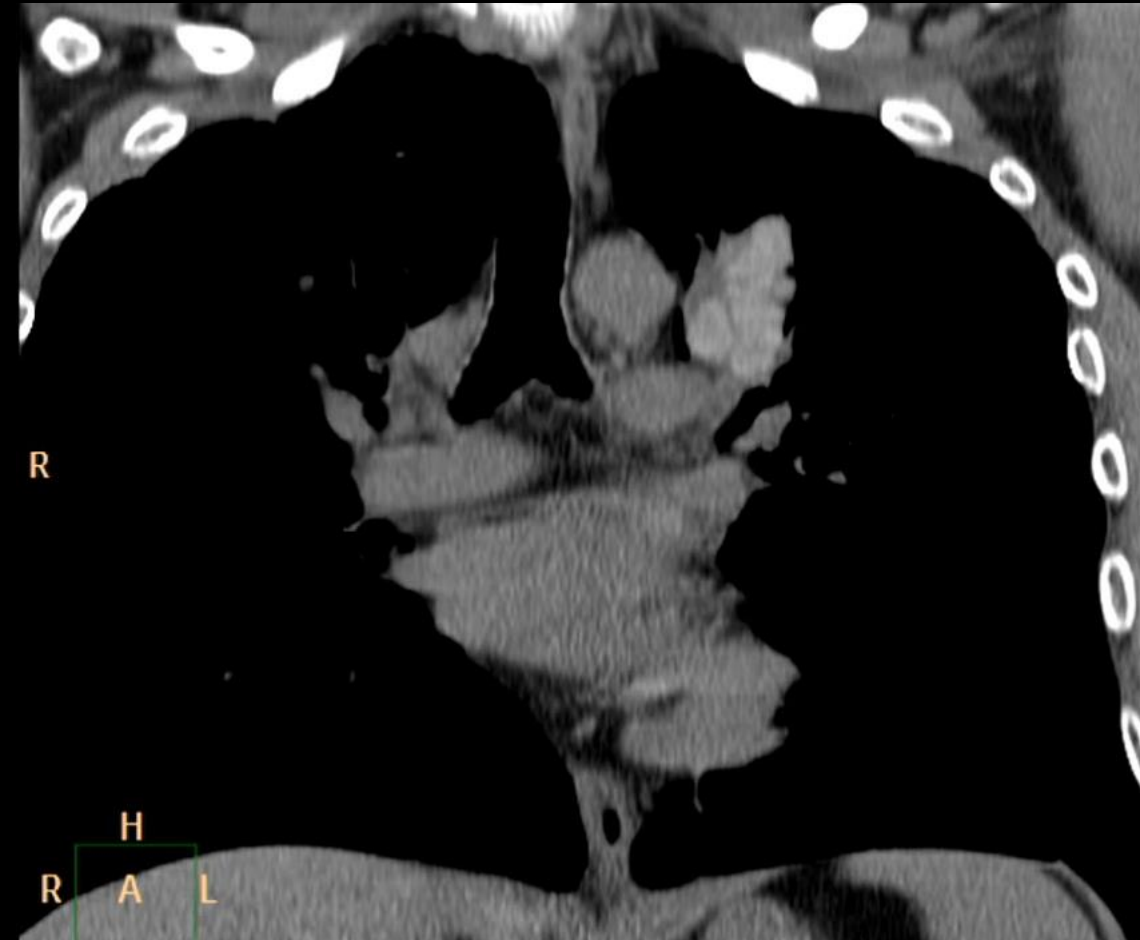


- CT chest: **central bronchiectasis**
- Some nodular opacities:dense
- Fingering lobe
- Mucus impaction: high density
- Asthma + central bronchiectasis + mucus plugging (hyper dense)

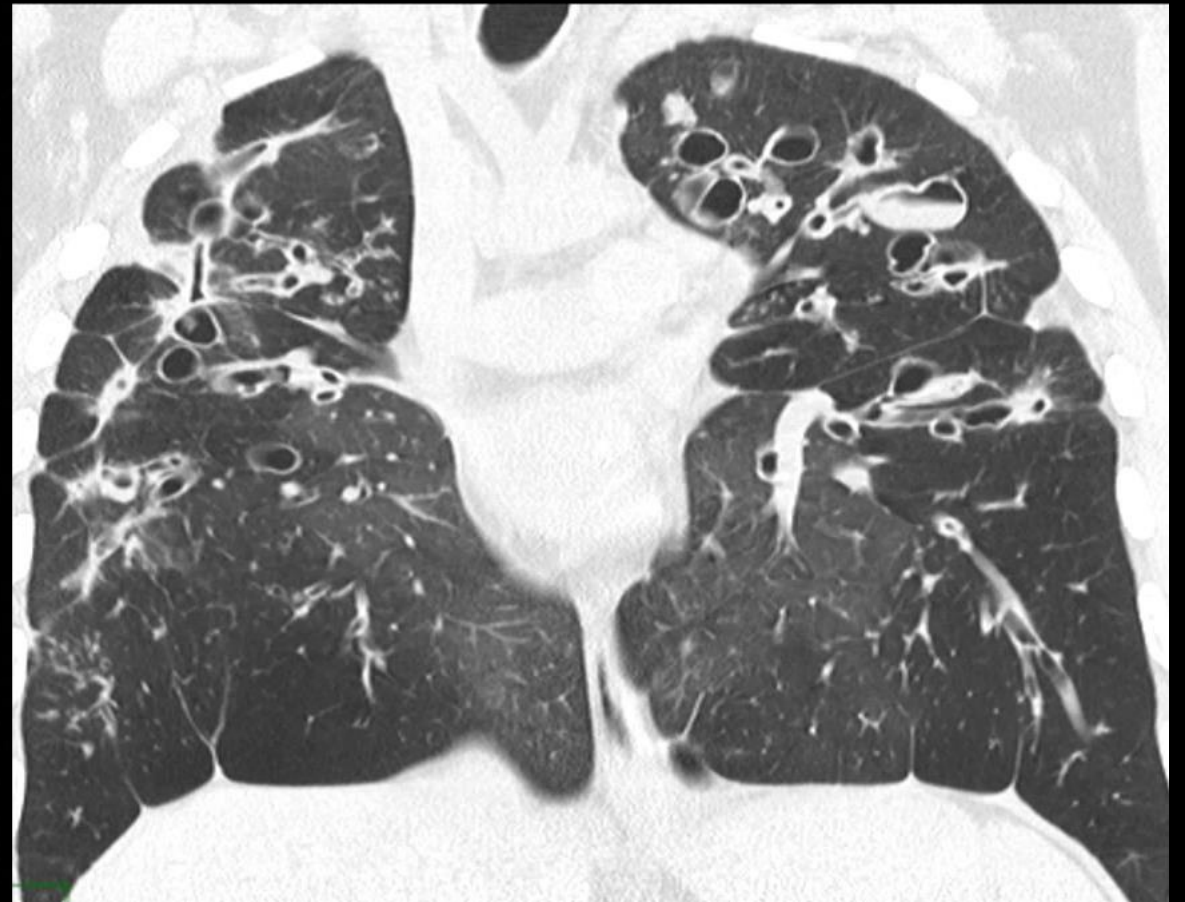
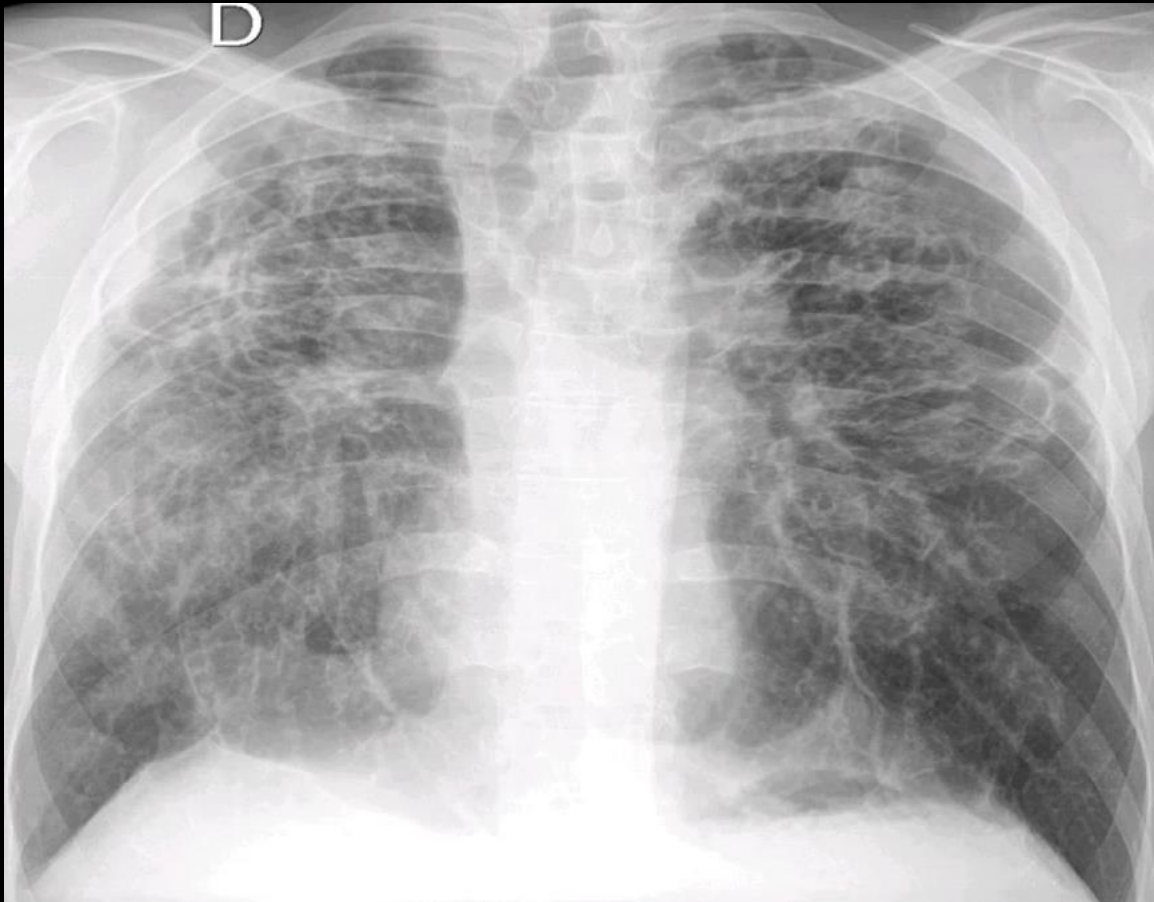


Case: Allergic bronchopulmonary aspergillosis

- Almost exclusively seen in patients with asthma or CF
- Eosinophilia; high IgE
- CT shows central bronchiectasis and mucous impaction
- Mucoid impaction has high attenuation on CT (30%)
(Calcium of the aspergillus; high dense mucus impaction)



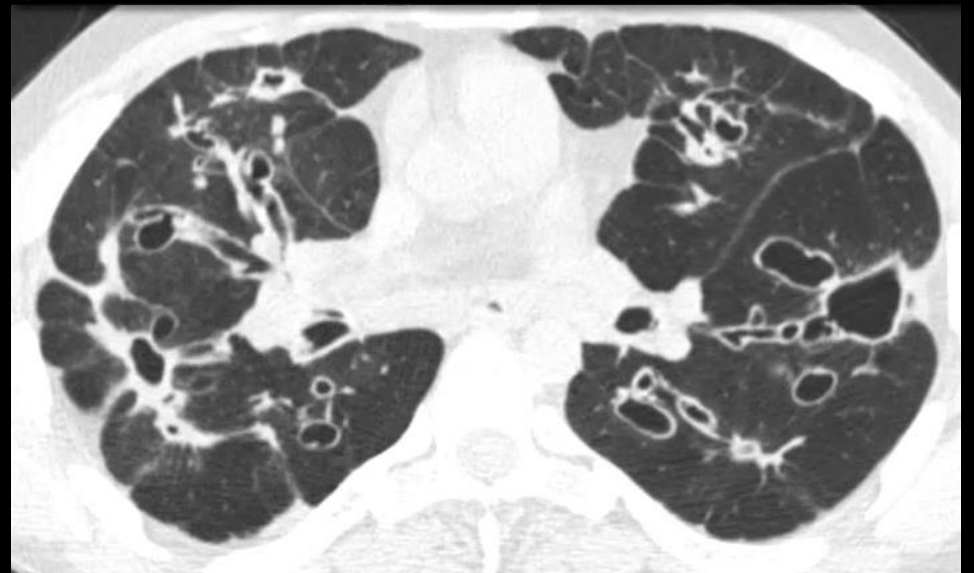
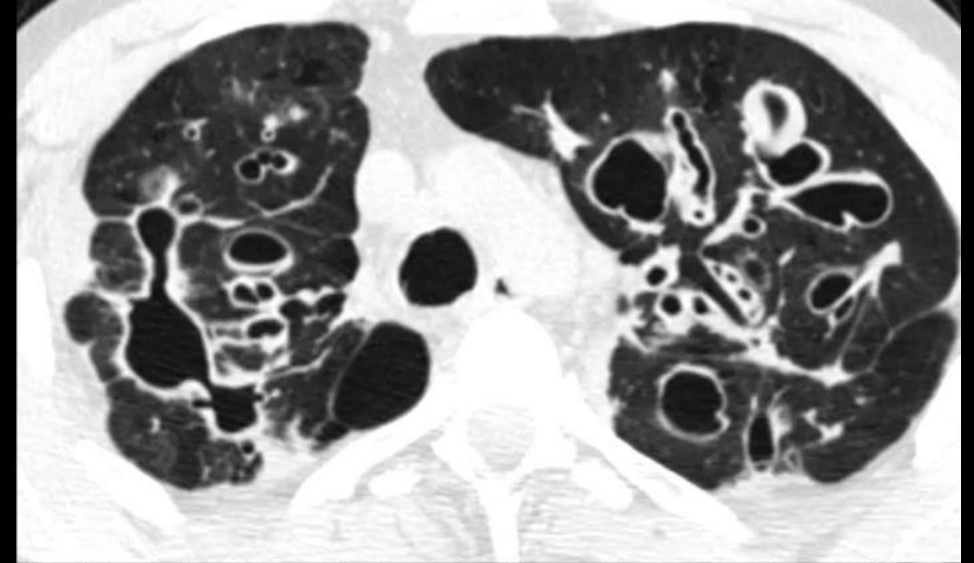
Case:



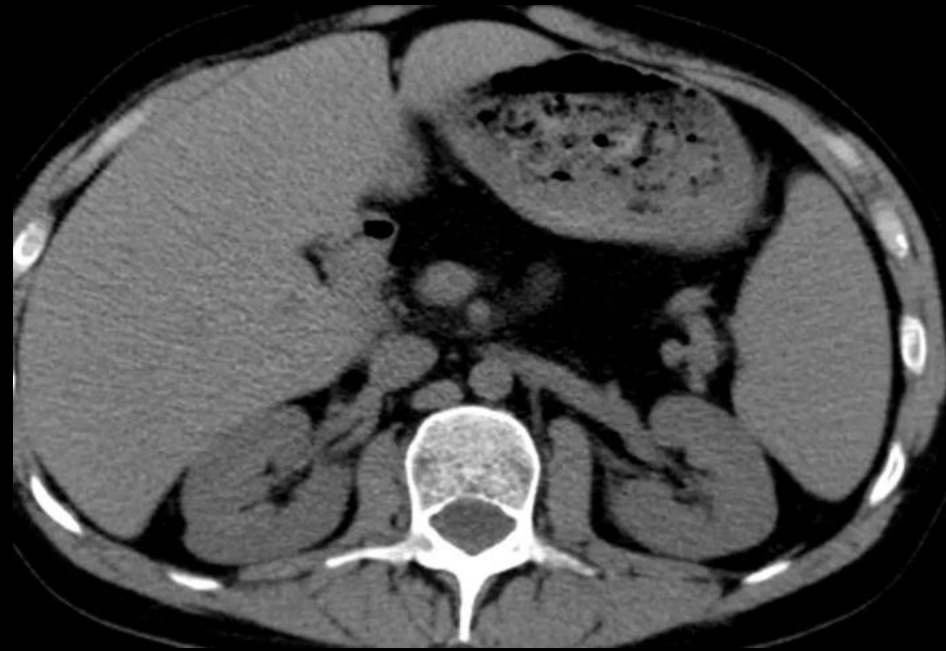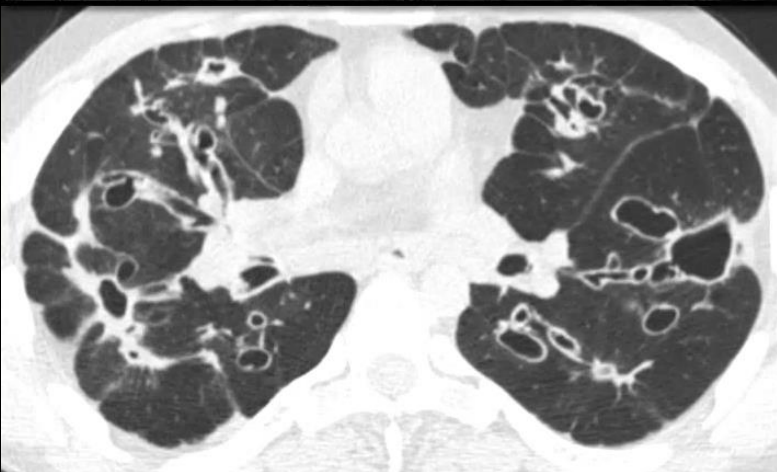
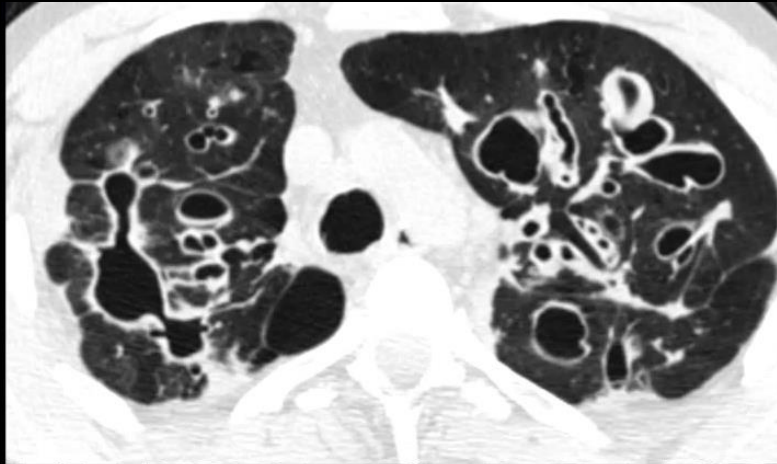
33 Y/O Female; cough; Dyspnea

Case: cystic fibrosis

- CxR and CT chest: traction bronchiectasis
- Some bronchial thickening
- Mainly in the upper lungs
- Some areas of air trapping



CT chest : Atrophy of pancreas



Cystic fibrosis

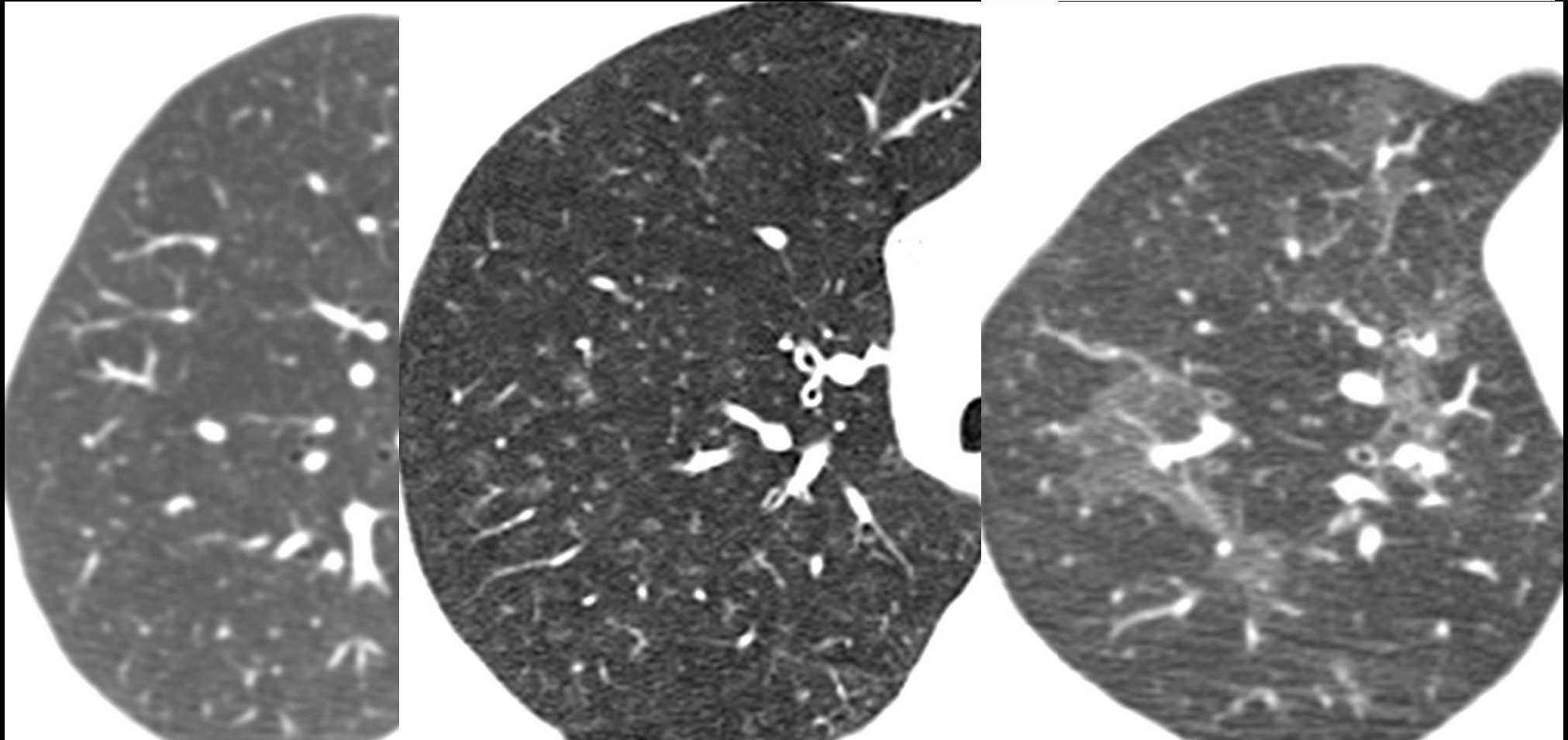
- Diagnosis is made before age 6 years in about 80% of patients
- Recurrent respiratory infections associated with productive cough, wheezing and dyspnea
- Bronchiectasis
- Bronchial wall thickening, mucus plugging, tree in bud pattern, mosaic attenuation and air trapping on expiratory CT

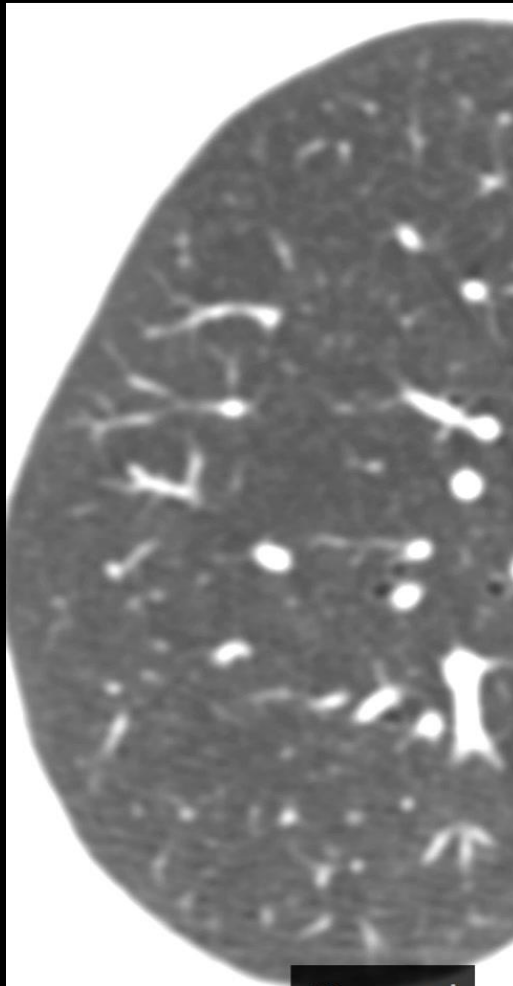
(2) Large airways disease : Summary

- **MDCT** is the preferred non-invasive tool for imaging large airways
- **Expiratory CT** can be helpful in evaluation of tracheal collapsibility

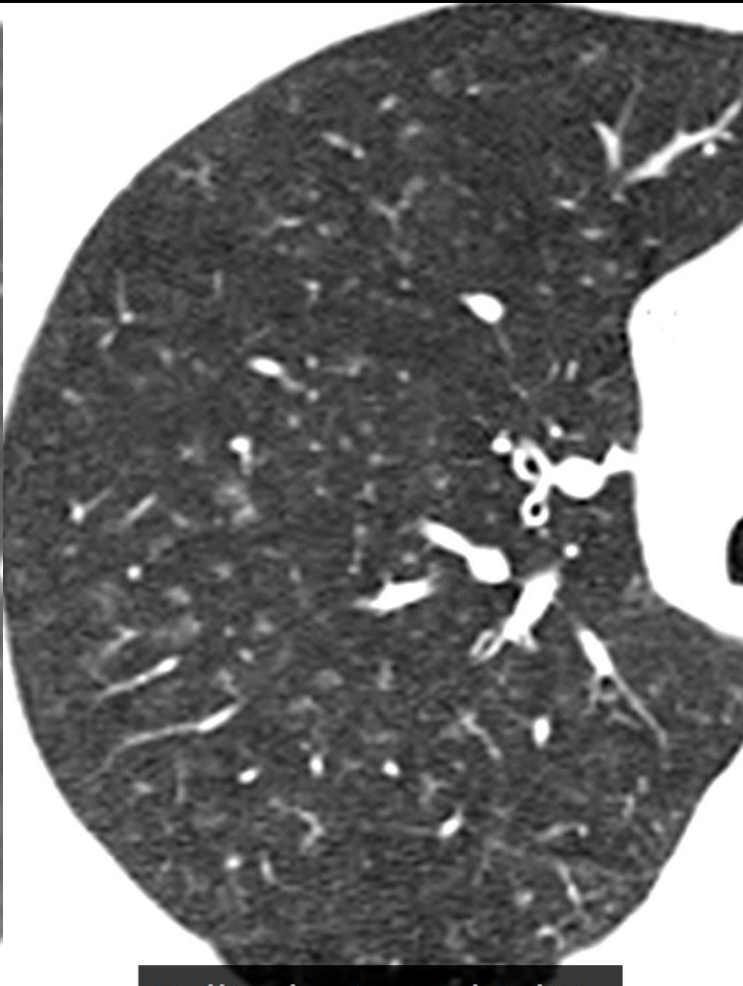
(3) Small Airways Disease

- Small airways?
- Noncartilagenous
- < 2 mm in diameter
- All airways below the resolution of HRCT in the normal state (ERJ 2001, David Hansell, British radiologist)
- Small airways disease = Bronchiolitis

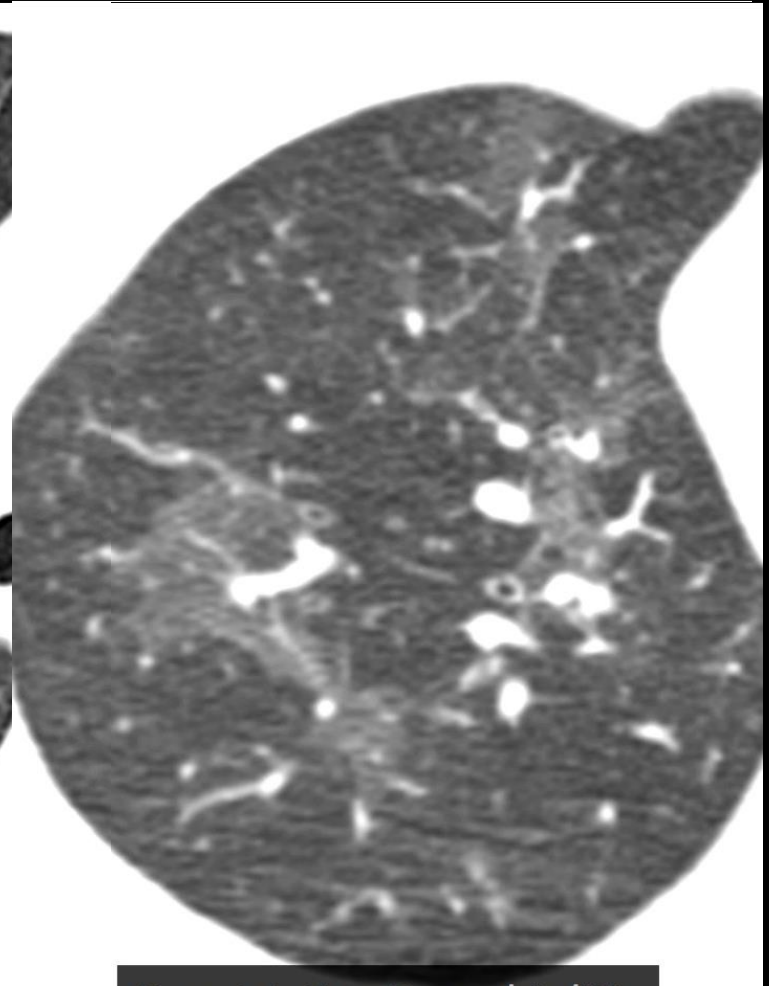




Normal



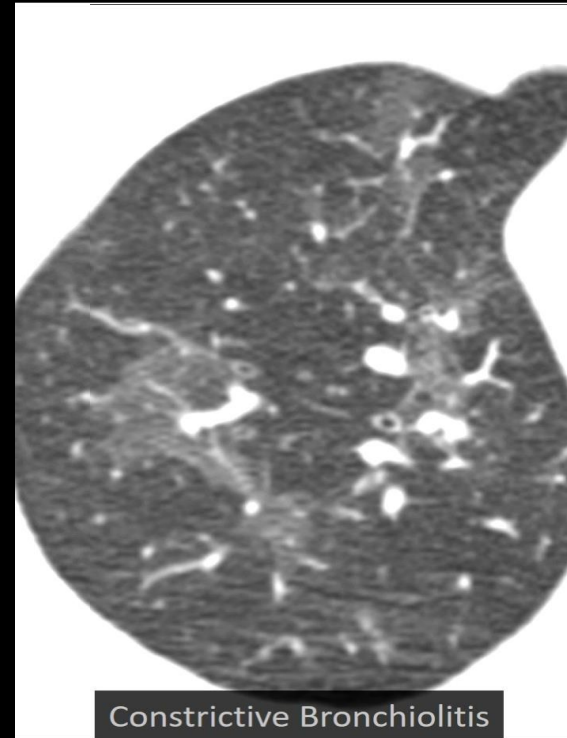
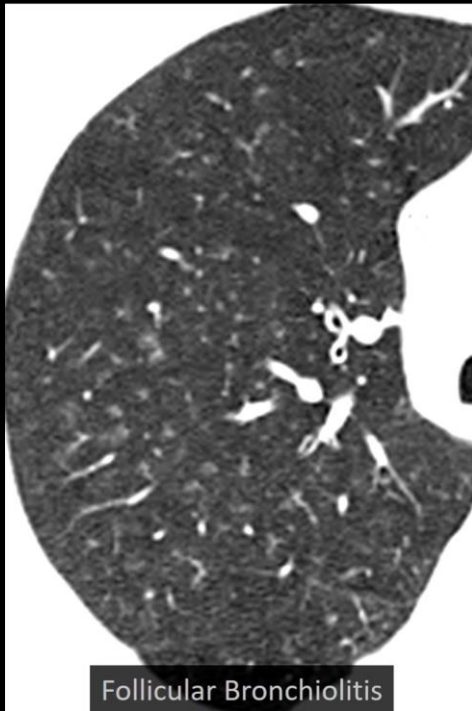
Follicular Bronchiolitis



Constrictive Bronchiolitis

Two Ways to See Small Airways!

- (1) **Centrilobular Nodules**: example: follicular bronchiolitis
- (2) **Air trapping**: example: constrictive bronchiolitis



Small airways disease: Different classifications

(1) Clinical :

- Proven or presumed etiology
- Systemic conditions

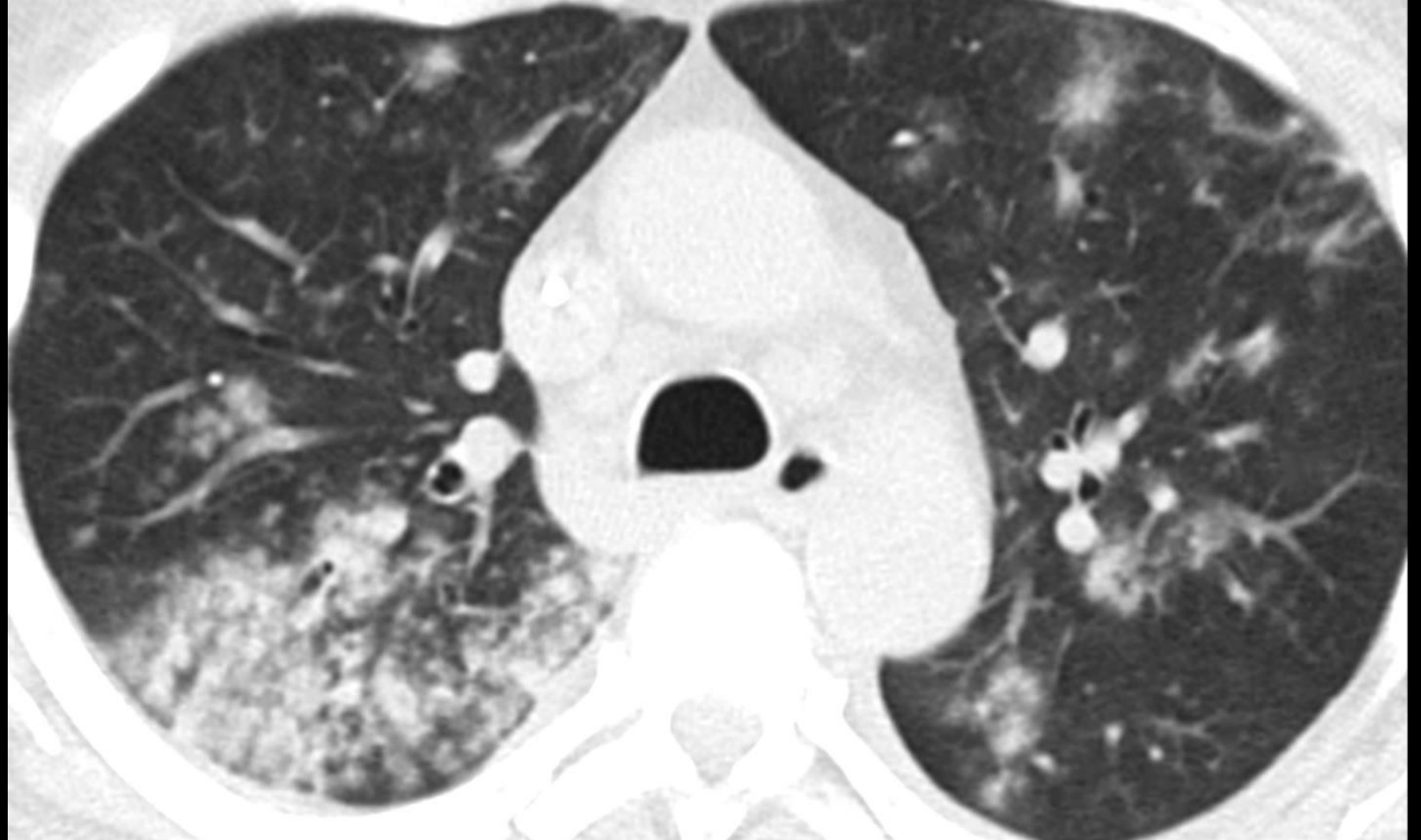
(2) Histologic: (Histopathologic diagnosis)

- **Cellular (proliferative)**
- **Constrictive (fibrotic; obliterated bronchiolitis)**

CT findings often correlate with histology

Case

- 62 Y/O; male
- Hx of stem cell transplantation
- S/S: fever



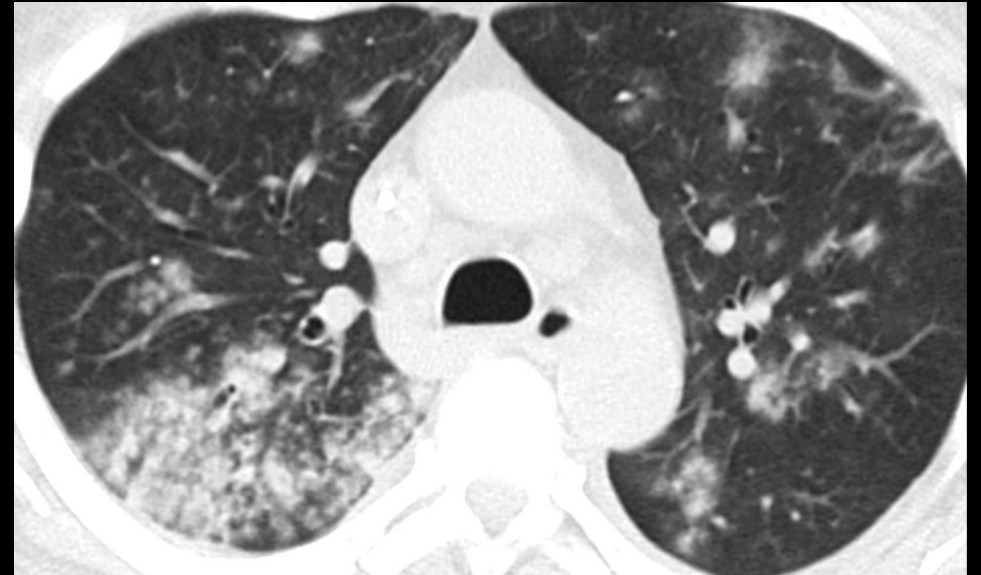
CT chest: areas of consolidation

- Clues for differential diagnosis

-> **look for less severe areas!** (less affected area often a big clue to what is actually going on!)

- **Infection clues:**

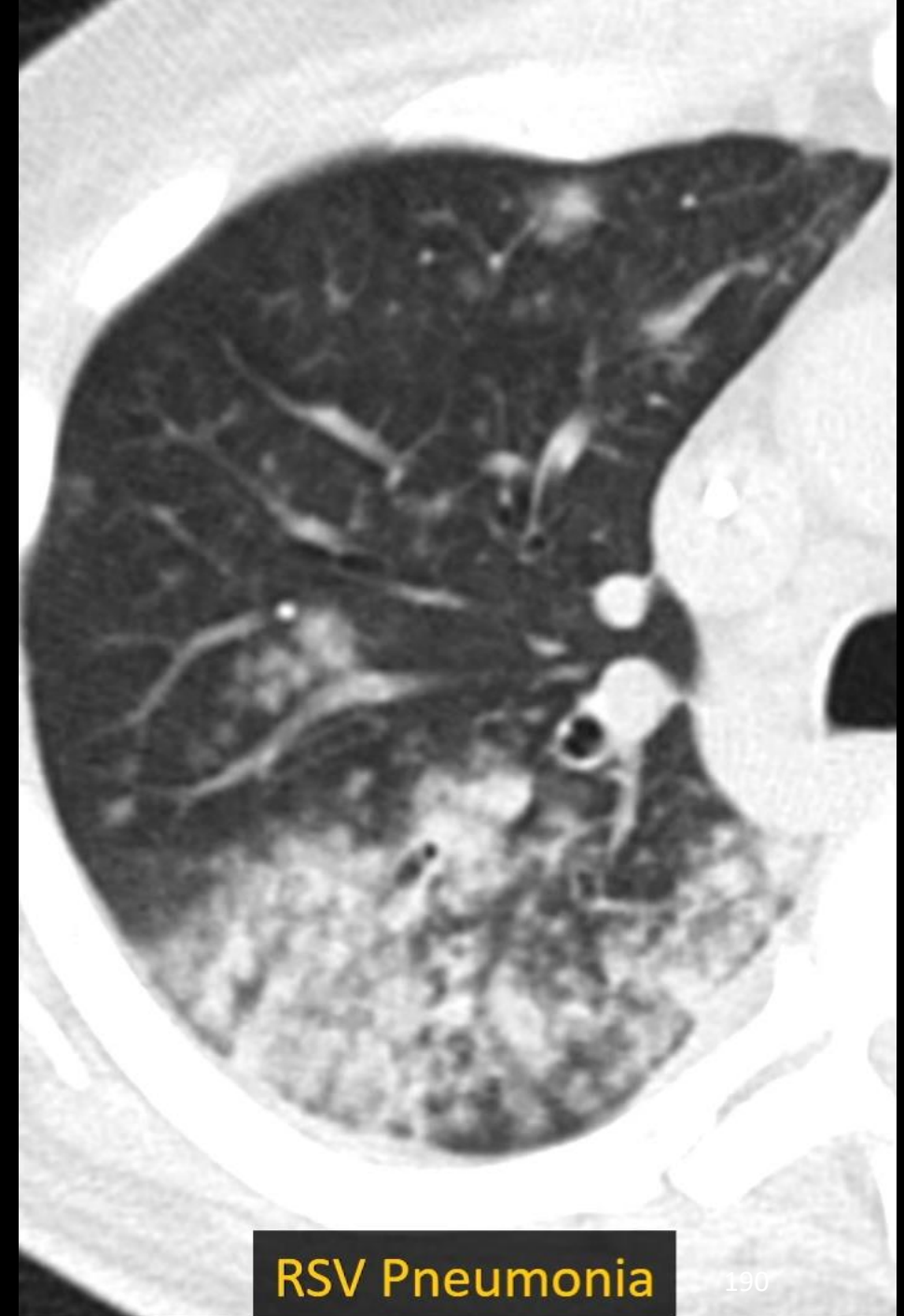
- => clustered centrilobular nodules;
- => Sparing pleural surface;
- => vary patchy opacity and asymmetric (not a uniform process);



Case:

Infectious bronchiolitis

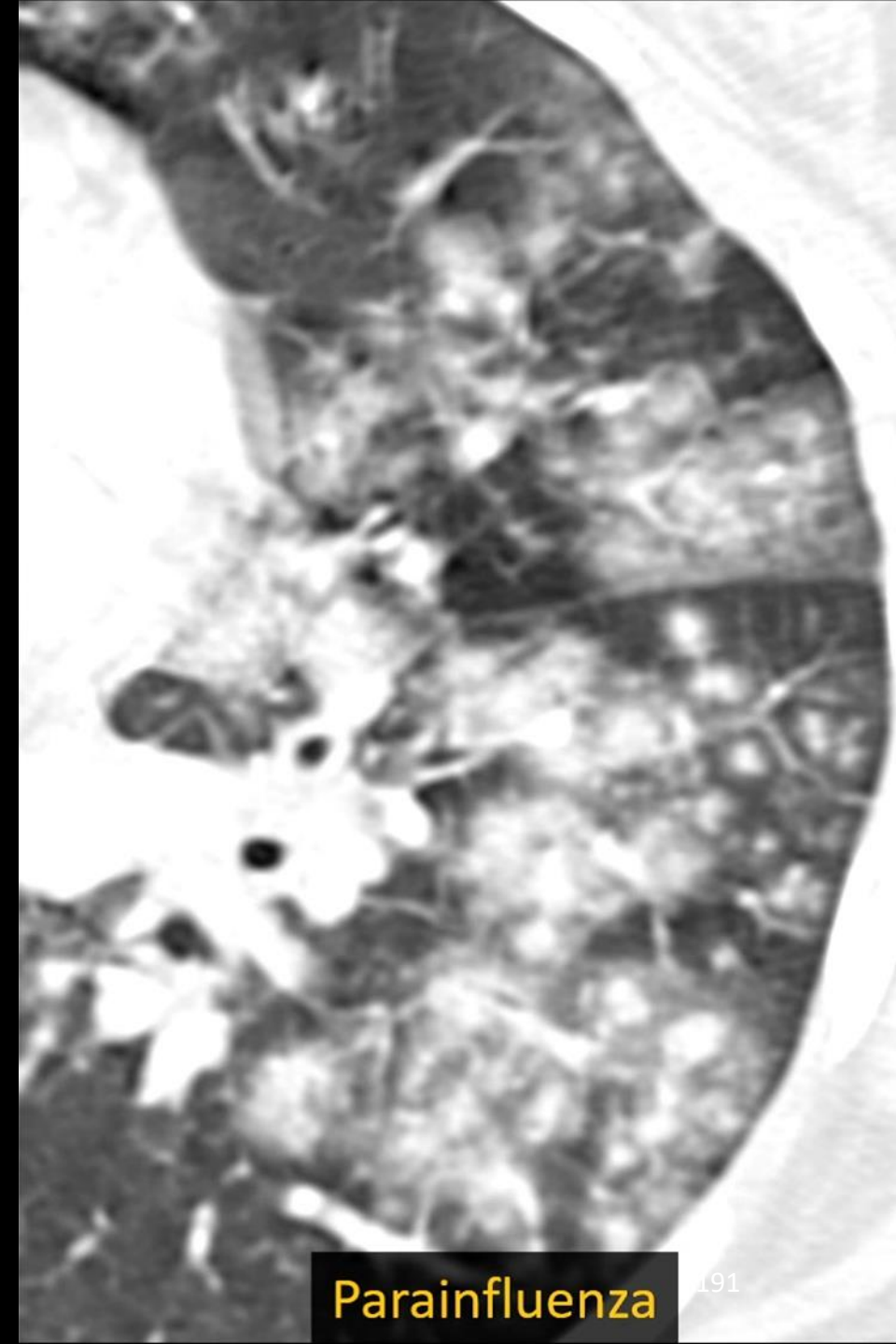
- Many pathogens (viral, bacterial, fungal)
- **Clues**
- => Nodules of varying sizes
- => Consolidation
- => Clustered/asymmetric



RSV Pneumonia

Case: Parainfluenza

- CT chest:
- **First step** -> **look for less affected area**
- -> find small **centrilobular nodules** (the heart of this process is at the center of secondary pulmonary nodules in the small airways)
- **Second step** -> find more coalescent areas of ground-glass consolidation; patchy opacity;

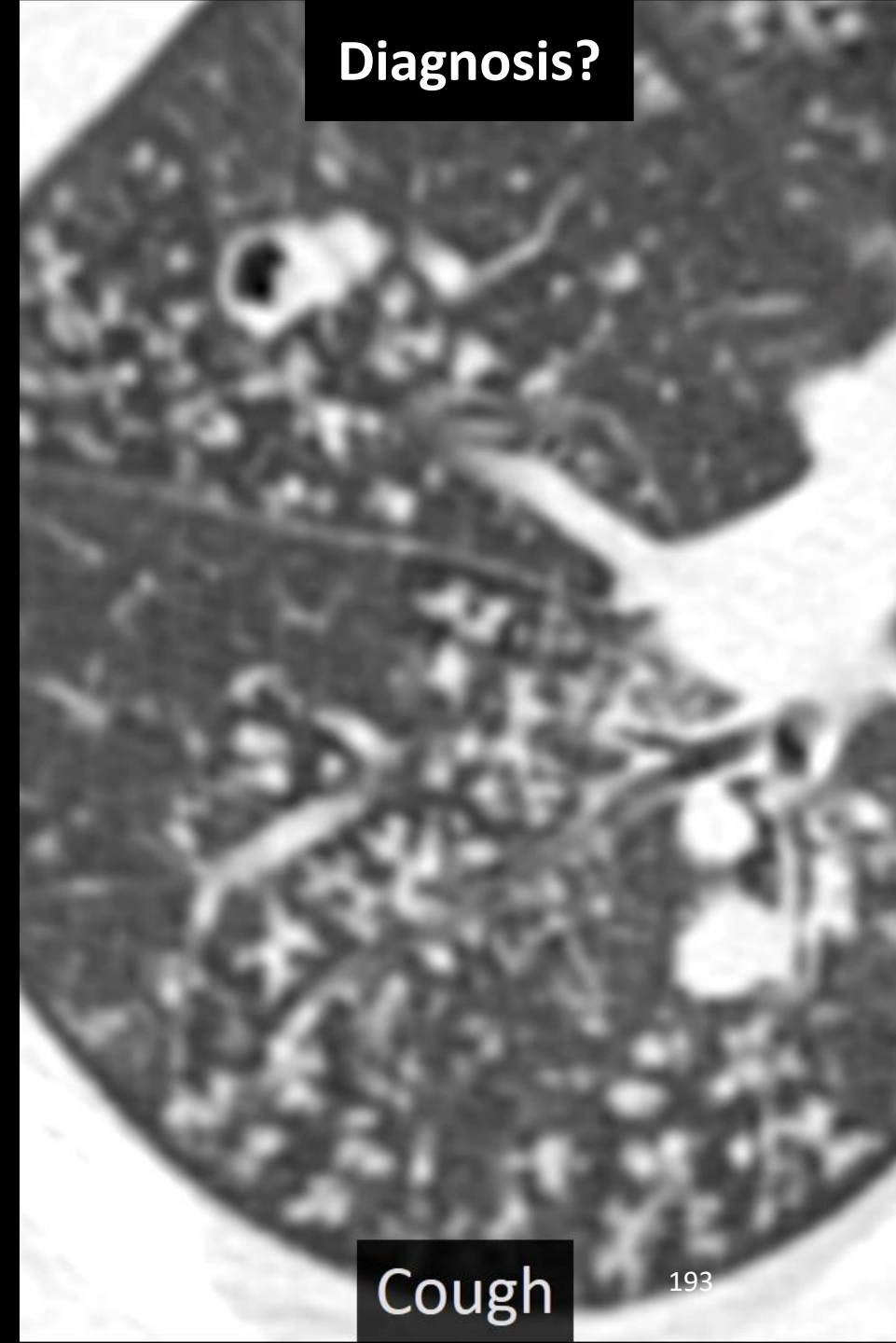


CT chest

- Book: differential diagnosis: different kinds of viral pneumonia
- Unfortunately, it is often not helpful!
- Infectious bronchiolitis ? Yes -> need further investigations!

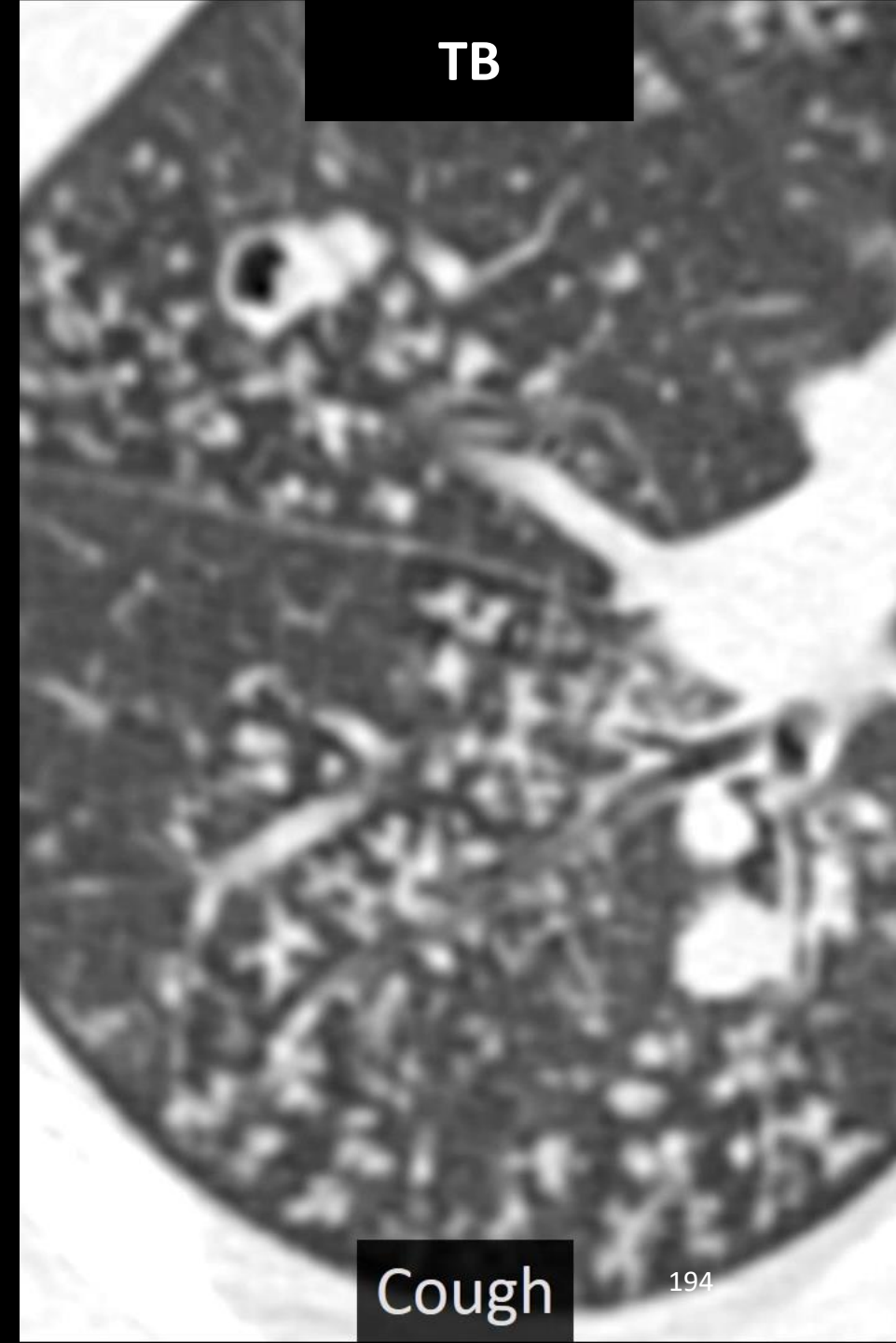
Diagnosis?

- Case: cough
- CT chest: what is ***the best first step*** in the management of this patient?



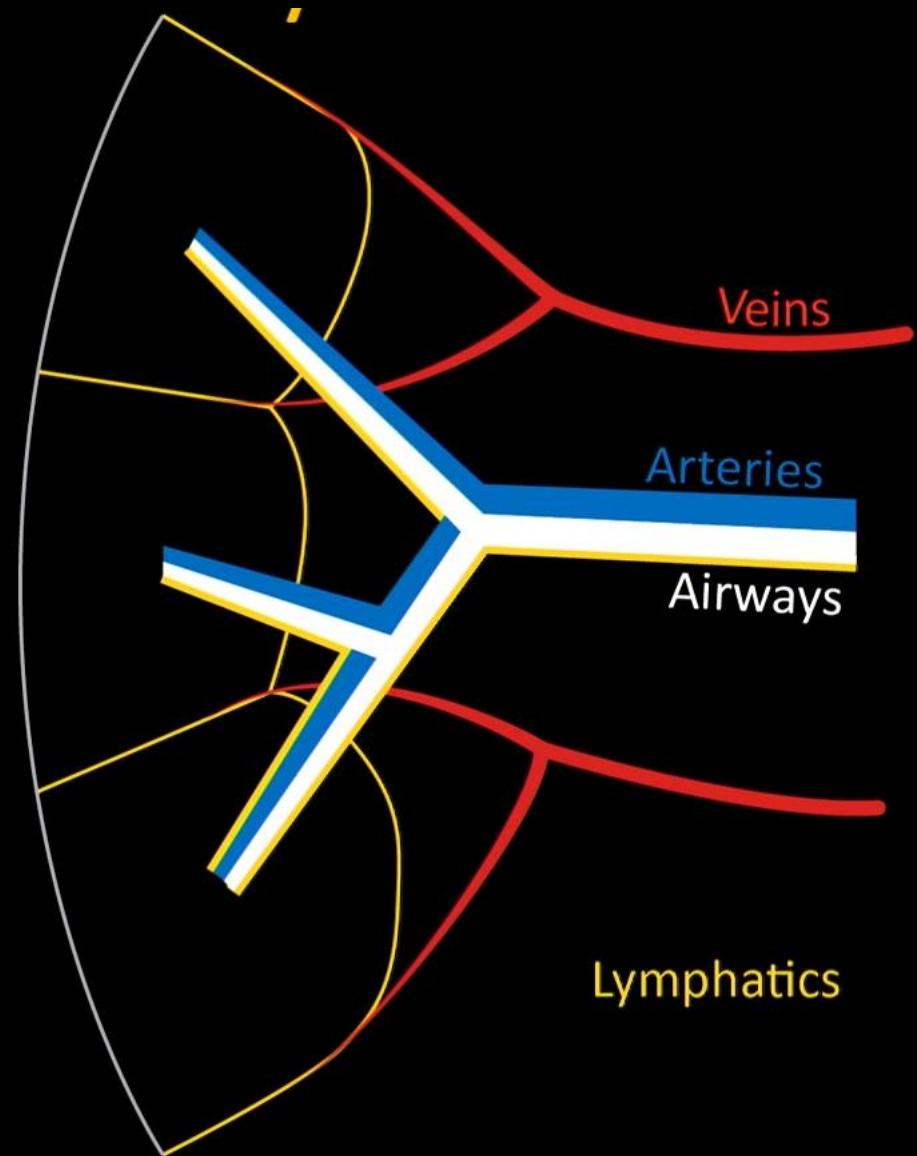
Case: Tuberculosis

- Case: cough
- CT chest: what is the best first step in the management of this patient?
- **Answer: “respiratory isolation first!”**
- CT chest:
- (1) Central lobular nodules; with Tree-in-bud; spare the pleural surface
- (2) A cavity (Cavitation)
 - 20-45% on CxR
 - Posterior upper lobes/superior segment of lower lobes



Secondary Pulmonary Lobule

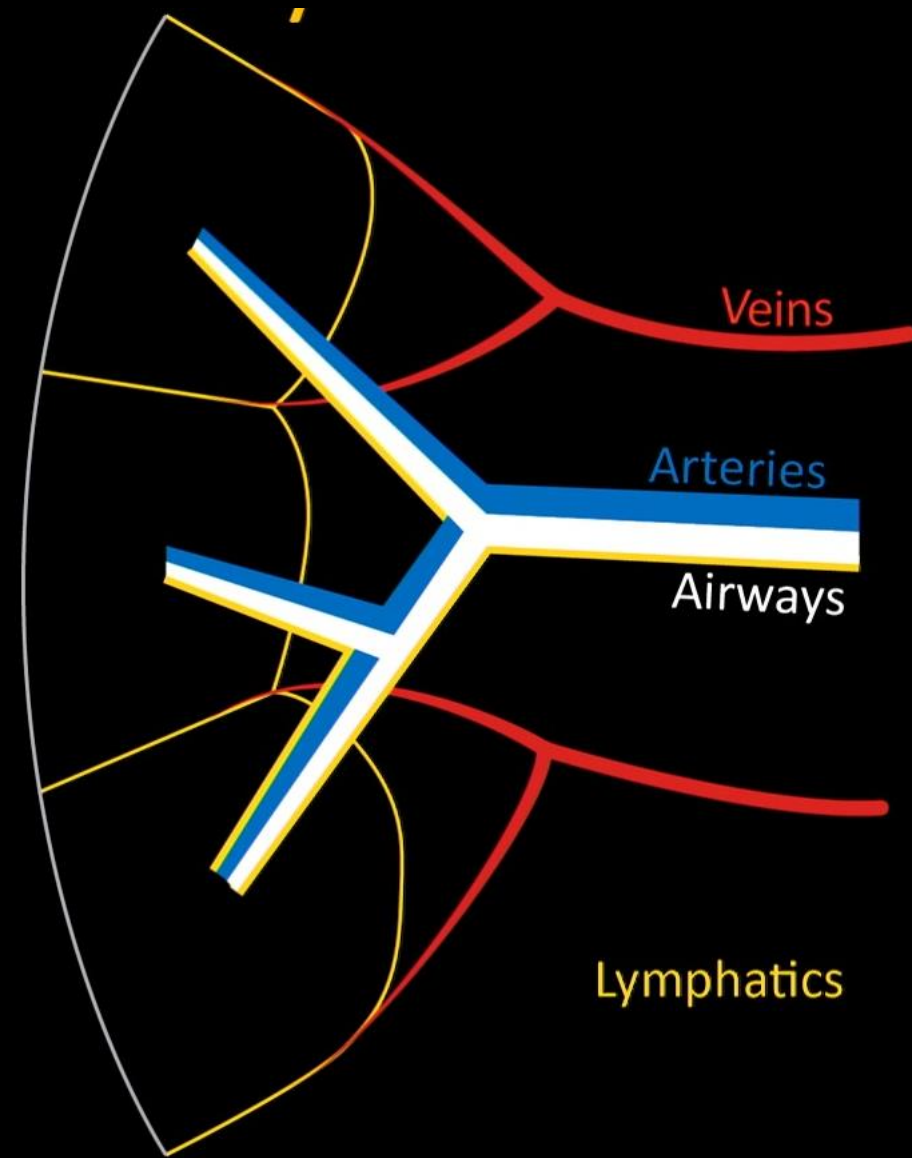
- Smallest unit of lung marginated by connective tissue
- 1.0-2.5 cm in diameter
- Fundamental unit of lung structure



Webb WR. Thin-section CT of the secondary pulmonary lobule: anatomy and the image--the 2004 Fleischner lecture. *Radiology* 2006; 239:322-338⁴⁹⁵

Secondary Pulmonary Lobule

- Polygons;
- Central:
=> arteries, airways, and lymphatics;
- Interlobular septa:
=> the veins and lymphatics
- Lymphatics: both in the interlobular septa and at the center



Do they touch the pleura?

Three Patterns of nodules:

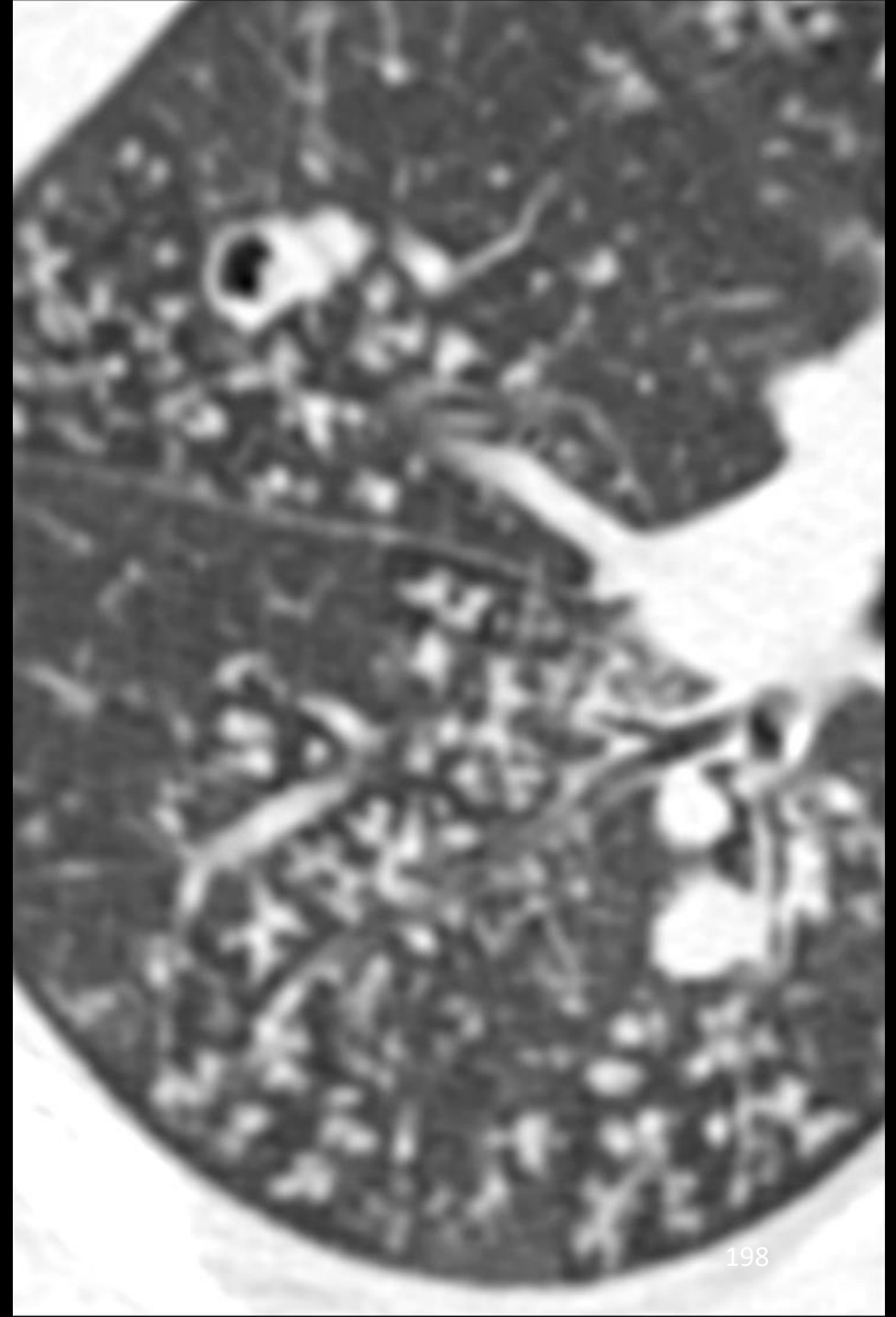
- (1) **Centrilobular**: spare pleural surfaces
- (2) **Random**: Both touch the pleura
- (3) **Perilymphatic**: Both touch the pleura

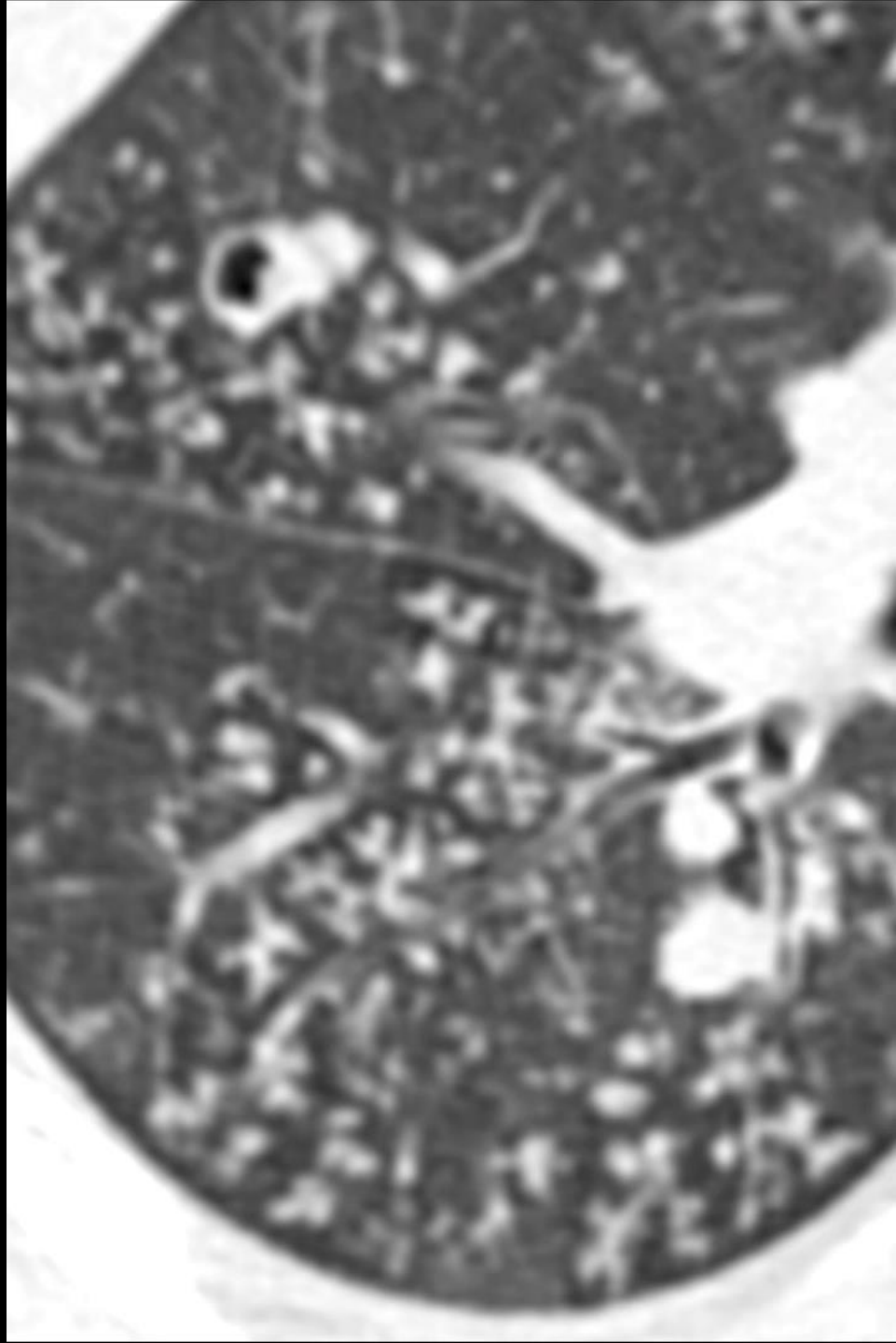
The most important question (the key): **Do they touch the pleura?**

- ⇒ No! -> centrilobular nodules -> small airway diseases!
- ⇒ Yes! -> Random or perilymphatic nodules!

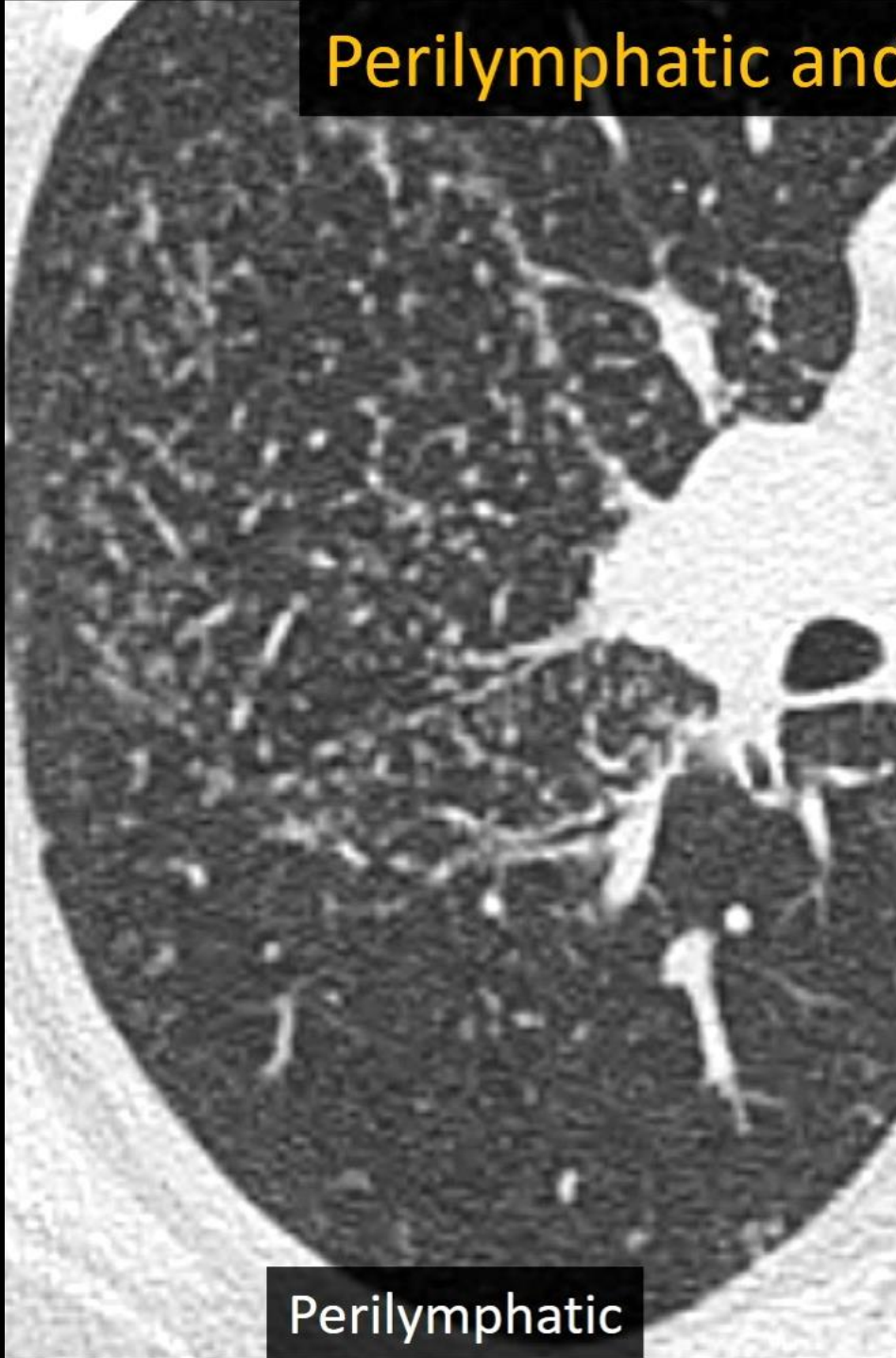
Centrilobular nodules

- Filling of the airway
- Inflammation surrounding the airway
- Obstruction of the airway

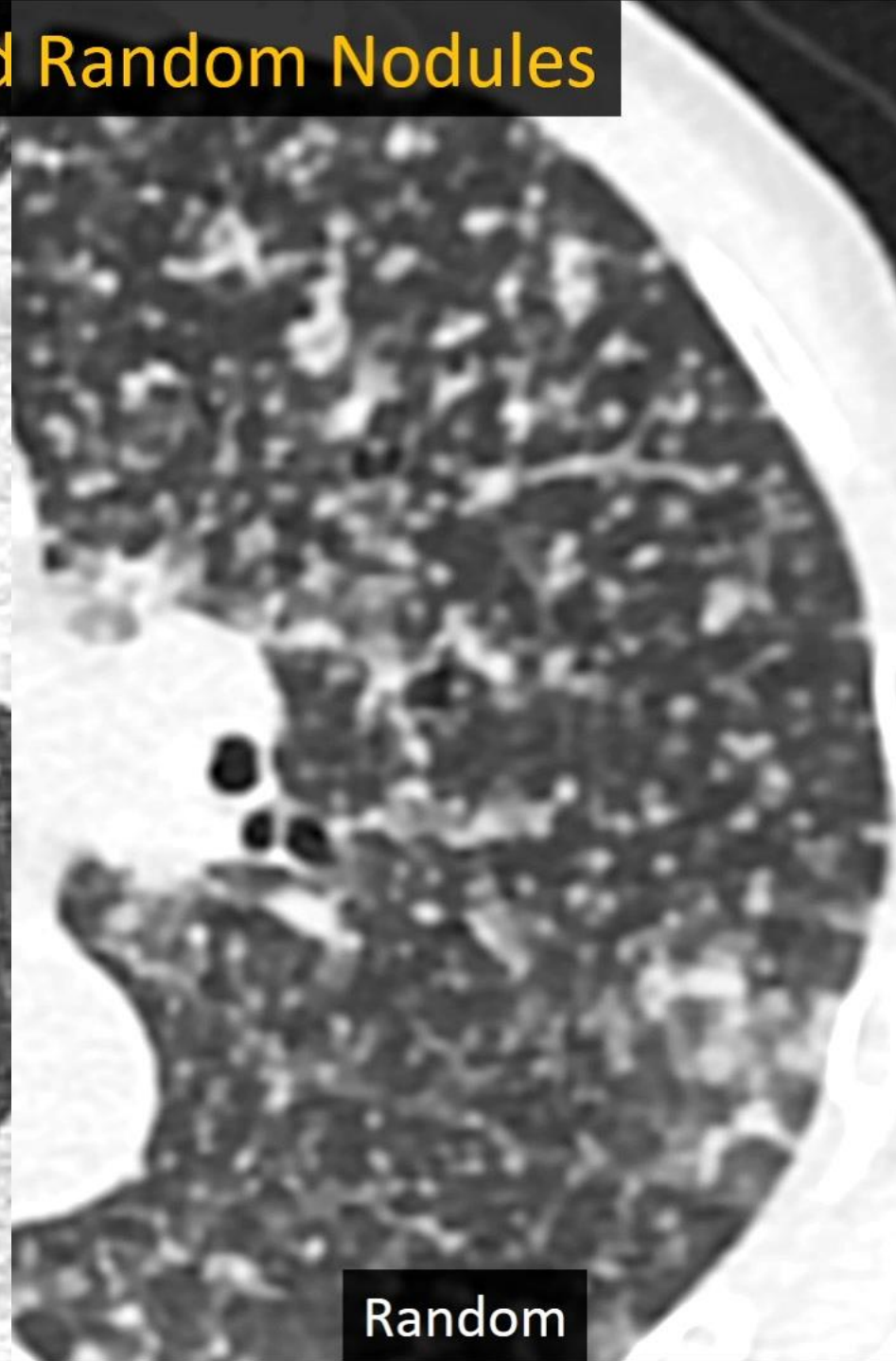




Perilymphatic and Random Nodules

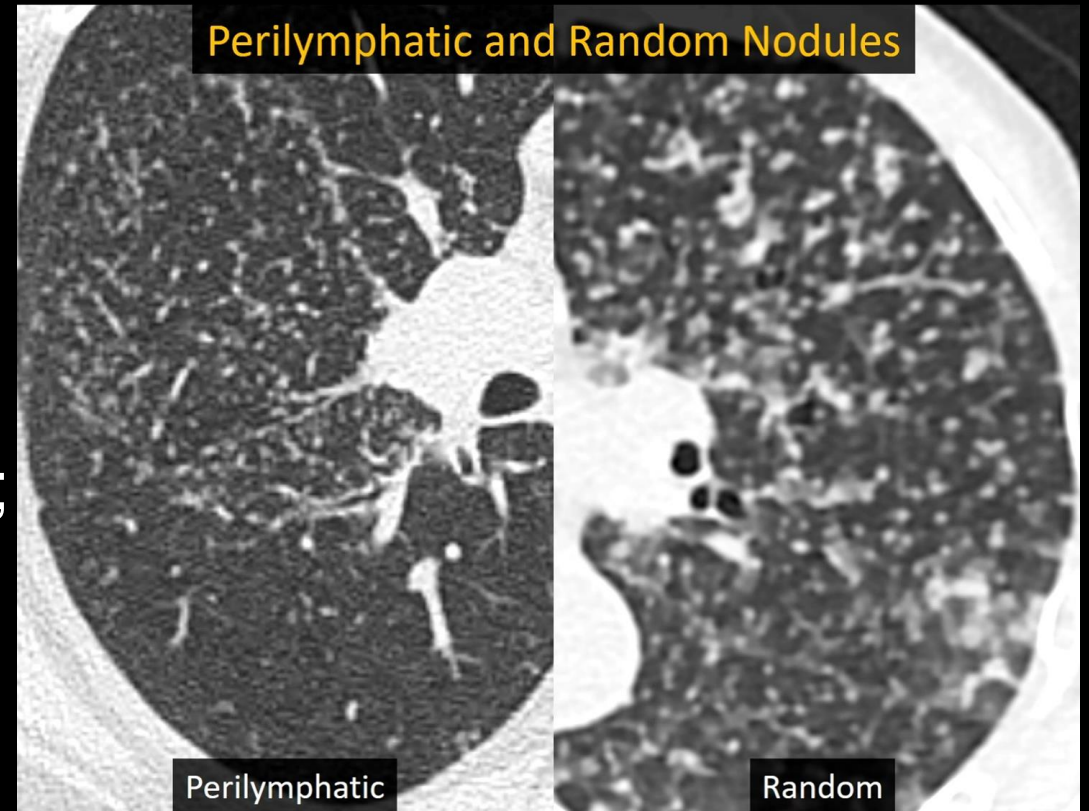


Perilymphatic

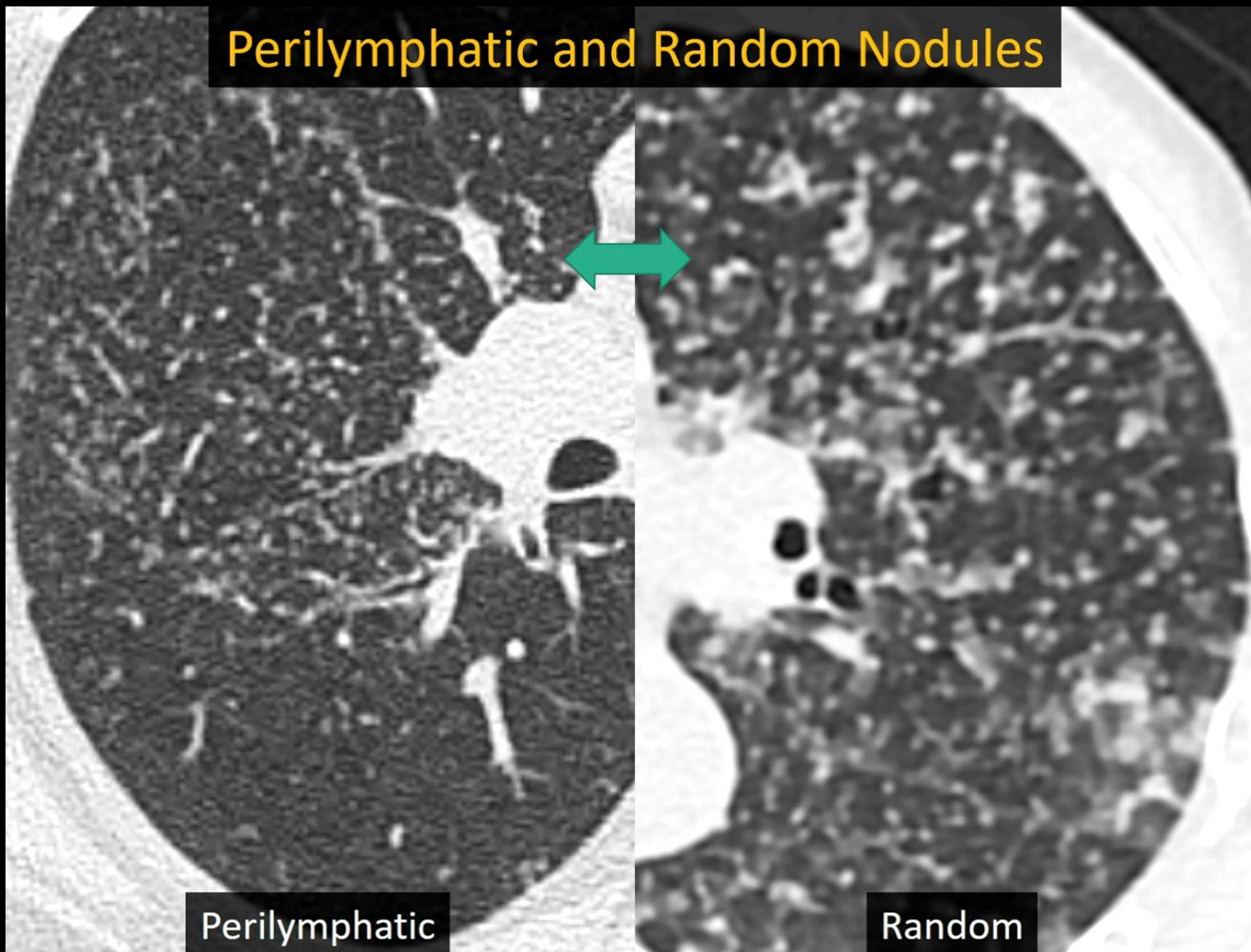


Random

- CT chest: **do not spare the fissures or the pleural surfaces**
- The fissures: major fissure; minor fissure;
- Random nodules: **miliary nodules**;
- Perilymphatic nodules: **tend to cluster**
- Differential diagnosis: similar but different orders;

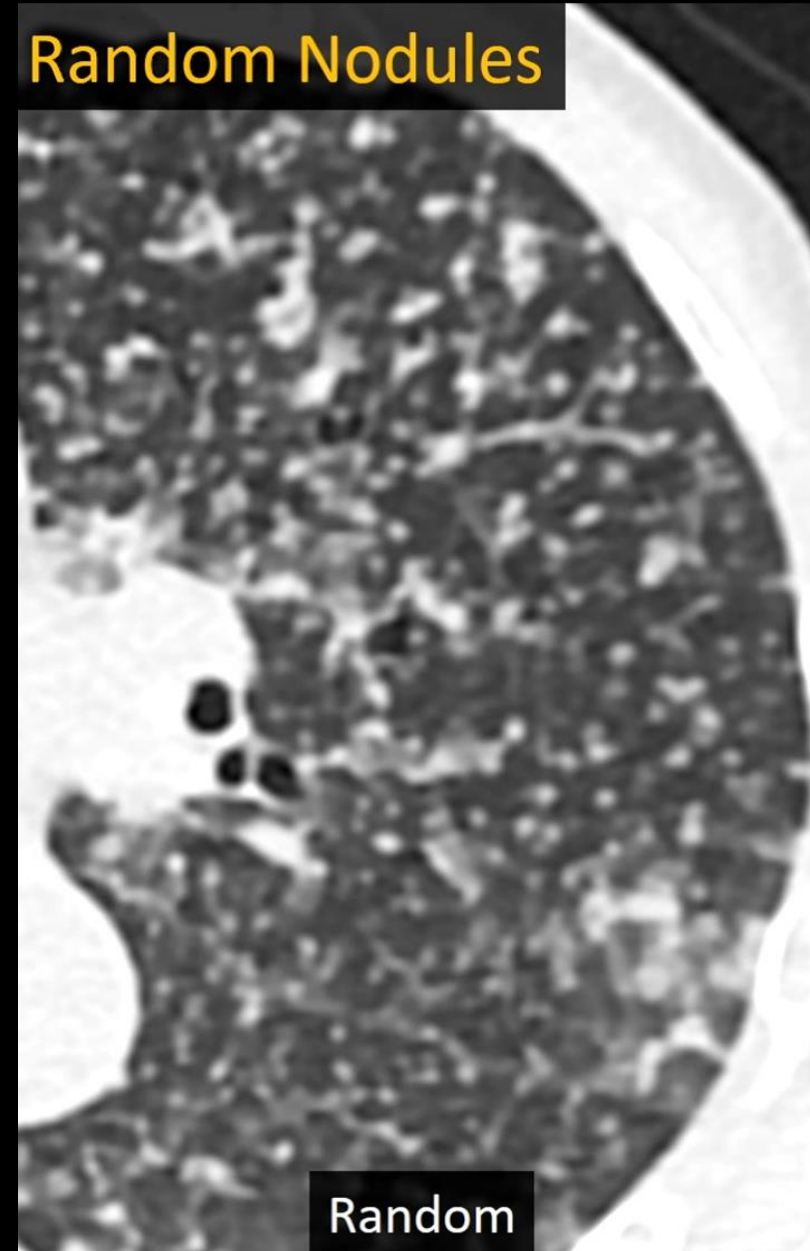


Perilymphatic and Random Nodules



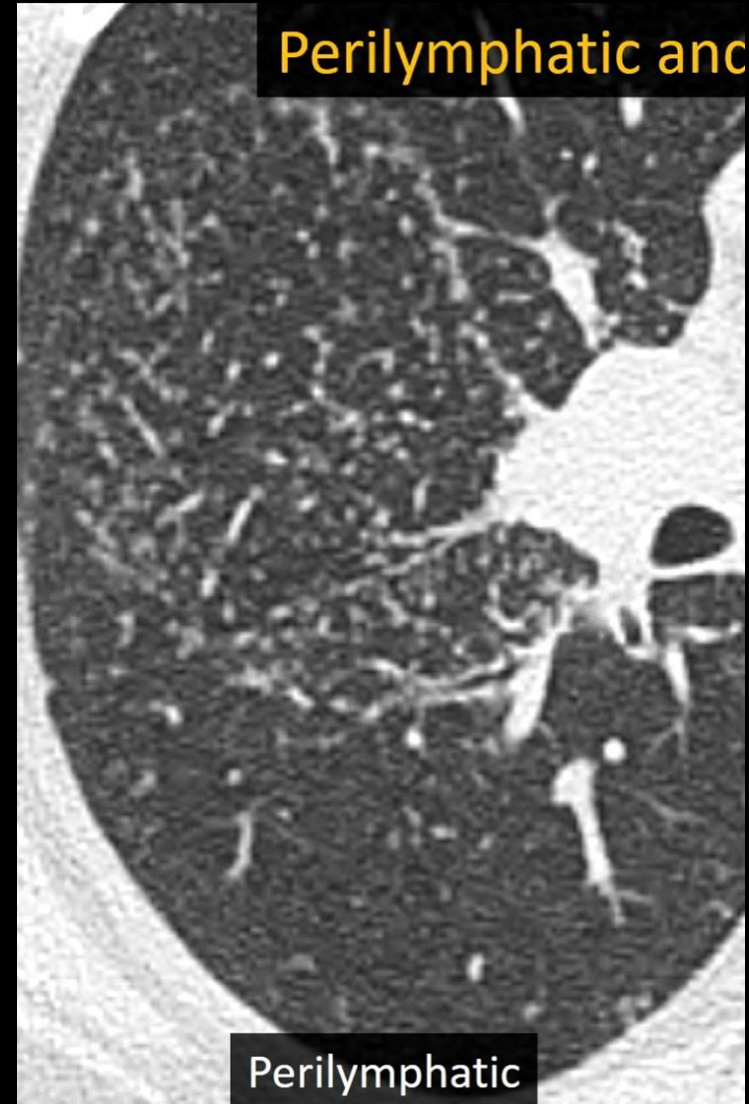Random nodules

- DDX: orders
- **Granulomatous infection** (mycobacterial, fungal)(Hematogenous infection or miliary infection)
- **Metastatic disease** (thyroid cancer, renal cell carcinoma, breast cancer, etc)
- Rarely sarcoid

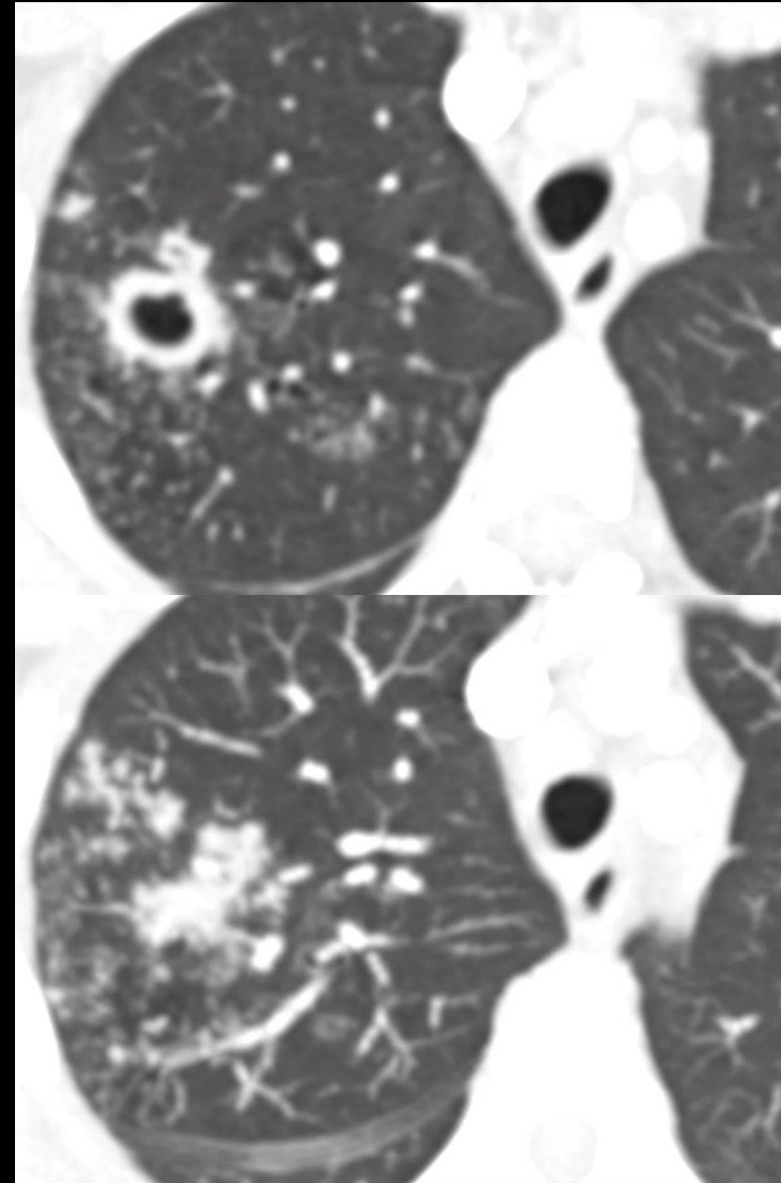


Perilymphatic nodules

- DDX: orders
- Sarcoid/silicosis
- Granulomatous infection (mycobacterial, fungal)
- Metastatic disease

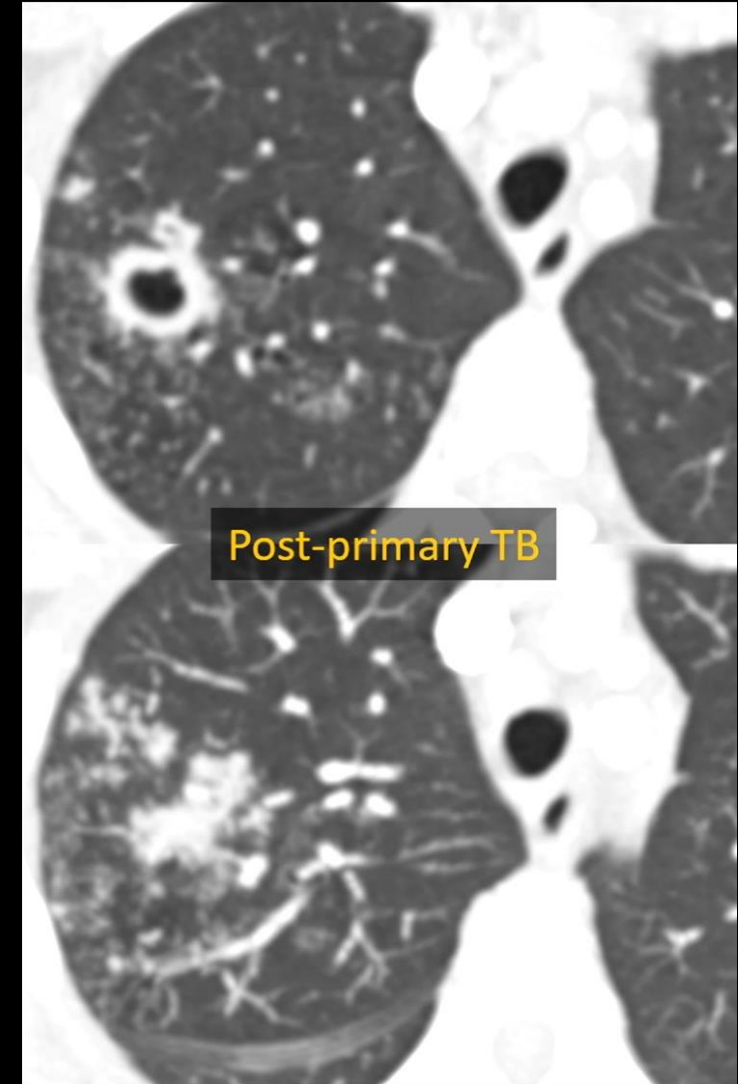


- Case: CT chest:
- **Larger Cavities**
- -> **look at less affected area!** Clues!
- -> nodules with sparing the pleural surfaces
- -> Tree in bud nodules
- -> Area of consolidation (doesn't help us for further differential diagnosis)



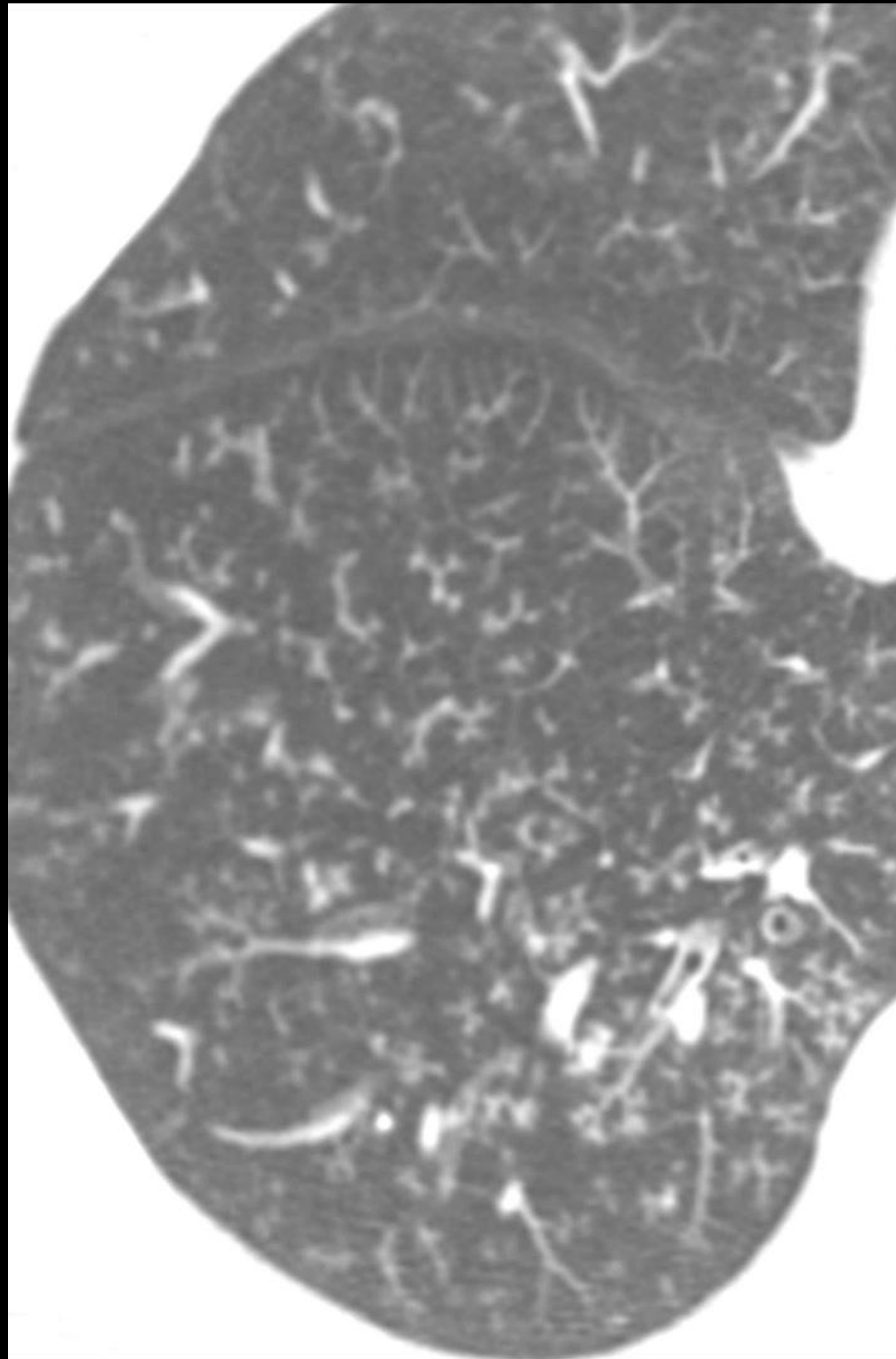
Tree-in-bud (A, B, C, D, E)

- It can help us narrow the differential diagnosis
- **Almost always “infection” or “aspiration”**
- Infectious variants (bronchiectasis, ABPA)
- Specific type of centrilobular nodules
- Represents:
 - -Mucus/pus/fluid in impacted bronchioles
 - -Peribronchiolar inflammation



Diagnosis?

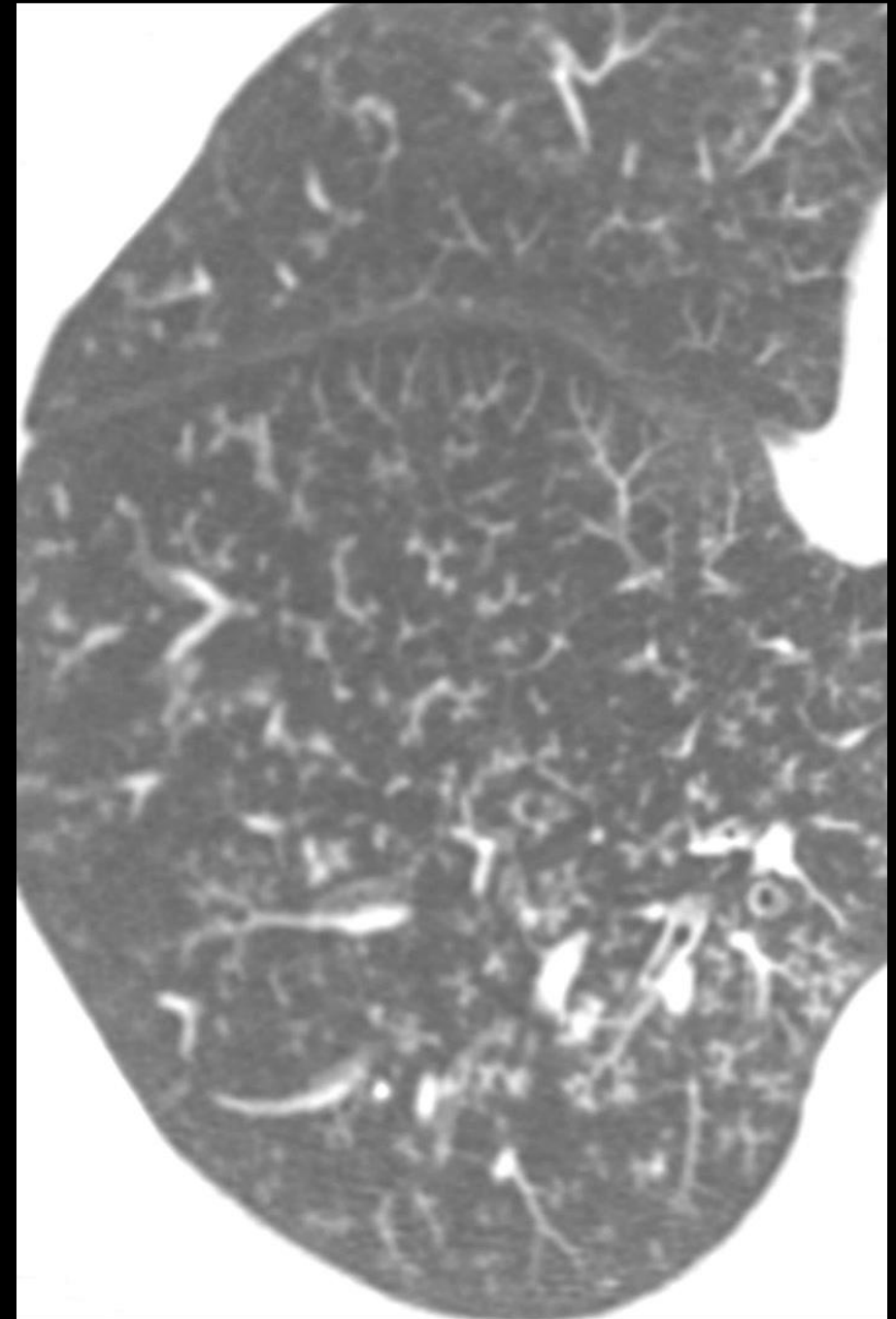
- Case: CT chest



Answers:

A patient with recurrent aspiration

- Centrilobular nodules with tree-in-bud
- Spare the pleural surface
- A little bit of larger airways thickening
- Tend to be in the dependent portions of the lower lobes

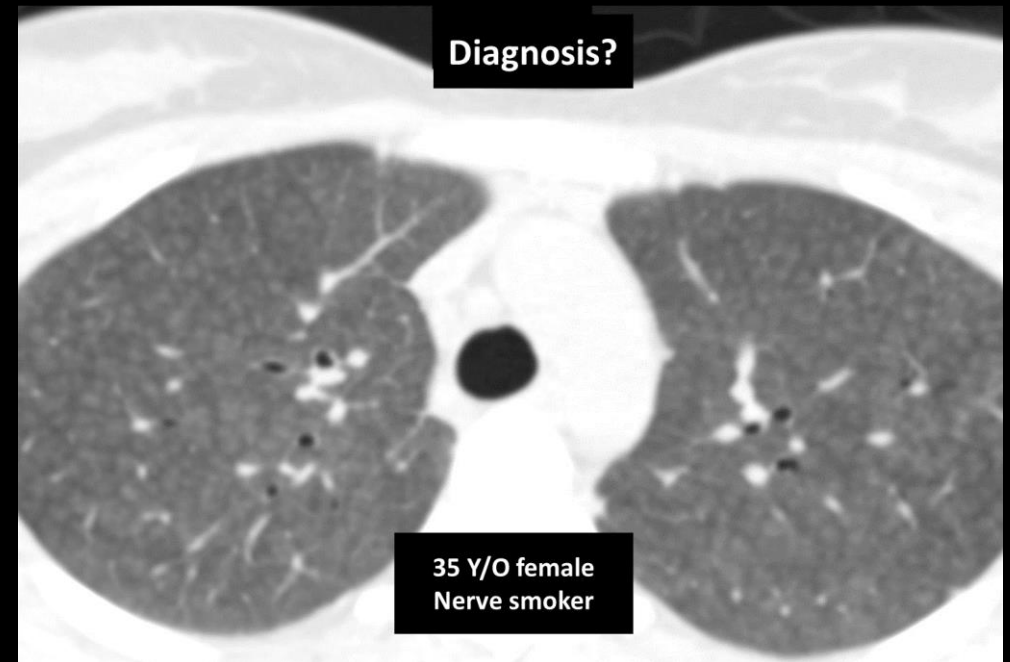


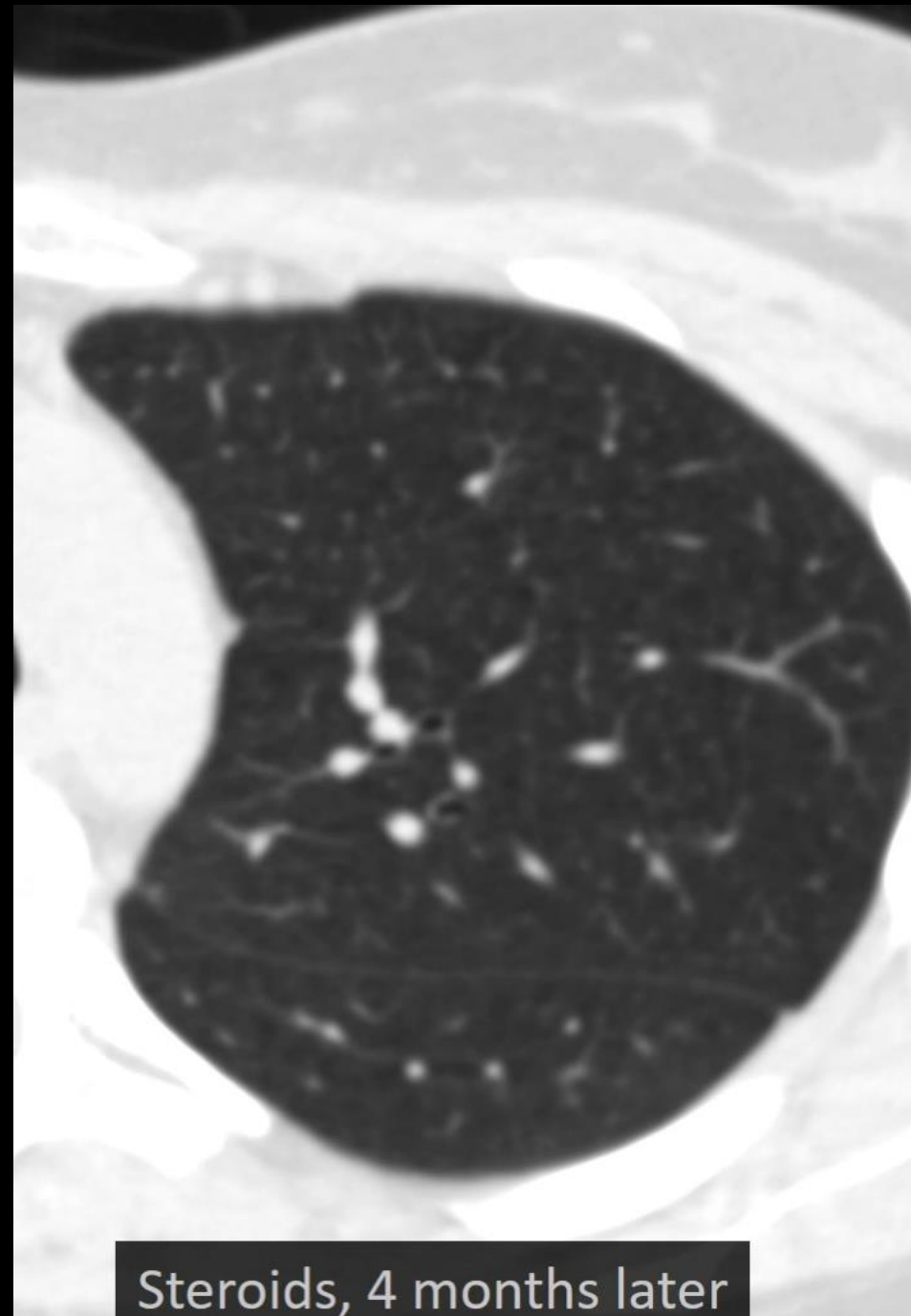
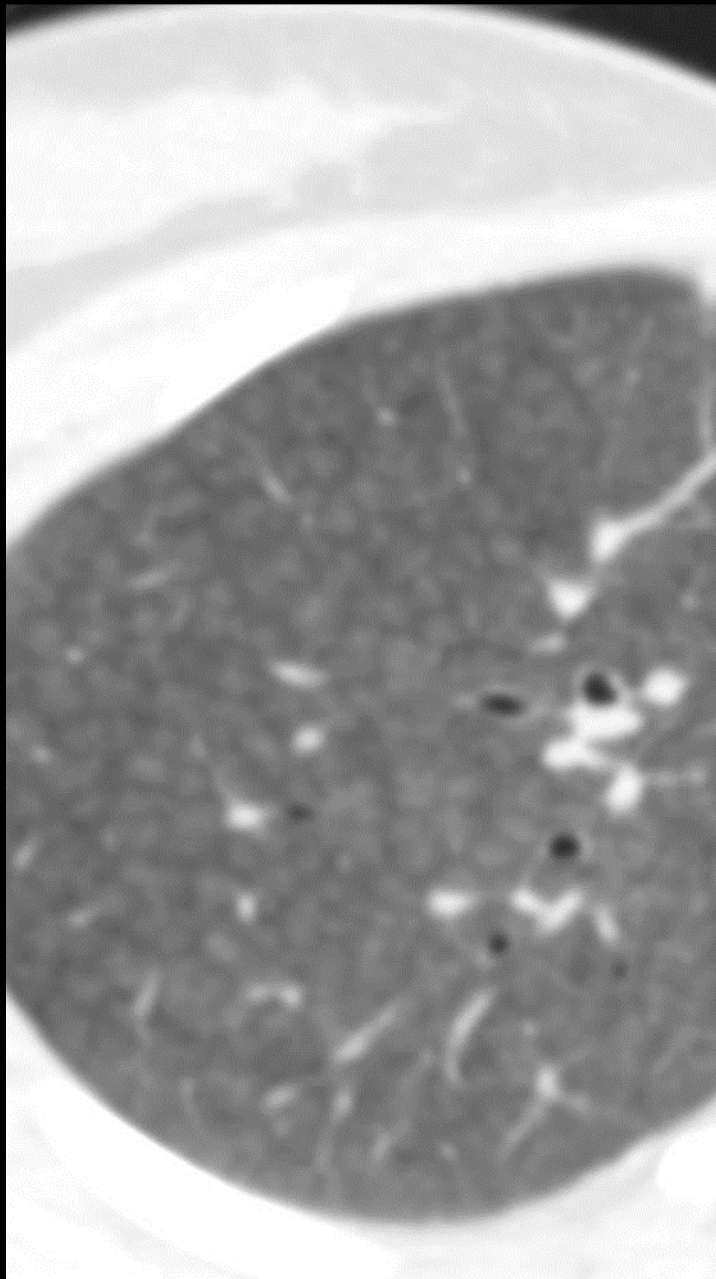
Diagnosis?

**35 Y/O female
Nerve smoker**

Dx: Hypersensitivity pneumonitis (acute)

- Case: 35 Y/O
- A never smoker
- CT chest: representative : all of her lungs
- What is the most likely diagnosis?
- CT chest:
=> diffuse ill-defined centrilobular ground glass nodules; sparing the pleural surface; **Uniform distribution**;
- Rx: steroids

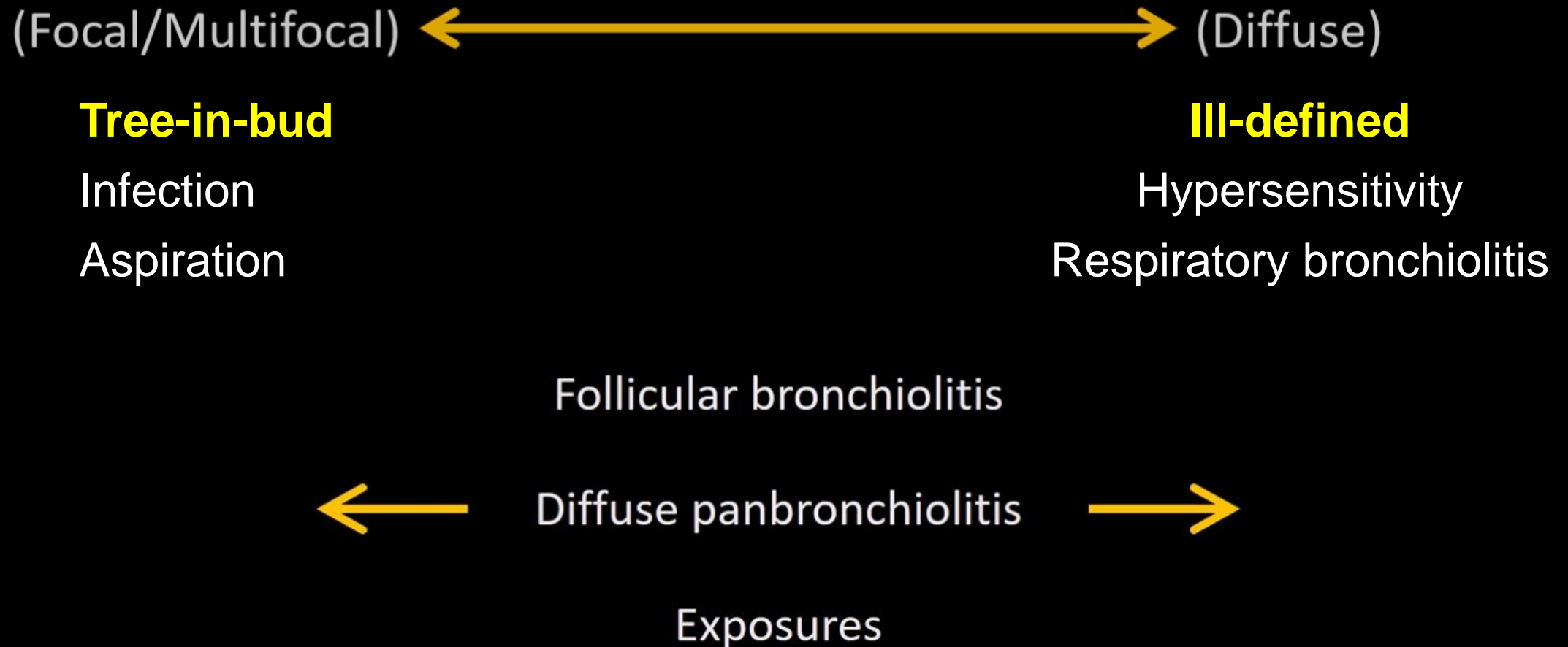




“Centrilobular” vs “tree-in-bud”

- Centrilobular nodules: broad differential; cellular bronchiolitis
- Tree-in-bud nodules: narrow differential, specific; Infection or aspiration;





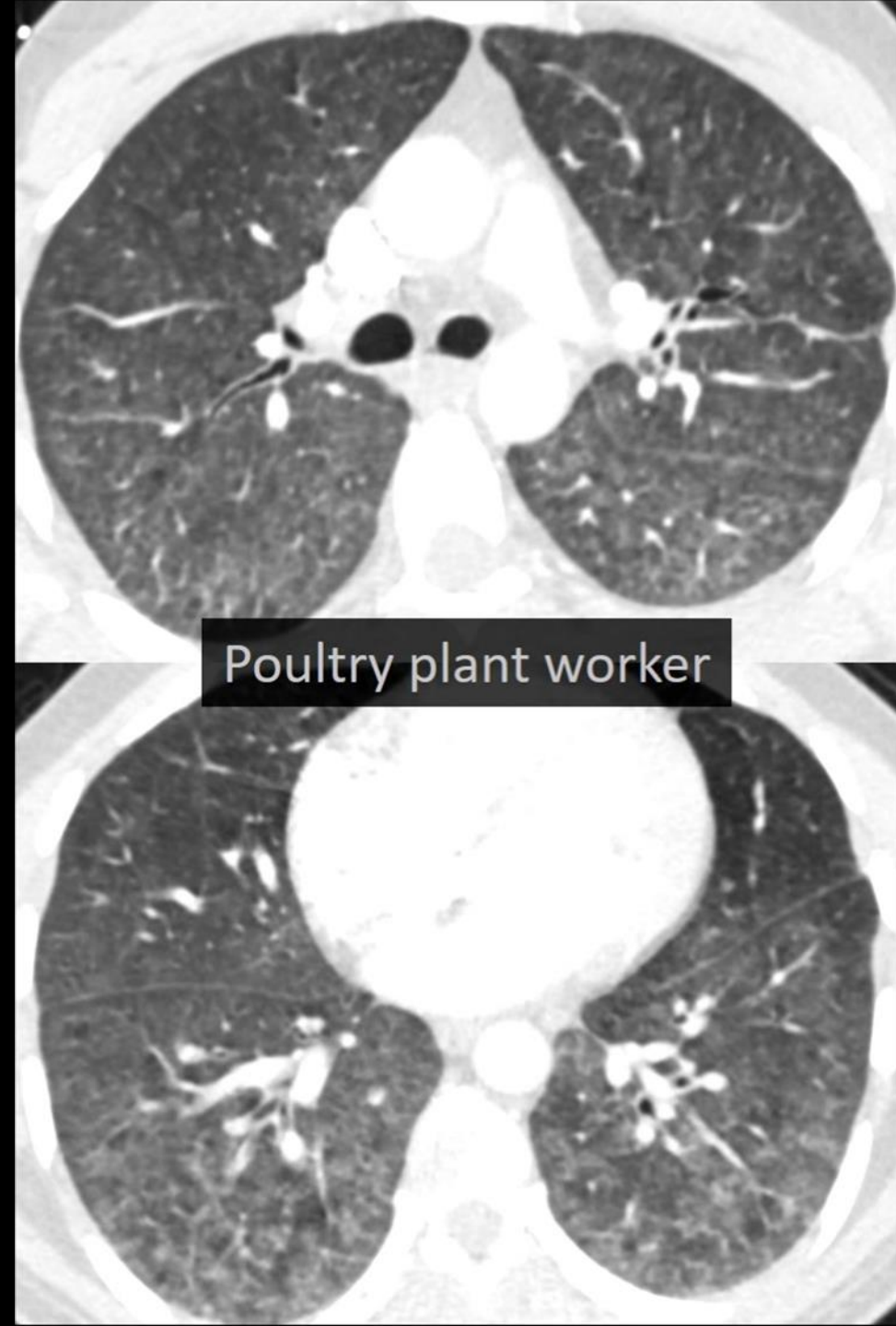
家禽

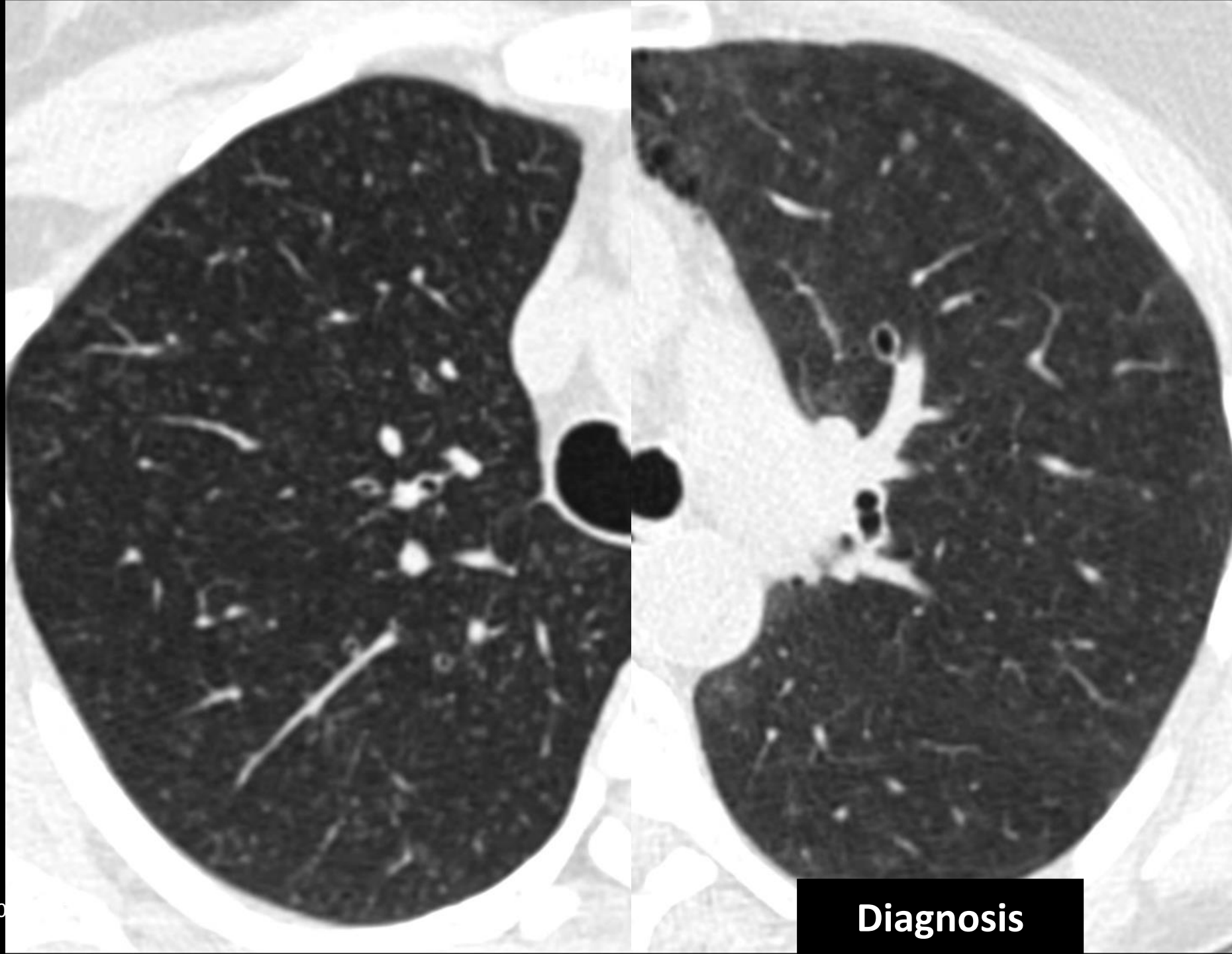
Poultry plant worker

Pet parrot

鸚鵡

- CT chest: more confluent ground glass opacity in the lower lobes
- **Less affected area:** centrilobular ground glass nodules;
- **Avian Hypersensitivity Pneumonitis**





Diagnosis

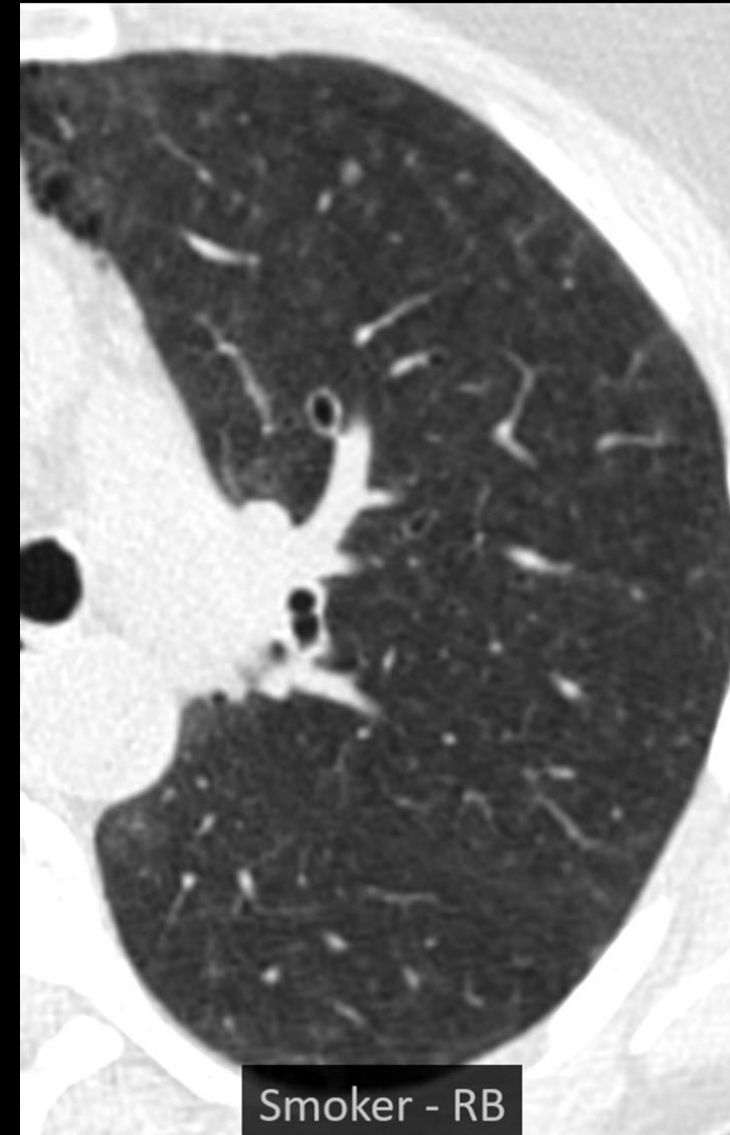
Cases

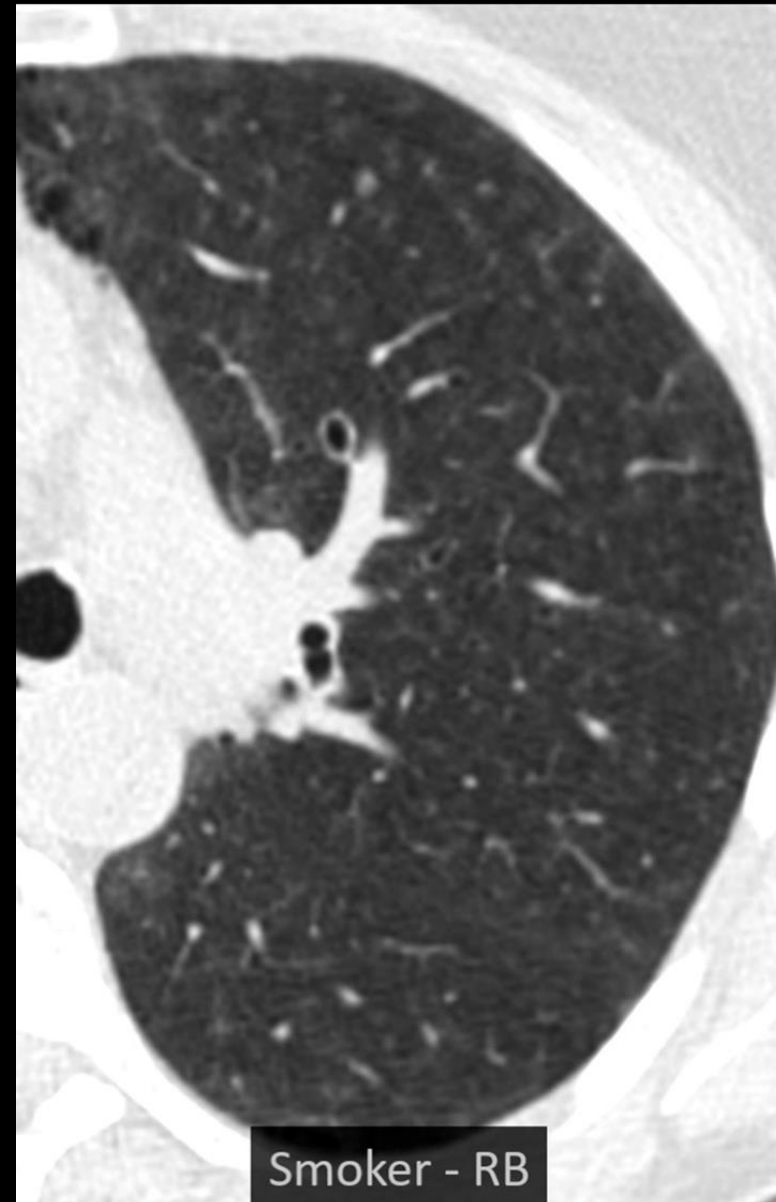
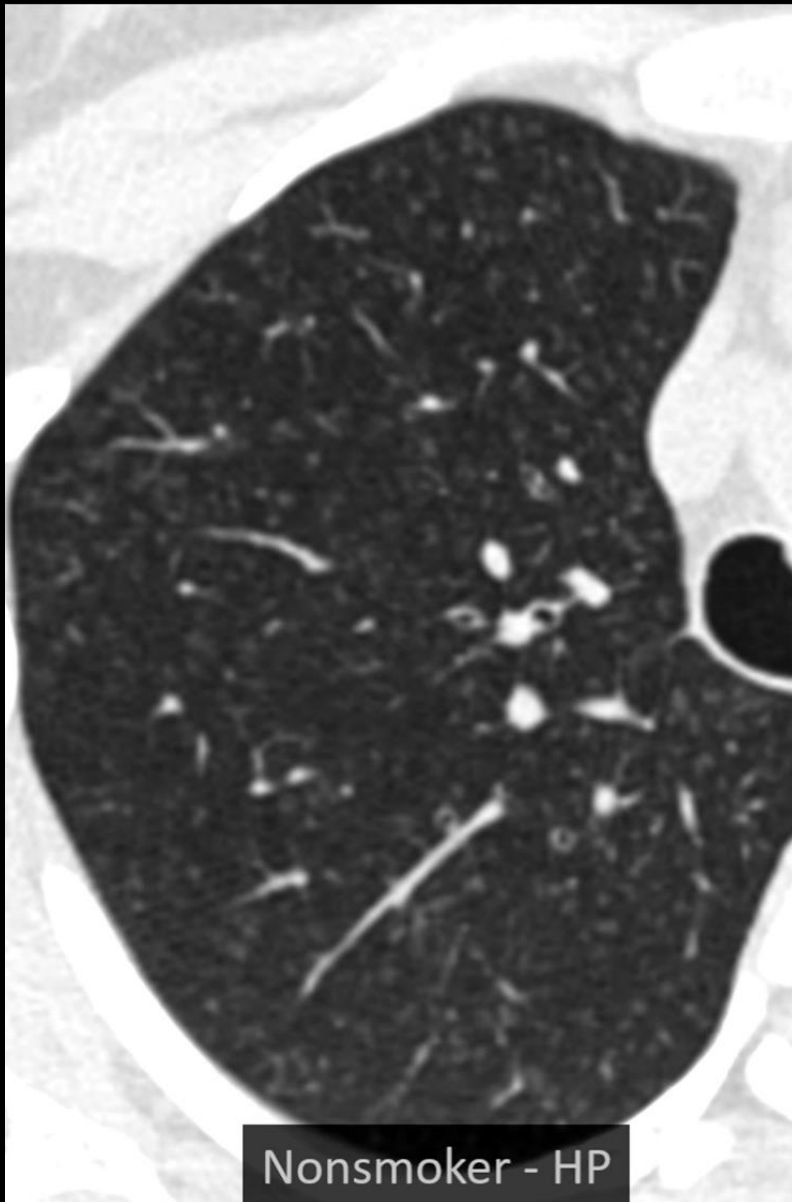
- CT chest: small centrilobular nodules
- Spare the pleural surfaces
- **One of the first question you want to know!**

=> A smoker?

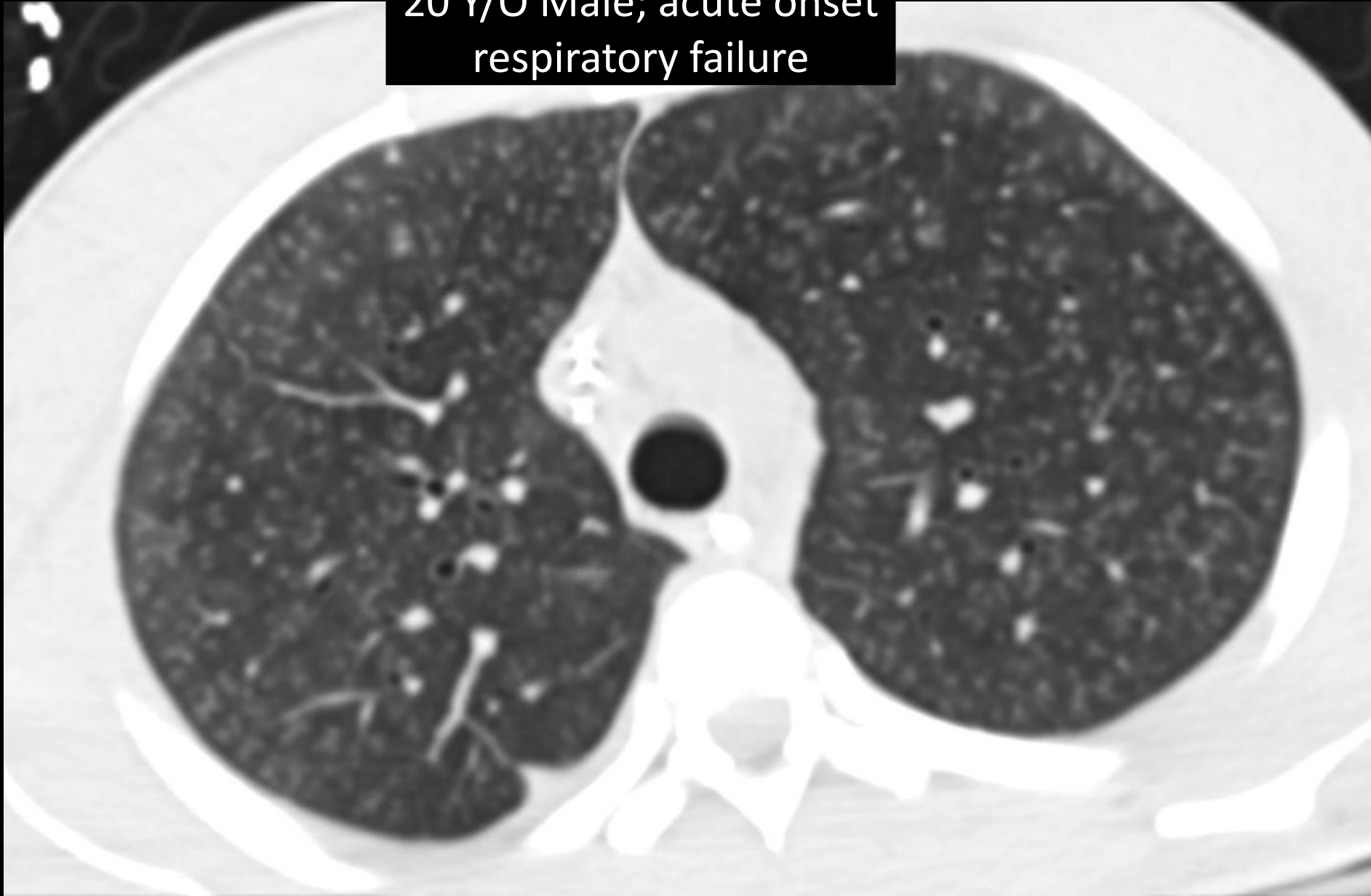- Clues: Have a little bit of emphysema?

-> Smoker: RB (smoking related respiratory bronchiolitis)



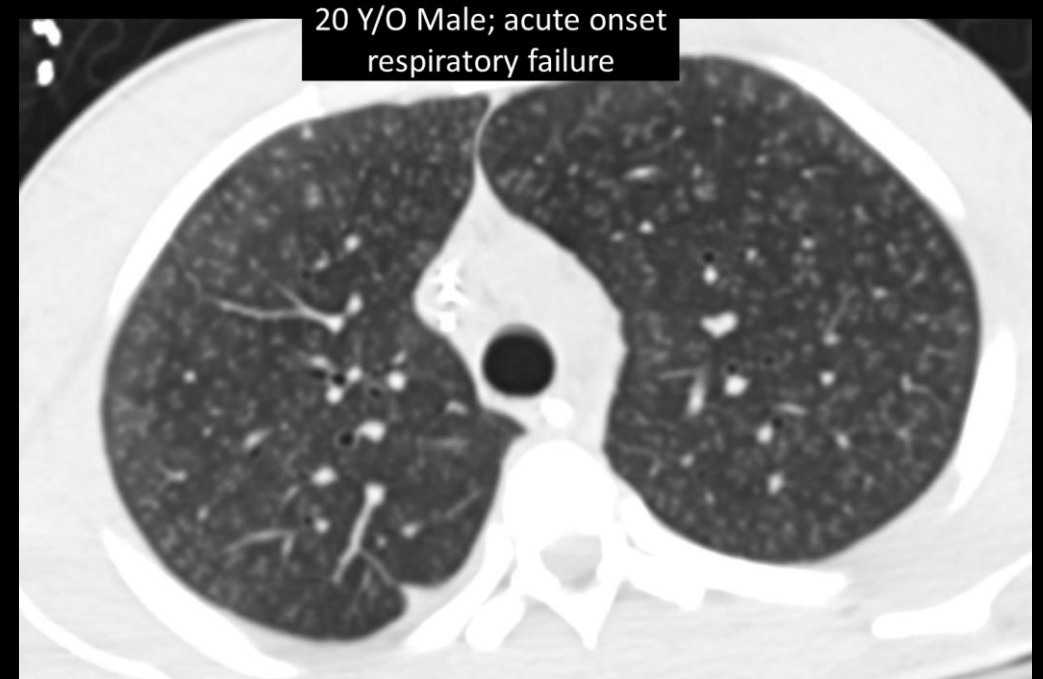

20 Y/O Male; acute onset
respiratory failure



Case: CT chest

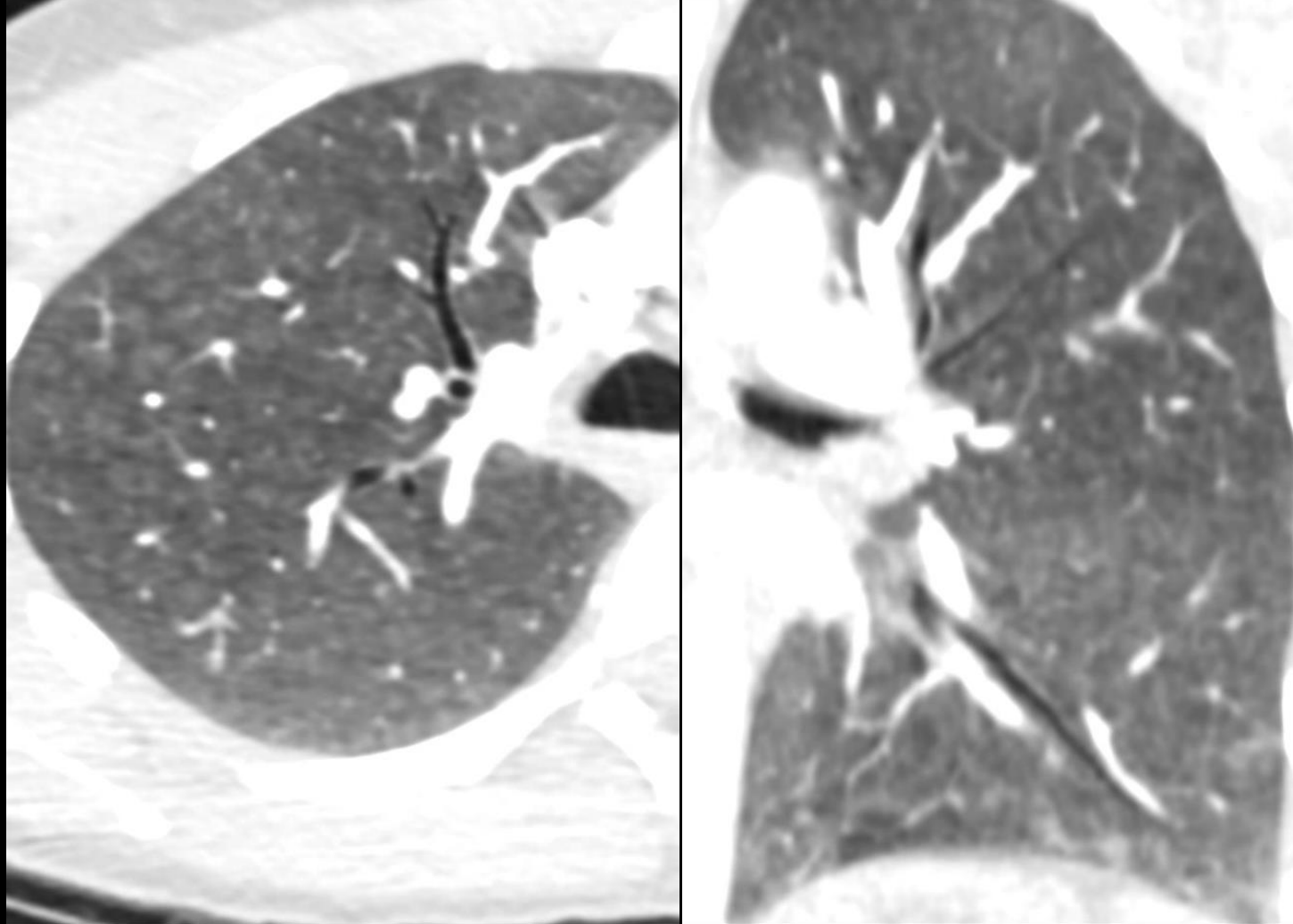
- Two clues -> “**non-infectious**” causes
- (1) **Diffuse** centrilobular nodules
- (2) Diffuse and **uniformly** involved the lungs
- History taking: “**exposure**” history



Case: Synthetic marijuana

- Dx: **Smoking synthetic marijuana**
- S/S: Profound dyspnea
- Respiratory failure
- Death in 2 of 5 patients
- Chemical -> intense inflammation -> acute lung injury
- Diffuse centrilobular nodules-think non-infectious causes

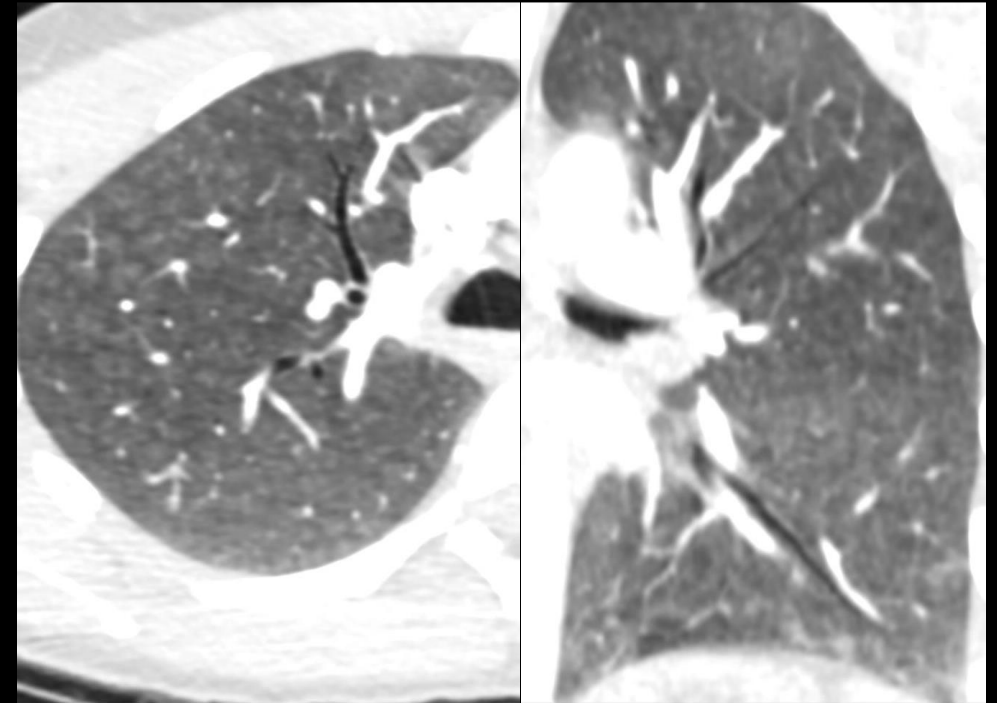
30 Y/O Female; dyspnea
Diffuse centrilobular nodules



Case:

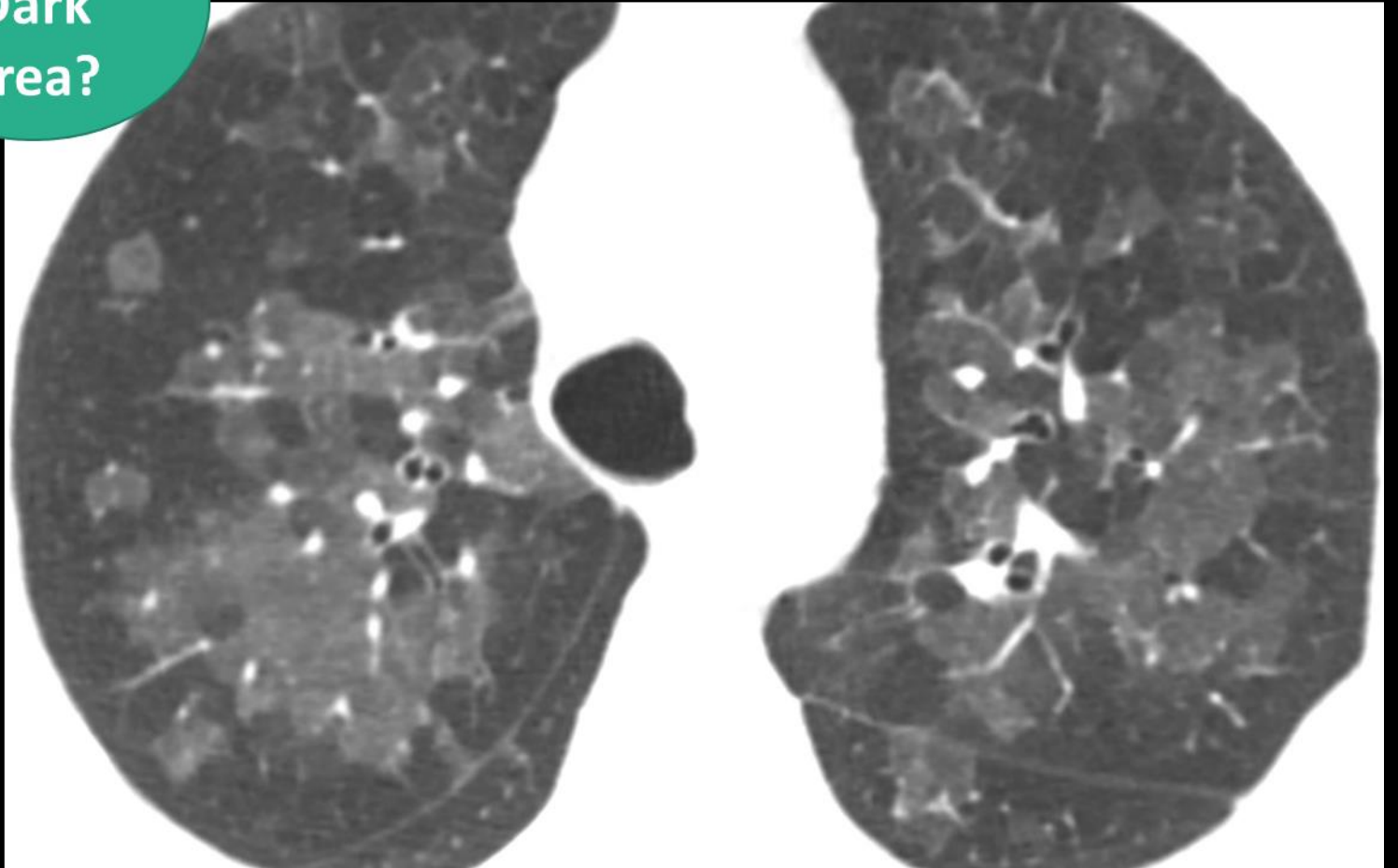
- CT chest: centrilobular nodules
- Coronal CT: diffuse
- Smoking? Any sort of smoking?
- => **Starting to vape marijuana oil (CBD oil)**
- S/S onset: the same time!
- Cannabidiol (CBD) oil

30 Y/O Female; dyspnea
Diffuse centrilobular nodules

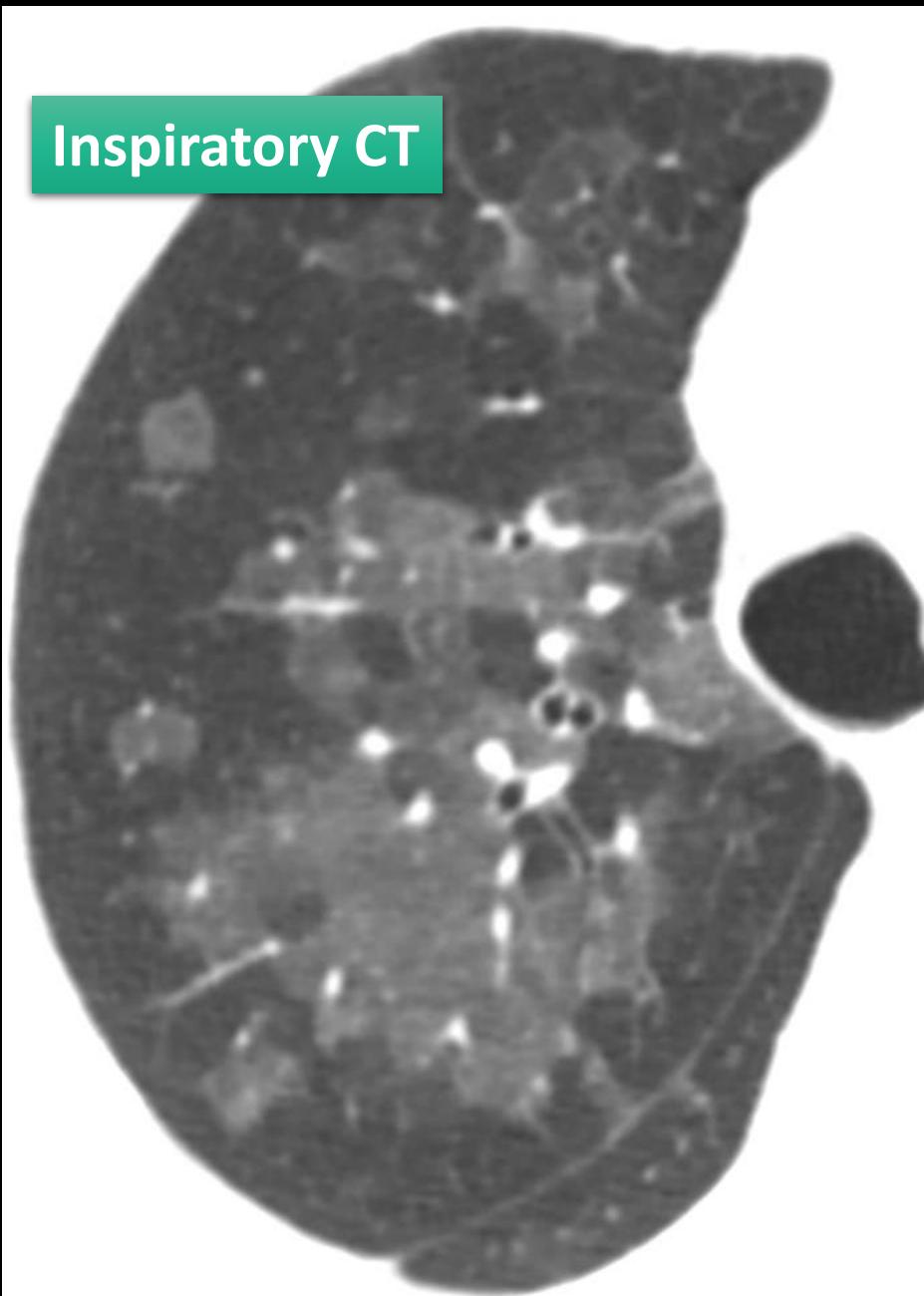


- Case: 60 Y/O male
- CT chest:
- Question:
Which areas are abnormal?

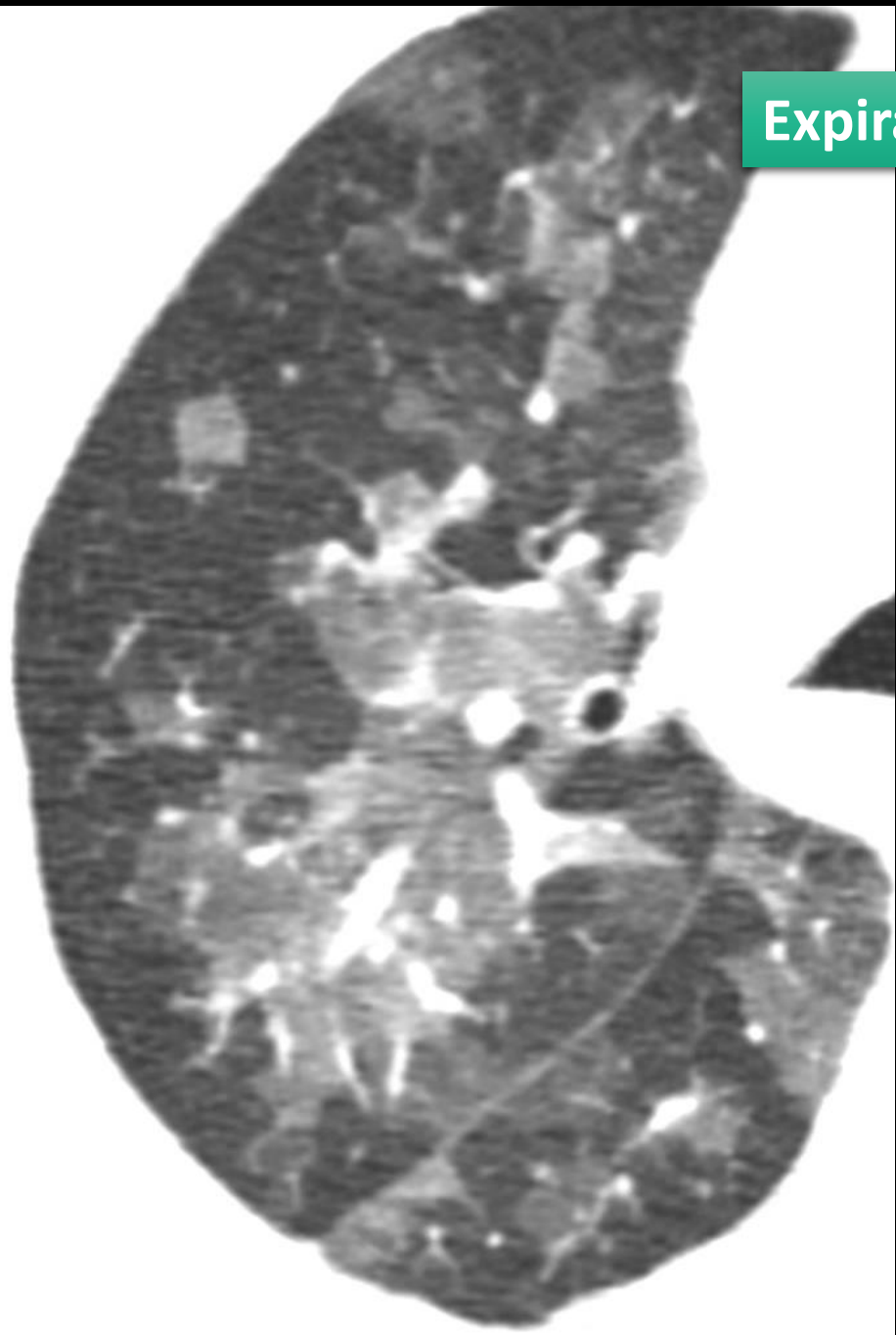
Gray or
Dark
area?



Inspiratory CT

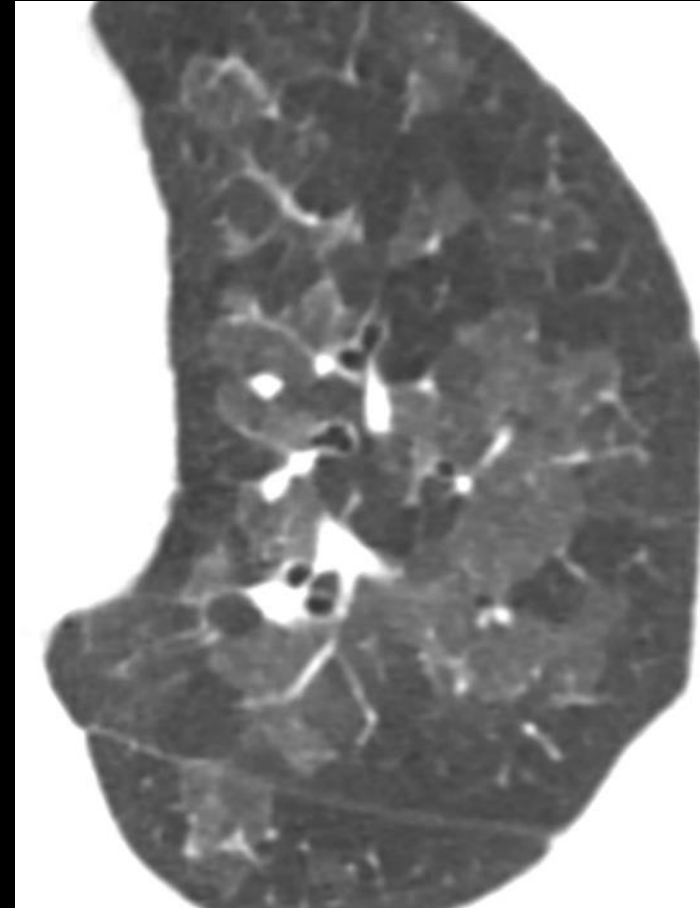


Expiratory CT



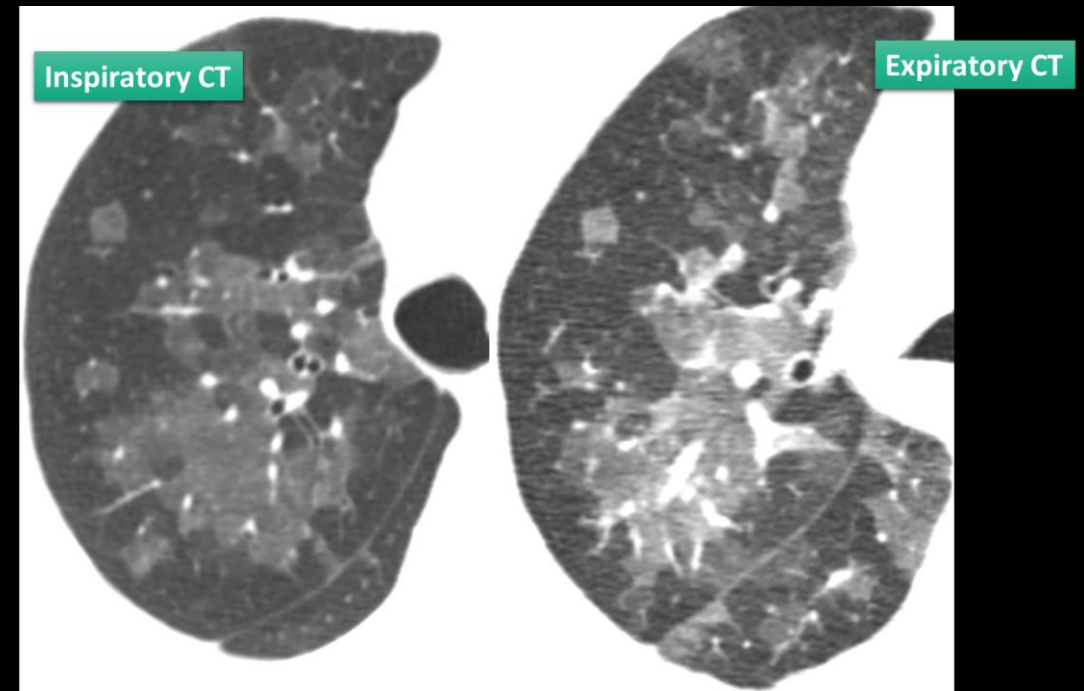
Case: Mosaic attenuation/air trapping

- CT chest: mosaic attenuation (different densities in the lungs)
- **Answers: The dark areas are abnormal!**
- Hypersensitivity pneumonitis
- Obliterative bronchiolitis (constrictive bronchiolitis)

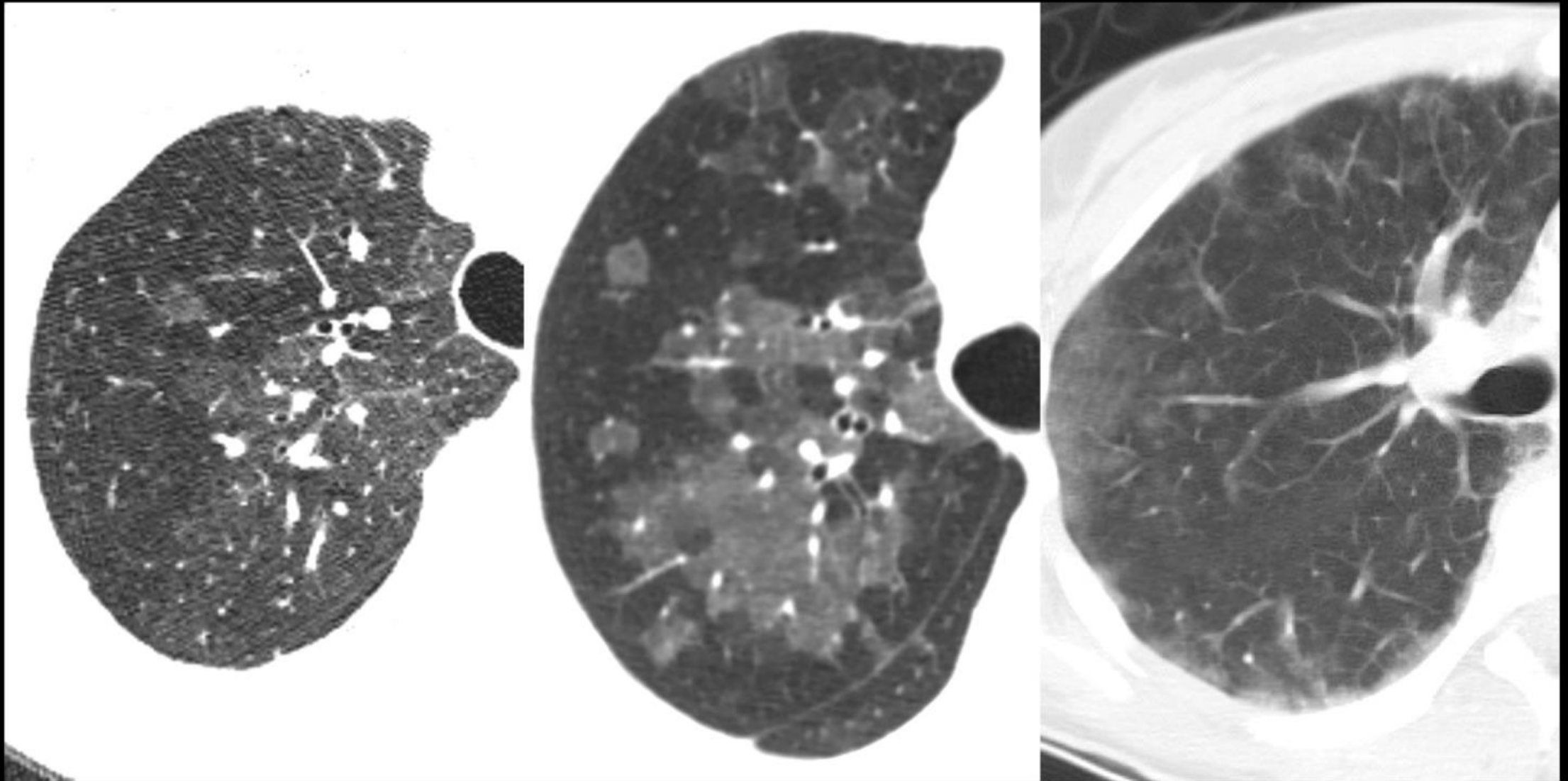


Case

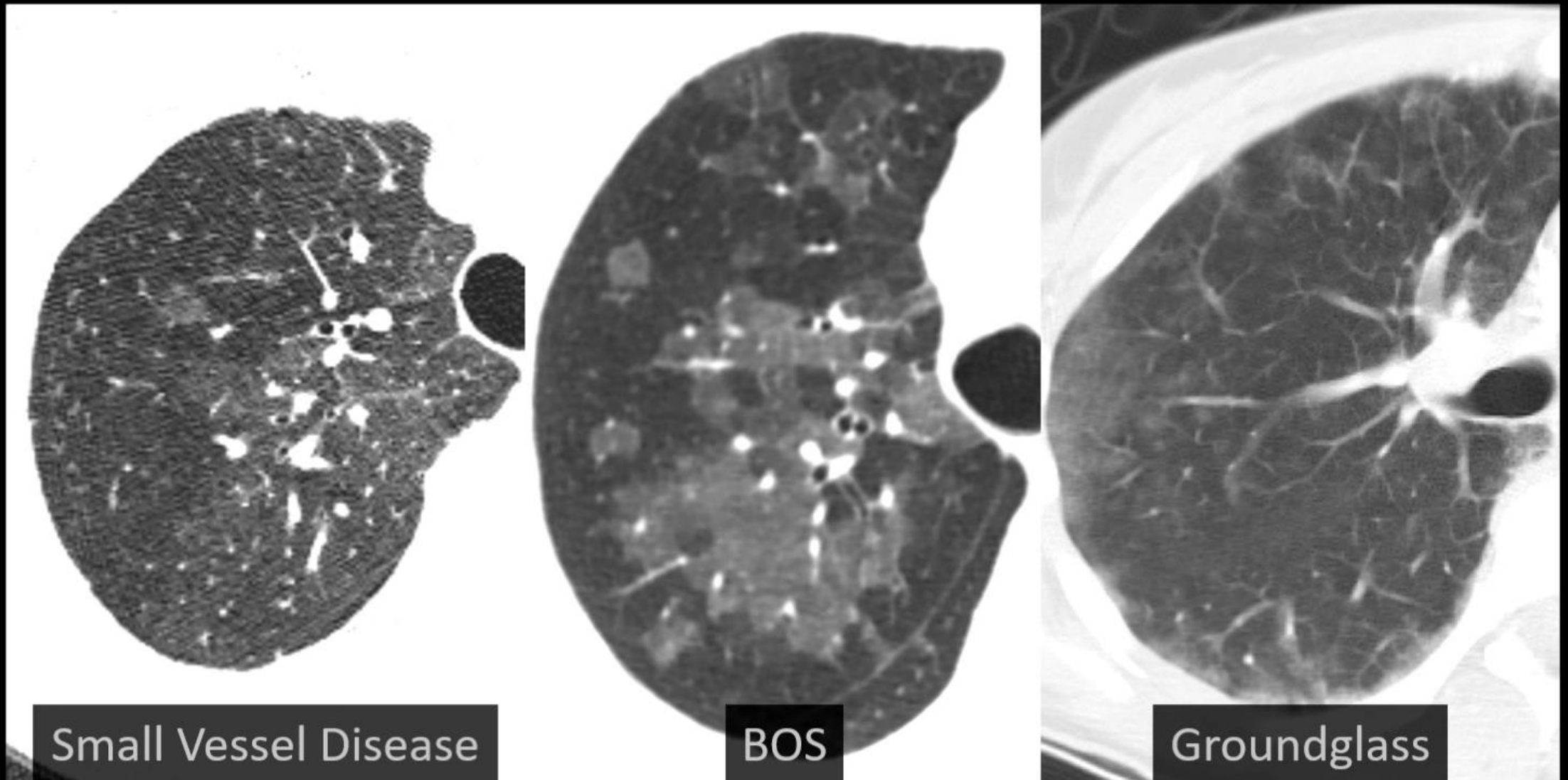
- Inspiratory CT
- **Expiratory CT: dark area persist;**
- Gray area: normal caliber vessels
- **Dark area: don't have normal caliber vessels**
- Expiratory CT: dark area persist => **Air trapping!**
- Dx: Bronchiolitis



- Histologic:
- Cellular (proliferative): Direct imaging findings
- Constrictive (fibrotic): Indirect imaging findings: “air trapping”



Kligerman SJ, Henry TS, Lin CT, et al. Mosaic Attenuation: Etiology, Methods of Differentiation, and Pitfalls. Radiographics 2015; 35:1360-1380



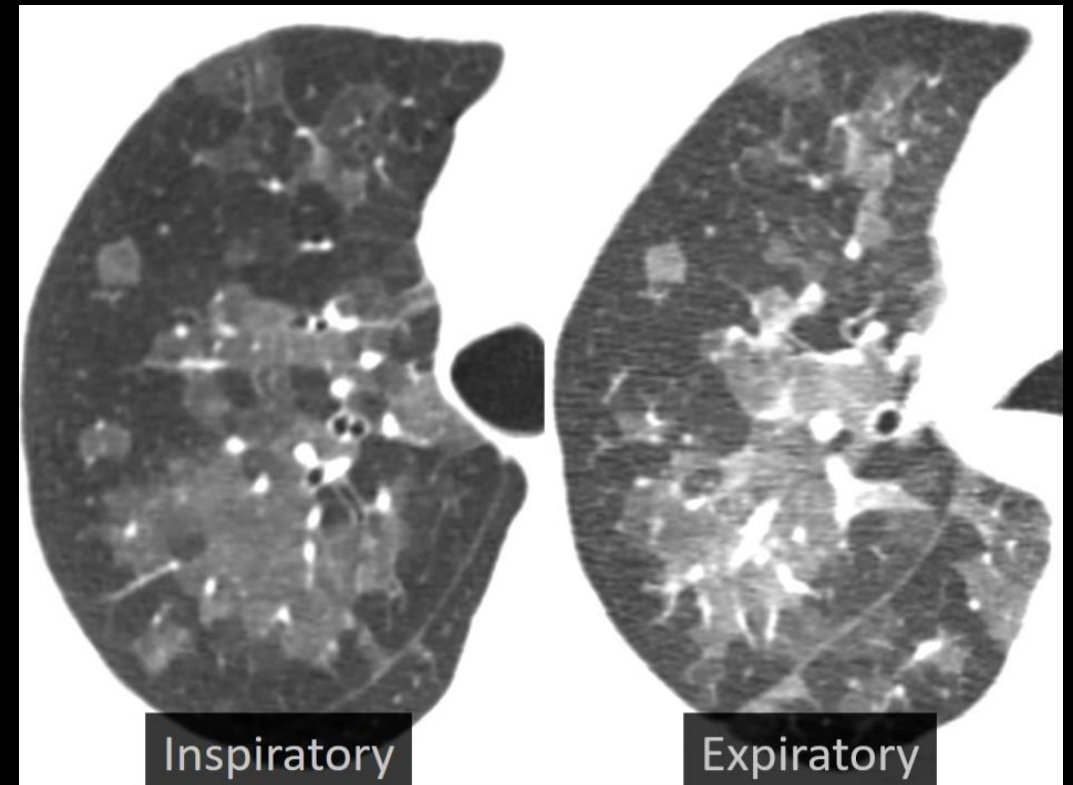
Kligerman SJ, Henry TS, Lin CT, et al. Mosaic Attenuation: Etiology, Methods of Differentiation, and Pitfalls. Radiographics 2015; 35:1360-1380

Mosaic attenuation

- Small vessel disease vs BOS vs Ground glass
- Small vessel disease: **chronic thromboembolic disease**
- Bronchiolitis obliterans (in a **post-lung transplantation patient**)
- Ground glass opacities: **pneumocystis pneumonia**

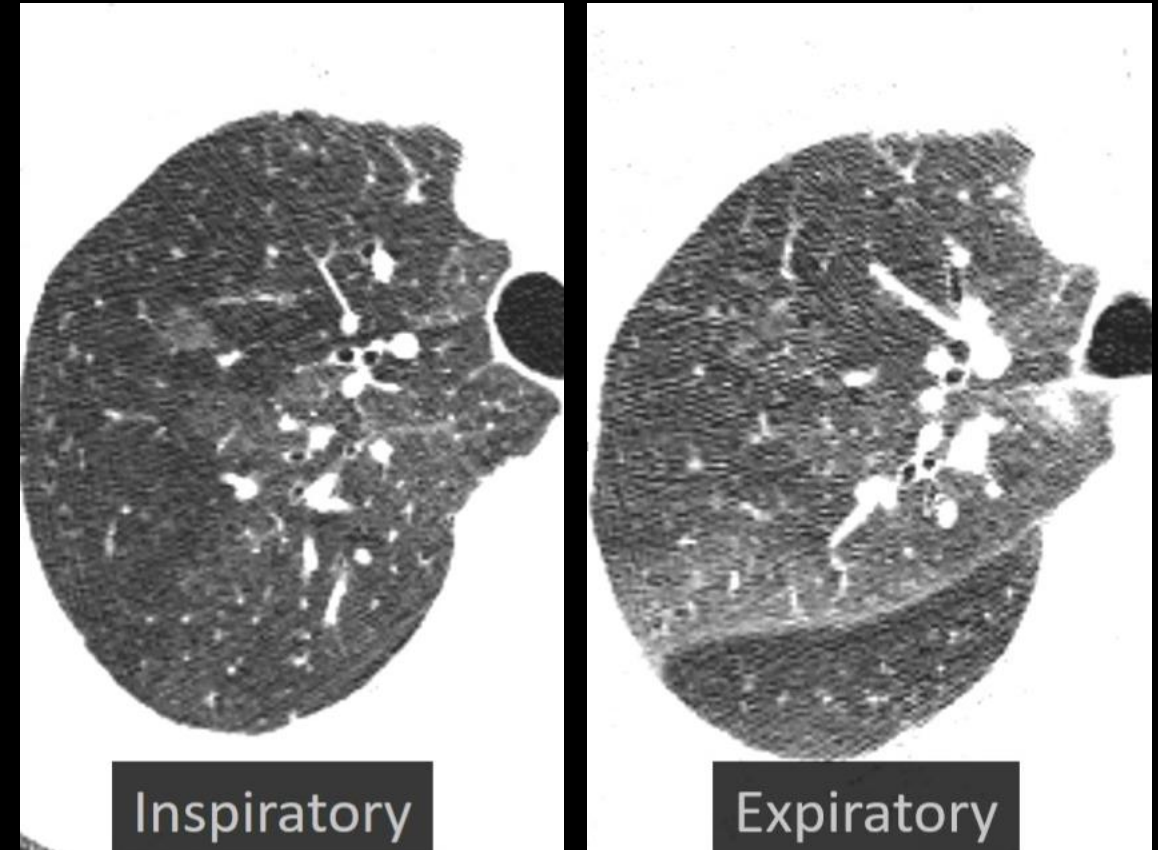
Constrictive (Obliterative) Bronchiolitis

- Small airway disease -> need expiratory CT
- Bronchiolar obstruction
 - > reduced ventilation
 - > **Hypoxic vasoconstriction**
 - > Lucent lung (dark area)
- Inspiratory CT -> Expiratory CT
- Air-trapping -> Attenuation difference “magnified” -> dark area: persist

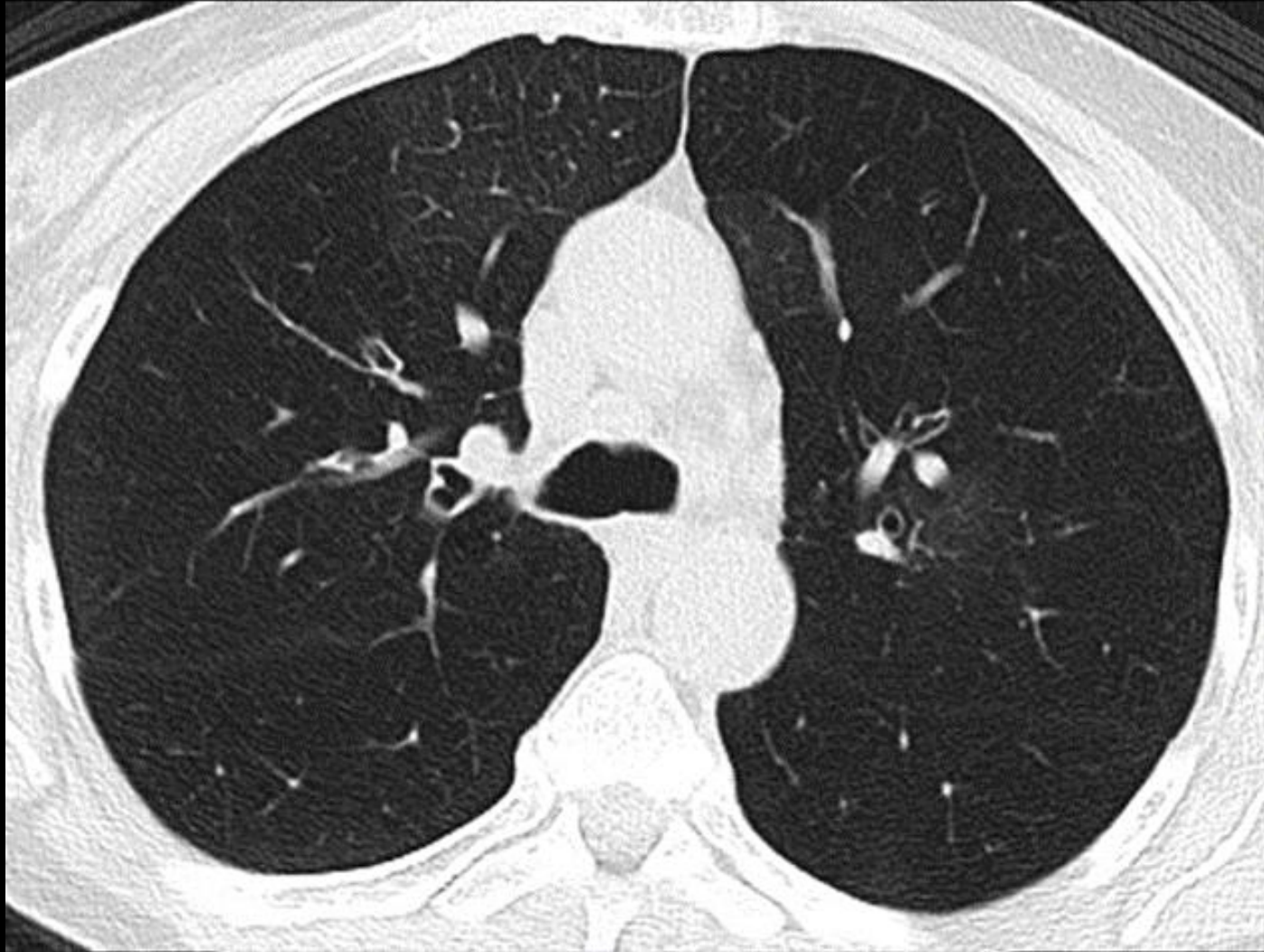


Small vessel disease

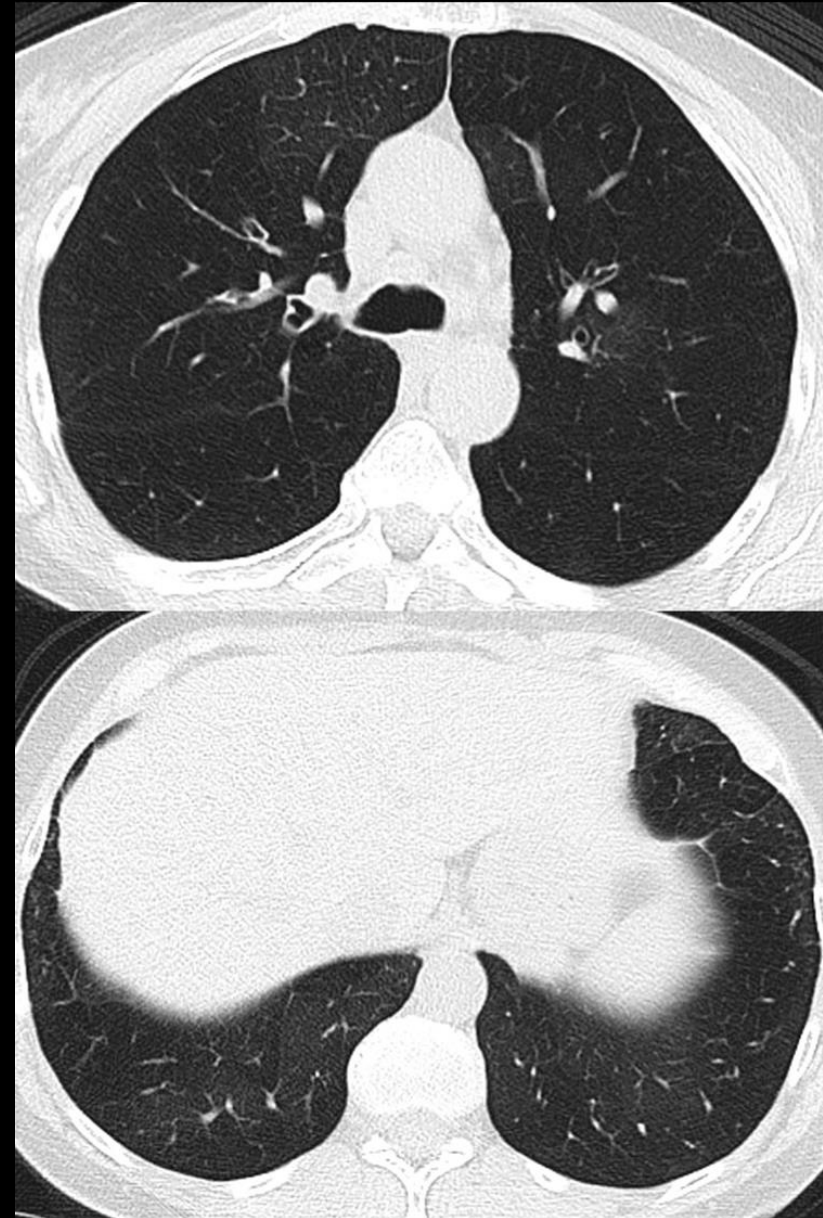
- Segmental or subsegmental artery: oligemia
- Vascular obstruction
 - > **decreased blood flow**
 - > lucent lung
- Inspiratory CT -> Expiratory CT: more air out! -> grey!
- Air-trapping
 - > **Attenuation difference “minimized”**

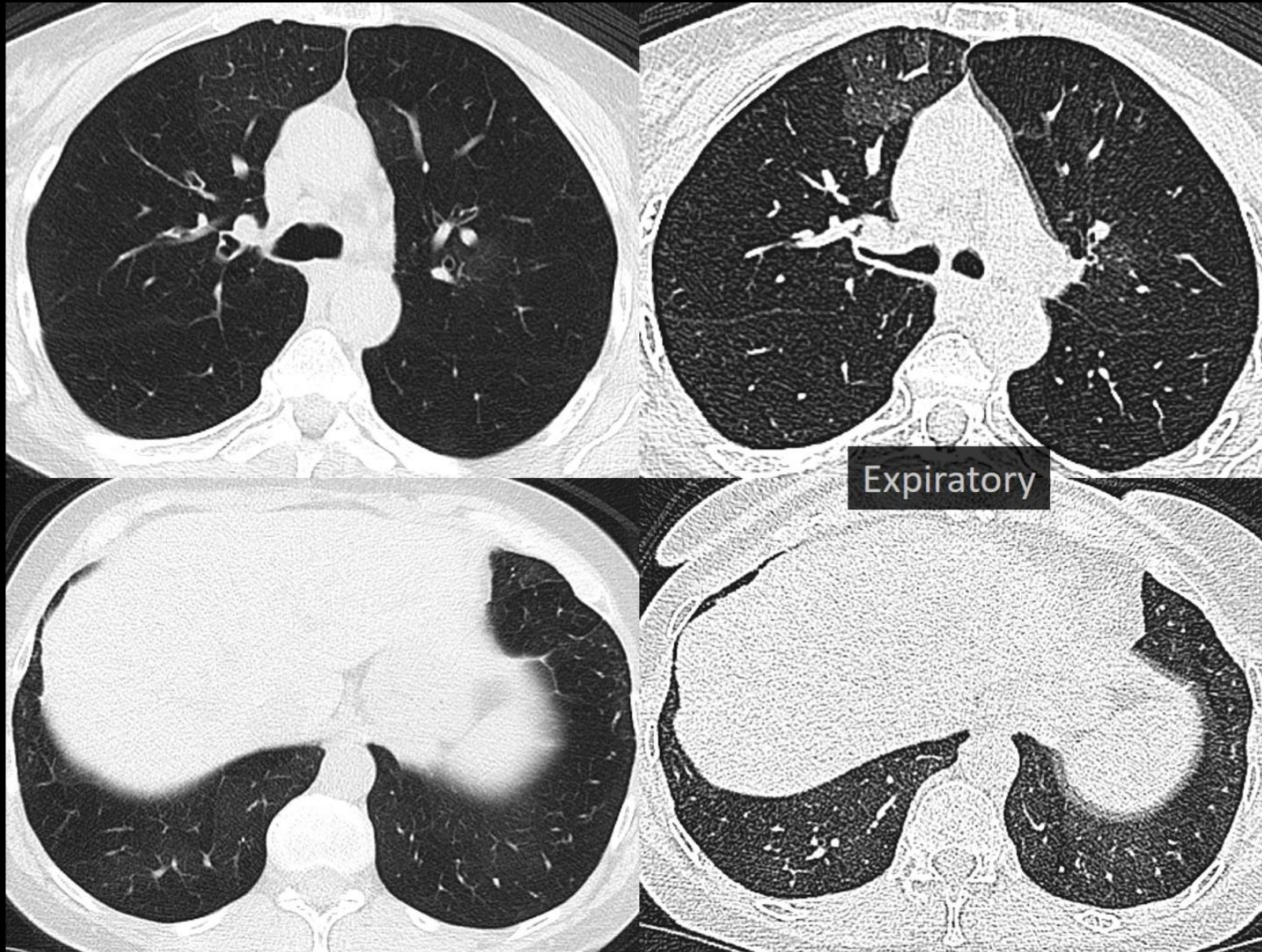


Case:

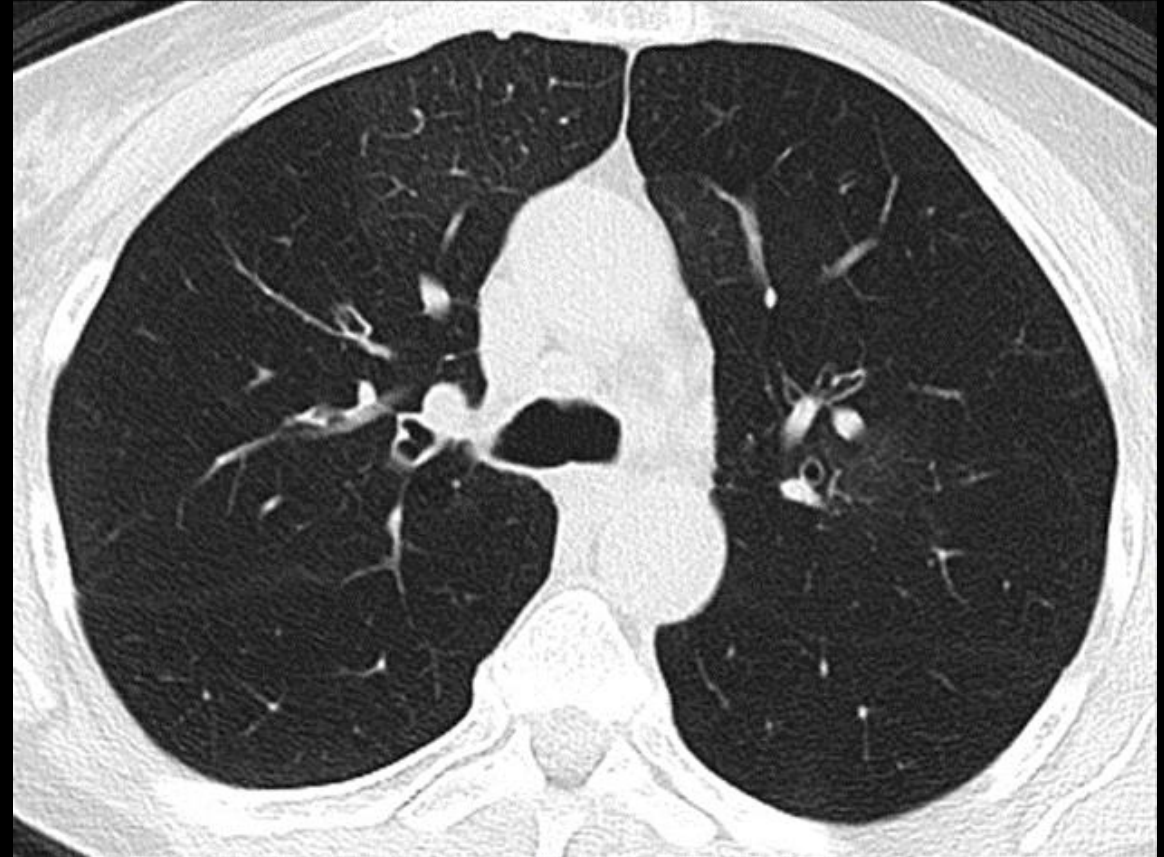


- Case: 60 Y/O female
 - **s/s: hypoxemia;**
 - Hx of scleroderma
 - On immunosuppression
 - Prior DVT
-
- D Dx:
 - Obliterated bronchiolitis?
 - Opportunistic infection?
 - Chronic thromboembolic disease?



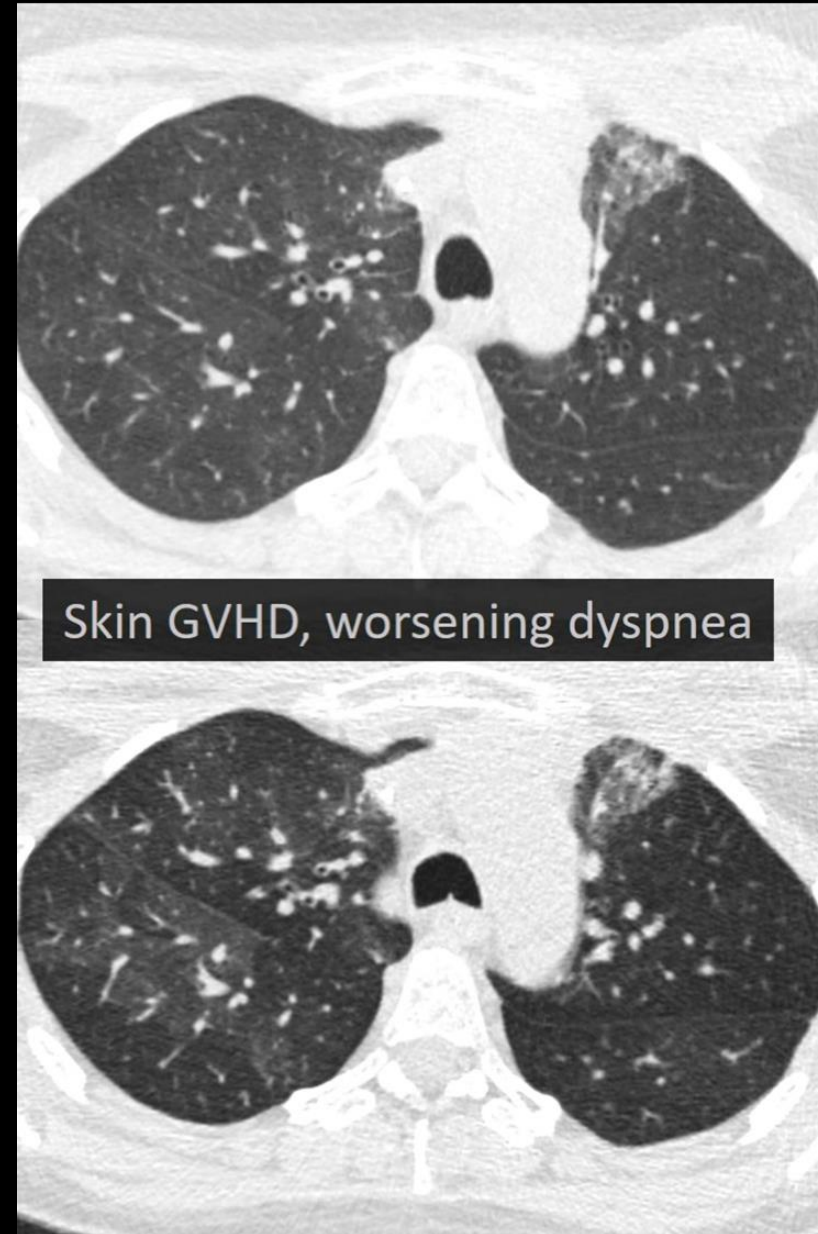

- Case
- CT chest: “normal” -> No !
-> **Almost all air trapping!**
(> 90%)
- PFT: Severe obstructive ventilatory defect!



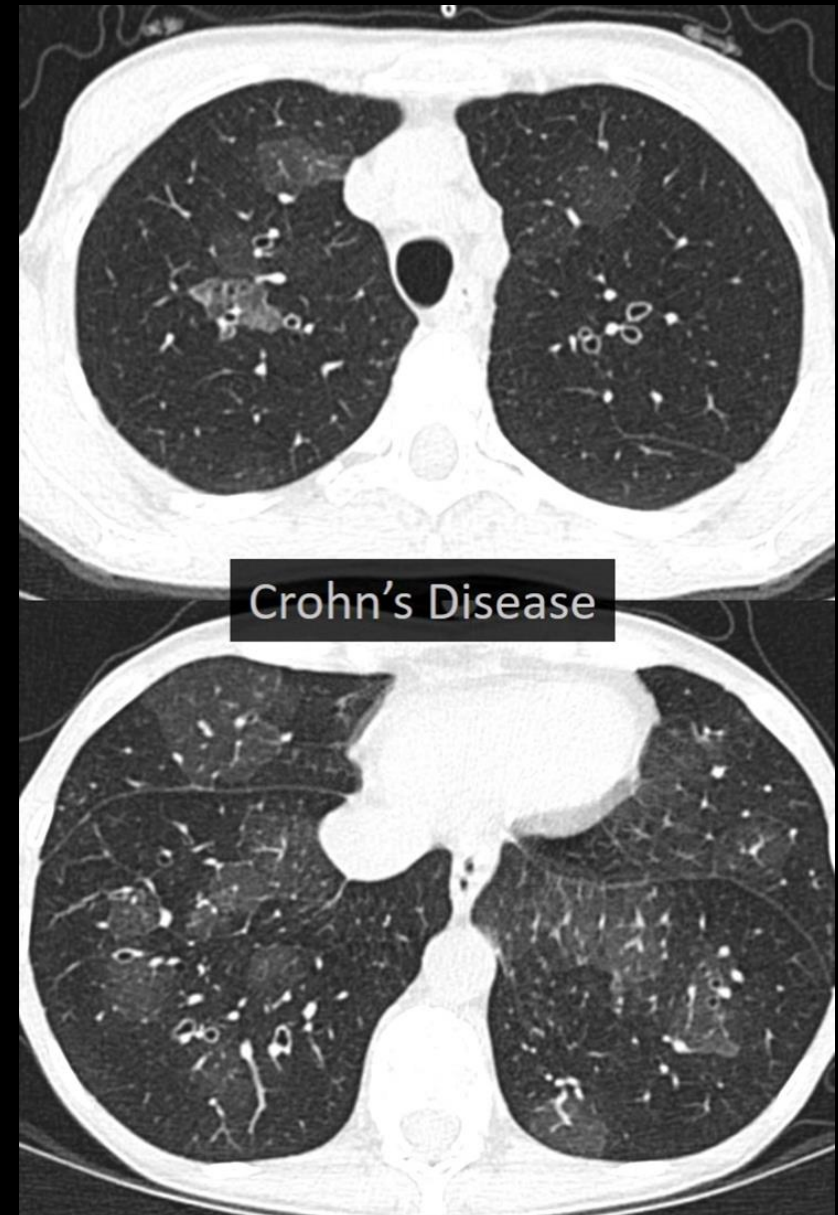
Constrictive bronchiolitis

- Think “Underlying diseases”
- Lung transplant
- Bone marrow transplant
- Autoimmune
- Inhalation
- Infection
- Diffuse idiopathic
Neuroendocrine cell
hyperplasia

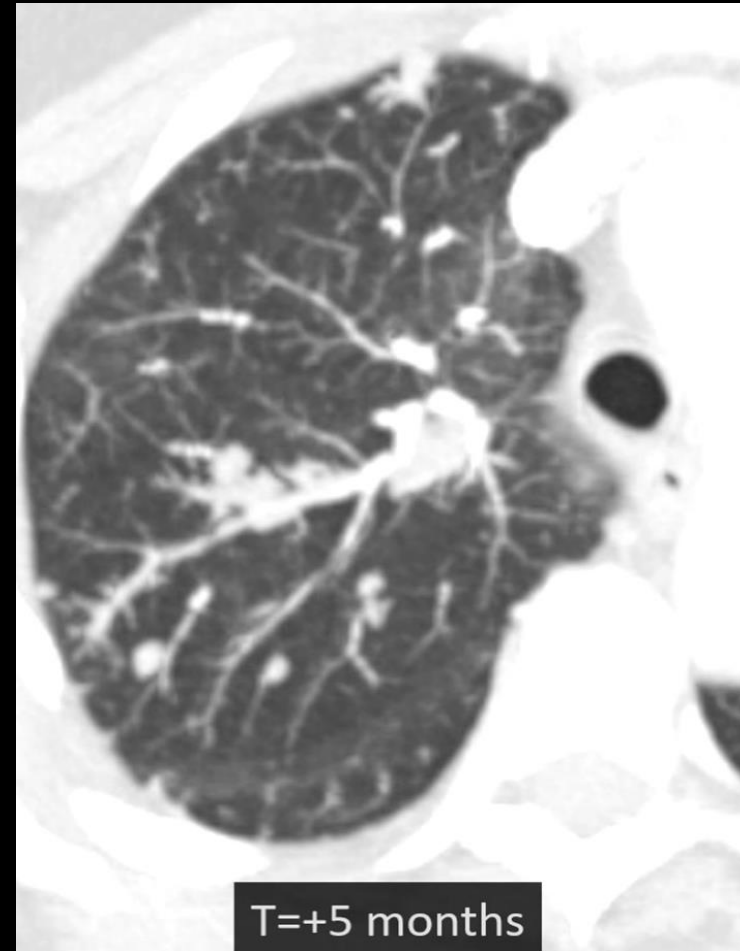
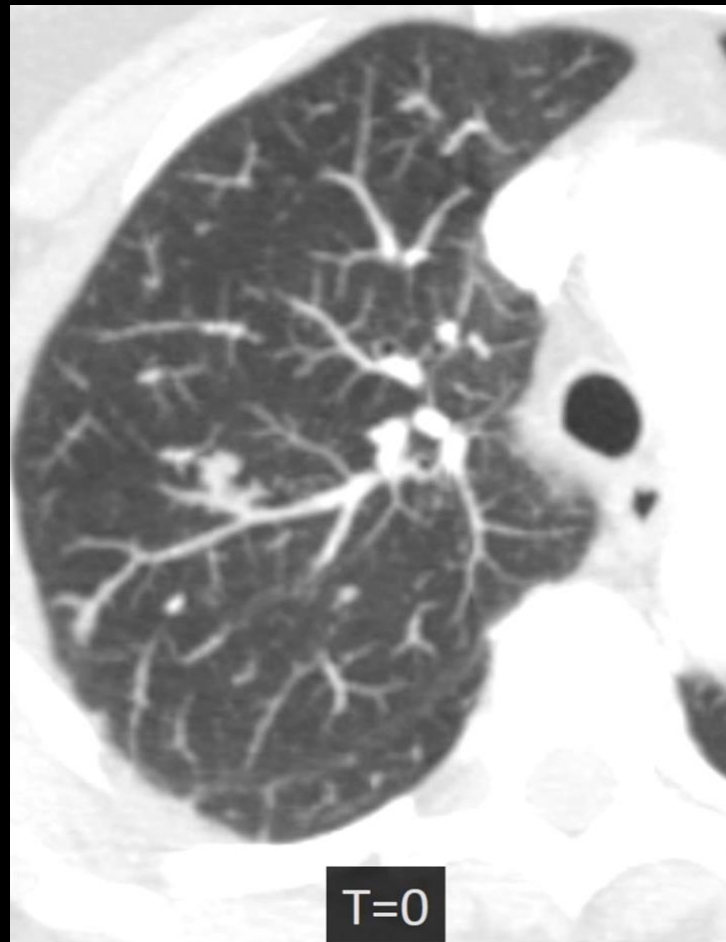

Constrictive bronchiolitis

- Think “Underlying diseases”
- Lung transplant
- Bone marrow transplant
- Autoimmune
- Inhalation
- Infection
- Diffuse idiopathic
Neuroendocrine cell
hyperplasia



Colon Cancer on chemotherapy

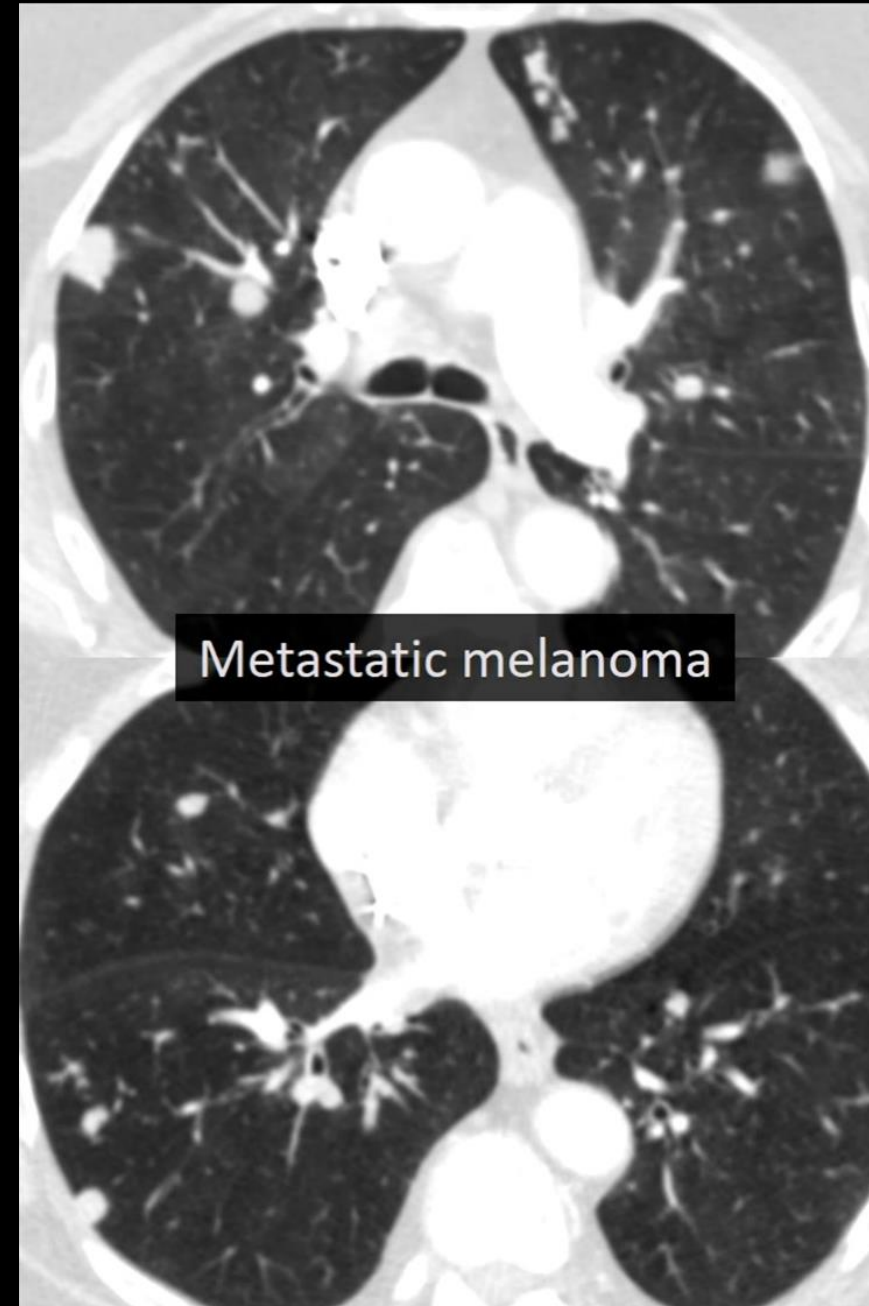


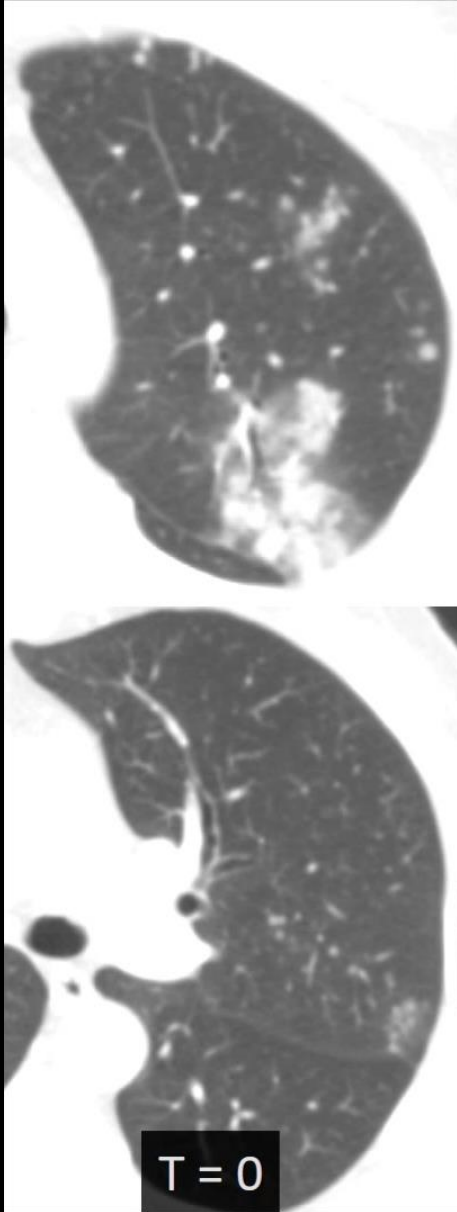
Case: Intravascular metastases

- “Beaded” appearance
- Persis/grow on multiple studies
- **Not all centrilobular nodules represent small airway disease**
- **Arteriolar disease** can manifest,
- Occasionally lymphatic disease can manifest: centrilobular process!

Case

- CT chest: centrilobular nodules
- Follow up: metastatic melanoma!
- **Intravascular metastasis: arteriolar metastasis!** (centrilobular distribution!)



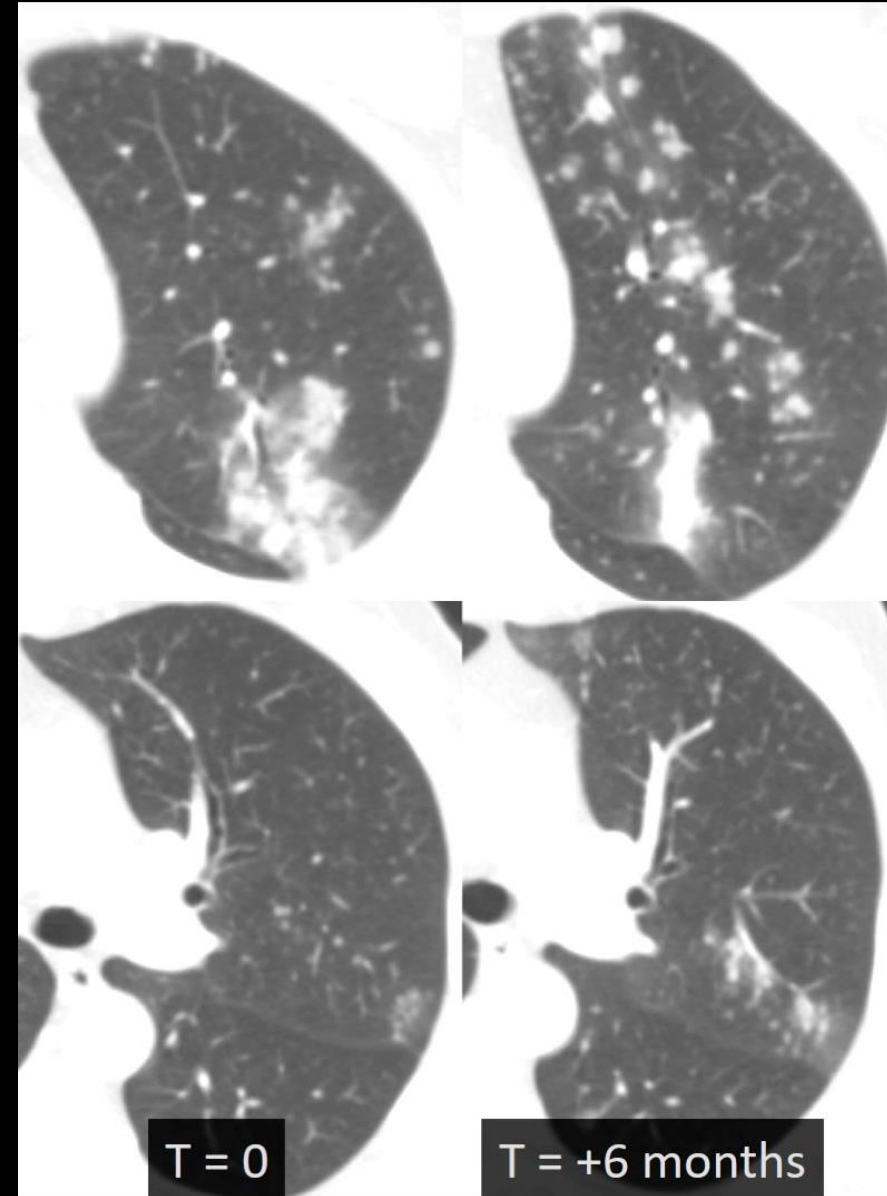


Case:

- CT chest:
- (1) Areas of consolidation
- (2) Small centrilobular nodules
- (3) Largely sparing the pleural surfaces
- **Rx: antibiotics treatment**

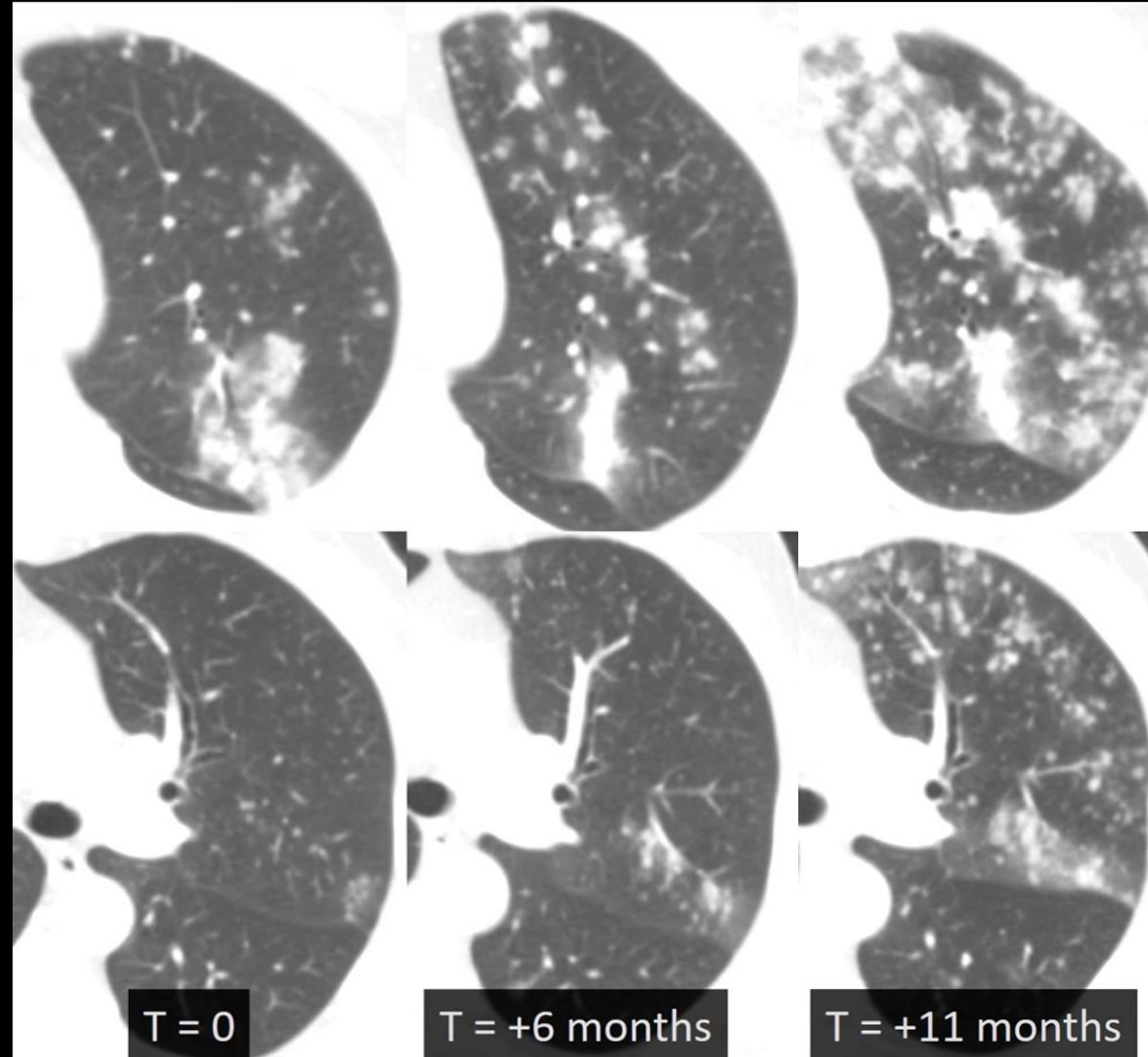
Case:

- **Follow up: 6 months later**
- *Some areas: got better*
- Some areas: got worse
- Rx: shift to another antibiotics



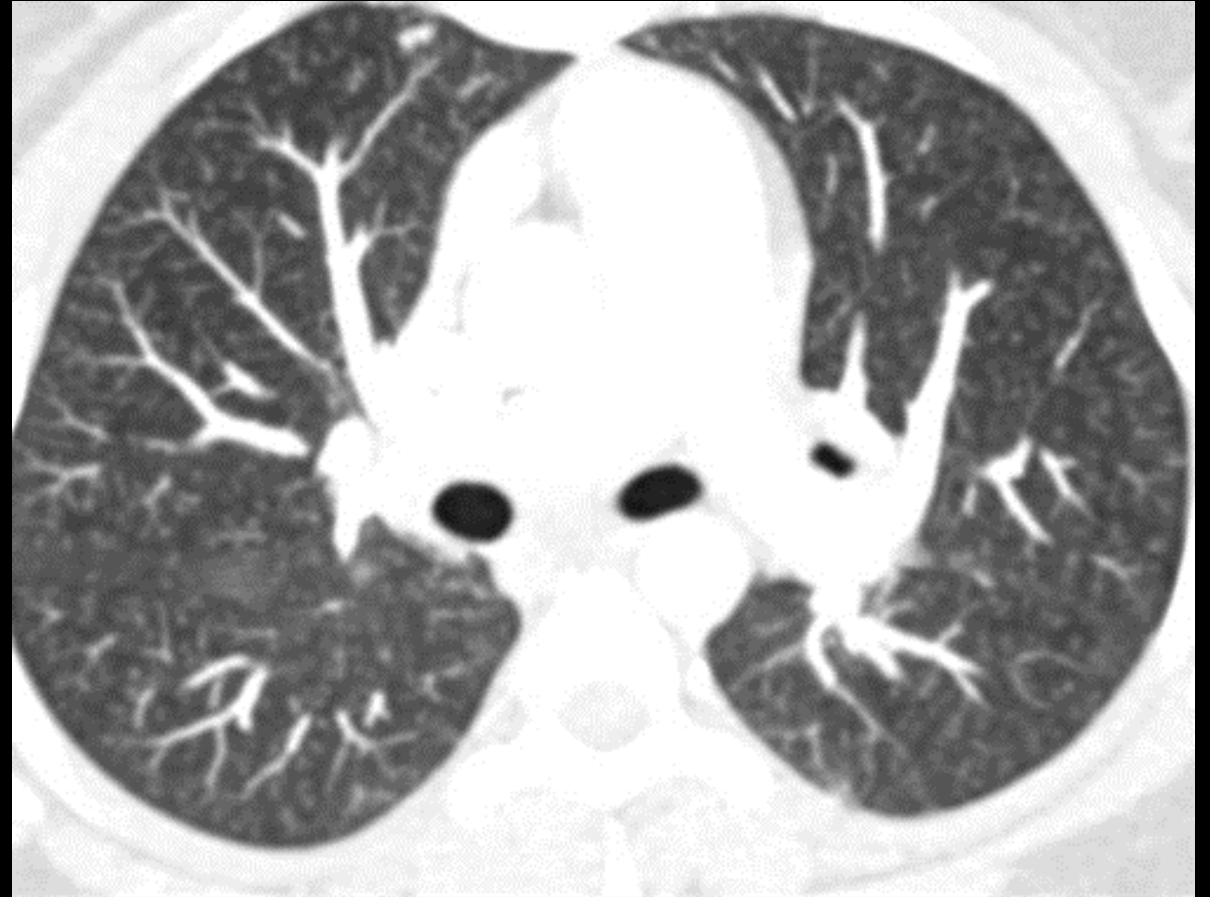
Dx: Aerogenous spread of adenocarcinoma!

- Case
- **Eleven months later**
- Tumors: Spread through the airways!



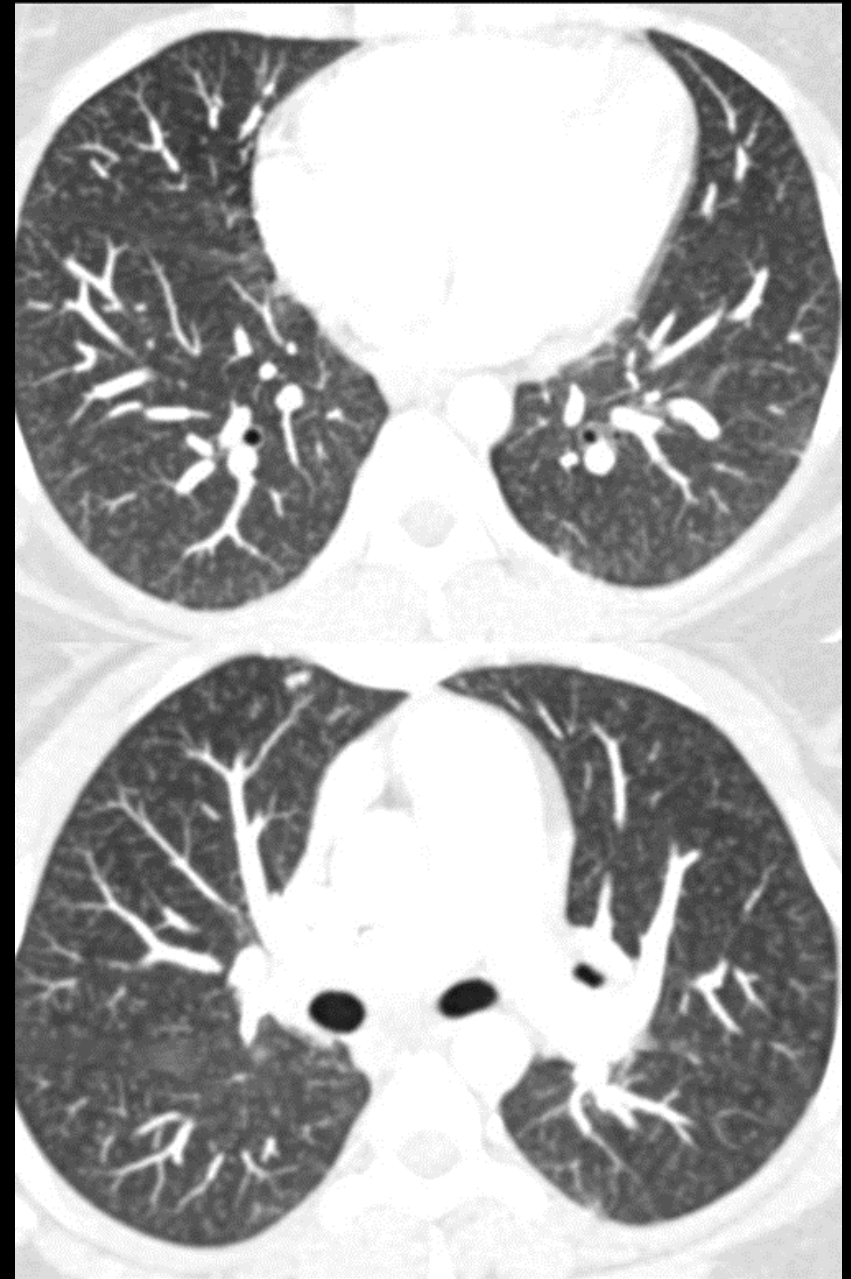
Case:24 Y/O ; PICC for Crohn's disease

- Recurrent line infections
- CT chest:
 - (1) diffuse centrilobular nodules;
 - (2) Spare the pleural surfaces
 - (3) Enlarged pulmonary artery (pulmonary artery hypertension)



Excipient Lung

- **Tablets crushed and injected intravenously**
- Excipient = inert binder of medication
- Talc -> now is methyl cellulose crows? povidone (different binders)
- Right heart failure (pulmonary hypertension)
- Unexplained fever/bacteremia
- Indwelling catheters (IV route: 請假!)
- (vs Talc granulomatosis; drug users lung; drug abusers lung)



- **Nodules: a direct sign** of small airways disease
- **Air trapping: an indirect sign** of small airways disease

■ Nodules: a direct sign of small airways disease

- **Step 1: Do the nodules touch the pleura?**
- Step 2: Tree-in-bud think infection or aspiration
- Step 3: Not all centrilobular nodules represent small airways disease

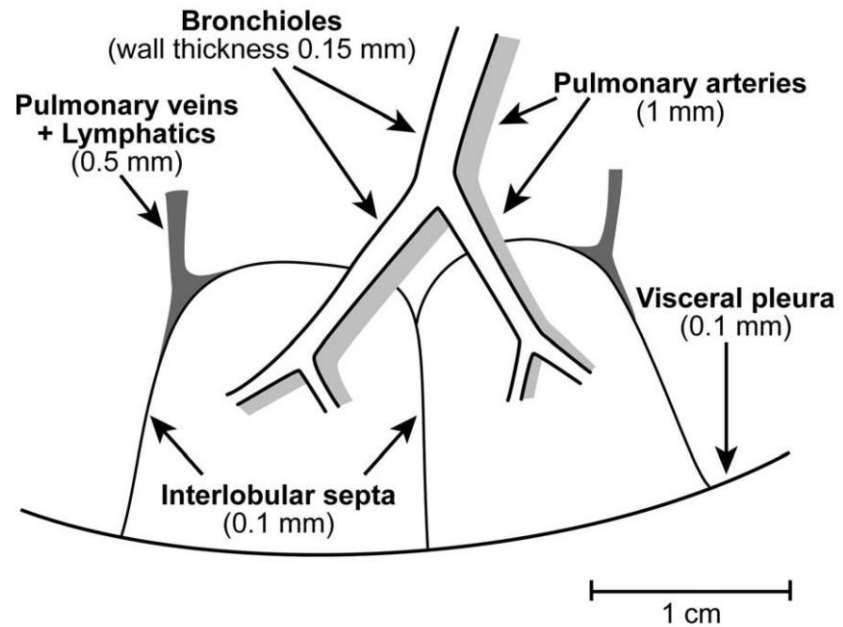
■ **Air trapping: an indirect sign of small airways disease**

- Nodules: a direct sign of small airways disease
 - Do the nodules touch the pleura?
 - Tree-in-bud think infection or aspiration
 - Not all centrilobular nodules represent small airways disease

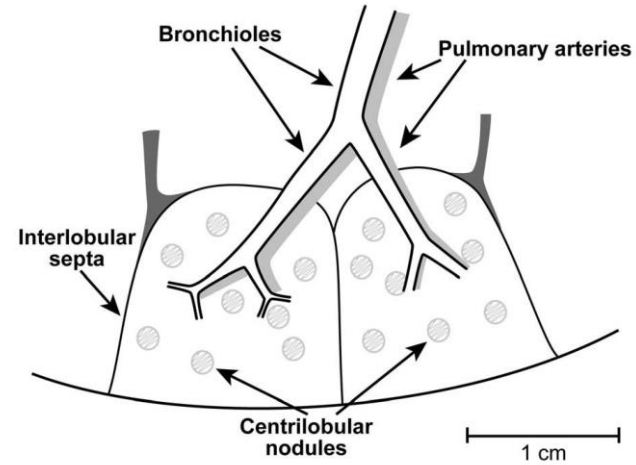
- Air trapping: an indirect sign of small airways disease
 - **Expiratory imaging is essential if you suspect small airways disease**

THANK YOU!

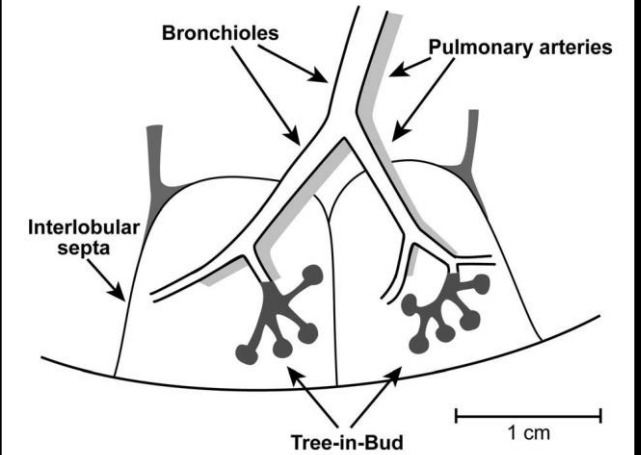
Normal Secondary Lobular Anatomy



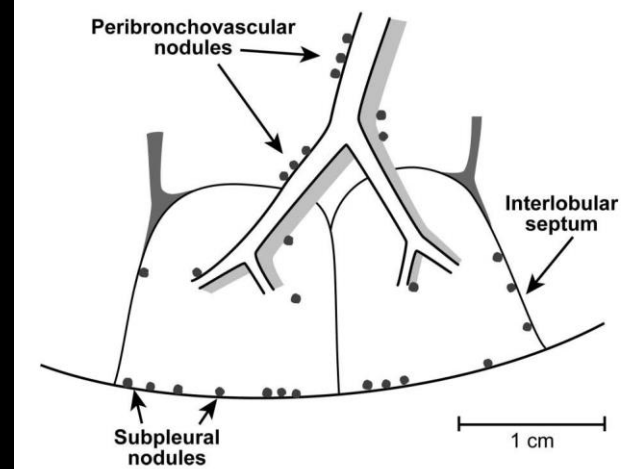
Centrilobular Disease



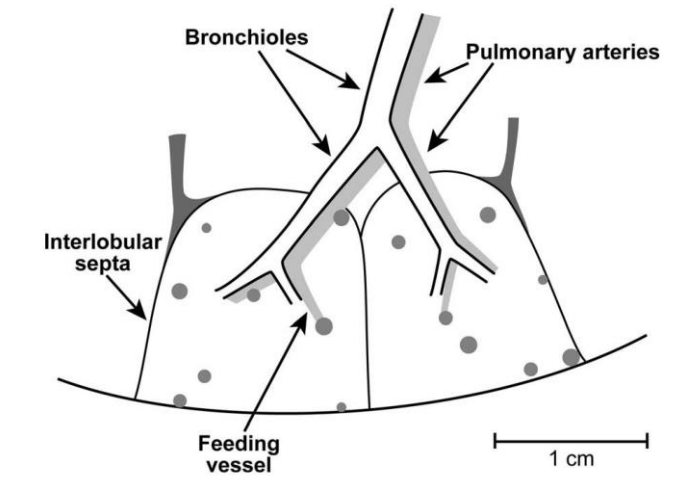
Bronchiolar Disease



Perilymphatic Disease



Random Nodules



Thank you